



Evaluation of Secondary Hydrocele after Open versus Laparoscopic Unilateral Inguinal Hernial Repair in Pediatrics

Mo'men Mohamed Mohamed El Lithy M.B, B.Ch¹, Mohamed Ahmed Abdel Aziz MD¹, Abdel Aziz Yehya Mahmoud MD¹ and Hisham Wefky Anwar Hassan MD²

¹Pediatric Surgery Department, Faculty of Medicine, Al-Azhar University, Cairo, Egypt

²General Surgery Department, Faculty of Medicine, Al-Azhar University, Cairo, Egypt

Abstract: Background; Hydrocele in children is one of the common congenital diseases in boys. The main reason for this is that intraperitoneal fluid enters the scrotum through a congenital patent processus vaginalis (PPV), thus forming hydrocele. **Aim and objectives;** the aim of this study was evaluation of secondary hydrocele after open versus laparoscopic unilateral inguinal hernial repair. **Subjects and Methods;** this was a prospective controlled randomized study for evaluation of secondary hydrocele after open versus laparoscopic unilateral inguinal hernial repair in children. It was conducted on one hundred and twenty male infants and children. It was done at Pediatric Surgery department, of Al Hussien and Sayed Galal Hospitals. **Results;** There was no statistical significant difference (p-value > 0.05) between studied groups as regard the presence of secondary hydrocele in post-operative follow up. The cases with marked secondary hydrocele at 12th week needed surgical interference. In group I laparoscopic inguinal hernial repair 1 case (1.25%) needed surgical interference to repair secondary hydrocele; on the other hand in group II open herniotomy 1 case (2.5%) needed surgical interference to repair secondary hydrocele. **Conclusion;** In conclusion, in this study there is no statistical significant difference (p-value > 0.05) between studied groups as regard the presence of secondary hydrocele in post-operative follow up, and so we don't prefer any specific technique.

[Mo'men Mohamed Mohamed El Lithy, Mohamed Ahmed Abdel Aziz, Abdel Aziz Yehya Mahmoud and Hisham Wefky Anwar Hassan. **Evaluation of Secondary Hydrocele after Open versus Laparoscopic Unilateral Inguinal Hernial Repair in Pediatrics.** *Researcher* 2020;12(12):72-78]. ISSN 1553-9865 (print); ISSN 2163-8950 (online). <http://www.sciencepub.net/researcher>. 9. doi:[10.7537/marsrsj121220.09](https://doi.org/10.7537/marsrsj121220.09).

Keywords: Laparoscopic Repair; Open Repair; Inguinal Hernias, Hydrocele, Herniotomy.

1. Introduction

The original technique of hernia repair as described by Ferguson et al. is based on the standard principles of external oblique muscle, exposure of the internal ring, exposure of the sac, and the repair of the anterior wall of the inguinal canal. However, there has been a great variability in the technique of herniotomy among the pediatric surgeons over the past six decades as has been described by Levitt et al. ⁽¹⁾

Open herniotomy has been an excellent method of repair in pediatrics. However, the potential risks of it cannot be ignored, such as the injury of spermatic vessels or vas deferens, hematoma formation, iatrogenic ascent of the testis, testicular atrophy, and so on. ⁽²⁾

Duplex Doppler sonographic assessment is the recommended diagnostic tool for identifying hydrocele. This method identifies hydrocele in patients that may have intrascrotal calcifications or non-palpable hydrocele. ⁽³⁾

Ultrasonography (USG) of the inguinal canal to detect occult inguinal hernia has been described and

its use varies in different countries. Studies show that the preoperative USG can decrease the future risk of developing metachronous inguinal hernia. ⁽⁴⁾

Reported advantages of laparoscopic hernia repair include excellent visual exposure, minimal dissection, less complications, comparable recurrence rates, and improved cosmetic results compared with the traditional open approach. In addition, laparoscopic hernia repair also allows contralateral patent process vaginalis (PPV) hernias to be defined and repaired in the same operation. ⁽⁵⁾

Unlike open herniotomy extensive tissue dissection is not done in laparoscopic hernial repair. Therefore dissection-related complications such as hematoma, wound infection and scrotal edema are expected to be lesser with laparoscopic hernial repair. Pooled data of a systematic review suggested that these complications occur in 0.9% of laparoscopic hernial repair as against 2.7% of open herniotomy. ⁽⁶⁾

As mentioned earlier, a hydrocele will present with a positive transillumination test. A scrotal

ultrasonography that is positive for hydrocele reveals fluid surrounding the testicles. ⁽⁷⁾

2. Patients and Methods

This was a prospective controlled randomized study for evaluation of secondary hydrocele after open versus laparoscopic unilateral inguinal hernial repair in children. It was conducted on one hundred and twenty male infants and children. It was done at Pediatric Surgery department, of Al Hussien and Sayed Galal Hospitals.

Ethical Consideration:

The protocol of this study was discussed and approved by the Ethical Research Committee of Pediatric Surgery department, Al-Azhar University. The procedures and the aim of the study were clearly explained to the parents. A written informed consent was obtained before enrollment of the patient into the study.

Method of randomization:

One hundred and twenty 120 patients with unilateral inguinal hernia will be randomized into two groups (**Group I & Group II**) by a random-number table sequence.

Patients were classified into two main groups:

Group I & Group II: In Group I (80 patients) Laparoscopic unilateral inguinal hernial repair. This group was subdivided into two equal groups: Group I (A): Laparoscopic purse-string unilateral inguinal hernial repair (40 patients). Group I (B): Laparoscopic unilateral herniotomy by dissecting method (40 patients). In Group II (40 patients): Open unilateral inguinal herniotomy.

Inclusion criteria:

Age: 1-4 years, Sex: Male patients only and Cases of the study: Uniateral inguinal hernia.

Exclusion criteria: Recurrent cases, complicated cases, cases with bilateral inguinal hernia and Hernia associated with hydrocele.

Preoperative preparation:

All children were subjected to full history taking, full clinical examination, and routine laboratory investigations (CBC, PT, PTT, INR, Liver and Renal

Profile). Preoperative ultrasound to confirm the diagnosis and to measure the diameter of IIR All patients received one dose of preoperative antibiotic prophylaxis.

Outcome:

Secondary hydrocele was evaluated by clinical assessment and ultrasound at 2, 4, 6, 8 and 12 weeks, postoperatively for early detection. The results obtained from this study were compared with each other and with that reported in the literature. According to ultrasound finding secondary hydrocele was classified into minimal, mild, moderate and marked hydrocele. Ultrasonography, using a 7.5 MHz transducer, is the current modality of choice as an aid for diagnosis.

Statistical analysis:

Data were analyzed using Statistical Program for Social Science (SPSS) version 15.0. Quantitative data were expressed as mean± standard deviation (SD). Qualitative data were expressed as frequency (F) and percentage.

3. Results

All studied patients were classified into 2 groups: group I (Laparoscopic unilateral inguinal hernial repair) and group II (Open unilateral inguinal herniotomy). Group I is sub-divided into: IA (Laparoscopic purse-string unilateral inguinal hernial repair) and IB (Laparoscopic unilateral herniotomy by dissecting method). **Table (1)**

There was no statistical significant difference (p-value > 0.05) between studied groups as regard the presence of secondary hydrocele in post-operative follow up. **Table (4)**

The cases with marked secondary hydrocele at 12th week needed surgical interference. In group I laparoscopic inguinal hernial repair 1 case (1.25%) needed surgical interference to repair secondary hydrocele; on the other hand in group II open herniotomy 1 case (2.5%) needed surgical interference to repair secondary hydrocele. **Table (5)**

Table (1): Classification of studied patients according to operative choice

Groups Variable		Group I Laparoscopic		Group II Open
		IA Purse-string	IB Dissection	
Studied patients (N = 120)	N	40	40	40
	%	33.3 %	33.3 %	33.3 %

Table (2): Comparison between studied groups as regard age

Variable \ Groups		I A (N = 40)	I B (N = 40)	II (N = 40)
Age (Monthes)	Mean	45	43	21

Table (3): Comparison between studied groups as regard the affected side

Variable \ Groups		I A (N = 40)	I B (N = 40)	II (N = 40)
Affected side	Rt.	30 (75%)	22 (55%)	23 (57%)
	Lt.	10 (25%)	18 (45%)	27 (43%)

Table (4): Comparison between studied groups as regard the presence of secondary hydrocele in post-operative follow up

Variable \ Groups		I A (N = 40)	I B (N = 40)	II (N = 40)	Chi-square	
					X ²	p-value
2 Weeks	No	36(90%)	28 (70%)	32 (80%)	13.9	0.16
	Minimal	0 (0%)	2 (5%)	1 (2.5%)		
	Mild	0 (0%)	4(10%)	4(10%)		
	Moderate	0 (0%)	2 (5%)	2 (5%)		
	Marked	4(10%)	4(10%)	1 (2.5%)		
4 Weeks	No	36(90%)	32 (80%)	34 (85%)	11.1	0.23
	Minimal	0 (0%)	2(5%)	1(2.5%)		
	Mild	0 (0%)	2 (5%)	4(10%)		
	Moderate	3(7.5%)	4(10%)	0 (0%)		
	Marked	1 (2.5%)	0 (0%)	1 (2.5%)		
6 Weeks	No	36(90%)	36 (90%)	36(90%)	9.1	0.08
	Minimal	0 (0%)	0 (0%)	3(7.5%)		
	Mild	3 (7.5%)	4 (10%)	0 (0%)		
	Moderate	0 (0%)	0 (0%)	0 (0%)		
	Marked	1 (2.5%)	0 (0%)	1 (2.5%)		
8 Weeks	No	36 (90%)	36(90%)	39 (97.5%)	4.2	0.14
	Minimal	3 (7.5%)	4(10%)	0 (0%)		
	Mild	0 (0%)	0 (0%)	0 (0%)		
	Moderate	0 (0%)	0 (0%)	0 (0%)		
	Marked	1 (2.5%)	0 (0%)	1 (2.5%)		
12 Week	No	39 (97.5%)	40 (100%)	39 (97.5%)	-----	-----
	Minimal	0 (0%)	0 (0%)	0 (0%)		
	Mild	0 (0%)	0 (0%)	0 (0%)		
	Moderate	0 (0%)	0 (0%)	0 (0%)		
	Marked	1 (2.5%)	0 (0%)	1 (2.5%)		

Table (5): Comparison between studied groups (group I and Group II) as regard the presence of secondary hydrocele in post-operative follow up

Groups Variable		Group I laparoscopic inguinal hernial repair (N = 80)	Group II open herniotomy (N = 40)
2 Weeks	No	64 (80%)	32 (80%)
	Minimal	2 (2.5%)	1 (2.5%)
	Mild	4 (5%)	4 (10%)
	Moderate	2 (2.5%)	2 (5%)
	Marked	8 (10%)	1 (2.5%)
4 Weeks	No	68 (85%)	34 (85%)
	Minimal	2(2.5%)	1 (2.5%)
	Mild	2(2.5%)	4(10%)
	Moderate	7(8.75%)	0 (0%)
	Marked	1 (1.25%)	1 (2.5%)
6 Weeks	No	72 (90%)	36 (90%)
	Minimal	0 (0%)	3 (7.5%)
	Mild	7 (8.75%)	0 (0%)
	Moderate	0 (0%)	0 (0%)
	Marked	1 (1.25%)	1 (2.5%)
8 Weeks	No	72 (90%)	39 (97.5%)
	Minimal	7 (8.75%)	0 (0%)
	Mild	0 (0%)	0 (0%)
	Moderate	0 (0%)	0 (0%)
	Marked	1 (1.25%)	1 (2.5%)
12 Week	No	79 (98.75%)	39 (97.5%)
	Minimal	0 (0%)	0 (0%)
	Mild	0 (0%)	0 (0%)
	Moderate	0 (0%)	0 (0%)
	Marked	1 (1.25%)	1 (2.5%)

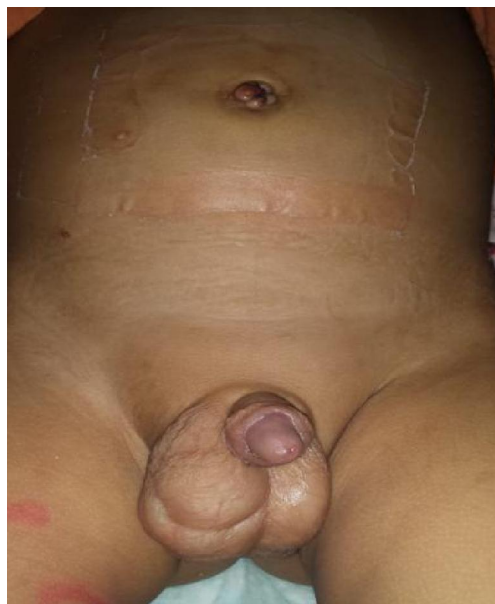

Fig (1): Marked Rt secondary hydrocele after Rt laparoscopic inguinal hernial repair by purse-string at 12th week postoperative.

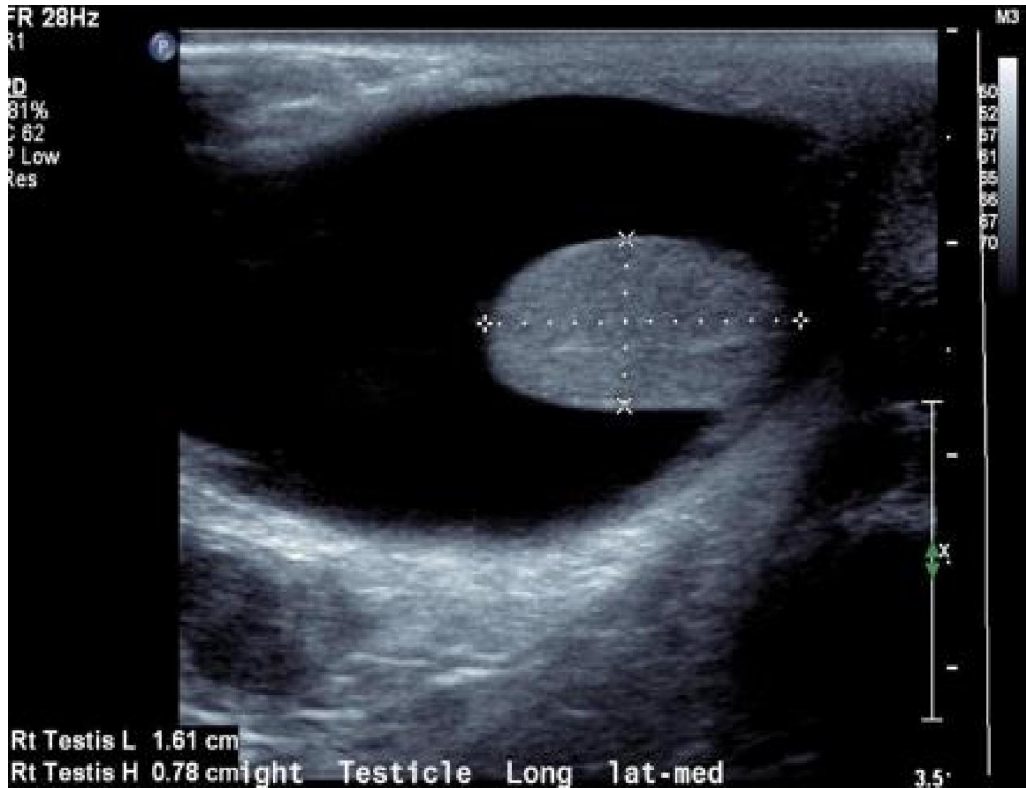


Fig (2): Scrotal ultrasound shows Marked Rt secondary hydrocele after Rt laparoscopic hernial repair by purse-string.

4. Discussion

Inguinal hernia is a common problem among children, and herniotomy constitutes a major portion (>15%) among pediatric surgical practice. ⁽⁸⁾

The standard surgical treatment for inguinal hernia, in children, is limited to ligation of the hernia sac at the internal inguinal ring without narrowing the ring. ⁽⁹⁾

The advantage for laparoscopy in inguinal hernia repair is to approach inguinal hernias in children from the site of origin leaving the outer anterior abdominal wall intact. The laparoscopic approach is rapidly gaining popularity with more and more studies validating its feasibility, safety, and efficacy. ⁽¹⁰⁾

Open herniotomy in children has been reported to have recurrence rates of 0.8–3.8% (138). While in laparoscopic hernia repair it is ranged from 0.7% to 4.5%. That is may be due to the presence of skip areas during placement of purse-string sutures as well as the tension resulting from intracorporeal knotting particularly in closure of large defects.

The study of **Shaoguang Feng et al**, ⁽⁶⁾ who did five randomized clinical trials with a total of 553 children (OH 278, LH 275), shows that less total postoperative complications was found in the LH group, especially for major postoperative

complications in male children. Yet there is no significant difference regarding recurrences.

This study is a prospective study and concerned with detection of secondary hydrocele, on the other hand the other researches don't specify the occurrence of secondary hydrocele as a single complication.

The study of **Ciro Esposito et al**, ⁽¹¹⁾ who did A literature search on all studies published from 1994 to 2014, reporting on outcomes of OH and LH, in terms of operative time, recurrence rate and other complications, finding of rare hernias, and incidence of contralateral patency, shows that complications such as wound infections, hydrocele, iatrogenic cryptorchidism, and testicular atrophy were significantly higher for OH compared with LH (P =.001).

The study of **Mairi Steven et al**, ⁽¹²⁾ who did a retrospective review of all children undergoing LH repair from January 2010 to December 2013 versus a historic cohort of all OH repairs between January 2010 and December 2011 was conducted. LH repair was performed by a simple purse string technique using nonabsorbable braided suture. Recurrence rate was 2.9% in the LH group and 3.9% in the OH group, and overall complication rates were 7.8% and 9.9%, respectively steven 2016.

The study of **L. L. Zhu et al**,⁽¹³⁾ who did analyze all the patients with inguinal hernia who underwent surgery in their hospital from January 1, 2015 to December 31, 2015. There were 1125 patients, of who 202 patients received laparoscopic inguinal hernia repair (group A) and 923 patients received open herniotomy (group B). Three cases developed hydrocele in the early postoperative follow-up period in group A, while in group B postoperative hydrocele was reported in 78 cases. However, all cases responded well to conservative management within 3 weeks.

The study of **Yasser Ashour et al**, who did a prospective controlled randomized study of laparoscopic repair of congenital inguinal hernia [CIH], was conducted over ninety patients at the Pediatric Surgery Department, Al-Azhar University Hospitals, Cairo, over a period of 2 years from April 2014 to April 2016. They were randomized into two equal groups: Group I (n = 45) received Intracorporeal purse string suture ligation of the hernia sac in at IIR leaving the sac intact; and Group II (n = 45) received disconnection of the hernia sac with intracorporeal suture of proximal part at IIR. Early follow up was done within 2 weeks after the procedure. In group I, postoperative hydrocele developed in 12 cases (24.5%) but resolved conservatively without surgical intervention within 3 weeks. In group II postoperative hydrocele appeared in 4 cases (8.9%) and also spontaneously resolved. Post-operative hydrocele and hematoma are acceptable complications after laparoscopic hernia repair as they resolve spontaneously.

In the study of **Tam et al**,⁽¹⁴⁾ postoperative hydrocele also was reported (1%) and was treated non surgically. In another series of **Shalaby et al**,⁽¹⁵⁾ there were 4 reported hydroceles (0.57%), one required percutaneous aspiration, and the others responded well to conservative treatment.

In our study, results showed that 4 cases (10%) of cases of laparoscopic purse-string hernial repair developed secondary hydrocele, 3 cases (7.5%) resolved conservatively without surgical intervention and 1 case (2.5%) needed surgical intervention to repair secondary hydrocele, also results showed that 12 cases (30%) of cases of laparoscopic hernial repair by dissection developed secondary hydrocele and were treated conservatively without surgery, on the other hand results showed that 8 cases (20%) of cases of open herniotomy developed secondary hydrocele, 7 cases (17.5%) resolved conservatively without surgical intervention and 1 case (2.5%) needed surgical intervention to repair secondary hydrocele.

In our study follow up was done 2, 4, 6, 8 and 12 weeks after the procedure.

At the 2nd week after procedure, In Group **I A** post-operative hydrocele reported in 4 cases (10 %) and all of these cases were marked hydrocele. In Group **I B** post-operative hydrocele reported in 12 cases (30 %) which subdivided into 2 cases (5%) were minimal hydrocele, 4 cases (10%) were mild hydrocele, 2 cases (5%) were moderate hydrocele and 4 cases (10%) were marked hydrocele. In Group **II** post-operative hydrocele reported in 8 cases (20%) which subdivided into 1 case (2.5%) was minimal hydrocele, 4 cases (10%) were mild hydrocele, 2 cases (5%) were moderate hydrocele and 1 case (2.5%) was marked hydrocele.

At the 12th week after procedure, In Group **I A** post-operative hydrocele reported in 1 case (2.5 %) which was marked hydrocele. In Group **I B** all cases of post-operative hydrocele spontaneously resolved conservatively without surgical intervention. In Group **II** post-operative hydrocele reported in 1 case (2.5%) which was marked hydrocele.

Conclusion:

In conclusion, in this study there is no statistical significant difference (p-value > 0.05) between studied groups as regard the presence of secondary hydrocele in post-operative follow up, and so we don't prefer any specific technique.

Conflict of Interest:

The Authors declare that there is no conflict of interest

References

- [1]. Ladd WE and Gross RE. Abdominal Surgery of surgery of infancy and childhood. Philadelphia: WB Saunders; 1941.
- [2]. Shalaby R, Ismail M, Dorgham A. Laparoscopic hernia repair in infancy and childhood: evaluation of 2 different techniques. J Pediatr Surg. 2010; 45:2210–2216.
- [3]. Hussein O, El Setouhy M, Ahmed ES, Kandil AM, Ramzy RM, Helmy H, et al. Duplex Doppler sonographic assessment of the effects of diethylcarbazine and albendazole therapy on adult filarial worms and adjacent host tissues in Bancroftian filariasis. Am J Trop Med Hyg 2004; 71:471–477.
- [4]. Toki A, Watanabe Y, Sasaki K. Ultrasonographic diagnosis for potential contralateral inguinal hernia in children. J Pediatr Surg 2003; 38:224–6.
- [5]. Lee Y and Liang J. “Experience with 450 cases of microlaparoscopic herniotomy in infants and children,” Pediatric Endosurgery

- and Innovative Techniques, 2002; 6(1): 25–28.
- [6]. Feng S, Zhao L, Liao Z, Chen X. Open versus laparoscopic inguinal herniotomy in children: a systematic review and meta-analysis focusing on postoperative complications. *Surg Laparosc Endosc Percutan Tech.* 2015; 25: 275–80.
- [7]. Davis JE and Silverman M. Scrotal emergencies. *Emerg Med Clin North Am.* 2011; 29(3):469-484.
- [8]. Cheung TT and Chan KL. Laparoscopic inguinal hernia repair in children. *Ann Coll Surg HK.* 2003; 7:94–96.
- [9]. Parelkar SV, Oak S, Gupta R. Laparoscopic inguinal hernia repair in the pediatric age group; experience with 437 children. *J Pediatr Surg.* 2010; 45: 789-92.
- [10]. Bharathi RS, Arora M, Baskaran V. Pediatric inguinal hernia: laparoscopic versus open surgery. *JSLs.* 2008; 12, 277-81.
- [11]. Esposito C, Peter SD, Escolino M, Juang D, Settini A, Holcomb GW. Laparoscopic versus open inguinal hernia repair in pediatric patients: a systematic review. *J Laparoendosc Adv Surg Tech A.* 2014; 24: 811–8.
- [12]. Steven M, Carson P, Bell S, Ward R, McHoney M. “Simple purse string laparoscopic versus open hernia repair,” *Journal of Laparoendoscopic and Advanced Surgical Techniques A,* 2016; 26(2): 144-147.
- [13]. Zhu LL, Xu WJ, Liu JB, Huang X, Lv ZB. “Comparison of laparoscopic hernia repair and open herniotomy in children,” a retrospective cohort study *A,* 2017; *Hernia,* 2017; 21(3), 417-423.
- [14]. Tam YH, Lee KH, Sihoe JD. Laparoscopic hernia repair in children by the hook method. A single-center series of 433 consecutive patients. *J Pediatr Surg.* 2009; 44, 1502-5.
- [15]. Shalaby R, Ismail M, Dorgham A. Laparoscopic hernia repair in infancy and childhood: evaluation of 2 different techniques. *J Pediatr Surg.* 2010; 45, 2210-6.

9/3/2021