

## Management of Medio-lateral Instability after Primary Total Knee Replacement

Tharwat Mohamed Abdel-Rahman, Abdel-Hamed Abdel-Aziz Atallah, Mohamed Ahmed Khalil

Orthopedics department, faculty of medicine (for Girls), Al-Azhar University, Cairo, Egypt.  
[mohamed1ahmedkhalil@gmail.com](mailto:mohamed1ahmedkhalil@gmail.com)

**Abstract: Background:** Instability is defined as the abnormal and excessive displacement of the articular elements that leads to clinical failure of the arthroplasty and is one of the most common causes of aseptic failure following total knee replacement. Instability may be early or late, and may involve global instability or anteroposterior (flexion) instability or mediolateral (extension) instability. **Objective:** The different ways and tools needed to evaluate mediolateral instability after primary total knee replacement are covered as well as possible aetiologies of mediolateral unstable replaced knee along with treatment options and management for mediolateral unstable knee prosthesis and their results. **Method:** Systematic review comparing 4 studies of total 304 studies concerning management of mediolateral instability after primary total knee replacement. Outcomes from included trials will be combined using the systematic review manager software and manually screened for eligibility to be included. PRISMA (preferred reporting items for Systematic reviews and Meta-Analyses) flowchart will be produced based on the search results. **Results:** In this systematic review we used to calculate the mean preoperative and postoperative IKS, FKS, HSS and ROM among 114 patients with follow-up varying from 2-7 years to find satisfactory knee scores after revision using the appropriate prosthesis comparing IKS score vary preoperatively from (42-45) and postoperatively to (77-87), HSS score vary preoperatively from (34-53) and postoperatively to (83-89) and for FKS score vary preoperatively from (21.5-45) and postoperatively to ( 51-84) with ROM preoperatively from (79-109) and postoperatively to ( 111-122). **Conclusion:** A revision TKA with or without a more constrained prosthesis regardless of the implant types would be a definite solution to TKA instability, but the solution according to the causes is very effective and seems to have a chance of avoidance of unnecessary over-constrained implant selection in a revision surgery for an unstable TKA.

[Tharwat Mohamed Abdel-Rahman, Abdel-Hamed Abdel-Aziz Atallah, Mohamed Ahmed Khalil. **Management of Medio-lateral Instability after Primary Total Knee Replacement.** *Researcher* 2019;11(7):66-71]. ISSN 1553-9865 (print); ISSN 2163-8950 (online). <http://www.sciencepub.net/researcher>. 6. doi:[10.7537/marsrj110719.06](https://doi.org/10.7537/marsrj110719.06).

**Keywords:** Totalkneearthroplasty-Instabilityaftertotalkneearthroplasty-Revisionaftertotalkneearthroplasty-TKA-Ligamentbalancing Mediolateral instability.

### 1. Introduction

Knee prosthesis instability is cited as the third most frequent cause of failure of total knee arthroplasty<sup>(1)</sup>.

It has been reported that 10–22% of revision surgeries after TKA are due to instability<sup>(2)</sup>.

Instability is one of the most common causes of failure following total knee arthroplasty. There are multiple known etiologies and the presentation can vary greatly from subtle intermittent pain to frank dislocation<sup>(3)</sup>.

KPI is defined as the abnormal and excessive displacement of the articular elements that leads to clinical failure of the arthroplasty and is one of the most common causes of aseptic failure following total knee replacement. Instability may be early or late, and may involve global instability or anteroposterior (flexion) instability or mediolateral (extension) instability<sup>(1)</sup>.

Acute instability is related to intraoperative injuries or excessive release of important coronal stabilizers such as the medial collateral ligament in extension or the posterolateral corner in flexion<sup>(2)</sup>.

Chronic instability in extension is due to imbalance in the medial and lateral ligamentous soft tissues. This is likely to occur when there is inadequate release of the contracted side of either a severe varus or valgus preoperative deformity. The problem is compounded when there is failure to restore a neutral mechanical alignment<sup>(2)</sup>.

Further classification for mediolateral instability is symmetrical or asymmetrical depending on the shape of extension space whether is rectangular in symmetrical or trapezoid in asymmetrical<sup>(4)</sup>.

When addressing instability after TKA, it is critical to determine the root cause of the problem as well as evaluate for other causes of pain such as problems with the patellofemoral articulation, muscular weakness, component loosening, and infection or aseptic loosening. Patient-related risk factors predisposing to post-operative instability include deformity requiring a large surgical correction and aggressive ligament release, general or regional neuromuscular pathology, and hip or foot deformities<sup>(1)</sup>.

So this systematic review is conducted to identify definition, types, and management strategies for mediolateral (varus/valgus) instability starting by different techniques for ligament balancing and release to overcome instability after arthroplasty ending in revision to more constrained prosthesis.

Finally, KPI can be prevented in most cases with appropriate selection of implants and good surgical technique.

**Aim of the Work**

Asystematic review of literature to evaluate mediolateral (varus/valgus) instability after primary total knee arthroplasty.

This review aims to discuss anatomical as well as relevant biomechanical consideration of the knee joint, with mentioning biomechanical background of knee replacement designs.

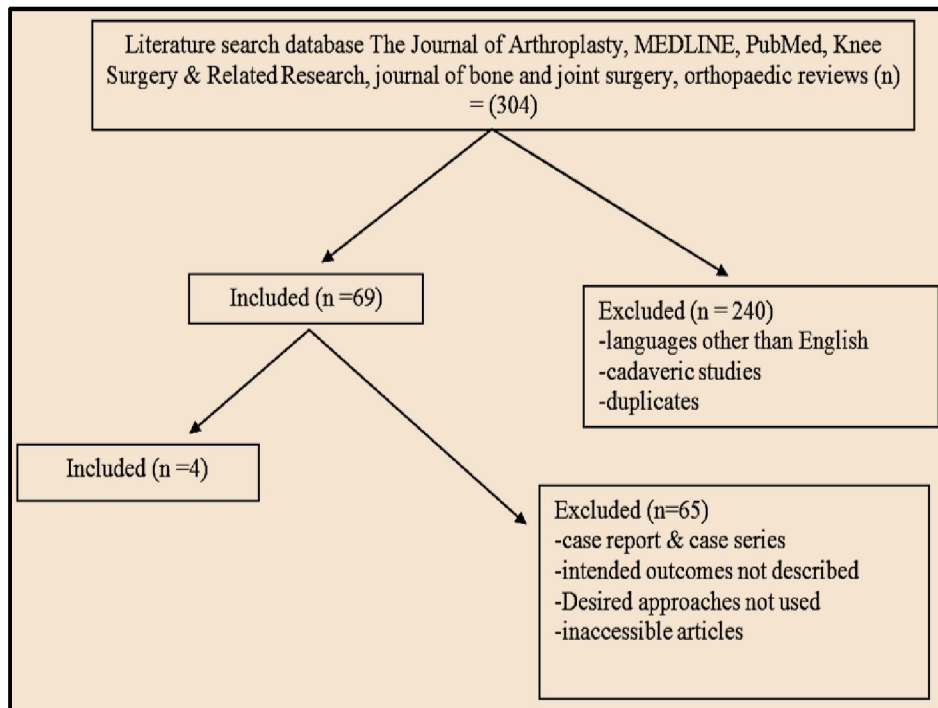
The different ways and tools needed to evaluate mediolateral instability after primary total knee replacement are covered as well as possible aetiologies of mediolateral unstable replaced knee along with treatment options and management for mediolateral unstable knee prothesis and their results.

**2. Materials and Methods**

Literature searches were conducted using the following databases: The Journal of Arthroplasty, MEDLINE, PubMed, Knee Surgery & Related Research, journal of bone and joint surgery, orthopaedic reviews using the following Search keywords: To talk near throplasty-Instability after to talk neearthroplasty-Revision after to talk near throplasty-TKA-Ligament balancing Mediolateral instability for published studies from2000 – 2017.

After application of our inclusion criteria & focusing on the intended outcomes, the electronic comprehensive literature search identified 4 studies of total 304 studies concerning management of mediolateral instability after primary total knee replacement.

Outcomes from included trials will be combined using the systematic review manager software and manually screened for eligibility to be included. PRISMA (preferred reporting items for Systematic reviews and Meta-Analyses) flowchart will be produced based on the search results & the inclusion/exclusion criteria.



**Figure (1):** PRISMA flowchart of article selection for qualitative analysis of literature

**Inclusion criteria:**

Medio-lateral instability after primary total knee arthroplasty of all clinical studies (prospective and retrospective). Search articles include publications from 2000 through 2017and data extracted will be

aggregated approach and a narrative synthesis provided.

**Exclusion criteria:**

Global instability besides review articles and conference abstracts in non-English.

**3. Results**

Our included studies were published between 2010 & 2014. Earliest included study was published by **Daniel Herna´ndez-Vaquero** 2010 & reviewed the results for management of both medial and lateral collateral ligament deficiencies leading to mediolateral instability after total knee replacement & latest study was published by **Sang Jun Song** 2014

which reviewed the results of management of mediolateral instability after total knee replacement according to flexion /extension gap mismatch or isolated ligament deficiencies.

The following **Table (1)** shows type of each study & date of publication; while **Table (2)** shows Summary of patients data and follow up.

**Table (1):** Type of studies & date of publication

Author	Year of publish	Type of study
Sang Jun Song, <sup>(69)</sup>	2014	Retrospective
Daniel Herna´ndez-Vaquero, <sup>(70)</sup>	2010	Retrospective
Michele Vasso, <sup>(71)</sup>	2013	Retrospective
In-Soo Song, <sup>(72)</sup>	2014	Retrospective

**Table (2):** Summary of patients data and follow up

Author	No of patients	No of revisions	Mean age	Male: female ratio	Median follow up in months
Sang Jun Song, <sup>(69)</sup>	47 from 78	47 from 83	76	5:8	67.2
Daniel Herna´ndez-Vaquero, <sup>(70)</sup>	21 from 25	21 from 25	77	1:4	24
Michele Vasso, <sup>(71)</sup>	57	60	72	7:12	108
In-Soo Song, <sup>(72)</sup>	19 from 22	19 from 24	71	2:9	33.8

**Table (3)** showing classifications of mediolateral instability according to each author and the way of management whether by polyethylene (PE) exchange or by revision by whatever design while **Table (4)**

shows summary of median preoperative and postoperative international knee score (IKS), hospital for special surgery knee score (HSS), functional knee score (FKS) and range of motion (ROM).

**Table (3):** Summary of study characteristics

Author	category	No of knees		
		PE exchange	Revision	Total
Sang Jun Song et al. <sup>(69)</sup>	Flexion/extension mismatch	8	16 cck	24   47
	Component malposition	0	12 cck	
	Isolated ligament insufficiency	4	7 cck	
Daniel Hernandez-Vaquero Et al. <sup>(70)</sup>	Lateral collateral deficiency		5 RHP	21
	Medial collateral deficiency		3 RHP	
	Medial and Lateral collaterals deficiency		13 RHP	
Michele Vasso et al. <sup>(71)</sup>	Intact collateral ligaments		7 PS	60
	Collateral Ligament deficiency		35 CCK	
	absent collateral ligaments		18 RHP	
In-Soo Song et al <sup>(72)</sup>	Coronal instability with posteromedial polyethylene wear and lateral ligament attenuation		Revision with long stem (10) Revision without long stem (3)	13
	Coronal instability with posteromedial wear of polyethylene insert	Upsized bearing exchange (4) Same sized bearing exchange (2)		6
Total				147

**Table (4):** Summary of median preoperative and postoperative data

	Median IKS		Median HSS		Median FKS		Median ROM	
	PRE	POST	PRE	POST	PRE	POST	PRE	POST
Sang Jun Song et al. <sup>(69)</sup>	45	87	NR	NR	45	82	109	111
Daniel Herna´ndez-Vaquero et al. <sup>(70)</sup>	40	77	NR	NR	36	51	NR	NR
Michele Vasso et al. <sup>(71)</sup>	41	81	34	83	21.5	79	79	121
In-Soo Song et al <sup>(72)</sup>	42	80	53	89	42	84	123	122

The following **Fig. (2)** represents a diagram that compares the mean preoperative and postoperative IKS between chosen articles, while **Fig. (3)** represents a diagram that compares the mean preoperative and postoperative FKS between chosen articles.

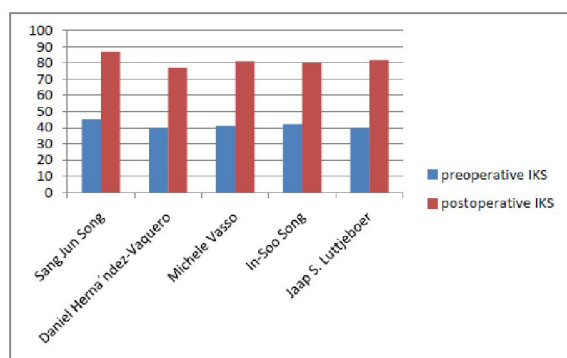


Figure (2): Chart showing preoperative and postoperative IKS

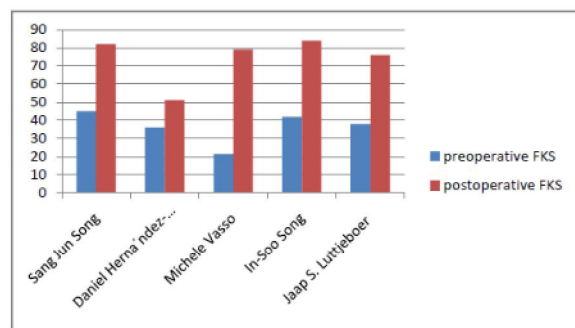


Figure (3): Chart showing preoperative and postoperative FKS

**Details**

**Sang Jun Song et al. <sup>(69)</sup>** (published 2014) Stated that surgical treatment modalities for instability are not one kind of procedure, but several different procedures, according to the category of causes. They ranged from exchange of PE insert to total revision TKA with variable level of constraint with complex combination of the combined surgeries. It is well known that the results of isolated exchange of PE insert are usually poor and unpredictable.

**Daniel Herna´ndez-Vaquero et al. <sup>(6)</sup>** (published 2010) study has demonstrated rotating-

Comparing mean preoperative and postoperative HSS between chosen articles as shown in **(fig 4)** and median preoperative and postoperative ROM compared in **(fig 5)**

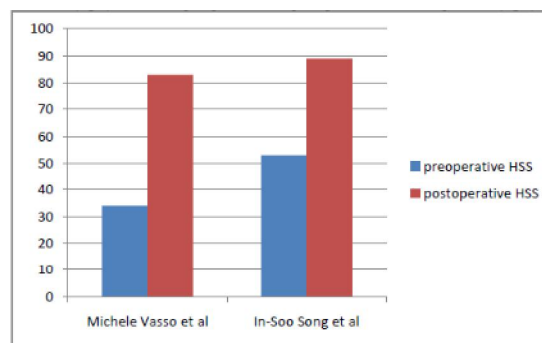


Figure (4): Chart showing preoperative and postoperative HSS

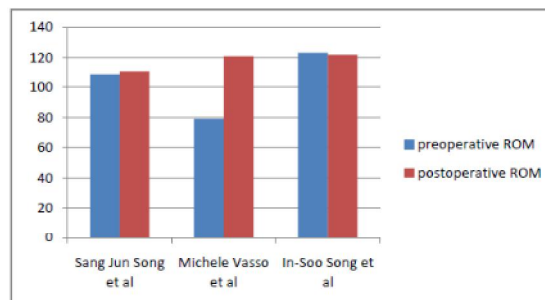


Figure (5): Chart showing preoperative and postoperative ROM

hinge prostheses are a correct alternative for ligamentous deficiencies and severe types of bone loss in revision surgery. We obtained an improvement in function, pain, and ROM of the knee. No patient got worse compared with preoperative status.

**Michele Vasso et al. <sup>(7)</sup>** (published 2013) showed that 60 knee revisions were satisfactorily managed through three implants with different constraint degrees, relative to the state of peripheral ligaments and to the bone defects AORI classification: primary PS, semi constrained CCK and rotating hinged (RHK) prostheses.

**In-Soo Song et al** <sup>(8)</sup> (published 2014) showed that treatments of unstable TKA with coronal instability don't need revision surgery using constrained type with long stem. And only the exchange of inserted polyethylene demonstrated sufficient stability in the treatment of coronal instability with posteromedial polyethylene wear. But, presence of lateral ligament attenuation is very important in taking decision to revise with constrained type using long stem.

#### 4. Discussion

Mediolateral instability or coronal instability a frequent reason for revision of TKA and it can be due to incorrect ligament balancing or lack of identification of an incompetent collateral ligament. Inadequate medial structural releases that can evoke the delayed MCL rupture or attenuation frequently lead to delayed coronal instability. We didn't experience such circumstances because we always attended to check the adequate medial release and mediolateral balance, but there were several cases of coronal instability showing posterolateral polyethylene insert wear. Treatments of unstable TKA with coronal instability don't need revision surgery using constrained type with long stem and only the exchange of inserted polyethylene.

Analysis of the cause of instability is most important in the revision of an unstable TKA and this analysis procedure is very important to prevent a re-revision of the recurrence of instability. Extensor mechanism incompetence, inadequate balancing of the PCL, excessive release of posterolateral structures, polyethylene post fracture, hyperextension or a broken polyethylene insert.

We can divide such TKA instability by type into early instability and late instability for consideration. An early instability can result from a component malalignment, incorrect mechanical axis, gap imbalance, ligament rupture (PCL or MCL) and extensor mechanism abnormality, while late instability may result from polyethylene wear, polyethylene post wear or fracture, ligament attenuation, extensor mechanism dysfunction.

Most ligament reconstructions cannot solve the problem of instability due to collateral ligament attenuation, which ultimately may progress into knee dislocation or polyethylene dislocation.

The principle of treatment for TKA instability is to exchange unstable knee to stable knee, but the exchange to thicker polyethylene must carefully consider the variation in the flexion and extension gap. It is considered that there will be few cases in which stability can be ensured with upsized polyethylene alone. According to recent reports, patients undergoing revision of femoral and tibial

components had better outcomes than those undergoing isolated polyethylene exchange. But, our study contained cases with posteromedial polyethylene bearing wear leading to coronal instability and to an exchange of isolated polyethylene bearing, and its final results demonstrated excellent results without recurrent instability.

The use of a more constrained type of implant must be considered for TKA instability and the semi-constrained prosthesis or the hinged type of implant can be used. Efforts must be made to carefully raise by stage the level of constraint to obtain stability.

The most fundamental point of such revision surgery is to obtain equal flexion and extension gap. For this, an accurate evaluation of the integrity of each ligament must be performed.

Some authors asserted that coronal instability can be divided into reconstructable MCL and non-reconstructable MCL according to the stability of MCL. And the semi-constrained type of implants are used for reconstructable MCL, whereas linked or hinged implants are necessary for the case of absent or non-reconstructable MCL.

A hinged revision implant can be used in cases of absence of MCL or non-reconstructable MCL, unstable flexion gap, poorly functioning extensor mechanism and revision of previous hinge, but increasing component constraint might reduce the instability.

Revision TKA usually requires a more constrained prosthesis than primary TKA. However, doing so may increase the forces transmitted to the fixation and implant interfaces, which might lead to premature aseptic loosening. A more constrained type of prosthesis was not always required in the cases of simple polyethylene wear or post fracture with TKA instability, but a more constrained type of prosthesis was always required when instability was accompanied by two planes or more.

The research of our series has its shortcoming as the volume of cases is not enough to classify the types of unstable TKA. An additional limitation was the simple coronal instability due to posteromedial wear of polyethylene.

To sum up, the present study shows that those cases of knee instability after primary TKA have various causes and an analysis of the causes of instability could be helpful to choice the implant and the surgical techniques in the revision TKA. A revision TKA with or without a more constrained prosthesis regardless of the implant types would be a definite solution to TKA instability, but the solution according to the causes is very effective and seems to have a chance of avoidance of unnecessary over constrained implant selection in a revision surgery for an unstable TKA.

## Conclusion

The vast majority of articles in the literature support the concept that a balanced knee is beneficial to the success of total knee arthroplasty. Its relevance is determined by its contribution to improving alignment and stability. A balanced knee is likely to have reduced wear and loosening. The patient with a balanced knee is likely to be more satisfied with an increased ROM and proprioception, and less pain. However, the surgeon must be wary of possible complications; for example, instability from excessive ligament resection and the possibility of peroneal nerve damage. Currently no consensus exists regarding the best method to produce a balanced knee. Many differing techniques and sequences for ligament release have been reported over the many years since Freeman and Install first highlighted the importance of ligament balancing in the late seventies.

A hinged revision implant can be used in cases of absence of MCL or non-reconstructable MCL. An increasing component constraint might reduce the instability. Revision TKA usually requires a more constrained prosthesis than primary TKA.

Analysis of the causes of instability could be helpful to choice the implant and the surgical techniques in the revision TKA.

A revision TKA with or without a more constrained prosthesis regardless of the implant types would be a definite solution to TKA instability, but the solution according to the causes is very effective and seems to have a chance of avoidance of unnecessary over-constrained implant selection in a revision surgery for an unstable TKA.

## References

1. Parratte S, Pagnano MW (2008) Instability after total knee arthroplasty. *J Bone Joint Surg Am.*; 90(1):184–194.
2. Vince KG, Abdeen A, Sugimori T (2006) the unstable total knee arthroplasty: causes and cures. *J Arthroplasty.*; 21(4 suppl 1):44–49.
3. Callaghan JJ, O'Rourke MR, Liu SS (2005). The role of implant constraint in revision total knee arthroplasty: Not too little, nottoo much. *J Arthroplasty*; 20: 41–3.
4. Abdel MP, Haas SB. (2014). The unstable knee: wobble and buckle. *Bone Joint J*; 96B (11 Supple A):112–4.
5. Sang Jun Song, Robert C. Detch, William J. Maloney, Stuart B. Goodman, James I. Huddleston III(2014): Causes of Instability After Total Knee Arthroplasty *The Journal of Arthroplasty* 29 360–364.
6. Daniel Hernandez-Vaquero, Manuel A. Sandoval-Garcia (2010): Hinged Total Knee Arthroplasty in the Presence of Ligamentous Deficiency *Clin Orthop Relat Res* 468:1248–1253 DOI 10.1007/s11999-009-1226-7.
7. Michele Vasso, Philippe Beaufils, Alfredo Schiavone Panni (2013): Constraint choice in revision knee arthroplasty *International Orthopaedics (SICOT)* 37:1279–1284 DOI 10.1007/s00264-013-1929-y.
8. In-Soo Song, Doo-Hoon Sun, Jae-Gyun Chon, Sung-Won Jang, Dong-Hyuk Sun (2014): Results of Revision Surgery and Causes of Unstable Total Knee Arthroplasty *Clinics in Orthopedic Surgery* 6:165-172 doi 10.4055/cios.2014.6.2.165.

7/15/2019