

## Role of Ultrasonography and MRI Arthrography in Diagnosis of Glenohumeral Instability

Ali Abdelhady Elsayed, Mohammad Abo Elnaga Mohammad and Abdulaziz Ali Mohammad

Radio-Diagnosis Department, Sayed Galal University Hospital, Faculty of Medicine, Alazhar University, Cairo, Egypt  
[abdulaziz.oraby@gmail.com](mailto:abdulaziz.oraby@gmail.com)

**Abstract: Introduction:** Glenohumeral instability refers to the humeral head slipping out of the glenoid socket and causing symptoms. This is a relatively common abnormality in which the shoulder is considered to be the most unstable joint in the body (1). **Back-ground:** Pathological Abnormalities in Glenohumeral Instability: Ultrasonographic and MRI Correlations. In an unstable shoulder, many findings are possible. Each finding can occur alone or in combination with other lesions. These lesions include the Bankart lesion (85% of cases), Hill-Sachs lesion (77%), anterior glenoid rim damage (73%), capsular redundancy, subscapularis deficiency, and glenoid fossa deficiency. Absence of pathologic findings is also possible (4). **Patients and Methods:** Our study was performed on thirty patients with history of shoulder dislocation. All patients complained of shoulder dislocation either traumatic or non-traumatic. **Exclusion criteria:** Previous shoulder surgery, glenohumeral joint arthropathy, or substantial shoulder defects other than the sequelae of glenohumeral joint dislocation. **Results:** This study included 30 patients; 28 males, 2 females with age range from 18 years to 51 years (mean age 30 years, SD 11.9, mode 20 and median 26), suffering from symptoms of glenohumeral instability in the form of dislocation whether traumatic or non-traumatic associated with pain and/or limitation of movement. All of the 30 patients were examined with ultrasound and MRI and the MRI results were then compared with the collected data of US. **Conclusion:** We concluded that ultrasonography can be used as a screening method when there is any uncertainty, or when the issue of labral or capsular tear is not obvious from the clinical investigation, especially in hospitals that far or donot have MRI. However, MR allows accurate depiction of the size and location of labral tears and their associated capsular and glenohumeral ligament injuries and it is needed to evaluate the suspicious or negative Bankart or Perthes cases with ultrasound.

[Ali Abdelhady Elsayed, Mohammad Abo Elnaga Mohammad and Abdulaziz Ali Mohammad. **Role of Ultrasonography and MRI Arthrography in Diagnosis of Glenohumeral Instability.** *Researcher* 2018;10(7):9-15]. ISSN 1553-9865 (print); ISSN 2163-8950 (online). <http://www.sciencepub.net/researcher>. 2. doi:[10.7537/marsrj100718.02](https://doi.org/10.7537/marsrj100718.02).

**Keywords:** Role; Ultrasonography; MRI; Arthrography; Diagnosis; Glenohumeral; Instability

### 1. Introduction

Glenohumeral instability refers to the humeral head slipping out of the glenoid socket and causing symptoms. This is a relatively common abnormality in which the shoulder is considered to be the most unstable joint in the body (1). Ultrasonography can examine the shoulder structures during movement and contemporaneously compare the finding of the symptomatic side with those of the asymptomatic side. It shows high accuracy in the depiction of labral tears (2). The main shoulder structures that can be evaluated with US in patients with instability problems are the long head of biceps, the glenohumeral joint, and the acromioclavicular joint. US can be used for documenting the presence, direction, and extent of glenohumeral translation, especially in patients with posterior shoulder dislocation (2). MRI is the ultimate tool in assessing shoulder instability. Direct MR arthrography is the standard of care for diagnosis of shoulder instability (3).

**Aim of this study:**

The aim of this study is to evaluate the role of ultrasonography and MRI Arthrography in diagnosis of glenohumeral instabilities.

**Back-ground: Pathological Abnormalities in Glenohumeral Instability: Ultrasonographic and MRI Correlations**

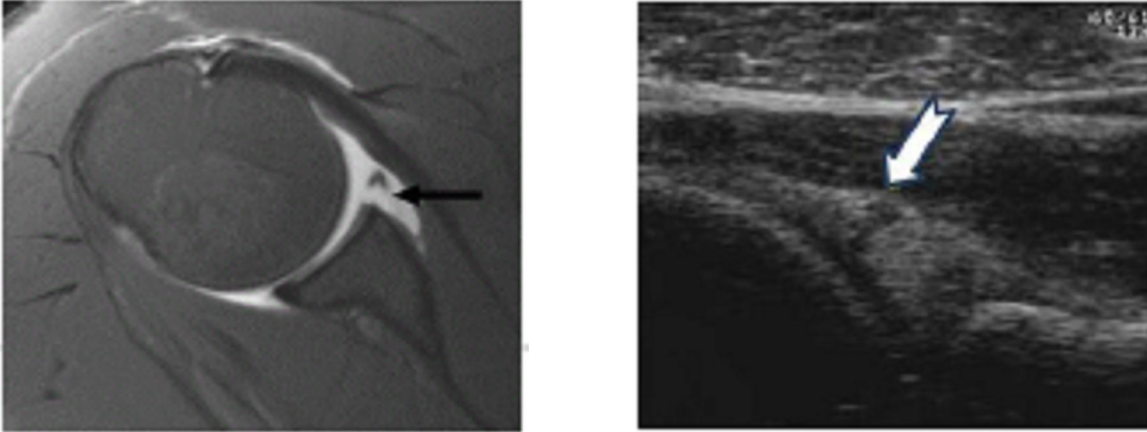
In an unstable shoulder, many findings are possible. Each finding can occur alone or in combination with other lesions. These lesions include the Bankart lesion (85% of cases), Hill-Sachs lesion (77%), anterior glenoid rim damage (73%), capsular redundancy, subscapularis deficiency, and glenoid fossa deficiency. Absence of pathologic findings is also possible (4).

#### 1. Bankart lesions:

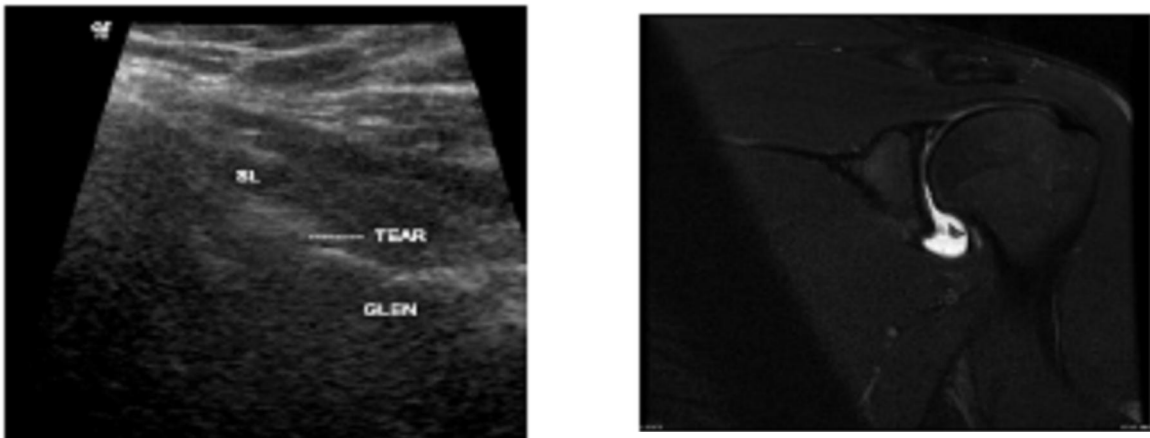
They are the commonest labral injury, manifesting as tear of the anterior inferior labrum with associated periosteal tear (5). It was described by Bankart at 1932. It can be purely cartilaginous or may involve the bony glenoid rim. Bankart lesion is usually accompanied by Hill-Sachs lesion (6). **On MRI;** the anteroinferior labrum is seen to be attenuated or absent

on MRI. The signal intensity on T2 gradient-echo or PD fat suppression, Fast Spin Echo MR images may be increased secondary to degeneration of the labrum (6). **On US**; the evaluation of the labrum is achieved, particularly in excluding labral tears when the labrum appears normal. Despite having limitations in the

assessment of the anteriorglenoid, US may occasionally demonstrate fragmentation of the antero-inferior rim, a finding that represents a Bankart lesion, as a V-shaped bone defect over the anterior aspect of the glenoid (7).



**Fig1: Ultrasound examination anterior approach in transverse view shows tear in the anterior labrum (the right image) And MRI Axial images showing tear of the antero-inferior labrum (the left image)**



**Fig 2: Ultrasound examination of shoulder showing a hypoechoic line in the superior labrum denoting labral tear (the left image) and MRI coronal oblique showing tear in the superior labrum denoting a SLAP lesion (the right image).**

## 2. Osseous Bankart:

Occurs when some of the glenoid bone is broken off with anterior labrum. This leads to loss of the normal architecture and also loss of bone, making the glenohumeral joint more unstable than usual Bankart tear alone (8).

## 3. Hill-Sachs lesion:

Is one of the most common injuries associated with anterior glenohumeral instability (6). It is an osteochondral compression fracture located on the posterolateral humeral head that occurs in anterior shoulder dislocation. The fracture is created when the posterolateral humeral head strikes the antero-inferior

glenoid rim during dislocation. Impaction fracture or associated bonemarrow edema both are observed in acute cases (9). **On MRI**, there is abnormal signal intensity within the marrow indicative of acute trauma (Contusion) that will not be detected by CT (10). This should not be mistaken with erosion at the same area and overall Hill-Sachs lesion (11). **On US**; A Hill-Sachs lesion appears as a shallow wedge-shaped defect of the hyperechoic bony contour of the humeral head at the point where the infraspinatus inserts into the greater tuberosity (12).

## 4. Perthes lesion:

Described by Perthes in 1905, is defined as a tear of the glenoid labrum with intact scapular periosteum (13). The torn anterior labrum is often undisplaced and visualized in its normal location on conventional MR imaging. **On MRI**, partial labral detachments, but it can be missed on routine MRI and even on arthroscopy because they can heal spontaneously. Thus, there may be no clinical findings despite symptoms of shoulder instability, in which case MR Arthrography (MRA) is superior for diagnosis and guiding treatment because it can visualize partial tears revealed by contrast material-induced tension within the capsule (14).

## 2. Patients and Methods:

### Patients:

**Our study was performed on** thirty patients with history of shoulder dislocation. All patients complained of shoulder dislocation either traumatic or non-traumatic.

### Exclusion criteria:

Previous shoulder surgery, glenohumeral joint arthropathy, or substantial shoulder defects other than the sequelae of glenohumeral joint dislocation.

### All patients will be subjected to the following:

1. Full history taking with a special emphasis on age, sex, mechanism of injury trauma, number of dislocation (s), they are athletic or not.
2. Radiological investigations:
  - a. Gray scale ultrasound.
  - b. MRI Arthrography.

### Methods:

#### 1- Grey scale sonography:

Patients will be examined according to the Ultrasonic Shoulder protocol (12)

#### Technique of examination: Patient position:

Typically, the patient is seated on a backless chair or stool in the static technique and supine in the dynamic technique. Longitudinal and transverse scans and sometimes also oblique and unconventional views must be performed in order to make a detailed assessment of the shoulder structures (15)

#### Labral echogenicity is recorded as:

**Hyper echoic**; equal to bone cortex. **Hypo echoic**; less echogenic than bone cortex and homogeneous. **Heterogeneous**; less echogenic than bone cortex but not homogeneous). (16)

**Grey scale sonography** was done using static and dynamic techniques for examination of rotator cuff tendons, anterior labrum (superior and inferior) and posterior labrum (superior and inferior), the depth of penetration was set at 8-10cm from the transducer, and the focus was located at the level of the labrum.

#### 2-Magnetic Resonance Imaging:

MRI was done after fluoroscopic guided direct intra-articular injection of contrast.

Using a **dedicated shoulder coil** or **Surface coil (Flexible coils)** those that wrap around and conform to the anatomic area of interest.

#### Imaging planes and pulse sequences:

Preliminary Scout Localizer in axial, Coronal FFE, Coronal T2, Coronal PD, Axial PD SPIR, Axial T1, Sagittal T2, Post contrast injection Axial T1, post contrast injection Coronal T1, Post contrast injection Sagittal T1.

## 3. Results

This study included 30 patients; 28 males, 2 females with age range from 18 years to 51 years (mean age 30 years, SD 11.9, mode 20 and median 26), suffering from symptoms of glenohumeral instability in the form of dislocation whether traumatic or non-traumatic associated with pain and/or limitation of movement.

All of the 30 patients were examined with ultrasound and MRI and the MRI results were then compared with the collected data of US.

The frequency & percentage according to sex in the study population where male patients represented 93% while female patients represented 7%.

The frequency of different pathological injuries according to the mean age (30 years) revealed that patients below 30 years showed high incidence of labro-ligamentous injuries (**66.7 %**) than those above 30 years (**33.3%**).

The examined patients were categorized according to the cause of instability to two large groups; traumatic or non-traumatic.

The frequency and percentage of traumatic and non-traumatic instability in the study group were 20 patients (66.7%) and 10 patients (33.3%) respectively.

Another classification was done according to whether the patient was athletic or non-athletic and its impact on the frequency and percentage of labroligamentous injury. The athletic group (16 patients) showed higher incidence of labroligamentous injury of Perthes (4 of 16) 25%, while non-athletic group (14 patients) was more prone to SLAP (2 of 14) 14% and Osseous Bankart (2 of 14) 14%.

#### Ultrasonographic findings:

By ultrasonography, the abnormal antero-inferior labral lesions were detected in (22 of 30) patients (73.3%).

#### Findings that were detected in both ultrasound and MRI:

1. Effusion was detected in 12 patients. (40%).
2. Loose bodies were seen in two patients. (6%).
3. Hill Sach's lesion was detected in 26 patients. (86.6%).
4. SLAP lesion detected in 2 patients (7%).
5. Rotator cuff tendon pathological lesions 4 patients (13.3%), involving mainly the supraspinatus

tendon full thickness tear was seen in 2 patients, regarding the infraspinatus tendon partial tear was

detected in one patient as well as tear of biceps tendon was detected in another patient.

**Table 1: The frequency and percent of US findings in relation to MRI findings.**

Lesion	Detected by US	Detected by MRI	US/MRI %
<b>Cartilaginous Bankart</b>	14	22	63.6 %
<b>Osseous Bankart</b>	2	2	100 %
<b>Perthes</b>	2	4	50 %
<b>SLAP</b>	2	2	100 %
<b>Hill Sach's</b>	26	26	100 %
<b>Effusion</b>	12	12	100 %
<b>Loose bodies</b>	2	2	100 %
<b>Rotator cuff tendon tear</b>	4	4	100 %

#### 4. Discussion

The shoulder joint is the most commonly dislocated joint because of the large size of the humeral head compared to the small size of the glenoid fossa (17) (Ogul et al., 2014). Shoulder instability represents a common condition primarily affecting young active people and especially athletes. It occurs when the humeral head is forced out of the glenoid fossa. This can be the result of a sudden injury or from overuse activities of the shoulder joint. Once the soft tissues (ligaments, tendons, and muscles) supporting the shoulder become loose or torn, the shoulder joint becomes prone to dislocations. Chronic shoulder instability is defined as the persistent inability of the soft tissues to keep the humeral head congruent into the glenoid fossa. (18) (Pavic et al., 2013) Our study conformed with (18) (Pavic et al., 2013) that more of our patients (53.4 %) were athletes. In Shoulder instability the commonest labral injury is **Bankart lesion (85%)**, which is manifested as a tear of the anterior inferior labrum with associated periosteal tear (5) (Calvert, 2015), it can be purely cartilaginous or may involve the bony glenoid rim. Bankart lesion is usually accompanied by **Hill-Sachs lesion (77%)** (Osteochondral compression fracture located on the posterolateral humeral head that occurs in anterior shoulder dislocation) (6) (Jana & Gamanagatti, 2011). Several other variants of Bankart lesion have been described, including the **Perthes lesion, anterior labroligamentous periosteal sleeve avulsion (ALPSA) lesion, glenolabral articular disruption (GLAD) lesion (19) (Smithuis & Woude, 2012)**. This is agreed with our study that we reviewed 30 cases of shoulder dislocation, 28 of them were antero-inferior labral lesions (22 cartilaginous Bankart 73.3 %, 2 osseous Bankart 6.6 % and 4 Perthes 13.3%) lesions and associated 26 Hill

Sach's defects 86.6%. **In this study** most of patients (66.7 %) were young active individuals and most of the older patients had started shoulder dislocation when they were young and this is conformed with (20) (Mascarenhas et al., 2014) who showed that the glenohumeral instability is a common problem that affects a significant number of young, active patients. In symptomatic recurrent glenohumeral instability, advanced imaging techniques are strongly recommended before proceeding to surgery in order to quantify glenohumeral bone loss, including defect size and location (20) (Mascarenhas et al., 2014) **In this study**, the patients were divided into two main groups; Patients with traumatic instability 66.6 % (20 patients) and patients with no history of trauma 33.4% {(atraumatic type) 10 patients}}, This classification agreed with (9) Tseng et al. (2013) study where they categorized their patients according the underlying causes in the form of; atraumatic (congenital laxity) and traumatic.

Our patients were examined by ultrasound as first investigation then MRI was done to confirm the diagnosis. Only few studies have addressed the possibility of using ultrasonography to detect anterior labral lesions and the ability to characterize the instability. Furthermore, the ability of US to reveal ligament-capsular injuries has not been well documented, recently, it has also been stated that more knowledge was required in terms of the value of diagnostic ultrasonography on the therapeutic decision-making, especially concerning diagnostic accuracy in or close to the labrum (Bankart lesions, SLAP lesions) (21) (Magnusson et al., 2007).

**In our study**, the criteria used by US to define torn labrum mainly the antero- inferior labrum were:-

1- The presence of hypo-echoic zone of at least 2mm distant between the presumed torn labrum and its glenoid attachment or being absent or deformed.

2- The echogenicity of the examined labrum was also used as another criterion to evaluate where the normal labrum appeared as hyper-echoic triangular shaped while the torn labrum appeared heterogeneous and attenuated.

This agrees with (22) **Hammer et al. (2001)** as well as (23) **Rasmussen (2004)** and confirmed by (21) Magnusson et al. (2007) where they evaluated the anterior labrum by using multiple approaches to prevent misinterpretation, yet, the approaches did not significantly differ in the depiction of the anterior structures of the shoulder. Arthroscopy or arthrotomy was subsequently performed as the golden standard. Sonography correctly depicted the presence or absence of fractures of the humeral head or glenoid rim, and the labral tear was seen as a hypo-echoic zone larger than 2mm. In this study, we used the above criteria and ultrasound was able to detect [20 of 28] patient with antero-inferior labral lesions, and this was confirmed with MRI where the ultrasound showed (71.4%) sensitivity labral tears detection. This is agreed with (24) Jeong et al. (2011) where he studied the accuracy of conventional US versus US arthrography in detection of antero-inferior labral tear in 14 patient with anterior labrum tear and with arthroscopic results, he used the criteria of labral displacement or morphologic change of the labrum both (vacuum phenomenon and hypoechoic zone) for detection of the Bankart lesion group. He concluded that conventional US has 64% of sensitivity and 75% of specificity for detection of the Bankart lesion group. Our study results better than (16) Taljanovic et al. (2000), where the echogenicity of the labrum, was evaluated with sonography. Most of the normal labra were hyper-echoic; however, the appearance of torn labra showed variable degrees of heterogeneity, which showed 63% sensitivity which is lower than ours; this may be attributed to that we used multiple criteria to evaluate the labrum. In our study the ultrasound showed (73.3%) sensitivity in labral tears detection and failed to show the labral lesions in (8 of 30) patient (26.6 %). Hill-Sachs lesions can be a factor predictive of recurrent anterior shoulder instability (25) (Van Lancker et al., 2013). In the present study, Hill Sach's defect was detected in 26 patients by MRI and the ultrasound was able to detect the entire 26 patient with 100% sensitivity. This agreed with (23) Rasmussen (2004), that sonography can diagnose Hill Sach's lesion and effusion with 100% sensitivity. This is disagreed with (24) Jeong et al. (2011) and (18) Pavic et al. (2013) who showed statistical difference between ultrasound and MRI in diagnosing Hill Sach's defect, this difference may be due to that most of their

cases had single dislocation and had a small sized Hill Sach's or just a contusion and they couldn't diagnose it with US. In our study joint effusion was detected in 12 patients and the ultrasound was able to detect (12 of 12) patients (100%) sensitivity. This agreed with (26) Zubler et al. (2011) who performed sonographic study on 30 patients before and after MR arthrography of the shoulder and was able to diagnose glenohumeral anechoic collection that was consistently seen in the posterior glenohumeral joint recess with the arm in external rotation (30/30) patients (100%) sensitivity.

#### Limitations of our study:

- Unrandomized and small sample size, small number of patients of SLAP and Perthes, which did not allow further statistical analysis.
- All our cases had labral lesions in MRI and no cases were free so we couldn't calculate the US specificity, positive predicted value and negative predicted value.
- The reason behind the false-negative cases of Bankart and Perthes in US was the antero-inferior labral tears were deep in location and inaccessibility especially with obese patients.
- Finally, in the present study, we can conclude that the sensitivity of ultrasound in detecting labral lesions and Hill Sach's lesion were 73.3% and 100% respectively.

#### Summary:

The shoulder joint is anatomically complex, where its stability depends on a combination of osseous structures and soft tissue structures surrounding the shoulder known as the labral ligamentous complex, joint capsule, muscles and tendons where they are acting as dynamic as well as static stabilizers preventing the joint from exceeding the optimized range of motion. It is important to understand the anatomy, pathology, history, physical examination, and classification systems to diagnose these patients correctly. After arriving at an accurate diagnosis, an appropriate treatment program that may entail non-operative or surgical interventions can be instituted. There are potential lesions of the capsule and labroligamentous structures that can occur in association with shoulder instability, and the clinical history and physical findings are not always sufficient to make accurate diagnosis. Recently, various imaging modalities are now available including ultrasonography, CT arthrography, conventional MRI and MR arthrography. This study included 30 patients, clinically presented with multiple episodes of shoulder dislocation. Ultrasound as well as MRI- arthrography was done for all patients. Ultrasonography is cheap, readily available, fast, capable to provide high-resolution images, and does not use ionizing radiations. In addition, US allows performing dynamic evaluation of musculoskeletal structures. In the present

study the ultrasound shows 73.3% sensitivity in labral tears detection, 100% sensitivity for effusion and Hill Sach's defect. US imaging is minimally affected by metal artifacts (eg, cochlear implants, hardware, or pacemakers) and also can be used in certain patients who have contraindications to MRI imaging (eg, claustrophobic or obese patients). Standard high-frequency ultrasound probes also resolve finer imaging detail than many types of clinical musculoskeletal MRI. MR imaging, which allows direct visualization of major anatomic structures, had been traditionally used in the examination of patients with shoulder instability, though it has been pointed out that accurate interpretation of glenohumeral joint structures is beset with pitfalls. High field MRI arthrography improves the evaluation of smaller intra-articular structures such as the glenoid labrum and glenohumeral ligaments, MR arthrography is considered as sufficient tool for examination of glenohumeral instability providing very good visualization of complex anatomic structures of the joint and demonstration of subtle abnormalities.

### 5. Conclusion:

We concluded that ultrasonography can be used as a screening method when there is any uncertainty, or when the issue of labral or capsular tear is not obvious from the clinical investigation, especially in hospitals that far or donot have MRI. However, MR allows accurate depiction of the size and location of labral tears and their associated capsular and glenohumeral ligament injuries and it is needed to evaluate the suspicious or negative **Bankart** or **Perthes** cases with ultrasound.

### Recommendations:

We recommend that ultrasonography should be increasingly used for patients with shoulder dislocation because it is fast, safe and give real time examination and doctor patient communication.

### Recommended clinical scenarios for evaluation patients after shoulder dislocation:

- Plain X-ray needed to exclude major fractures in post-traumatic cases.
- Ultrasonography as a screening method for: - Post traumatic acute instability for young and elder patients, chronic instability and recurrent instability.
- MRI-arthrography is done when there is: - Negative ultrasonic results with high index of clinical suspicion of labral lesions Instability and in chronic recurrent instability.

### 1. References:

2. Tineke De Coninck, MD, Steven S. Ngai., et al.: Imaging the Glenoid Labrum and Labral Tears, 2016; 36(6): 422–433.
3. Sangeeta Rathi, Nicholas F. Taylor, JamieGee., et al.: Measurement of glenohumeral joint translation using real-time ultrasound imaging. 2016; 26 P 110-116.
4. Ruiz Santiago F, Martinez Martinez A, Tomas Munoz P., et al.: Imaging of shoulder instability. *Quant Imaging in Medicine and Surgery*. 2017 Aug; 7(4): 422–433.
5. Afsari, A. (2014): Anterior Glenohumeral Instability. *medscape*, available at <http://emedicine.medscape.com/article/1262004-overview>. Accessed in January 2015.
6. Calvert, P.: Glenoid labrum pathology. *Orthop Traumatol Surg Res*, 2015; 101(1):19-24.
7. Jana M., and Gamanagatti S.: Magnetic resonance imaging in glenohumeral instability. *World Journal of Radiology*, 2011; 3(9):224-232.
8. Bianchi S. & Martinoli C.: Ch 6 shoulder In Baert A. L., Brady L. W., Heilmann H. P., Knauth M., et al. (eds): *Ultrasound of the musculoskeletal system*. Springer Berlin Heidelberg, 2nd edition. 2007.
9. White L. M. & Recht M.: MR imaging of articularcartilage In Hodler J., von Schulthess G. K., Zollikofer Ch. L., (eds.): *Musculoskeletal Diseases 2009-2012: Diagnostic Imaging* Springer verlag Italia, 2009: p 180.
10. Tseng G. Y., Wilfred C. G., Cetik O., Uslu M., et al: Shoulder dislocation. The relationship between Hill-Sachs lesion and recurrent anterior shoulder dislocation. *Acta Orthop Belg*, 20013; 73(2):175-178.
11. Provencher, M. T., Frank, R. M., LeClere, L. E., Metzger, P. D., et al.: The Hill-Sachs Lesion: Diagnosis, Classification, and Management. *Journal of the American Academy of Orthopaedic Surgeons*, 2012; 20(4):242-252.
12. Freeman, R., Khanna, S., & Ricketts, D.: Inappropriaterequests for magnetic resonance scans of the shoulder. *International Orthopaedics*, 2013; 37(11): 2181–2184.
13. Singh, J. P.: Shoulder ultrasound: What you need to know. *The Indian Journal of Radiology & Imaging*, 2012; 22(4), 284–292.
14. Woertler, K., & Waldt, S.: MR imaging in sports-related glenohumeral instability. *European Radiology*, 2006; 16: 2622–2636.
15. Mutlu, S., Mah, M., L, J., Güler, O., Uçar, B. Y., et al.: Anterior Glenohumeral Instability: Classification of Pathologies of Anteroinferior Labroligamentous Structures Using MR

- Arthrography. *Advances in Orthopedics*, 2013; 2013:1-4.
16. Gilani, S. A.: An overview of musculoskeletal ultrasound– A thirteen years experience in Pakistan. *Perspectives in Medicine*, 2012; 1(1-12): 427– 430.
  17. Taljanovic M. S., Carlson K. L., Kuhn J. E., Jacobson J. A., et al.: Sonography of the glenoid labrum: acadaveric study with arthroscopic correlation. *AJR Am J Roentgenol.* 2000; 174(6):1717-1722.
  18. Ogul H., Karaca L., Can C. E., Pirimogglu B. et al.: Anatomy, Variants, and Pathologies of the Superior Glenohumeral Ligament: Magnetic Resonance Imaging with Three-Dimensional Volumetric Interpolated Breath-Hold Examination Sequence and Conventional Magnetic Resonance Arthrography. *Korean J Radiol*, 2014; 15(4): 508–522.
  19. Pavic, R., Margetic, P., Bencic, M., & Brnadic, R. L.: Diagnostic value of US, MR and MR arthrography in shoulder instability. *Injury, Int. J. Care Injured*, 2013; 44 (3):26–32.
  20. Smithuis R., and Woude H. J. van der. (2012): Shoulder MRI – Anatomy Variants and Checklist. *Shoulder MR Anatomy*: Available from: <http://www.radiology.assistant.nl/en/p4f49ef79818c2/shoulder-mranatomy>. Accessed in January 2015.
  21. Mascarenhas R., Rusen J., Saltzman B. M., Leiter J., et al.: Management of humeral and glenoid bone loss in recurrent glenohumeral instability. *Adv Orthop*, 2014; 2014: 1-13.
  22. Magnusson L., Ka'lebo P., Baranto A., Lundin O. et al.: The value of ultrasonography in the preoperative diagnostic evaluation of patients with recurrent anterior shoulder dislocation: a prospective study of 44 patients. *Knee Surg Sports Traumatol Arthrosc*, 2007; 15(5): 649–653.
  23. Hammer M. V., Wintezell G B., Astrom K. G. O. et al. Role of US in the preoperative evaluation of patients with anterior shoulder instability. *Musculoskeletal Imaging. Radiology*, 2001; 219: 29-34.
  24. Rasmussen, O. S.: Pictorial Essay Anterior shoulder instability: sonographic evaluation. *Journal of Clinical Ultrasound ( JCU)*, 2004; 32(9): 430– 437.
  25. Jeong W. K., ryu J. A., Kim M. Y., Heo J. N. et al.: Accuracy of Ultrasound Arthrography in the Bankart Lesion: Comparison with Conventional Ultrasonography. *European society of Radiology.*, 2011; 961:1-26.
  26. Van Lancker H. P., Martineau P A, and Khoury V.: Sonography as a Tool for Identifying Engaging Hill-Sachs Lesions: Preliminary Experience. *J Ultrasound Med*, 2013; 32(9):1653–1657.
  27. Zubler V, Mamisch-Saupe N, Pfirrmann CW, Jost B, et al: Detection and quantification of glenohumeral joint effusion: reliability of ultrasound. *Eur Radiol.*, 2011; 21(9): 1858-1864.

7/7/2018