

# Study The Possible Protective Influence of White Cabbage and Septilin on The Cardiac Muscle of Male Rats Exposed to Gamma Radiation

Enas A K<sup>1</sup> and Atif I A<sup>2</sup>

1 Department of Histology, National Organization for Drug Control and Research, 12553Cairo, Egypt

2 Department of Histology, Faculty of Medicine, Al-Azhar University, 11884 Cairo, Egypt

[enasamk@hotmail.com](mailto:enasamk@hotmail.com), [narmout@yahoo.com](mailto:narmout@yahoo.com)

**Abstract:** Radiation leads to increase the formation of free radicals. Oxygen free radicals have been shown to cause contraction failure and structural damage to the myocardium that will affect cardiac performance. Cabbage has a potent antioxidant activity and previously been linked to a lower risk of heart attacks and strokes. Septilin is a plant mixture extract proved to normalize lipid metabolism, lower cholesterol and triglyceride. Also, supports heart health, regulates blood pressure, blood vessel contraction and the tendency of blood to form clots. This study was designed to identify the possible protection of white cabbage and septilin to suppress the progression of cardiac impairments in rats exposed to whole body  $\delta$ - radiation. Sixty male albino rats were divided into six groups, control, irradiated, cabbage feeding, cabbage feeding for a month and irradiated, septilin treated and septilin treated for a week and irradiated. The present work showed serious histological alterations in the myocardium of irradiated rats appeared as thickened vascular wall of the myocardial blood vessels, dilated and congested blood vessels, mild vacuolation in myocytes, fragmentation, swelling and degeneration of the myocardial muscle fibers with edema in between the myocardial fibers. Altered protein, collagen fibers and DNA content were also observed in the cardiac myocytes. Feeding Cabbage leaves for a month before  $\delta$ - irradiation led to a marked protection of cardiac myocytes and blood vessels, an improvement in total protein and DNA content in the myocardium and non significant change in collagen fibers. Pretreatment of rats with Septilin 100mg/kg bw p. o. for 7days before -irradiation showed normal histological pattern of myocardium except few area appeared with edema in between the myocardial muscle fibers and dilated blood vessels, an improvement in total protein and DNA content was recorded in the myocardium with non significant change in collagen fibers. It is concluded that white cabbage proved marked protection than Septilin against  $\delta$ - irradiation. [Researcher. 2010;2(6):81-94]. (ISSN: 1553-9865).

**Key words:** radiation, white cabbage, septilin, cardiac muscle.

## 1. Introduction

Doses of ionizing radiation in the therapeutic range may produce damage to the myocardium (Bishop *et al*, 1965). Radiation induced heart disease during thoracic radiotherapy and breast cancer (Gladstone *et al*., 2004). Radiation leads to the increase formation of free radicals. Free radicals have been shown to cause contraction failure and structural damage to the myocardium that will affect cardiac performance (Tomomi and Hisjuki, 1999). The antioxidants contained in fruits and vegetables shared with the body enzymes to neutralize free

radicals (Eberhardt *et al.*, 2005). Chu, *et al*, 2002 reported that antioxidant activity of cabbage among other vegetables. Smieschowska *et al*, 2008 stated that high intake of white cabbage (Brassica Oleracea Var.Capitata) may be of the optimal exploitation in health protection. Katay and Hamza (2008) reported that Brassica vegetables ameliorate diabetic nephropathy Wu and Juurlink (2001) reported that Sulforaphane (the active component in Brassica members) could up-regulate the impaired glutathione system in vascular smooth cells of spontaneously hypertensive rats. Brassica vegetables are excellent

sources of fibers. Insoluble fiber helps to prevent constipation and reduce colorectal cancer risk. Soluble fiber helps to reduce blood cholesterol and blood sugar, thereby reducing the risk of heart disease and diabetes. A recent study in the Journal of the American Medical Association found that people who ate at least five servings of fruits and vegetables a day had a 30 percent lower risk of ischemic stroke. Each daily serving reduced the risk by six per cent. The most protective choices included the brassica vegetables (*Joshipra et al., 1999*). Brassica vegetables have a potent antioxidant and previously been linked to the a lower risk of heart attacks and strokes (*Xue et al,2008*).

Septilin is a plant mixture extract and supplied by the Himalayan Drug Co. (Bombay, India) in a form of tablets or syrup. Its main ingredients are: Balsamodendron mukul /Commiphora mukul which is known to increase white blood cell counts ,posses strong disinfecting properties and normalizes lipid metabolism (*Dev,1997*); Tinospora cordifolia, inhibiting growth of bacteria and enhancing the buildup of immune resistance; Rubia cordifolia purifying blood, immune regulator and regulate blood pressure(*Nair et al,1996*); Emblica officinalis, is an immune function booster, antioxidant and effective against respiratory complaints; Moringa pterygosperma functions as antibiotic (*Armado et al,1991*) and Glycyrrhiga glabra promotes gastrointestinal health(*Isbruker and Burdock,2006*).This polyherbal preparation has been reported to possess immunomodulatory (*Daswani and Yegnanaraya,2002*) antibacterial (*Ross,1984*), anti-inflammatory (*Khanna and Sharma,2001*)and wound healing properties (*Udapa et al.,1989*).It is said to be helpful in treating Gram-positive as well as Gram-negative infections (*Gadekar et al.,1986*). Researches displayed that Septilin is effective in chronic stubborn urinary tract infection (*Bhasin,1990*),Tonsillitis (*Gadekar et al.,1986*)and infective dermatose (*Sharma et al.,1986*).It is said to be useful in the management of upper respiratory tract infection (*Agrawal and Veena,1986*), lower respiratory tract infection(*Bhasin,1990*),allergic disorders of upper respiratory tract (*Sanjit,1992*),skin and soft tissue infections(*Srivastava,1985*),infective and inflammatory conditions of the eye (*Sarabhai and Sandeep,1989*),Bone and joint infections (*Ramesh ,et al,1989*) and has a prophylactic of diabetic foot ulcer (*Singh,2001*). Septilin proved to normalize lipid metabolism , lower cholesterol, triglyceride, maintains or improves high density lipoprotein and low density lipoprotein ratio, a blood purifying herb , immune regulator, supports heart health , regulates blood pressure, blood vessel

constriction and the tendency of blood to form clots. (*Dev, 1997*).

This study was designed to identify the possible protection of white cabbage and Septilin to weaken the progression of cardiac impairments in rats exposed to whole body - radiation.

## 2 .Materials and Methods

### 2.1. Animals

Sixty male Swiss rats weighing 120-140gms were used. The rats were housed under good hygienic environmental condition at the National Centre for Radiation Research and Technology, Cairo, Egypt. The rats were divided into six groups :control group (referred to as control), whole body -irradiated group (4GY), Brassica leaves fed rats treated group for a month, Brassica leaves fed rats treated group for a month before (4GY) irradiation, Septilin (100mg/kg bw. p.o.) treated group for a week and Septilin (100mg/kg bw. p.o.) treated group for a week before (4GY) irradiation.

### 2.2 .Plant materials

Rats were fed on cabbage leaves for a month before exposure to gamma radiation. Septilin is a plant mixture extract was supplied by the Himalayan Drug Co. (Bombay, India) in a form of tablets. Its ingredients are (mg): Balsamodendron mukul /Commiphora mukul,162 ; Tinospora cordifolia,32; Rubia cordifolia,32; Emblica officinalis,16; Moringa pterygosperma,16; and Glycyrrhiga glabra,6. Septilin pills were ground, dissolved in water and orally administered to rats. The dose of Septilin used in this study was 100 mg/kg b. wt /day for a week before exposure to gamma radiation.

### 2.3 Irradiation:

Whole body irradiation was achieved through Cesium -137Gamma cell-40 manufactured by the Atomic Energy of Canada (Ltd.).The dose rate was 1GY/1.42 min at the time of the experiment.

### 2.4 .Histological and histochemical investigations:

Samples of cardiac muscle of rats were used for histopathological studies, fixed in 10% formalin at room temperature for 24 h, washed, dehydrated and embedded in paraffin wax. The paraffin sections were cut at 5µm thickness and stained with haematoxylin and eosin (Drury and Wallington, 1980), others were stained with Mallory's Trichrome stain (Dunn, 1974) for determination of collagen fibers and examined microscopically, others were stained with Bromophenol blue ( *Mazia et.al,1953* ) and others were stained Feulgin reaction ( *Horobin and Bancraft,1998* ).

The histochemical interpretation was done using computer image analyzing system (Leica Model). Estimation of the optical density of thirty cells in each group was made. The data obtained were statistically analyzed according to *Sendecor and Coebram (1969)*. Differences between the group means were assessed using T-test. P 0.05 was considered significant, and the percentage of change was calculated as follows:

$$\% = \text{Percentage of change} = \frac{\text{Data of treated} - \text{Data of control}}{\text{Data of control}} \times 100$$

### 3. Results:

Cardiac muscle in control group showed the normal histological structure of myocardium, with branched, striated myocardial muscle fibers cut longitudinally with acidophilic sarcoplasm and blood capillaries appeared in the intracellular spaces (Figs. 1 & 2). Exposure to whole body - radiation showed serious histological alterations in the myocardium of irradiated rats appeared as thickened wall of the myocardial blood vessels, dilated and congested blood vessels, mild vacuolation in myocytes, fragmentation cardiac myocytes, swelling and degeneration of the myocardial muscle fibers with edema in between the myocardial fibers compared to control Figures 3, 4, 5). Rat cardiac muscle in cabbage feeding group for a month and exposed to - radiation revealed intact histological structure of the myocardial muscle fibers and blood vessels (7). Cardiac muscle of rats in cabbage feeding group for a month showed edema in between the myocardial muscle bundles with dilated myocardial blood vessels (6). Septilin treated group showed intact myocardium muscle fibers and blood vessels (8). Septilin treated group for a week and exposed to - radiation revealed normal histological pattern of myocardium except

few area appeared with edema in between the myocardial muscle fibers and dilated blood vessels (9).

Figs (10-15) represent total protein contents in the cardiac muscle of male rats which were highly significantly reduced in irradiated group, meanwhile Cabbage feeding and Septilin treated groups recorded non significant change. Cabbage feeding and irradiated group and Septilin treated and irradiated group recorded reduction in comparison to control (Table1). Figs (16-22) represent collagen fibers in the cardiac muscle of male rats which were Highly increased in irradiated group. While cabbage feeding, septilin treated, cabbage feeding and irradiated and septilin treated and irradiated groups recorded non significant changes compared to control (Table 1, Histogram1).

The measurements of DNA content in the cardiac muscle Figures 23-28 revealed highly significant reduction in irradiated group, meanwhile cabbage feeding group displayed significant reduction. Septilin treated group showed non significant reduction. Septilin treated and irradiated, cabbage feeding and irradiated groups recorded non significant change compared to control (Table 1, Histogram 1).

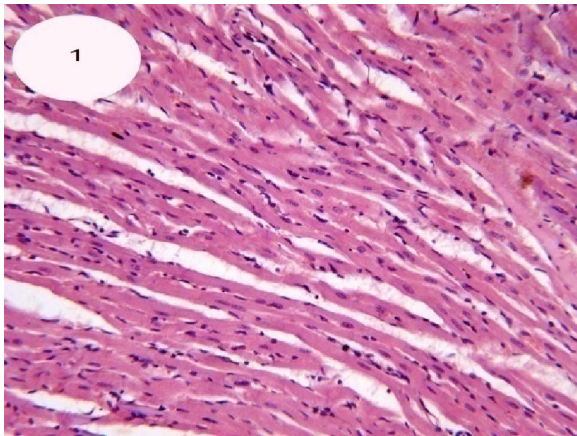


Figure1: A photomicrograph of a section of cardiac muscle of control group showing normal histological structure of cardiac muscle fibers cut longitudinally (H&E x200).

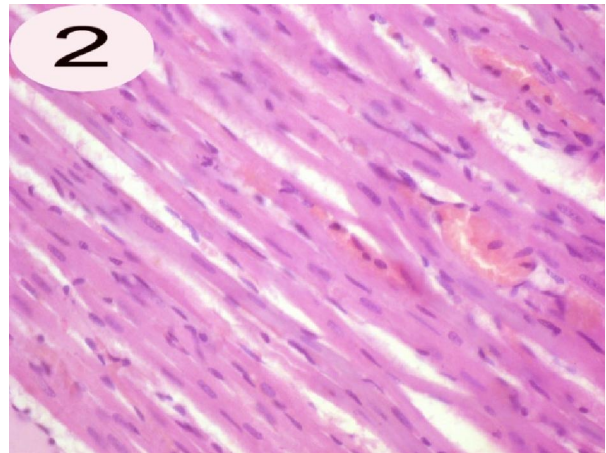


Figure2: A photomicrograph of a section of cardiac muscle of control group showing branched striated cardiac muscle fibers cut longitudinally with acidophilic sarcoplasm and centrally located nuclei. Myocardial blood capillaries appeared in the intercellular spaces (H&Ex400).

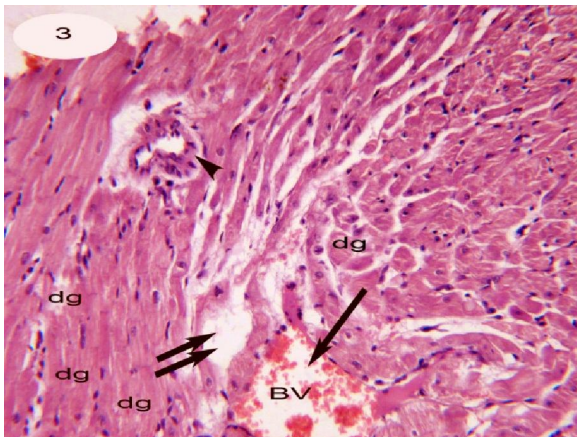


Figure3: A photomicrograph of a section of cardiac muscle of irradiated group displaying swelling, degeneration dg, with oedema ( ) in between the myocardial fibers, thickened vascular wall (head arrow) and dilated blood vessel ( ) (H&Ex400).

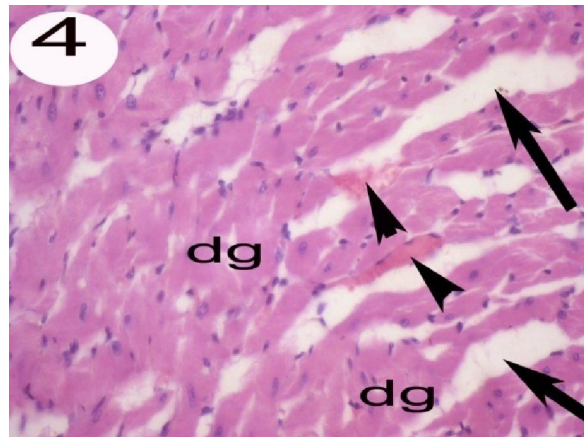


Figure4: A photomicrograph of a section of cardiac muscle of irradiated group displaying edema in between myofibers. Fragmentation, degeneration and widely separating myofibers with congestion of blood capillaries (head arrows) (H&Ex400).

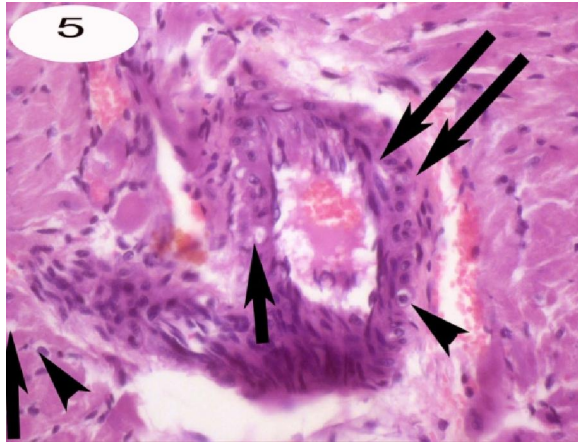


Figure5: A photomicrograph of a section of cardiac muscle of irradiated group showing thickened wall ( )Of the myocardial blood vessel with mild vacuolation (head arrow),Vacuolation ( )in the cells of cardiac muscle . cardiac muscle lost its normal architecture (H&Ex400).

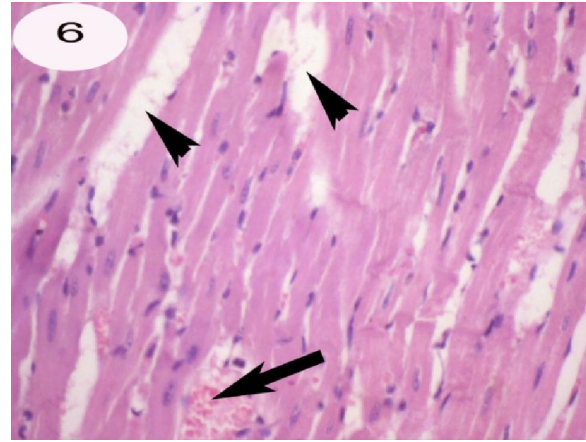


Figure6:A photomicrograph of a section of cardiac muscle of feeding cabbage leaves group showing edema in between the myocardial muscle fibers(head arrows) with dilated blood vessel ( ) (H&Ex400).

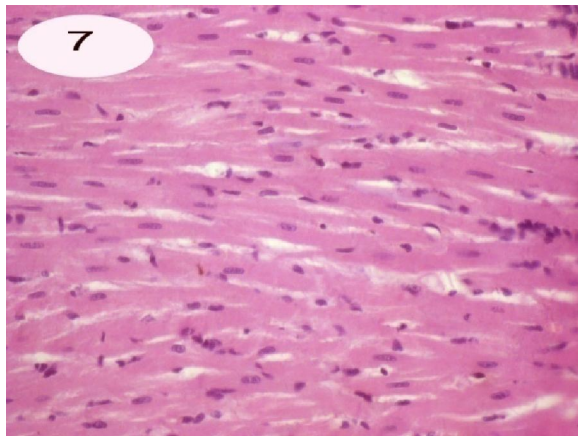


Figure7: A photomicrograph of a section of cardiac muscle of feeding cabbage leaves and irradiated group showing intact histological structure of myocardial muscle fibers (H&Ex400).

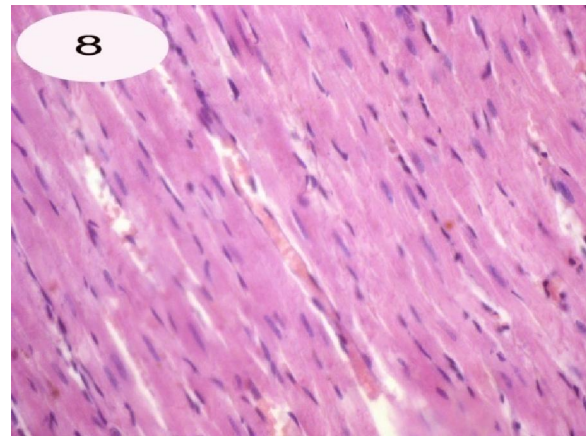


Figure8: A photomicrograph of a section of cardiac muscle of Septilin administration group showing normal histological pattern of myofibers and blood vessels(H&Ex400).

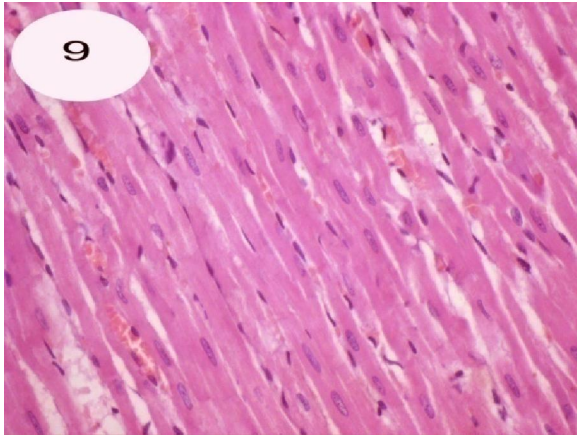


Figure9: A photomicrograph of a section of cardiac muscle of Septilin administration and irradiated group showing complete normal structure except edema appeared in small areas (H&Ex400)

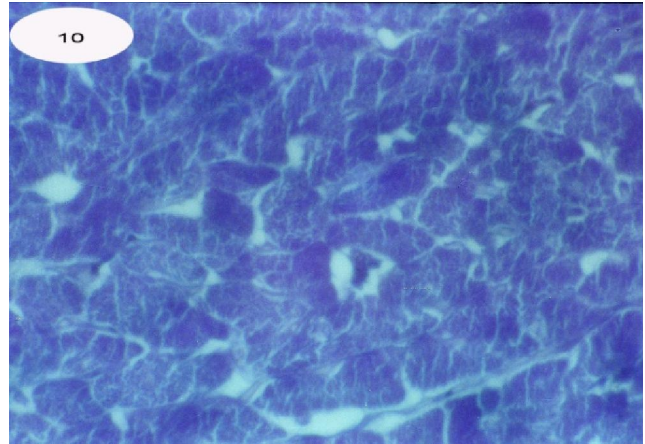


Figure10: A photomicrograph of a section of cardiac muscle of control group showing normal distribution of total protein (Bromophenol blue stain .X400)

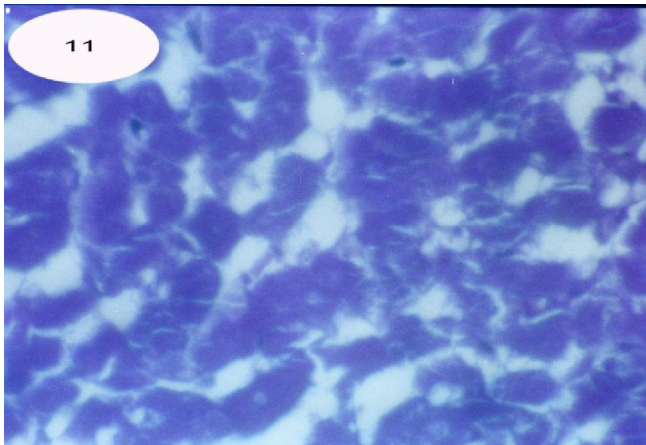


Figure11:A photomicrograph of a section of a cardiac muscle of irradiated group showing numerous areas negatively stained in between the myofibers with decreased total protein in the cardiac muscle (Bromophenol blue stain .X400).

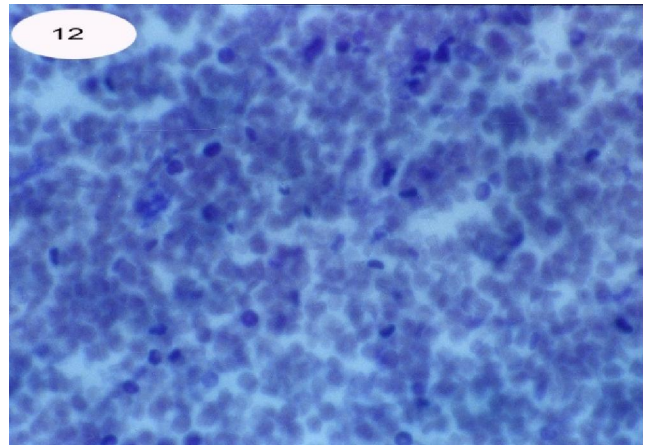


Figure12:A photomicrograph of a section of a cardiac muscle of Cabbage feeding group showing highly reduced total protein of the cardiac muscle (Bromophenol blue stain .X400) .

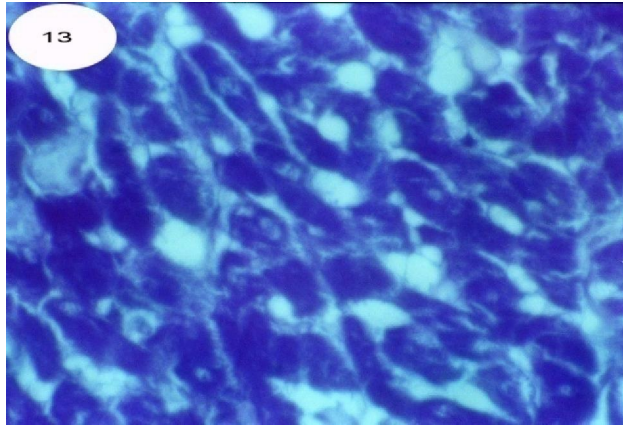


Figure13: A photomicrograph of a section of cardiac muscle of cabbage treated group and irradiated with gamma radiation showing highly depleted areas in between the myofibers . Some of these myofibers were moderately stained with fat cell deposition in between myofibers (Bromophenol blue stain .X400) .

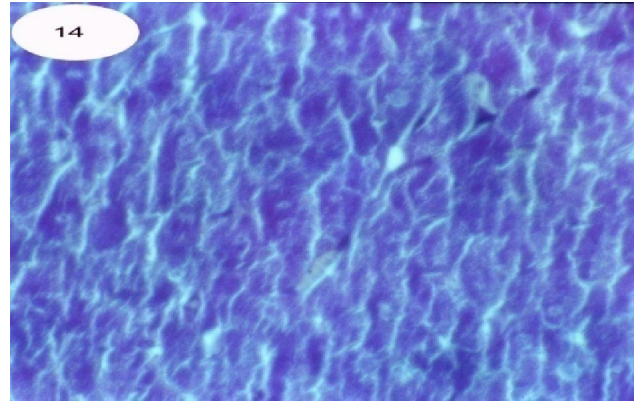


Figure14: A photomicrograph of a section of cardiac muscle of Septilin treated group showing normal predominant condensation of blue color (Bromophenol blue stain X400) .

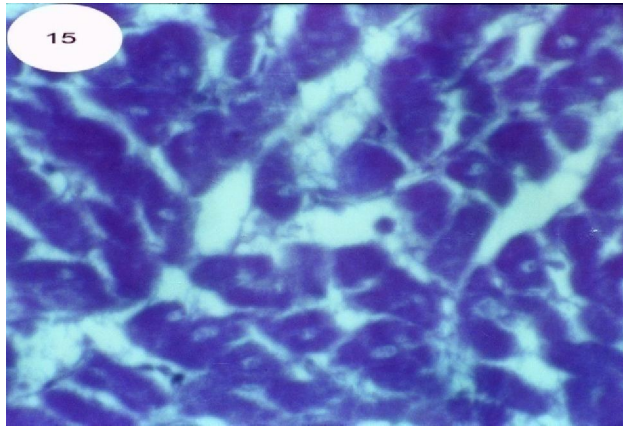


Figure15: A photomicrograph of a section of cardiac muscle of Septilin treated and irradiated group showing normal distribution of total protein (Bromophenol blue stain .X400) .

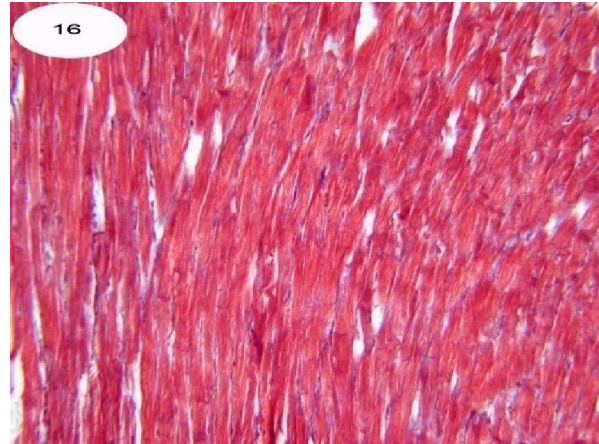


Figure16: A photomicrograph of a section of cardiac muscle of control group showing normal distribution of collagen fibers (Mallory's trichrome x200)

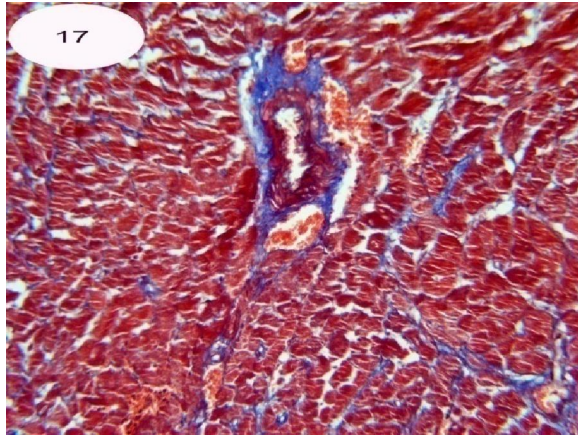


Figure17: A photomicrograph of a section of cardiac muscle of irradiated group showing densely stained collagen fibers in between myofibers and around blood vessels (Mallory's trichrome stain x200)

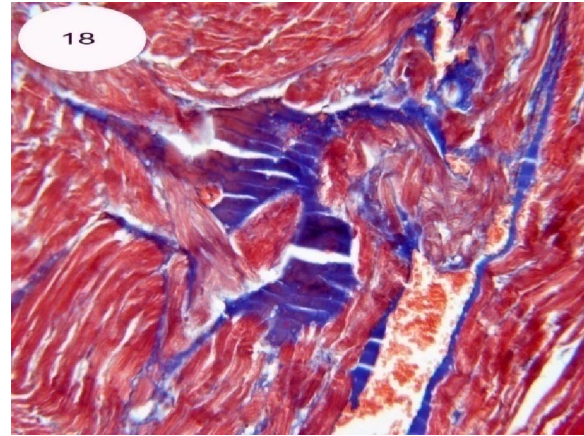


Figure18: A photomicrograph of a section of cardiac muscle of irradiated group showing magnification of fig.17 identify highly increased collagen fibers around blood vessels (Mallory's trichrome stain x400).

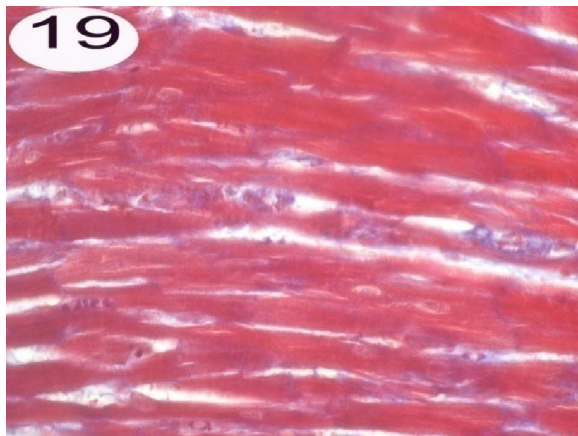


Figure19: A photomicrograph of a section of a cardiac muscle of Cabbage feeding group showing normal distribution of collagen fibers in between myofibers (Mallory's trichrome x400).

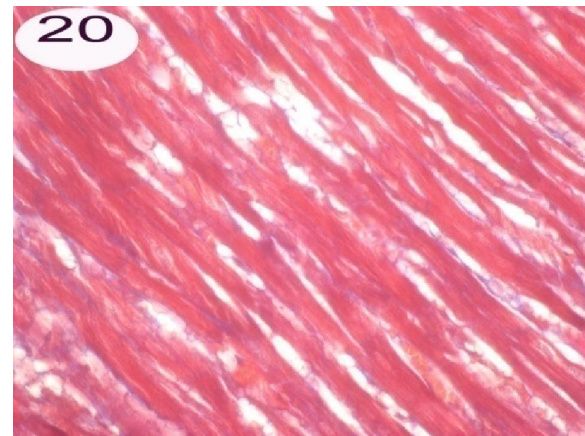


Figure20: A photomicrograph of a section of a cardiac muscle of Cabbage feeding and irradiated group showing normal distribution of collagen fibers with fat cell deposition in between myofibers (Mallory's trichrome x400).



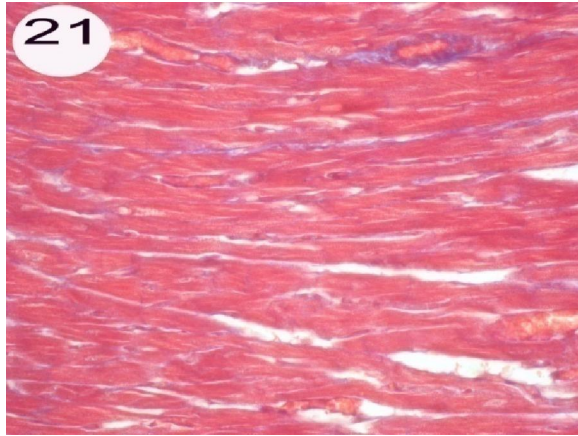


Figure21:Aphotomicrograph of a section of cardiac muscle of Septilin treated group showing normal distributin of collagen fibers with negatively stained edema areas (Mallory'strichrome x400).

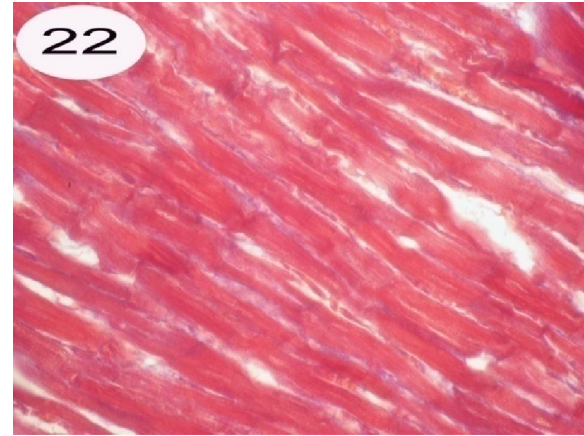


Figure22:Aphotomicrograph of a section of cardiac muscle of Septilin treated group showing normal distributin of collagen fibers with negatively stained edema areas (Mallory'strichrome x400).

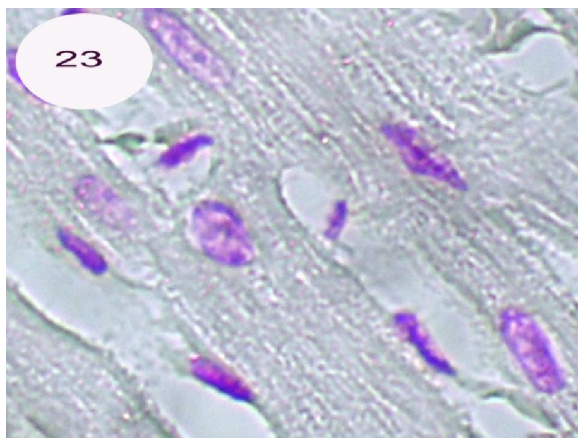


Figure23: A photomicrograph of a section of cardiac muscle of control group showing normal content of DNA (Feulgen reaction x1000).

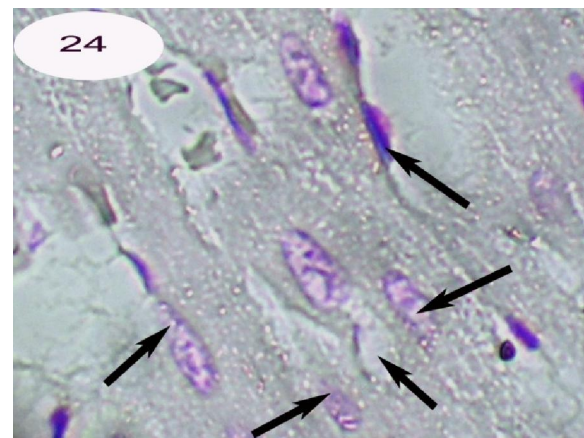


Figure24: A photomicrograph of a section of cardiac muscle of Irradiated group showing highly reduced chromatin content in myofibers (karyolysis ).(Feulgen x1000).

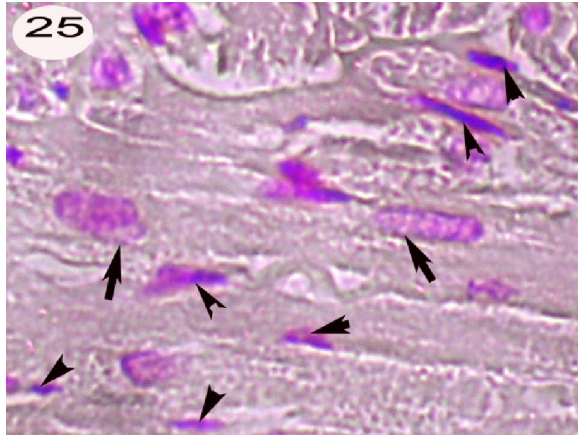


Figure25: A photomicrograph of a section of cardiac muscle of cabbage feeding group showing highly reduced chromatin materials in some myofibers( ), while some of these fibers contained condensed chromatin(pyknosis) (head arrow) (Feulgen reactionx1000).

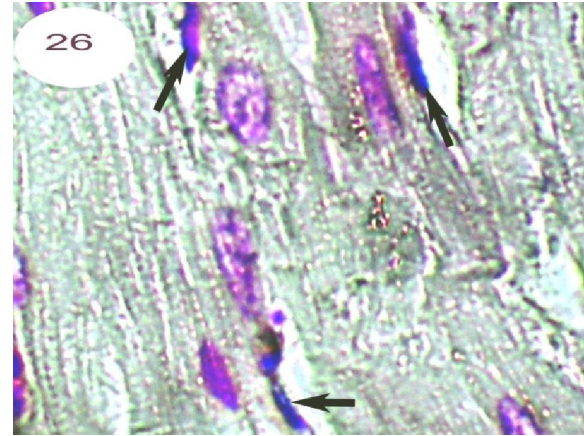


Figure26: A photomicrograph of a section of cardiac muscle of Cabbage feeding and irradiated group showing an improvement in DNA content. Some nuclei contained condensed chromatin (pyknosis)( ).

( Feulgen reaction x1000).

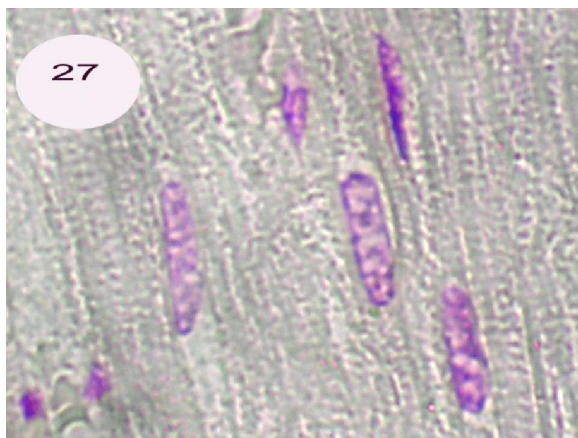

Figure27: Aphotomicrograph of a section of cardiac muscle of Septilin treated group showing nearly normal DNA content (Feulgen reaction x1000).

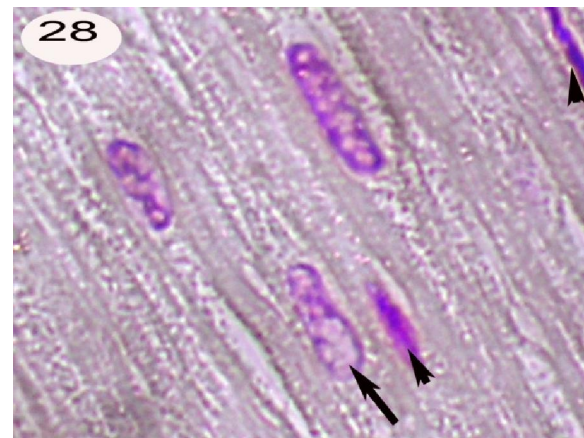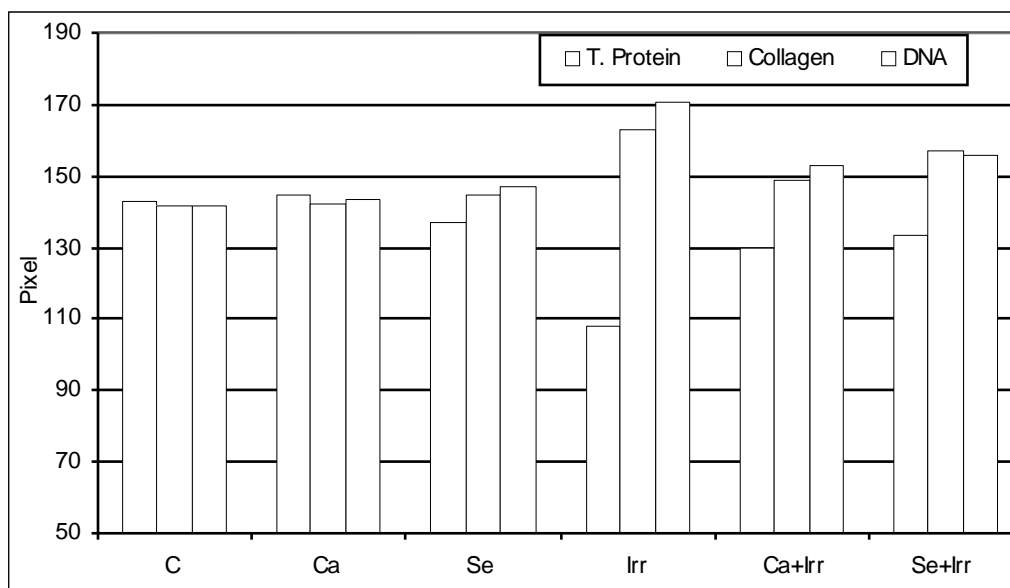


Figure28: Aphotomicrograph of a section of cardiac muscle of Septilin and irradiated group showing nearly normal DNA except few areas of condensed chromatin ( ),reduced chromatin ( )(Feulgen reaction x1000).

Table (1): The quantitative measurements of the color density (Pixel) of total protein, collagen and DNA in the cardiac muscles of control and treated groups of male rats.

		Control (C)	Cabbage (Ca)	Septilin (Se)	Irradiated (Irr)	Cabbage +Irradiated (Ca+Irr)	Septilin +irradiated (Se+Irr)
Total protein	Average	142.6	144.8	136.9	107.7	129.9	133.4
	± SD.	8.36	7.78	11.71	11.35	16.88	11.73
	Max.	155	152	152	129	160	152
	Min	129	128	118	95	108	119
	t test		0.27	0.13	0.00	0.03	0.04
	Probability		Non Sig.	Non Sig.	Highly Sig.	Sig.	Sig.
	% of change		1.54	-3.99	-24.47	-8.90	-6.45
Collagen	Average	141.8	142	144.6	162.9	148.8	156.7
	± SD.	19.33	10.51	13.27	17.85	19.07	15.18
	Max.	171	152	164	184	182	180
	Min	118	120	122	130	120	132
	t test		0.49	0.32	0.00	0.25	0.07
	Probability		Non Sig.	Non Sig.	Highly Sig.	Non Sig.	Non Sig.
	% of change		0.14	1.97	14.88	4.93	10.51
DNA	Average	141.4	143.2	146.6	170.6	152.5	155.7
	± SD.	14.83	16.34	15.01	11.26	9.91	14.15
	Max.	169	167	168	185	165	174
	Min	128	112	127	154	135	130
	t test		0.32	0.26	0.00	0.03	0.01
	Probability	Non Sig.	Non Sig.	Non Sig.	Highly Sig.	Sig.	Sig.
	% of change		1.27	3.67	20.65	7.85	10.11

$P \geq 0.01$  Highly Significant,  $P \geq 0.05$  Significant,  $P < 0.05$  Non significant



Histogram (1): Quantitative measurements of total protein, collagen and DNA in the cardiac muscles of control and treated groups of male rats.

#### 4. Discussion

Radiation leads to cardiotoxic effects in the therapeutic range. Histopathological evaluation proved these cardiac abnormalities. These changes were in accordance with Gladstone et al, 2004, Yeung Hopewell, 1986 and Bishop et al, 1965, who insisted on radiation induced cardiomyopathy (damage to the heart muscle). Radiation leads to the increase formation of free radicals. Oxygen free radicals have been shown to cause contraction failure and structural damage to the myocardium that will affect cardiac performance Tomomi and Hisjuki, (1999).

Cardiac muscle of rats in cabbage feeding group for a month and exposed to  $\gamma$ -radiation showing intact histological structure of the myocardial muscle fibers. This effect due to the antioxidant activity of cabbage that is capable of neutralizing free radicals molecules making them less reactive, and could protect cardiac muscles against radiation Eberhardt et al (2005).

Cardiac muscle of rats in cabbage feeding group for a month showing edema in between the myocardial muscle fibers with dilated myocardial blood vessels. These changes were in accordance

with Arora and Saremi, (2010), Kelemen et al, (2005) and Tribble, (1999) who pointed out to the long-term use of antioxidants in diseased individuals is of concern, owing to increased high density lipoprotein levels, which may aid in the development of atherosclerosis and thrombosis.

Cardiac muscle of rats administered Septilin for a week and exposed to radiation showing normal histological pattern except in small area edema appeared in between the myocardial muscle fibers with dilated blood vessel. Meanwhile Septilin administration showing intact myocardial muscle fibers this result may be due to its ability to normalize lipid metabolism, support heart health, regulate blood pressure, blood vessel constriction and tendency of blood to form clots (Dev, 1997).

In conclusion White Cabbage proved marked protection than Septilin against  $\gamma$ -radiation.

#### Acknowledgment

The authors thank to Professor Mona Ahmed El-Gawish in Biology Radiation Department at the National Centre for Radiation Research and

Technology, Cairo, Egypt for her help to achieve this research.

### Corresponding Author

Enas Aly Khalil

Assistant Professor of Histology National Organization for Drug Control and Research Cairo Egypt

E-mail enasamk@hotmail. Com.

Mobile: (+20) 0168025803

### References

- Agrawal, N. and Veena, A. (1986): Prophylactic role of Septilin in prevention of upper respiratory tract infections (URTI) smokers. *Uttar Medicine and surgery*(26),5,25.
- Armado, C.; Cabrera, O.; Morales, O and Menda, P. (1991): Pharmacological properties of Moringa Oleifera, 1—Preliminary screening for antimicrobial activity. *Journal of Ethnopharmacology* 33, 213-216.
- Bishop, V. ; Stone, H.; Simek, J and Davis, J (1965): Effects of external irradiation of the heart on the cardiac output, venous pressure and arterial pressure. *The journal of Nuclear Medicine* Vol.6No.9 645-650.
- Bhasin, R. (1990): Clinical evaluation of Septilin in chronic bronchitis. *Ind. Practit.*, 43:83-87
- Chu, Y.; Sun, J. Wu, X and Luu, R (2002): Antioxidant and antiproliferative activities of common vegetables. *J. Agri. Food. Chem.* 6; 50(23): 6910-6916
- Daswani, B. and Yegnanarayan, R. (2002): Immunomodulatory activity of Septilin a polyherbal preparation. *Phytother. Res.*, 16:162-165
- Dev, S. (1997): Ethnotherapeutics and modern drug development: The potential of Ayurveda, *Current Science*, 73:909-928
- Drury, R. A. and Wallington, E.A. (1980): *Carleton's Histological Techniques*, 5<sup>th</sup> ed, Oxford University Press. London, New York Toronto, 1:653-661
- Dunn, W.L. (1974): *Hand book of Histopathological and Histochemical Techniques*, 3<sup>rd</sup> ed., RED WOOD BURN Limited . Great Britain., 415-416
- Eberhardt, M.V. ,Kobira, K., Keck, A .S., Juvik J Aand Jeffery EH (2005): Correlation analyses of phytochemical composition, chemical and cellular measures of antioxidant activity of broccoli (*Brassica Oleracea* L.Var.italica) *J. Agric Food Chem.*53:7421-31
- Gadekar, H; Vijay, A. ; Komawqar, J. and Sonawar, S. (1986): Septilin in acute tonsillitis in children below 12 years of age *Probe*, 25:164-165
- Gladstone, D.; Flanagan, M.; Southworth, J.; Halady, V.; Thibault, M.; Hu, E. and Hoopes, P. (2004) : Radiation induced cardiomyopathy as a function of radiation beam gating to the cardiac cycle. *Phys. Med. Biol.*, 1475-1484
- Horobin, R.W. and Bancraft, J.B. (1998): *Trouble Shooting Histology Stains*. Churchill Living Stone Medical Division of professional limited. P.56.
- Isbrucker, R, and Burdock, G (2006): Glycyrrhizin Toxicity, *Regulatory Toxicol Pharmacol*, 46:167
- Joshi, K.; Ascherio, A. and Manson, J. (1999): Fruit and vegetable intake in relation to risk of ischemic stroke. *JAMA*, 282, 1233-9
- Katay, H. and Hamaza, A. (2008): Red Cabbage ameliorates diabetic nephropathy in rats. *Evid Based Complement Alternat Med.* 5(3) 28, 1-7.
- Kelemen, M.; Vaidya, D.; Walters, D.; Ioward, B. and Younes N (2005): Hormone therapy and antioxidant vitamins do not improve endothelial vasodilator function in postmenopausal women with established coronary artery disease. *Atherosclerosis*; 179:193-200
- Mazia, D.; Brewer, P. and Alert, M. (1953): The cytochemical staining and measurement of protein with bromophenol. *Biol Bull* ,104:57-76
- Nair, S.; Nagar, R and R. Gupta, (1996): Dietary anti-oxidant phenolics and flavonoids in coronary heart disease. *Indian Heart Journal* P. 545.

20. Ramesh, S., Thakur, R. and Bahanu, A. (1989): Septilin in compound infected injuries. *Probe* (28),2,138-141
21. Ross, D. (1984): The anti-infective and anti-bacterial efficacy of Septilin. *Probe*,23:84-87.
22. Sarabhai, K. and Sandeep, G. (1989): Role of Septilin in prevention of acute dacryocystitis. *Probe*(29),1,29-31.
23. Saremi and Arora (2010): Vit E and cardiovascular disease. *Am. J. Ther.* ( May-June),17(3):233-256
24. Sanjit, R.(1992):Clinical evaluation of Septilin in allergic rhinitis. *Probe* (31)2, 146-156
25. Sendecor, G.W. and Coebam, W.G.(1969 ): In "Statistical Methods" 6<sup>th</sup> ed . Iowa State Univ. Press. Ames, Iowa, USA, P.70.
26. Sharma, S.; Agarwal, H. and Dharam, P. (1986). Septilin in infective dermatoses. *Probe*, 25:156-161.
27. Singh, K. (2001): Role of combination of multiple herbal drugs (Septilin) in the prophylaxis of diabetic foot ulcer double blind trial. *Indian Journal of Dermatology* (46), 2,83.
28. Smiechowschowska, A.; Bartoszek, A. and Namiesnik, J. (2008): Cancer chemoprotective agents: glucosinolates and their decomposition products in white Cabbage (*Brassica oleracea* Var. *Capitata*). *Postepy High Med Dosw.* Apr.2; 62:125-40.
29. Srivastava, A. 1985: Clinical trial of Septilin on ulcers (specific and non specific and surgical wounds). *The medicine and surgery*, 25,10,31.
30. Tomomi, I. and Hisjuki, J. (1999): Oxygen free radicals in the failing myocardium. *Circulation Res.*; 85: 357-363.
31. Tribble, D (1999): Antioxidant consumption and risk of coronary heart disease emphasis on vitamin C, vitamin E and  $\beta$ -carotene. *Circulation*, 99:591-595
32. Udupa, A L : Rao, S G : Kulkarni, D R (1989): Wound healing profile of Septilin Indian-J-*Physiol-Pharmacol.* 1989 Jan-Mar; 33(1): 39-42
33. Yeung, T. and Hopewell, J. (1986): Histological and physiological studies on rat heart following irradiation with single doses of x-rays. *Br. J. Cancer Suppl.* 7:169-8.
34. Wu, L. and Juurlink, K. (2001): The impaired glutathione system and its up-regulation by sulphoraphane in vascular smooth muscle cells from spontaneously hypertensive rats. *Hypertension*; 19:1819-1825.
35. Xue, M.; Qian, Q.; Adaikalakoteswari, A.; Rabbani, N.; Babaei Jadidi, R. and Thornalley, P. (2008): Activation of NF-E2-Related Factor-2 Reverses Biochemical Dysfunction of Endothelial Cells Induced by Hyperglycemia Linked to Vascular Disease. *Diabetes* 57;2809-2817.

5/9/2010