



## Teratogenic Effect of Ciprofloxacin in Albino Rats.

Zeinab. M. Gazi & Nura, I. AL Zail

[zgazi.75@gmail.com](mailto:zgazi.75@gmail.com)

**Abstract:** The present study aims to evaluate the risk of the ciprofloxacin drug on the development of fetuses of the albino rat during pregnancy. Pregnant rats were exposed orally to 206 mg kg<sup>-1</sup> of coumatetralyl daily on days 5 through 20 of gestation. Animals were sacrificed on the 20th day of gestation for fetal examination. Ciprofloxacin produced a significant elevation in the percentages of late resorption sites **aab. M. Gazi & Nura, I. AL Zail** and dead fetuses compared with the control group. The mean fetal weights were significantly reduced. Visceral abnormalities were revealed in the form of dilated brain ventricles, hypertrophy of the heart, hypoplasia of the lung, dilated renal pelvis. Skeletal examination showed wide open fontanel, incomplete ossification of parietal and interparietal bones, incomplete ossification of the sternum, reduction in the number, or even complete absence of phalanges, sacral, and/or caudal vertebrae. The results indicate that ciprofloxacin has a teratogenic effect at lower doses. Therefore, further studies are necessary to evaluate its safety during pregnancy.

[Zeinab. M. Gazi & Nura, I. AL Zail. **Teratogenic Effect of Ciprofloxacin in Albino Rats.** *Rep Opinion* 2021;13(6):70-79]. ISSN 1553-9873 (print); ISSN 2375-7205 (online). [http://www.sciencepub.net/report\\_2](http://www.sciencepub.net/report_2). doi: [10.7537/marsroj130621.02](https://doi.org/10.7537/marsroj130621.02).

**Keywords:** Ciprofloxacin, Teratogenic Effects, Visceral, Skeletal, Rats.

### Introduction

Antibiotics are among the most generously prescribed medications during pregnancy and lactation. (Susan *et al.*, 2004) Pregnancy can increase the susceptibility of urinary tract infections (UTIs) in women because of physiological changes (Gilbert *et al.*, 2013). Bacterial infections need effective treatment during pregnancy because they may be hazardous to the health of the mother and the unborn child (Nicolle, 2003 and Matuszkiewicz *et al.*, 2015). Fluoroquinolones are one of the main classes of antimicrobials used in the treatment of urinary tract infections (Schuid *et al.*). The original fluoroquinolone is norfloxacin; others in the group include ciprofloxacin, ofloxacin, clinofloxacin, ternofloxacin, levofloxacin lomefloxacin, and sparfloxacin (Patrick, 2003). All are entirely synthetic (Rita, 2019) Ciprofloxacin is one of the most recent advancements of Fluoroquinolone derivatives in the field of synthetic antimicrobial agents, It has a greater intrinsic antibacterial activity and a broader antimicrobial spectrum than Nalidixic Acid, because of its high concentration in urine (Friedman and Polifka 2000) However, experimental studies on animals and human experience dealt with the side effects of it, including teratogenicity and fetotoxicity [Aboubakr *et al.*, 2014, Siddiqui and Naqvi 2010 and Hamida *et al.*, 2018]. Therefore, With this objective in view, The aim of the work is to study the teratogenic effect of ciprofloxacin in the offspring of rats treated orally at a dose of 206 mg / kg during the period of organogenesis.

### Materials and Methods

#### Drug

**Ciprofloxacin** (CPX) (1-Cyclopropyl -6-Fluoro-1, 4-Dihydro -4-Oxo -7-(1-Piperazinyl) -3-Quinolonecarboxylic Acid). Its empirical formula is  $C_{17}H_{18}FN_3O_3$  and its molecular weight is 331.4 g/mol. It is a faintly yellowish to light yellow crystalline substance Obtained from the pharmacy (prescribed by doctors), Ciprofloxacin 500 mg, Bristol Laboratories Ltd.

#### Animals

The total number of 40 adult female albino rats weighing 200–220 g. All animals had access to laboratory Standard feed and tap water.

The total number of 40 adult female albino rats weighing 200–220 g. All animals had access to laboratory Standard feed and tap water.

The animals were left for a week to adjust to laboratory conditions before use. Each two adult virgin females in proestrus were caged overnight in an animal plastic cage with a normal mature male. Vagina was examined daily for suggesting pregnancy by a vaginal smear technique according to the method of (Matthews and Kenyon, 1984) [Fig.1] Pregnancy was confirmed the following morning by the presence of sperms in the vaginal washing of each female and considered as the zero-day of pregnancy.

### Experimental Design

The pregnant rats were divided into two groups each of 20 rats. The first group was kept without any treatment and served as a control. The second group was given Ciprofloxacin orally at a dose of 206 mg kg<sup>-1</sup> (low dose) (Fatemeh et al.,2012) The dose of 206 mg/ kg for a mouse is comparable to the human daily therapeutic dose, following correction for interspecies differences with a dose-scaling factor. (Reagan et al.,2007) daily on days 5-20 of gestation.

### Procedures of teratogenic examination

External examination All treated and control female groups were killed by slaughter to the calculated date of delivery (at the 20th day of gestation). After that, an incision was made in the abdominal wall to expose the I viscera. The gravid uterus of each dam was exteriorized then the numbers then the numbers The fetuses were blotted dry, weighed, and examined for gross external abnormalities. The remained fetuses were divided into one-third kept in Bouin's fixative for at least one week, after which fetuses were sectioned using Wilson's free-hand razor blade sectioning technique as described by Manson and Kang, (1994) searching for internal visceral malformations. The remaining two-thirds of the fetuses from each group were fixed in 95% ethanol, eviscerated then cleared with 2 % potassium hydroxide,

and stained with alizarin red S – stain solution for examining the skeletal deformities.

### Statistical analysis

Our data are recorded as percentages and means  $\pm$  standard error(SE). Statistical significance of fetal weights was determined by one way ANOVA while Chi-square test was used for the comparison of the different morphological, visceral skeletal anomalies between Our data are recorded as percentages and means  $\pm$  standard error(SE). Statistical significance of fetal weights was determined by one way ANOVA while Chi-square test was used for the comparison of the different morphological, visceral skeletal anomalies between

### Results

The pregnant rats were orally administered 206 mg kg<sup>-1</sup> (Group B) of ciprofloxacin during the gestational period (5-20th day), with no clinical signs, with no mortality cases recorded. and Significantly decreased the numbers of live fetuses per dam. and the fetal body weights compared to the control (Fig. 2). The resorption (Fig. 3) and dead fetuses number per dam were significantly increased in the treated group compared with the control group. which were recorded in Table (1).

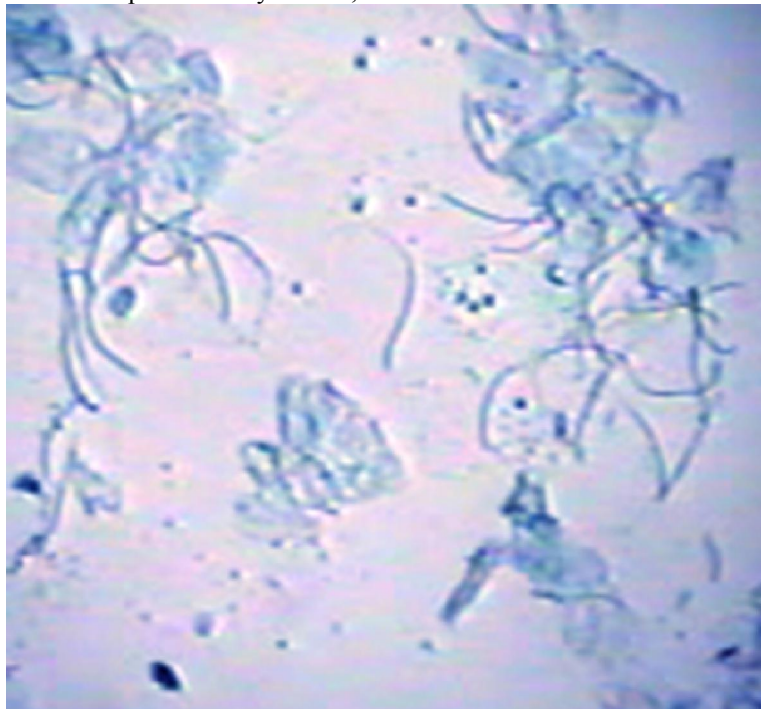


Fig.1 vaginal smear of a female rat showing sperm

Table 1: Morphological examination of rat fetuses obtained from control and treated dams.

Groups	Parameters
--------	------------

	No. of pregnant dams	No. of uterine implants	Late resorption	Dead fetuses	Live fetuses	Mean fetal weights (g)
			NO. %	NO. %	NO. %	
Control	10	103	0.97 1	0 0	99 102	4.05±0.03
ciprofloxacin	10	80	19 23.8*	13.8* 50	62.5* 50	3.01±0.07*

Significant difference between control and treated groups at  $p \leq 0.05$ .\*

Table 2: Visceral malformations of rat fetuses obtained from control and treated dams.

Groups	Parameters				
	Total No. of fetuses examined	Dilated renal pelvis	Hydrocephaly	Heart hypertrophy	Lung hypoplasia
		NO. %	NO. %	NO. %	NO. %
Control	34	0 0	0 1	0 0	0 0
ciprofloxacin	21	9 42.9	52.4 11	57.1 12	42.9 9

Significant difference between control and treated groups at  $p \leq 0.05$ .\*




Fig.2 Two rat fetuses the left one is control and the right one obtained from a pregnant dam treated orally with 206 mg kg<sup>-1</sup> ciprofloxacin daily on days 5-20 of gestation showing stunted growth (dwarfism).

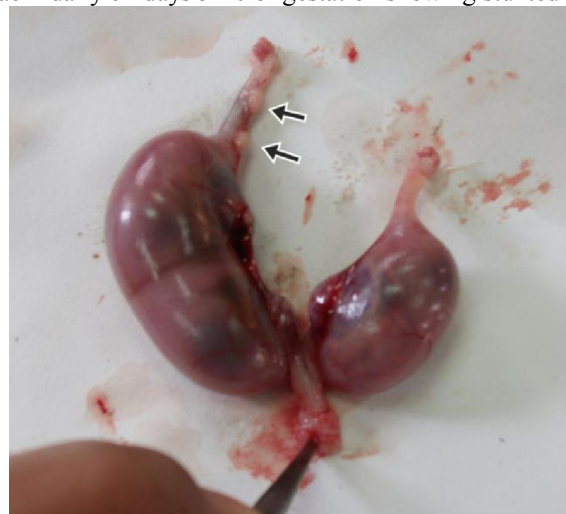

Fig. 3 Uterus of a pregnant female rat exposed to ciprofloxacin exposure at 206mg kg<sup>-1</sup> on days 5-20 of gestation showing resorption sites( Arrow).

The effects of ciprofloxacin exposure (orally at 206mg/ kg on days 5-20 of gestation) on the visceral organs of the obtained rat fetuses from exposed dams are shown in Table( 2) and Fig. 4–7. Ciprofloxacin significantly increased

the total fetuses with visceral anomalies compared to the control. The visceral anomalies recorded in the treated groups were in the form of dilated brain lateral ventricles (hydrocephaly) (Fig. 4), heart and lung hypoplasia (Fig. 5 and 6), dilated renal pelvis (Fig. 7).

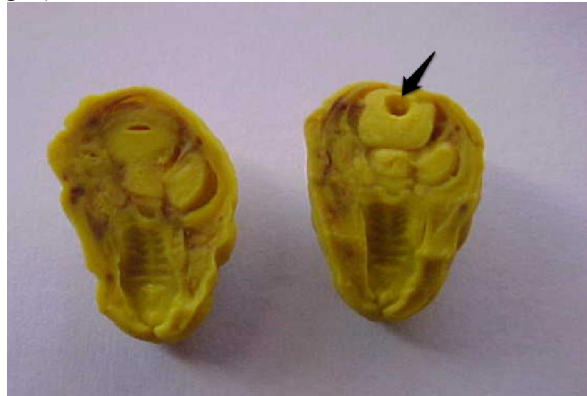


Fig. 4 Transverse sections in the head of two rat fetuses, the left one is control and the right one obtained from a pregnant dam treated orally with  $206 \text{ mg kg}^{-1}$  ciprofloxacin daily on days 5-20 of gestation showing Dilation of the third ventricle of the brain.

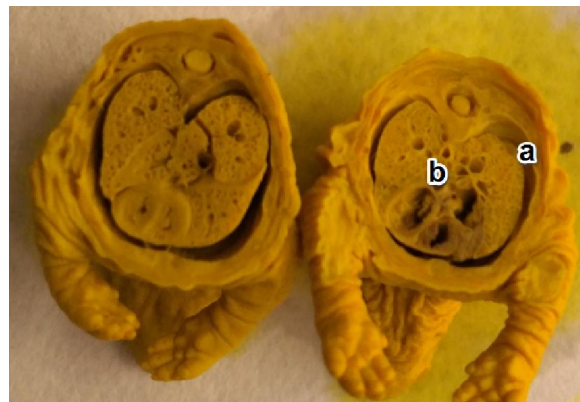


Fig. 5 Transverse sections in the chest of two rat fetuses the left one is control and the right one obtained from a pregnant dam treated orally with  $206 \text{ mg kg}^{-1}$  ciprofloxacin daily on days 5-20 of gestation showing pulmonary hypoplasia(a) with cardiac enlargement(b)



Fig. 6 Transverse sections in the chest of two rat fetuses the left one is control and the right one obtained from a pregnant dam treated orally with  $206 \text{ mg kg}^{-1}$  ciprofloxacin daily on days 5-20 of gestation showing hypoplasia of the lung



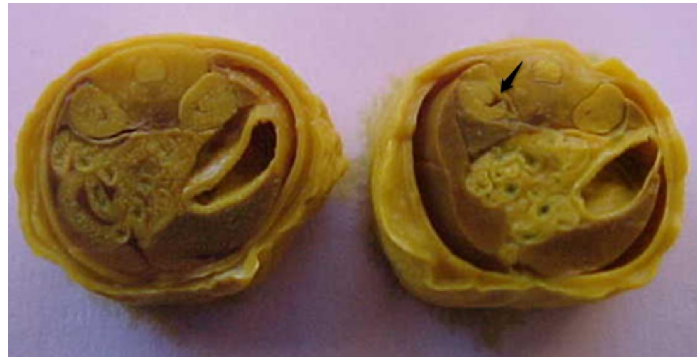


Fig.7 Transverse sections in two rat fetuses the left one is control and the right one obtained from a pregnant dam treated orally with  $206 \text{ mg kg}^{-1}$  ciprofloxacin daily on days 5-20 of gestation showing dilated renal pelvis Many skeletal abnormalities in the examined fetuses from ciprofloxacin-treated dams are shown in Table( 3) and Figs. 8–13. It was revealed that oral exposure of pregnant dams to ciprofloxacin induced a significant elevation in the percentages of the offspring that had skeletal anomalies compared to the control.

T

Table 3: Skeletal malformations of rat fetuses obtained from control and treated dams

Groups	Parameters						
	No. of Examined Foetuses	Wide open fontanel	Incomplete ossification of parietal and/or interparietal bones	Sternum	Phalanges	Sacral vertebrae	Caudal vertebrae
		NO. %	% NO.	NO. %	NO. %	NO. %	NO. %
Control	68	1.161	0 0	00	0 0	0 0	2 2.9
ciprofloxacin	40	35* 14	30* 12	27.5* 11	25*10	22.5*9	32.5* 13

Significant difference between control and treated groups at  $p \leq 0.05$ .\*

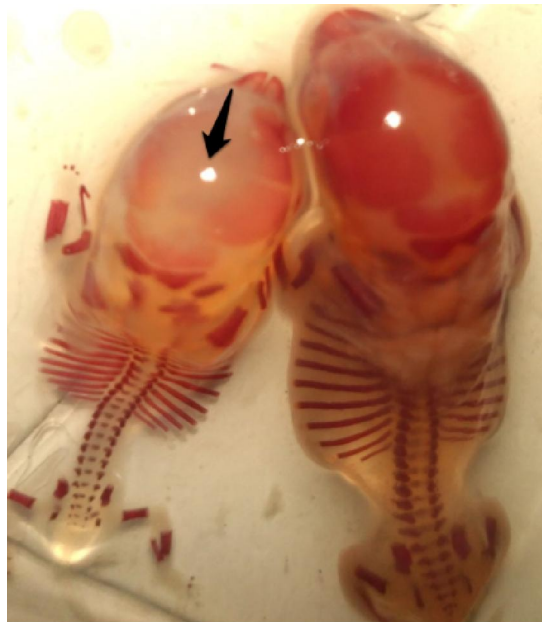


Fig. 8 Skeleton of two rat fetuses the left one is control and the right one obtained from a pregnant dam treated orally with  $206 \text{ mg kg}^{-1}$  ciprofloxacin daily on days 5-20 of gestation showing wide open fontanel.’

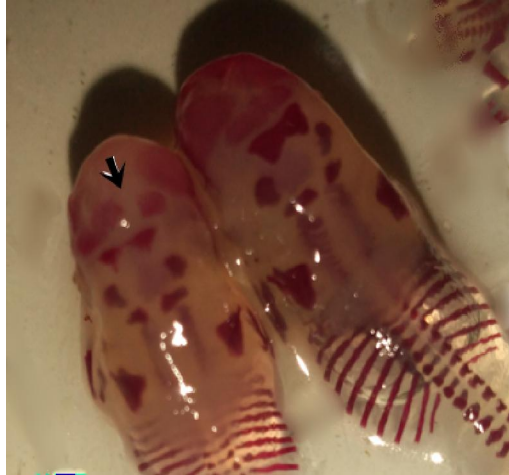

Fig. 9 Skeleton of two rat fetuses, the left one is control and the right one obtained from a pregnant dam treated orally with  $206 \text{ mg kg}^{-1}$  ciprofloxacin daily on days 5-20 of gestation showing incomplete ossification of parietal and interparietal bones.

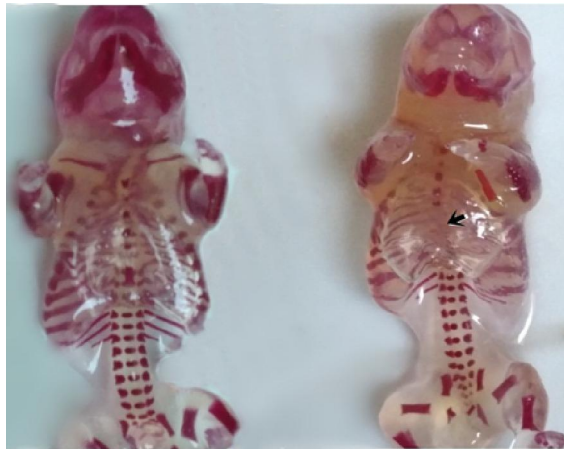

Fig. 10 Skeleton of two rat fetuses, the left one is control and the right one obtained from a pregnant dam treated orally with  $206 \text{ mg kg}^{-1}$  ciprofloxacin daily on days 5-20 of gestation showing reduced number of sternbrae.

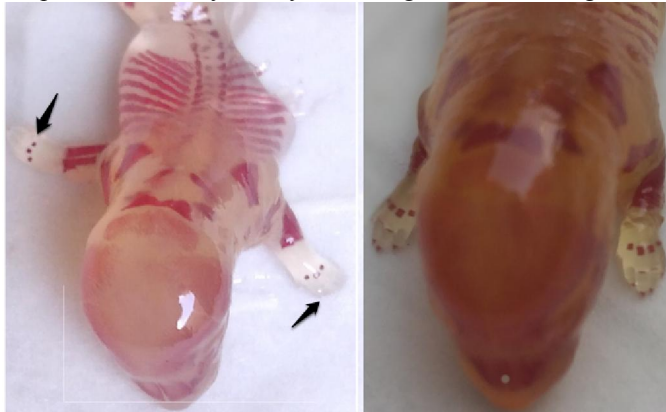

Fig. 11 Skeleton of two rat fetuses, the left one is control and the right one obtained from a pregnant dam treated orally with  $206 \text{ mg kg}^{-1}$  ciprofloxacin daily on days 5-20 of gestation showing absence of hind limb phalanges.

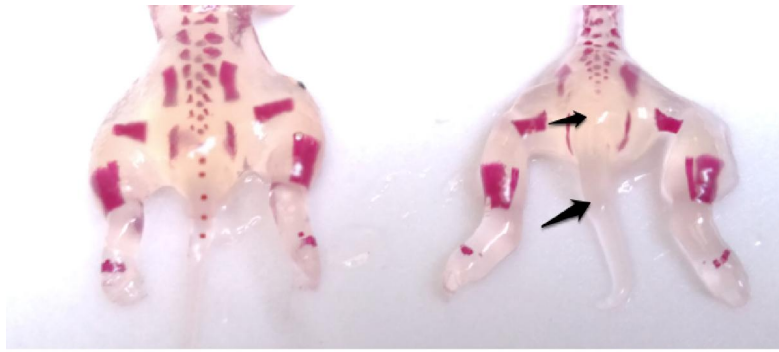


Fig. 12 Skeleton of two rat fetuses, the left one is control and the right one obtained from a pregnant dam treated orally with 206 mg kg<sup>-1</sup> ciprofloxacin daily on days 5-20 of gestation showing absence of sacral and caudal vertebrae.

## DISCUSSION

Oral administration of ciprofloxacin to female pregnant rats during the period of organogenesis induced a decrease in the number of fetuses and an increase in the number of resorbed fetuses either early or late when compared with that recorded value of the control group. This result was consistent with the data reported after administration of enrofloxacin, ciprofloxacin, ofloxacin, and norfloxacin to domestic animals. Where very high doses of it in female monkeys led to a decrease in the number of fetuses (Vancutsem et al.,1990 and Watanabe et al.,1992). there was a significant decrease in fetal body weight, fetal body length, and fetal tail length significantly decreased after ciprofloxacin administration in pregnant female rats. (Siddiqui, M.A and Naqvi,2010) reported that, ciprofloxacin significantly decreased litter size, and fetal weight and increased fetal resorption ratio and fetal loss when given to pregnant rats. These results are consistent with other studies of teratogenicity of ciprofloxacin in women exposed to ciprofloxacin during pregnancy. (Friedman and Polifka 2000 and Nahum et al., 2006). Also other several studies (Changwon Yang, et al.,2020; Schaefer et al.,1996; Gerenutti et al.,2006; Greenfield, 2004; and Loebstein et al.,1998) concluded that treatment with a rapamycin-induced decrease in the number of fetuses and fetal weight and increase in the number of resorbed fetuses.in another study, pregnant rats were found to be exposed to norfloxacin During the period of organogenesis, the weight and height of the fetus decreased significantly (Siddiqui, M.A and Naqvi,2010) . Chernoff et al.,1989) showed a relationship between maternal toxicity and developmental toxicity. Cassano, et al. and Giamarellouet al. found that the maternal serum levels of ciprofloxacin are several times lower than those in non-pregnant women(Cassano et al.,2010 and Chernoff et al.,2008).

The antibiotics having low plasma protein binding usually reach the highest concentrations in the

fetal serum (Niebyl 2003 and Gian,2006) as enrofloxacin and ciprofloxacin (Mares et al.,2018) For this reason, the increase in the number of resorbed fetuses in the present study may be attributed to the interference of the tested drug with the placental transmission of leucine amino acid and magnesium as deficiency of leucine or magnesium produced a high incidence of a fetal resorption.(Tuchmann-Duplessis, 1975) Also it may be attributed to discontinued production of placental progesterone when hormone production switched from luteal to placental[Carter, 2012] The reported decrease in fetal weight and height that resulted from the oral administration of the medication may be attributed to a nutrient deficiency Needed by embryos because female rats receive ofloxacin Or, levofloxacin diarrhea may occur due to an imbalance in the intestinal bacteria as reported in a study [Takayama, et al., 1986 and Watanabe, et al.,1992]. of the fluoroquinolones is mild at therapeutic doses, and generally consists of gastrointestinal disturbances such as nausea, vomiting, and diarrhea (Marchbanks, 1993). At slightly higher doses the central nervous system ( CNS) signs of dizziness, restlessness, headache, depression, somnolence, or insomnia may be seen (Christ,1990). On the other hand the quinolone group causes a detectable level of DNA damage in fetal tissues (Pino et al.,1991) decreases the number of viable cells (Shakibaei et al.,2002) and increased embryo lethality (Hummler et al.,1993 and Watanabe et al.,1992).

Fluoroquinolones are known to act as DNA gyrase inhibitors as well as mitosis inhibitors. The complete damage of DNA could result in fetal loss or resorption, while partial damage could induce malformation (Al-Snafi, and Shafik 1997and Jeffry et al.,2019) . On the other hand DNA damage induced by CPX may be attributed to its ability to releasing oxygen free radicals (Gürbay et al.,2006) It is known that oxygen free radicals attack DNA (Arriaga et al.,2000).

Previous studies reported that ciprofloxacin caused chromosomal aberration and sister chromatid

exchange when human lymphocytes were cultured in vitro where abnormalities appeared in the form of dilated cerebral ventricles (Minta et al., 2005). Also the findings of (hydrocephalus), nasal dilation, cardiac hypoplasia, and intra-thoracic pelvic dilatation agreed with (Stahlmann 1990 and Schaefer et al., 1996). The result is also similar to that reported by (Gilfillan et al., 1984) in which about 4.7% of cases of congenital anomalies (hydrocephalus) were found in live-born babies exposed to ciprofloxacin during the first trimester of pregnancy. Diverticulum dilatation in the brain of fetuses might be attributed to the lack of placental transfusion of amino acid, arginine, metabolism in the fetus (Tuchmann, 1975) the neurotoxic effect of norfloxacin (Zhang et al., 2003), or some antibacterials that had a neurotoxic effect as levofloxacin and ciprofloxacin which easily cross the blood-brain barrier and compete with gamma-aminobutyric acid receptor (Akahane et al., 1993). Fluoroquinolones can block the cardiac potassium channel leading to cardiac arrhythmias and consequently cardiac enlargement (Kang et al., 2001). Pulmonary hypoplasia might be attributed to extensive distribution into the lung and achieved higher concentration malformation in fetuses exposed to ciprofloxacin during the period of organogenesis. Some fetal skeletal malformations were recorded such as impaired ossification of the skull, absence of sternebrae, absence of digit's bone of fore and hind limb, and absence of some metacarpal and metatarsal bone, reduction or absence of caudal vertebrae. This result agrees with that reported by many investigators (Kim et al., 2003 and Kim et al., 2005). Also, with the administration of ofloxacin to pregnant female rats and rabbits (Takayama et al., 1986), administration of levofloxacin to rats (Manson et al., 1982 and Watanabe et al., 1992), and administration of fluoroquinolones (DW-116) to the pregnant rats and rabbits, respectively (Kim et al., 2005, Hall et al., 2011). These results can be explained by the association of fluoroquinolones with a wide range of musculoskeletal complications that include not only tendons but also cartilage, bone, and muscle. [54], and that these effects are associated with irreversible bone damage and growth inhibition. These effects may be explained by the magnesium-chelating properties of these drugs, leading to a deficit of functionally available magnesium and, subsequently, to radical formation and irreversible connective tissue lesions (Stahlmann, 2003) also, Arora stated that bone and cartilage damage can be caused by fluoride accumulation with frequent administration of fluoroquinolones (Arora, 1994).

#### Conclusion

Through these results, it can be said that caution should be exercised when using ciprofloxacin during

pregnancy, and future studies should be conducted to assess its toxic effects on the mother and fetuses at low doses.

#### References

- 1- Susan, E., Andrade, Jerry, H., Gurwitz, Robert, L., Davis, K., Arnold Chan, Jonathan, A. Finkelstein, Kris Fortman, Heather McPhillips, Marsha, A. Raebel, Douglas Roblin, David H. Smith, Marianne Ulcickas Yood, Abraham, N. Morse and Richard Platt. Prescription drug use in pregnancy Am J Obstet Gynecol. 2004, 191(2), 398-407
- 2- Gilbert, N., Brien, V., Hultgren, S., Macones, G., Lewis, W. and Lewis AL. Urinary tract infection as a preventable cause of pregnancy complications: opportunities, challenges, and a global call to action. Glob Adv Health Med. 2013, 2, 59-69.
- 3- Nicolle, L., Asymptomatic bacteriuria: when to screen and when to treat. Infect Dis Clin North Am. 2003, 17, 367-94.
- 4- Matuszkiewicz-Rowińska, J., Małyżko, J. and Wieliczko, M. Urinary tract infections in pregnancy: old and new unresolved diagnostic and therapeutic problems. Arch Med Sci. 2015, 11, 67-77.
- 5- Schuid, A., Small, W. and Harris Arris, T. Cipro facts: fluoro and toxic reactions. Available from: <http://www.rense.com>.
- 6- Patrick G. L., in *An introduction to Medicinal Chemistry*, Oxford University Press, Oxford, United Kingdom, 2003, pp. 379-435.
- 7- Is ciprofloxacin safe to use in pregnancy? By net doctor.
- 8- Friedman, M. and Polifka, J., Teratogenic effects of drugs: a resource for clinicians (TERIS). Baltimore, Maryland: Johns Hopkins University Press, 2000, 149-95.
- 9- Aboubakr, M., Elbadawy, M., Soliman, A. and El-Hewaity, M. Embryotoxic and teratogenic effects of norfloxacin in pregnant female albino rats. Adv. Pharmacol. Sci. 2014, 924706
- 10- Siddiqui, M.A and Naqvi, S. Evaluation of the teratogenic potentials of ciprofloxacin in albino rat J. Morphol. Sci., 2010, 27, 1, 14-18
- 11- Hamida, H., Abd El-Wahab, E. and Eman, S. Fetal exposure to the antibiotic drug (Ciprofloxacin) in Albino rats. J Pharm. Chem. Pharmacol. 2018, 2, 1.
- 12- Matthews, M. and Kenyon, R. Four- versus five-day estrous cycles in rats: vaginal cycling and pregnancy. Physiology & Behaviour. 1984, 33, 65-67.
- 13- Fatemeh, Z., Rajab-Ali Sadrkhanlou<sup>1</sup>, Siamak S., Karim Mardani<sup>2</sup> and Abbas Ahmadi<sup>1</sup>, The effect of ciprofloxacin on sperm DNA damage, fertility potential and early embryonic development in NMRI mice, Veterinary Research Forum. 2012, 3, 2, 131 - 135



- 14- Reagan-Shaw, S., Nihal, M. and Ahmad N. Dose translation from animal to human studies revisited. *FASEB J.* 2007, 22, 659-661.
- 15- Manson, J.M., Zenick H. and Costlow, R.D. Teratology test methods for laboratory animals. In Hayes, A. W. (Ed), "Principals and Methods of Toxicology". (1982) Raven Press, New York. Pp. 141 – 18
- 16- Vancutsem, P. M., Babish, J. G. and Schwark, W. S. "The fluoroquinolone antimicrobials: structure, antimicrobial activity, pharmacokinetics, clinical use in domestic animals and toxicity," *The Cornell Veterinarian*, 1990 80, 2, 173–186.
- 17- Watanabe, T., Fujikawa, K., Harada, S., Ohura, K., Sasaki, T. and Takayama, S. Reproductive toxicity of the new quinolone antibacterial agent levofloxacin in rats and rabbits. *Arzneimittel- Forschung.* 1992, 42(3), 374–377.
- 18- Friedman, J. and Polifka, J. Teratogenic effects of drugs: a resource for clinicians (TERIS). Baltimore: Johns Hopkins University, 2000, 149-195.
- 19- Nahum, G.G., Uhl, K. Kennedy, DL. Antibiotic use in pregnancy and lactation: what is and is not known about teratogenic and toxic risks. *Obstet Gynecol.* 2006,107,1120-38.
- 20- antibiotics Comparative Biochemistry and Physiology Part C: Toxicology & Pharmacology , 237 , 2020, 108840
- 21- Schaefer, c., Amoura- Elefant, E., Vial, T. Ornoy, A. Gargbis, h., Rodrigez- Pinillia, E., Pexieder, T., Prapas, N. and Merlob, P. *Eur J Obstet Gynecol Reprod Biol.* 1996, 69 , 83.
- 22- Gerenutti, M.F. , Del Fioli, F. C. Prof. Dra. Marli Gerenutti, Av. Eugene Salerno and Sorocaba, SP. Reproductive performance of pregnant rats and embryotoxic effects of ciprofloxacin – Brazil Cep (ZIP code) – 18035-430, *Pharmazie.* 2006, 61, 79–80 .
- 23- Greenfield, M., Commonly used antibiotics in pregnancy. 2004,
- 24- Nahum, G., Uhl K and Kennedy, D. Antibiotic use in pregnancy and lactation: what is and is not known about teratogenic and toxic risks. *Obstet Gynecol.* 2006,107,1120-38.
- 25- Loebstein ,R. Addis, A. Ho, E. and et al. Pregnancy outcome following gestational exposure to fluoroquinolones: a multicenter prospective controlled study. *Antimicrob Agents Chemother.* 1998,42,6.
- 26- Loebstein, R. Lalkin, A. and Koren, G. Pharmacokinetic changes during pregnancy and their clinical relevance. *Clin Pharmacokinet* , 1997 33: 328–343.
- 27- Niebyl, J.R. Antibiotics and other anti-infective agents in pregnancy and lactation. *Am J Perinatol.* 2003, 20, 405–414.
- 28- Gian Maria Pacifici Placental transfer of antibiotics administered to the mother: A review
- 29- Chernoff, N., Rogers, J.M. and Kavlock, R.J. An overview of maternal toxicity and prenatal development: considerations for developmental toxicity hazard assessments. *Toxicology.* 1989. 59,111-125.
- 30- Cassano, A., Manganaro, A., Martin, T., Young D., Piclin, N., Pintore, M., Bigoni D. and Benfenati E. CAESAR models for developmental toxicity. *Chemistry Central Journal* ,2010, 4(Suppl 1),S4 ,29.
- 31- Chernoff, N., E. ,Rogers, M. ,Gage, and Francis. The relationship of maternal and fetal toxicity in developmental toxicology bioassays with notes on the biological significance of the "no observed adverse effect level". *REPRODUCTIVE TOXICOLOGY.* Elsevier Science Ltd, New York, NY2008,, 25(2),192-202.
- 32- Mares, R. E., Ellerbrock I. F., Canisso, P. J., Roady 1 , L. T., Rothrock, L., Zhong , P. Wilkins 1 , L. Dirikolu , F. S., Lima 1 and Honoroto 1, Diffusion of enrofloxacin to pregnancy fluids *Equine Veterinary Journal* and effects on foetal cartilage after intravenous administration to late pregnant November , 2018, 51(4).
- 33- Tuchmann-Duplessis, H. Drug effect on the fetus. ADIS press, New York, USA. (1975)
- 34- Carter A. M. , Evolution of placental function in mammals: the molecular basis of gas and nutrient transfer, hormone secretion, and immune responses. *Physiol. Rev.* 2012, 92, 1543–1576.
- 35- Takayama, S., Watanabe, T. and Akiyama ,Y. Reproductive toxicity of ofloxacin, *Arzneimittel- Forschung.* 1986,36, 1244–8.
- 36- Marchbanks, C.R. Drug-drug interactions with fluoroquinolones. *Pharmacotherapy.* 1993, 13 ( 2), 23S–8S.
- 37- Christ, W. Central nervous system toxicity of quinolones: human and animal findings. *J Antimicrob Chemother.* 1990, 26,219–25.
- 38- Pino ,A., Maura ,A., Villa, F. and Masciangelo, L. Evaluation of DNA damage exposure. *Mutat Res.* 1991,264,81–5.
- 39- Shakibaei ,M., Baumann-Wilschke, I., Rucker, M. and Stahlmann, R. Ultrastructural characterization of murine limb buds after in vitro exposure to grepafloxacin and other fluoroquinolones. *Arch Toxicol.* 2002,75,725–33.
- 40- Hummler, H. Richter ,W.F. and Hendrickx, A.G. Developmental toxicity of fleroxacin and comparative pharmacokinetics of four fluoroquinolones in the cynomolgus macaque (*Macaca fascicularis*). *Toxicol Appl Pharmacol.* 1993,122,34–45.
- 41- Watanabe, T., Fujikawa, K., Harada, S. Ohura ,K. Sasaki, T. and Takayama S. Reproductive toxicity of the new quinolone antibacterial agent levofloxacin in rats and rabbits. *Arzneimittelforschung* 1992,43,374–7.

- 42- Al-Snafi, A. E. and Shafik, N.A. Embryotoxicity of Norfloxacin in mice The Medical Journal of Tikrit University.1997, 3,200-203.
- 43-Jeffry, C. W., Soo, S. K., James, D., Lisa, A., Nicholas, A., Lee, T. and Sharon, D. R. Inhibition of Clinically Relevant mutant variants of HIV-I by quinazolinone Non-Nucleoside reverse transcriptase inhibitors. *J. Med. Chem.* 2000,43(10), 2019-2030.
- 44- Gürbay, A., Gonthier, B., Signorini-Allibe, N. and et al. Ciprofloxacin-induced DNA damage in primary culture of rat astrocytes and protection by vitamin E. *Neurotoxicol.* 2006,27,6-10.
- 45- Arriaga, Alba, M., Rivera Sanchez, R., Parra Cervantes, G., and et al. Antimutagenesis of b-carotene to mutations induced by quinolone on *Salmonella typhimurium*. *Arch Med Res.* 2000,31,156-61.
- 46-Minta, M. Wilk, I. and Zmudzki, J. Inhibition of cell proliferation by quinolones in micromass cultures of rat embryonic limb bud and midbrain cells. *Toxicol in Vitro.* 2005., 19, 915-919.
- 47-Stahlmann, R. Safety profile of the quinolones. *J Antimicrob Chemother.* 1990, 26(suppl D),31-44.
- 48-Gilfillan, E.C., Pelak, B.A., Bland, J.A., Malatesta, P.F. and Gadebusch, H.H. Pharmacokinetic Studies of Norfloxacin in Laboratory Animals *Chemotherapy*, 1984, 30, 288-296.
- 49- Zhang, R. Wang, Y. M. Chen, B. Y. and Cheng, N. N. "Neurotoxicity and toxicokinetics of norfloxacin in conscious rats," *Acta Pharmacologica Sinica.* 2003,24 (6), 605-623.
- 50- Akahane, M., Kato, and Takayama, S. "Involvement of inhibitory and excitatory neurotransmitters in levofloxacin- and ciprofloxacin-induced convulsions in mice," *Antimicrobial Agents and Chemotherapy.* 1993, 37(9), 1764-1770
- 51- Kang, L., Wang, X., Chen, D. J., Triggler, and Rampe, D. "Interactions of a series of fluoroquinolone antibacterial drugs with the human cardiac K<sup>+</sup> channel HERG," *Molecular Pharmacology.* 2001, 59 (1), 122-126.
- 52- Kim, J.G., DH, Shin, SH. and et al. Developmental toxicity evaluation of the new fluoroquinolones antibacterial DW-116 in rats. *Teratogenesis Carcinogenesis Mutagenesis.* 2003,1,123-36.
- 53-. Kim, J.G, Shin, DH, Kim, S.H. and et al. Developmental toxicity assessment of the new fluoroquinolone antibacterial DW-116 in rabbits. *J Appl. Toxicol.* 2005,25,52-9.
- 54- Hall, M. M., Finnoff, J. T. and Smith, J. "Musculoskeletal complications of fluoroquinolones: guidelines and precautions for usage in the athletic population," *Journal of Injury, Function and Rehabilitation.* 2011, 3(2), 132-142.
- 55-R. Stahlmann, "Children as a special population at risk-quinolones as an example for xenobiotics exhibiting skeletal toxicity," *Archives of Toxicology*, 2003, 77(1), 7-11.
- 56- Arora, N. K. "Are fluoroquinolones safe in children?" *Indian Journal of Pediatrics.* 1994,61(6), 601-603.

#### التأثير المشوه لعقار سيبروفلوكساسين في أجنة الجرذان البيضاء

زينب مختار عبد السميع & نورا الزاعل  
**الملخص** الهدف من هذه الدراسة هو تقييم مخاطر عقار سيبروفلوكساسين على نمو أجنة الجرذان البيضاء أثناء الحمل. تم تعريض الجرذان الحوامل عن طريق الفم إلى 206 مجم / كجم من سيبروفلوكساسين يوميًا في الأيام من 5 إلى 20 من الحمل قتلت الحيوانات في اليوم العشرين من الحمل لفحص الأجنة. سبب سيبروفلوكساسين ارتفاعًا ملحوظًا في النسب المئوية لمواقع الامتصاص المتأخر والأجنة الميتة مقارنة بمجموعة التحكم وكذلك انخفاض متوسط أوزان الأجنة بشكل كبير. تم الكشف عن تشوهات الأحشاء في شكل اتساع البطين الثالث للمخ، تضخم القلب، ضمور الرئة، اتساع الحوض الكلوي. أظهر فحص الهيكل العظمي اتساع اليافوخ، وتضخم غير مكتمل للعظام الجدارية وبين الجدارية، وتضخم غير كامل وغياب للقص، وانخفاض في العدد أو حتى الغياب التام لعظام المشط، والفقرات العجزية و / أو الذيلية. تشير النتائج إلى أن سيبروفلوكساسين له تأثير مشوه عند الجرعات المنخفضة. لذلك، من الضروري إجراء مزيد من الدراسات لتقييم سلامته أثناء الحمل.  
 الكلمات المفتاحية: عقار سيبروفلوكساسين، التشوهات الخلقية، الأحشاء، الهيكل، جرذان.