



## All In One Technique versus Lichtenstein Technique for Treatment of Inguinal Hernia in Zagazig University Hospitals

Waleed A. Abd-Elhady, Bassem Sieda, Ahmed M. Sallam, Wael M. Abdallah

General Surgery department, Faculty of Medicine, Zagazig University

**Abstract: Background/purpose:** Lichtenstein mesh repair is the most common procedure used by surgeons for management of inguinal hernia due to its low recurrence rate and complications. However, post-operative complications like chronic groin pain, foreign body sensation, loss of sensation obtained a great attention. Successful inguinal hernia repair measured by minimizing the post-operative complication and maximizing the patient satisfaction. **Guttadauro et al.** described a new open repair procedure called All In One technique for management of primary inguinal hernia in adult to decrease the incidence of chronic post-operative pain and foreign body sensation, leading to improving patient's comfort [1]. **The objectives of this study** To conduct a comparative study between the All In One technique and the Lichtenstein technique in order to evaluate the advantages and complications of each for treatment of inguinal hernia. **Methods:** This study was carried on 60 patients with primary inguinal hernia in the department of General Surgery, Zagazig University Hospitals during the period from August 2017 to January 2019. The patients divided into two groups : Group (A): was treated with All In One technique. Group (B): was treated with Lichtenstein technique. **Results:** the age of the studied patients in group (A) ranging from 22-70 years old with mean  $46.26 \pm 13.22$  and in group (B) ranging from 31-70 years old with mean  $48.9 \pm 11.95$  and most of the studied patients are in the 4th & 5th decade. All In One technique has significantly less loss of sensation over the groin, groin pain at 1,3,6 months and foreign body sensation over the groin . there is no significant difference in both groups as regard types of hernia ,operative time, Post-operative complications, Return to normal activity and Recurrence rate. **Conclusions:** the All In One technique procedure is considered as a good approach for the surgical treatment of primary inguinal hernia with less post-operative complications and less postoperative neuralgia, chronic groin pain, sensation of foreign body and loss of sensation with better patient compliance and satisfaction. It helps the less experienced surgeon to avoid pitfalls in dealing with nerves. [Waleed A. Abd-Elhady, Bassem Sieda, Ahmed M. Sallam, Wael M. Abdallah. **All In One Technique versus Lichtenstein Technique for Treatment of Inguinal Hernia in Zagazig University Hospitalst.** *Biomedicine and Nursing* 2021;7(4):67-75]. ISSN 2379-8211 (print); ISSN 2379-8203 (online). <http://www.nbmedicine.org>. 9. doi:[10.7537/marsbnj070421.09](https://doi.org/10.7537/marsbnj070421.09).

**Keywords:** Technique; Lichtenstein; Treatment; Inguinal Hernia; Zagazig University; Hospital

### INTRODUCTION

Inguinal hernia is a bulge or protrusion of the abdominal cavity contents or the pre-peritoneal fat through the inguinal canal. It is presented with swelling or discomfort in the groin that is observed when the intra-abdominal pressure rises during coughing, straining or bowel movement [2].

Lichtenstein mesh repair is the most common procedure used by surgeons for treatment of inguinal hernia due to its low recurrence rate and complications. However, post-operative complications like chronic groin pain, foreign body sensation, loss of sensation obtained a great attention [3].

Post-operative complications especially chronic groin pain is now known as one of the major

complication related to inguinal hernia repair because it affects the patient satisfaction and quality of life [4].

Successful inguinal hernia repair measured by minimizing the post-operative complication and maximizing the patient satisfaction [5].

**Guttadauro et al.** described a new open repair procedure called All In One mesh hernioplasty for management of primary inguinal hernia in adult, According to the described procedure a specific shaped mesh was placed on the floor of the inguinal canal to strengthen it and enveloped by a fibro-cremasteric sheath (the cremastic muscle and the external spermatic fascia) avoiding contact with neural structures to decrease the incidence of chronic post-operative pain and foreign body sensation, leading to improving patient's comfort [1].

**Aim of the work:** To conduct a comparative study between the All In One technique and the Lichtenstein technique in order to evaluate the advantages and complications of each for treatment of inguinal hernia in Zagazig University Hospitals.

**PATIENTS AND METHODS:** Technical Design:

a) **Type of study:**

This is prospective randomized study was carried out in the department of General Surgery, Zagazig University Hospitals during the period from August 2017 to January 2019.

b) **Sample size:**

This study was carried out on Sixty adult males patients diagnosed with primary inguinal hernia divided into two groups :

- **Group (A):** inguinal hernia was treated with All In One technique.
- **Group (B):** inguinal hernia was treated with Lichtenstein technique.

c) **Inclusion criteria:**

- Adult males, age above 18 years old presented with primary inguinal hernia without complications (irreducible or strangulated).

d) **Exclusion criteria:**

- Patients presented with recurrent or complicated inguinal hernia e.g., irreducible or strangulated.
- Patients <18 years.
- Not associated with other pathological conditions e.g. hydrocele.
  - Patients who refused the procedures.

Operational design:

All our patient are subjected to full history taking, clinical examination and investigations.

- 1) **Full history taking:** Name, age, occupation, symptoms, duration of symptoms, past medical & surgical history and smoking.

2)

**Clinical examination:**

- General clinical examination.
- Vital data: pulse, blood pressure, temperature and respiratory rate.

- Local examination of the swelling in the inguinal region and the scrotum.
- 

**3) Investigations:**

- **Routine pre operative investifation** as CBC, coagulation profile ( PT,PTT&INR), Liver and Kidney finction tests , random blood sugar and ECG.
- **Imaging studies** as **Pelviabdominal ultrasonography** and Inguino-scrotal superficial probe ultra sound.

**4) Technique:**

-Written informed consent was obtained from the patients.

-All patients were given prophylactic 1 gm. third generation cephalosporin intravenous over 30 minutes before the operation.

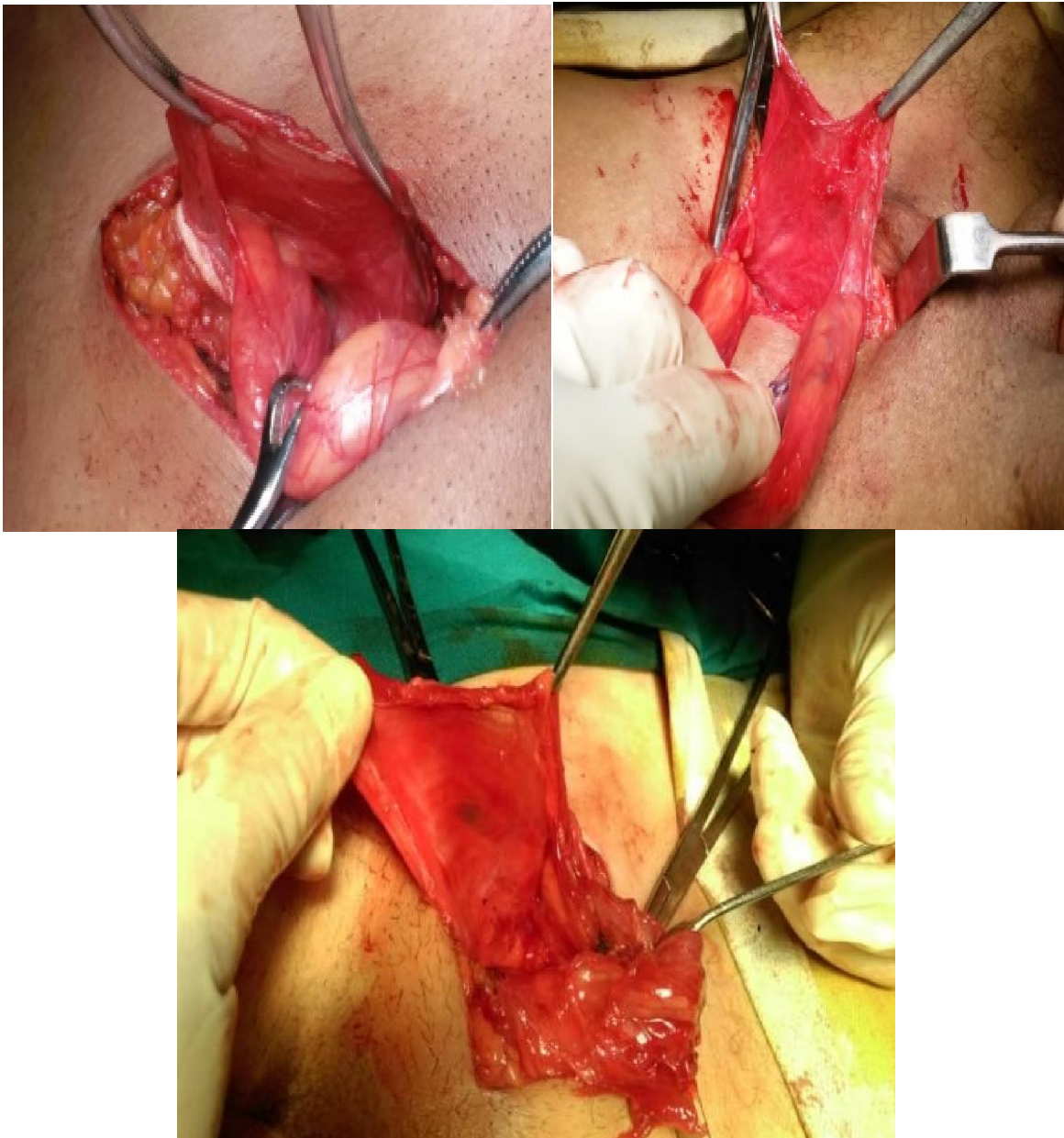
-Anesthesia was either spinal or general.

Operative data were recorded including: type of hernia; technique; duration of surgery and operative difficulties or complications.

**All In One technique**

An oblique incision 3cm above and parallel to the medial two third of the inguinal ligament or transverse incision along the inguinal crease is made. The subcutaneous tissues are dissected, dividing the external oblique aponeurosis in the direction of its fibers. Reflection of the external oblique aponeurosis and dissection of the aponeurosis from the cord until the inguinal ligament is reached.

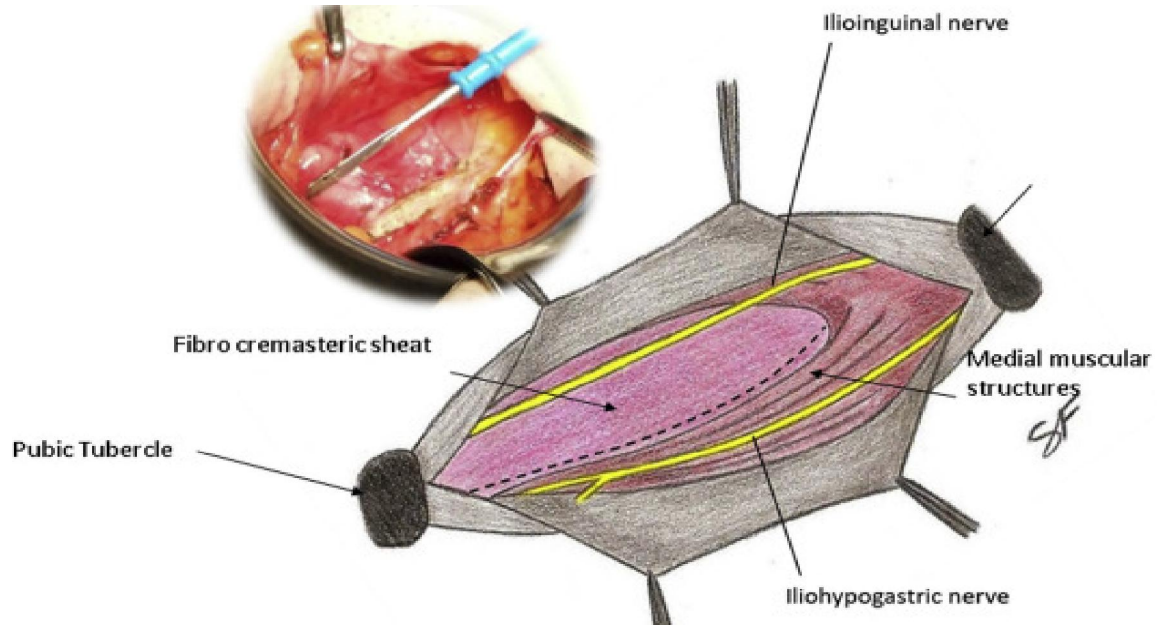
Identification of the spermatic cord, making a medial longitudinal incision of the fibro cremastic sheath by the diathermy coagulator parallel to the cord and close to the arched lower fibers of the internal oblique muscle. The margins of the fibro cremastic sheath are held back gently by forceps and the sheath is gently dissected from the cord by blunt dissection and exposed from the medial incision till the inguinal ligament. This fibro cremastic sheath will cover the mesh later.



**Fig. (1):** The fibro-cremasteric sheath.

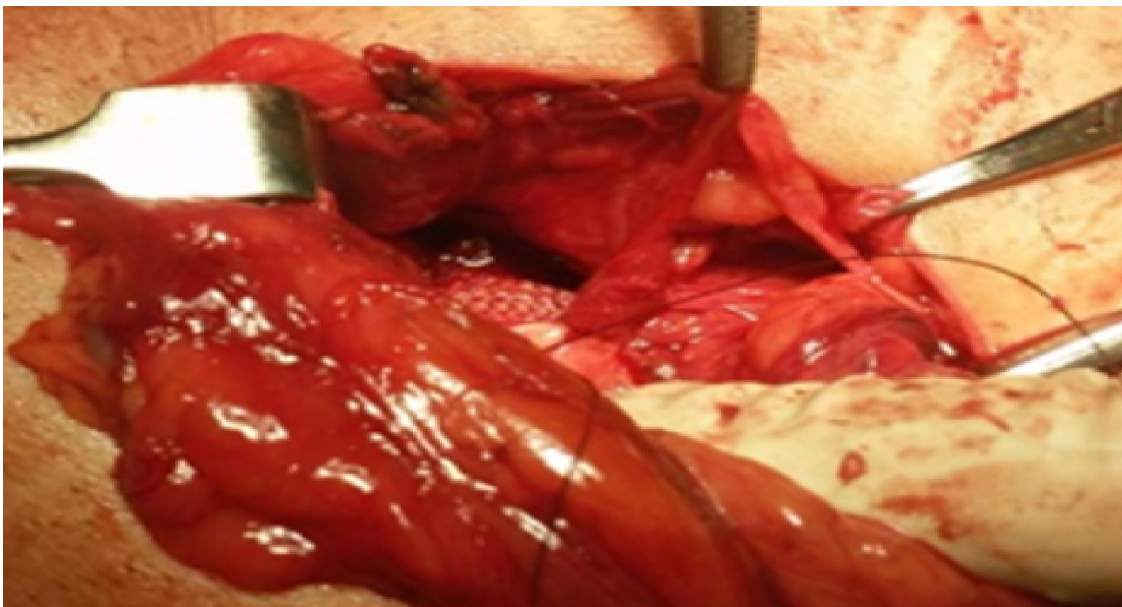
Dissection and excision of the hernial sac from the cord in case of indirect inguinal hernia, reduction of direct sac in case of direct hernia and plication of fascia transversalis, narrowing the deep inguinal ring by a few stitches if the deep ring is wide.

Reinforcement of the posterior wall of the inguinal canal using a particular shape of mesh. The mesh consists of 3 parts connected to each other: part A is circular in shape 3.5x3.5 cm with a central hole 1.5 cm in diameter to surround the spermatic cord at the internal inguinal ring; part B is a small rectangular shape 0.5x0.5 cm connecting part A with part C; part C is trapezoidal in shape designed to support the floor of the inguinal canal. The mesh will be covered by a fibro-cremasteric sheath (the cremasteric muscle itself and the external-spermatic fascia).

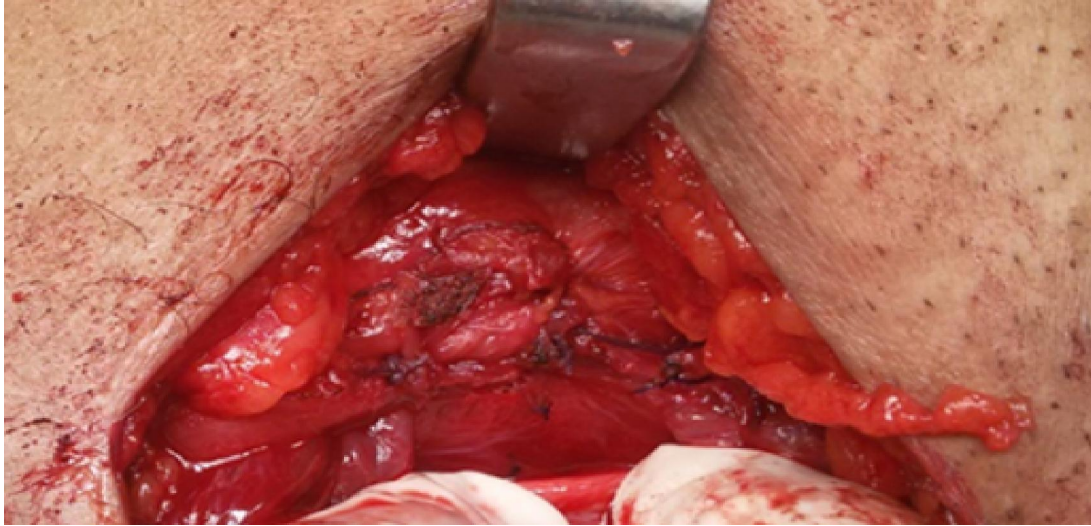


**Fig. (2):** The mesh and the fibro-cremasteric incision (*Guttadauro et al., 2017*).

The medial margin of the fibro cremasteric sheath is transported below the cord to cover the mesh with fixation of the fibro cremasteric sheath to the medial muscular structures with absorbable sutures.



**Fig. (3):** Suturing the fibro cremasteric sheath to the medial muscular structures



**Fig. (4):** The fibrocremasteric sheath covers the mesh.

No need for stitching the mesh to adjacent structures as it will stay in place enveloped by the fibrocremasteric sheath. The cord returned back to its normal position and the fibrocremasteric sheath will prevent adhesion between the cord element and the prosthetic mesh. Also the fibrocremasteric sheaths acts like a barrier between the nerves and the mesh. The external oblique aponeurosis is closed with absorbable sutures.

#### **Post-operative care and follow up...**

Patients were rested in bed post operatively, they were encouraged to walk, move and start normal light activity. Post-operative pain at time of recovery from anesthesia was controlled by intramuscular NSAIDs analgesic, and then was controlled according to the patient requirement.

The post-operative data were recorded about:

- Surgical site infection, Seroma, hematoma, scrotal oedema, testicular atrophy, Loss of sensation over the groin, foreign body sensation, Post-operative groin pain and chronic groin pain ,Return to normal activity and Recurrence. Post-operative pain intensity was evaluated through the visual analogue scale (VAS) and Japanese Questionnaire.

## **RESULTS**

**Table (1) : Age and sex distribution in both studied groups:**

| Age in years    | Group (A) All IN ONE |      | Group (B) Lichtenstein |      |
|-----------------|----------------------|------|------------------------|------|
|                 | No.                  | %    | No.                    | %    |
| Up to 25 years  | 2                    | 6.7  | 0                      | 0    |
| 26-35           | 6                    | 20   | 6                      | 20   |
| 36-45           | 6                    | 20   | 6                      | 20   |
| 46-55           | 10                   | 33.3 | 7                      | 23.3 |
| >55             | 6                    | 20   | 11                     | 36.7 |
| <b>Range</b>    | (22-70) years        |      | (31-70) years          |      |
| <b>Mean ±SD</b> | 46.26±13.22          |      | 48.9±11.95             |      |

This table shows that there is no significant difference as regard both age or sex.

**Table (2) : Types of hernia in both studied groups:**

| Type of hernia | Group (A) All IN ONE |       | Lichtenstein |       | P value     |
|----------------|----------------------|-------|--------------|-------|-------------|
|                | No.                  | %     | No.          | %     |             |
| <b>ID</b>      | 22                   | 73.3  | 21           | 70.0  | P=0.8 (NS)  |
| <b>D</b>       | 8                    | 26.7  | 9            | 30.0  | P=0.75 (NS) |
| <b>Total</b>   | 30                   | 100.0 | 30           | 100.0 |             |

This table shows that hernia type in most cases was indirect inguinal hernia and there no significant difference as regard types of hernia in both groups.

**Table (3) : Operative time in both groups :**

|                       | Group (A) All IN ONE | Lichtenstein | P-value   | T test |
|-----------------------|----------------------|--------------|-----------|--------|
| <b>Operative time</b> | 33 - 45 min          | 33 – 56 min  | 0.34 (NS) | t=0.91 |
| <b>Mean ±SD</b>       | 40.4±3.28            | 41.56±5.74   |           |        |

This table shows that there is no significant difference as regard operative time in both groups.

**Table (4) : Post-operative complications**

|                                | All In One |      | Lichtenstein |      | P value   |
|--------------------------------|------------|------|--------------|------|-----------|
|                                | No.        | %    | No.          | %    |           |
| <b>Surgical site infection</b> | 0          | 0.0  | 0            | 0.0  | NS        |
| <b>Seroma</b>                  | 1          | 3.33 | 2            | 6.66 | 0.56 (NS) |
| <b>Hematoma</b>                | 0          | 0.0  | 0            | 0.0  | NS        |
| <b>Scrotal oedema</b>          | 1          | 3.33 | 1            | 3.33 | NS        |
| <b>Testicular atrophy</b>      | 0          | 0.0  | 0            | 0.0  | NS        |

This table shows that there is no significant difference as regard Post-operative complications in both groups.

**Table (5) : loss of sensation over the groin.**

| Loss of sensation | All In One |       | Lichtenstein |       | P value    | Chi-Square |
|-------------------|------------|-------|--------------|-------|------------|------------|
|                   | number     | %     | number       | %     |            |            |
| <b>Present</b>    | 0          | 0.0   | 11           | 36.66 | 0.0008 (S) | 11.129     |
| <b>Absent</b>     | 30         | 100.0 | 19           | 63.33 |            |            |

This table shows that **Group (A) All IN ONE** (no cases 0.0%) has significantly less loss of sensation over the groin than **Group (B) Lichtenstein** (11 cases 36.66%).

**Table (6) :** foreign body sensation.

| FOREIGN BODY SENSATION | All In One |       | Lichtenstein |      | P value   | Chi-Square |
|------------------------|------------|-------|--------------|------|-----------|------------|
|                        | Number     | %     | Number       | %    |           |            |
| Present                | 0          | 0.0   | 9            | 30.0 | 0.0038(S) | 8.366      |
| Absent                 | 30         | 100.0 | 21           | 70.0 |           |            |

This table shows that **Group (A) All IN ONE** (no cases 0.0%) has significantly less foreign body sensation over the groin than **Group (B) Lichtenstein** (9 cases 30.0%).

**Table (7) :** Number of patients with groin pain.

|                     | All In One |       | Lichtenstein |       | P value    | Chi-Squared |
|---------------------|------------|-------|--------------|-------|------------|-------------|
|                     | No.        | %     | No.          | %     |            |             |
| 1 <sup>st</sup> day | 30         | 100.0 | 30           | 100.0 | NS         |             |
| 3 <sup>rd</sup> day | 20         | 66.66 | 22           | 73.33 | 0.079 (NS) | 0.079       |
| 1 week              | 12         | 40.00 | 17           | 56.66 | 0.301 (NS) | 1.067       |
| 1 month             | 0          | 0.0   | 11           | 36.66 | 0.0008 (S) | 11.129      |
| 3 month             | 0          | 0.0   | 11           | 36.66 | 0.0008 (S) | 11.129      |
| 6 month             | 0          | 0.0   | 11           | 36.66 | 0.0008 (S) | 11.129      |

This table shows that **Group (A) All IN ONE** (no cases 0.0%) has significantly less groin pain than **Group (B) Lichtenstein** (11 cases 36.66%) at 1,3,6 months.

**Table (20):** Number of patients with chronic groin pain.

| Chronic groin pain | All In One |       | Lichtenstein |       | P value   | Chi-Square |
|--------------------|------------|-------|--------------|-------|-----------|------------|
|                    | Number     | %     | Number       | %     |           |            |
| Present            | 0          | 0.0   | 11           | 36.66 | 0.0008(S) | 11.129     |
| Absent             | 30         | 100.0 | 19           | 63.33 |           |            |

This table shows that **Group (A) All IN ONE** (no cases 0.0%) has significantly less chronic groin pain than **Group (B) Lichtenstein** (11 cases 36.66%) .

**Table (21):** Return to normal activity.

| Return to normal activity | All IN ONE     | Lichtenstein   | P value    |
|---------------------------|----------------|----------------|------------|
| Min-max(days)             | 6-12           | 6-13           | 0.784 (NS) |
| Mean $\pm$ SD             | 8.8 $\pm$ 1.71 | 8.8 $\pm$ 1.97 |            |

This table shows that there is no significant difference as regard Return to normal activity in both groups.

**Table (22):** Recurrence.

| RECURRENCES | All In One |       | Lichtenstein |       | P value |
|-------------|------------|-------|--------------|-------|---------|
|             | Number     | %     | Number       | %     |         |
| Present     | 0          | 0.0   | 0            | 0.0   | NS      |
| Absent      | 30         | 100.0 | 30           | 100.0 |         |

This table shows that there is no significant difference as regard Recurrence in both groups

## DISCUSSION

Inguinal hernia repair is one of the most common surgical procedures implemented in the field of general surgery. The ideal success of this surgery depends on the surgeon's understanding of the anatomy and physiology of the groin and how the surgeon reacts with the tissues and the prosthetic mesh [5].

"A major goal of modern surgery is to achieve better outcomes with less invasive techniques while sparing functional tissue and reducing pain and long-term complications. Pain and restriction of daily activity rank high among patient concerns" [1].

In this study, we compare between the Lichtenstein technique and All In One technique to identify the better of the two methods and to compare effectiveness, complications, safety and patient satisfaction between the two techniques. This is a comparative study consists of 60 patients, with 30 patient in Lichtenstein technique group and 30 patients with All In One technique group undergoing mesh repair of primary inguinal hernia conducted in ZUH.

As regarded age, For Lichtenstein group the Age of the patient in other study was ranged from 18-70 years with a mean age of 50 years for Lichtenstein technique [6]. The age of patient ranged from 22-81 years and the mean age was 49 years for Lichtenstein hernioplasty [7]. In this study, as regarded age, for All In One mesh hernioplasty the age of the patients varied from 22 to 70 years While for Lichtenstein hernioplasty the age of the patients varied from 31 to 70 years.

In this study, hernia type in most cases was indirect inguinal hernia, 22 cases for All In One mesh hernioplasty and 21 cases for Lichtenstein hernioplasty. In other study it was reported that most of cases were indirect inguinal hernia [8].

In this study, as regard Operative time, no significant difference in both groups. The Mean & Standard Deviation for All in one mesh hernioplasty and Lichtenstein hernioplasty was (40.4±3.28 minutes, 41.56±5.74 minutes) respectively. other study Reported that the mean operative time was 25 min for All In One technique this difference in the operation time may be due to the learning curve of the procedure. [1].

In this study, as regard to post operative complication, no cases were presented with wound infection in both groups. another study reported that no cases with surgical site infection were present in his study [1]. Other study reported that the incidence of surgical site infection for Lichtenstein hernioplasty was 0.9% [9].

One patient in the All In One technique group had seroma (3%). Two patients (6%) in the Lichtenstein technique had seroma. None of both groups had hematoma. One patient (3%) who underwent All In

One technique had scrotal edema. One patient underwent the Lichtenstein's technique group had scrotal edema (3%). None of patients in both techniques had testicular atrophy. Other study reported that no cases with seroma, hematoma, scrotal oedema or testicular atrophy were present in All In One technique [1]. It was reported in other study that Testicular atrophy is rare with a rate of 0.5% and this happened as a result of chronic ischemia of the testis due to affection of its arterial blood supply [10]. It was reported that in other study Wound hematoma or scrotal hematoma occurs with a rate of 2-3% as a result of delayed bleeding due to traumatic injury of the vessels [11].

In this study, 11 patients (36.6%) had loss of sensation over the groin were noted for Lichtenstein technique and non for All In One technique. 9 patients (30%) complained of foreign body sensation for Lichtenstein technique compared to All In One technique where there were no such incidences. other study reported that no cases with loss of sensation over the groin or foreign body sensation were present in All In One technique. [1].

The incidence of chronic groin pain (lasts more than 3 months postoperatively) after Lichtenstein hernioplasty varies from 25:43%, this high incidence is probably caused by nerve entrapment syndrome secondary to excessive fibrosis around the mesh [12,13]. Other study reported that no cases with chronic groin pain were present in All In One technique in his study [1].

In the present study, we observed there is a statistically significant difference in loss of sensation over the groin, foreign body sensation and chronic groin pain between the two techniques. other study explained that his technique has a less amount of prosthetic materials and stitches because the mesh is specific in shape and not needed to be fixed to the surrounding muscular and aponeurotic structure by sutures and placed under the coverage of a fibro cremastic sheath where no contact with muscles or nerves occurs, all this will decrease the incidence of developing a chronic pain and sensation of foreign body and increasing patient's satisfaction [1].

In this study, all patients were discharged within 24 hours of post-operative period.

There is no significant value of the rate of return to normal activity between both techniques.

As regard to recurrence, there were no recurrences in both the groups in this study during the follow up period but this may need a long term follow up for better evaluation.

As compared to previous studies of inguinal hernia mesh repair, in our study, minor complications like wound seroma and scrotal edema were encountered in



a very few cases. These minor complications were managed successfully or resolved spontaneously. Other complications like surgical site infection, hematoma and testicular atrophy did not occur in this study.

## CONCLUSIONS

The All In One technique procedure is considered as a good approach for the surgical treatment of primary inguinal hernia with less post-operative complications and less postoperative neuralgia, chronic groin pain, sensation of foreign body and loss of sensation with better patient compliance and satisfaction. It helps the less experienced surgeon to avoid pitfalls in dealing with nerves.

## REFERENCES

- [1]. **Guttadauro A, Maternini Matteo, Frassani Silvia, et al. (2017)** “All-in-one mesh” hernioplasty: A new procedure for primary inguinal hernia open repair’, *Asian Journal of Surgery*. Elsevier Taiwan LLC, 41(5), pp. 473–479. doi: 10.1016/j.asjsur.2017.07.003.
- [2]. **Fitzgibbons RJ and Forse RA (2015)** ‘Groin Hernias in Adults’, *New England Journal of Medicine*, 372(8), pp. 756–763. doi: 10.1056/NEJMcp1404068.
- [3]. **Simons MP, Aufenacker T, Bay-Nielsen M, et al. (2009)** European Hernia Society guidelines on the treatment of inguinal hernia in adult patients, *Hernia*. doi: 10.1007/s10029-009-0529-7.
- [4]. **Leandro MP, Renato M DM, DA-SILVA, J, et al. (2017)** ‘comparative study of postoperative pain between the lichtenstein and laparoscopy surgical techniques for the treatment of unilateral primary inguinal hernia’, 30(3), pp. 173–174. doi: 10.1590/0102-6720201700030003.
- [5]. **Singh RR, Kumar GA, Singh Shah Avreen, et al. (2016)** ‘A study about inguinal hernia mesh repairs: plug and patch versus lichtenstein mesh repair technique’, *International Surgery Journal* Singh RR et al. *Int Surg J*, 3(4), pp. 1967–1974. doi: 10.18203/2349-2902.isj20163562.
- [6]. **Neogi, P., Gupta, V. and Tripathi, N. (2017)** ‘A comparative study of outcomes of Lichtenstein repair and Desarda tissue repair in patients of inguinal hernia’, *International Surgery Journal*, 4(8), p. 2693. doi: 10.18203/2349-2902.isj20173407.
- [7]. **KW M, Cummings B and Doolas A (2003)** ‘The millikan modified mesh-plug hernioplasty’, *Archives of Surgery*, 138(5), pp. 525–530. Available at: <http://dx.doi.org/10.1001/archsurg.138.5.525>.
- [8]. **Di Marzo F (2017)** ‘Inguinal Hernia and Other Types of Hernia: Diagnostic and Therapeutic Approach’, in Zini, R., Volpi, P., and Bisciotti, G. N. (eds) *Groin Pain Syndrome: A Multidisciplinary Guide to Diagnosis and Treatment*. Cham: Springer International Publishing, pp. 89–93. doi: 10.1007/978-3-319-41624-3\_10.
- [9]. **Nienhuijs, S. W, Van Oort I, Keemers-Gels ME, et al. (2005)** ‘Randomized clinical trial comparing the Prolene?? Hernia System, mesh plug repair and Lichtenstein method for open inguinal hernia repair’, *British Journal of Surgery*, 92(1), pp. 33–38. doi: 10.1002/bjs.4702.
- [10]. **Moore J. B. and Hasenboehler E. A. (2007)** ‘Orchiectomy as a result of ischemic orchitis after laparoscopic inguinal hernia repair: case report of a rare complication’, *Patient Safety in Surgery*, 1(1), p. 3. doi: 10.1186/1754-9493-1-3.
- [11]. **Lipskar A. M. and Reiner M. A. (2013)** ‘The SAGES Manual of Hernia Repair’. doi: 10.1007/978-1-4614-4824-2.
- [12]. **Klinge, U., Fiebeler, A. and Tur, M. K. (2010)** ‘Postoperative CRPS in inguinal hernia patients’, *Hernia Repair Sequelae*, pp. 213–219. doi: 10.1007/978-3-642-11541-7\_28.
- [13]. **Alfieri S, Amid P K, Campanelli G, et al. (2011)** ‘International guidelines for prevention and management of post-operative chronic pain following inguinal hernia surgery’, *Hernia*, 15(3), pp. 239–249. doi: 10.1007/s10029-011-0798-9.

3/3/2021