



Surgical Management of Craniocervical Junction Lesions, 35 Case Series

Ahmed Samir Elshikhali, MD., Esam Abd El Hay Mokbel, Ashraf Mohamed Farid and Magdy Abdel Aziz Elmahallawy

Department of Neurosurgery, Faculty of Medicine, Tanta University, Egypt
ahmed.elsheikh@med.tanta.edu.eg

Abstract: Purpose: Study surgical techniques used in management of CCJ lesions either: Anterior, Posterior and Posterolateral approach with attention to their relative effect on the outcome. **Patients and Methods:** Prospective case series, 35 patients with different pathologies, neoplastic and non-neoplastic lesions treated by either posterior, anterior, combined approach or far lateral approach. Complete clinical and radiological study including Plain radiographs and CT and MRI cervical spine were done in all cases. **Results:** 35 cases with different pathologies, the mean age: Mean \pm SD = 51.23 \pm 20.24 and male: female ratio is (28.6%: 71.4%). 5 neoplastic Cases with different types and 30 Cases of Non-Neoplastic origin. Post approach was the main approach used in 33 Cases, anterior approach in 3 cases and far lateral approach was used in One case. We had mild hypoglossal nerve dysfunction in one case, Failure of fusion and redo surgery in 2 cases and wound infection in one case. **Conclusion:-** Posterior approach is safe and covers a wide range of management for most of the CSJ lesions, for either decompression or tumors posteriorly or poster-laterally located or fusion for instability cases with minimal side effects.- Anterior and far lateral approach is less popular with limited indications.

[Ahmed Samir Elshikhali, Esam Abd El Hay Mokbel, Ashraf Mohamed Farid and Magdy Abdel Aziz Elmahallawy. **Surgical Management of Craniocervical Junction Lesions, 35 Case Series.** *N Y Sci J* 2020;13(2):1-17]. ISSN 1554-0200 (print); ISSN 2375-723X (online). <http://www.sciencepub.net/newyork>. 1. doi:[10.7537/marsnys130220.01](https://doi.org/10.7537/marsnys130220.01).

Keywords: Surgical; Management; Craniocervical; Junction; Lesions; Case; Series

1. Introduction

The craniocervical junction acts as a transitional zone between the cranial base and the upper cervical spine. A wide variety of lesions can affect the structures making up the CCJ. An understanding of the pathogenesis of these lesions in the context of the various structures affected is needed before proceeding with a therapeutic regimen. Lesions are generally classified as congenital, developmental, or acquired. [1]

Abnormalities at the CCJ can present with a wide range of signs and symptoms. These can include pain, paresthesias, motor weakness and gait disturbance caused by myelopathy, brain stem, cranial nerve, cervical nerve root dysfunction, and vascular insufficiency with segmental ischemia. [2]

All surgical approaches and stabilization techniques are limited by the complexity of this region, when evaluating the patient with a CCJ lesion, it is important to assess the site of maximum compression, to determine whether the lesion is reducible or not, and to determine whether the CCJ is stable or unstable. The CCJ may be unstable as a result of the destruction of osseous and ligamentous structures by the underlying pathologic process or

became unstable after surgical procedures. When CCJ malalignments are reducible, they must be considered unstable and fusion is always required. Based on these observations, a relatively straightforward treatment algorithm can be applied to determine the best management strategy for each patient. From this point, the selection of an anterior versus posterior surgical approach for decompression and stabilization is straightforward.[3]

The anterior surgical approaches are reserved for ventrally or ventrolaterally placed lesions that require resection and for decompression of mechanical lesions that cannot be reduced with traction or manipulation of the cervical spine. Lesions located ventral to the brain stem and spinal cord can be addressed through one of several anterior surgical approaches. Both the transoral transpharyngeal and high anterior cervical retropharyngeal approaches.[4]

A posterior decompression can be easily performed if dorsal compression from an irreducible malalignment or a dorsally located lesion is present. In most cases posterior approaches are used to stabilize the occipital-cervical junction if no anterior compression exists, after reduction of a malalignment

associated with anterior compression, or as an adjunct to an anterior, decompressive procedure. Some fixed anterior subluxations require laminectomy for adequate posterior neural decompression.[1]

Seeger was the first to describe a dorsolateral approach to the vertebrobasilar junction and to use the term “transcondylar” in the present context. Traditionally, the midline posterior approach was used to expose most intradural lesions located lateral or posterior to the neuraxis at the cervicomedullary junction. Being associated with significant disadvantages, the direct transoral approach to intradural pathology of the foramen magnum region has not gained wide acceptance. Instead, multiple variations of the suboccipital approach were elaborated and published in the 1980s and early 1990s. George and Laurian advocated the lateral enlargement of the usual posterior opening. This exposure requires control of the vertebral artery and sigmoid sinus. For further enlargement, medial transposition of the vertebral artery and transection of the sigmoid sinus with inferior petrosal resection are necessary.[5]

Various types of tumors may be found at the CCJ. Confusion between benign and malignant tumors or pseudotumors must be avoided, sometimes requiring a biopsy. Surgery using a lateral approach usually permits the surgeon to achieve a complete resection either preserving the stability of the CCJ whenever intact or associated with stabilization procedure. Tumoral involvement of the neighboring structures including bone, nerves and vertebral artery and the dynamic aspects of the bone structures raise technical difficulties in the surgical approach. The surgical management includes tumoral resection and stabilization of the CCJ.[6]

2. Patients and Methods

This descriptive study included 35 patients with different types of craniocervical junction lesions, managed in the departments of Neurosurgery, Tanta University between February 2016 to December 2018. The inclusion criteria included patients with different craniocervical junction lesions who were surgically treated were classified into: neoplastic and non-neoplastic lesions including congenital, developmental, traumatic bony lesions and other lesions as inflammatory lesions also included. We excluded in this series patients treated conservatively and

All patients were subjected to clinical history and examination (general and neurological). Suboccipital headache was evaluated by VAS, other symptoms were also evaluated as numbness, weakness. All cases were evaluated radiologically by MRI brain, Cervical and also whole spine MRI in

Chiari cases to assess for syrinx or not.

Treatment included an informed consent obtained from all participants in this research. Patients included in the study, according to inclusion and exclusion criteria mentioned above subjected to surgical intervention either Anterior, Posterior or Posterolateral approach to the craniocervical junction. Decision making based upon the radiologic study regarding anatomic location, relation to bone, Neurovascular structures and according to stability of this area, fusion was considered in unstable conditions or post-surgical instability.

Follow up, all patients were followed up after surgery for at least 6 months including Clinical evaluation of neurological status of patient and radiological evaluation including: follow up x-ray cervical spine and CT scan and /or MRI according to the pathology of the lesion.

Surgical approach to the craniocervical junction is usually chosen according to the pathology and location of the lesion and whether fusion is needed or not.

The posterior approach is the most common approach used in these thesis as it gives us wide range for managing cases in the region of the craniocervical junction, some cases we have to extend far lateral approach and other cases we used anterior approach in the form of odontoid screw insertion and the other situation we used the anterior approach in the form of retropharyngeal approach as first stage for either biopsy or infection drainage then we used posterior approach as second stage for fusion in selected cases will be discussed in details, transoral approach is not included in these thesis as we didn't face cases absolutely indicated plus reported high rate of complications.

Posterior Approach to the CCJ:

- Posterior Decompression in the CCJ:

The patient's position is prone on the operative bed and the cervical spine was prepped and draped in the usual sterile fashion. Intravenous perioperative antibiotics were administered as per protocol. X-ray fluoroscopy was used to localize the C1 through C2 vertebra. Neuromonitoring was used throughout the case to monitor somatosensory evoked potentials as well as motor evoked potentials.

A linear incision was made over the C1/2 spinous processes. A subperiosteal dissection was performed. At this point, the microscope was brought into the field and a C1 to C2 laminectomy was performed using the bone scalpel. Next, a suboccipital craniectomy was also performed for exposure of the cranial aspect of the lesion.

The thecal sac was gently palpated with a micro hook instrument to verify location of lesion. Next, a durotomy was performed in a linear fashion. The dura

was tacked up with 4-0 Nurolon structures. The tumor was immediately visible, with the spinal cord pushed to the contralateral side. At this point, microsurgical technique and instruments were used to resect the tumor in its entirety. An intraoperative consultation from the Neuropathology Department was obtained, and the lesion was consistent with a meningioma. All dural attachments were bipolarized. The motor evoked potentials were stable compared to baseline after tumor resection.

At the conclusion of the procedure, there appeared to be gross total resection of the tumor. Hemostasis in the surgical bed was achieved using bipolar cautery. The wound was copiously irrigated and the dura was closed in a watertight fashion using 4-0 Nurolon sutures. Duraseal was then applied over durotomy.

The incision was then closed in anatomical layers using 0 and 2-0 Vicryls. The skin incision was then closed using a running nylon stitch. A sterile dressing was applied and the patient was returned to the supine position onto his hospital bed.

In Chiari cases we used also a separate pericranial incision about 4 cm lateral to the midline incision and we close the duroplasty using double layered graft of pericranial and Gortex and achieve water tight closure of the duroplasty, the other steps similar to the previous method for closure of the wound.

- Posterior instrumentation in the CCJ:

In cases which show dislocation or evident instability confirmed by clinical and radiological investigations including movement in flexion and extension views and increased ADI and wide distances in powers ratio >1 On CT craniocervical junction and showing mostly pannus from instability as in Rheumatoid arthritis and traumatic instability we usually do decompression at C1 and C2 plus instrumented fusion, there are multiple instrumentation techniques used in our thesis, the preferred one for fusion of C1 and C2 is C1 lateral mass and C2 pedicle or pars screw either by free hand technique and C-Arm imaging or in some cases we used the neuronavigator for accurate screw insertion, Preoperative CT angiography is done for most cases to determine vertebral artery location and relation to bony anatomy, we measure screw length needed to be inserted in C1 and C2 in the preoperative scan, drilling the facet between C1 and C2 and decortication and using the bone from decompression for fusion augmented by allograft. In some Fusion cases where laminectomy is not needed and the C2 lamina is wide while C2 pedicle is thin and less prominent we preferred to use C2 lamina screw instead of C2 pedicle or pars screw, and decortication of lamina of C1 and C2 and augmenting the fusion with allograft.

-Example of C1-C2 Fusion for instability:

Description Of Procedure:

Neurophysiology monitoring was obtained to monitor somatosensory and motor-evoked potentials throughout the entirety of the case. Baseline signals were obtained prior to positioning. The patient was positioned prone on a regular table with his head fixed in a Mayfield C-clamp. After positioning the neuro monitoring signals remained stable. The posterior cervical spine was prepped and draped in usual sterile fashion. Perioperative intravenous antibiotics were administered as per protocol.

A linear incision was made over the C1-2 spinous processes. A subperiosteal dissection was then performed. Hemostasis was achieved using bipolar cautery and Surgiflo. At this point, bilateral lateral mass screws were placed on the C1 lateral masses measuring 18 mm. with trajectory about 20 degrees medial and 20 degrees superior towards anterior tubercle of C1, Appropriate positioning of the screws was verified using lateral fluoroscopy. We then subsequently placed C2 pedicle screws guided by anatomical entry point and feeling the pedicle by penfield instrument or feeler, measuring 22 mm bilaterally. This was once again confirmed using lateral fluoroscopy. Subsequently, a C1-2 laminectomy was performed using the bone scalpel. After placement of screws and laminectomy (Fig.1), the neuro monitoring signals remained stable.

At this point, all exposed bony surfaces and the C1/2 joint were decorticated and a combination of ViviGen, DBX, and local autograft was placed over all exposed bony surfaces spanning the C1-2 joint. Titanium screws were then connected bilaterally using a titanium rod. The wound was copiously irrigated with sterile saline and vancomycin powder was introduced in the wound. The wound was then closed in anatomical layers using 1 and 2-0 Vicryl sutures. The skin was then closed with skin staples. Cervical collar was then applied to the patient's neck and then the patient was returned to the supine position.

In some other cases, we used C2 laminar screw (Fig.3) instead of C2 pedicle or pars screw as mentioned and we used neuronavigation in some other cases (Fig. 2).

In cases of cervicocervical instability where occipitocervical fusion is indicated we used occipital plate and mostly skip C1 and use C2 pedicle or pars screw or C2 laminar screw and extend fusion to C3 and subaxial spine when needed using modified Magerl technique for lateral mass screws in the subaxial spine and the occipital plate screws around the occipital protuberance for maximal screw torque then connected to the C2 screw and the subaxial screws usually by connector to decrease stress on the rod at the bending site.

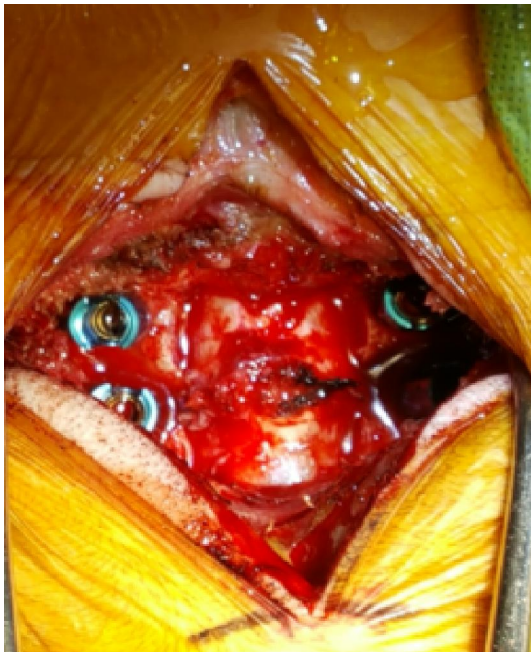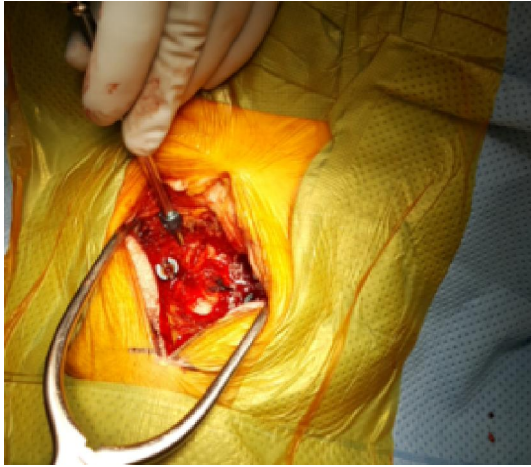


Fig. 1: Intraoperative images after decompression and C1- C2 screws insertion

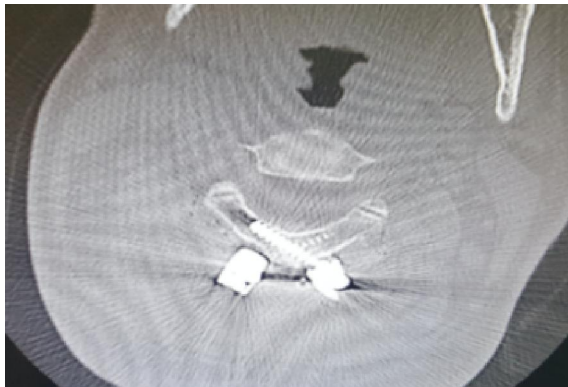


Fig. 2: postoperative picture C2 lamina

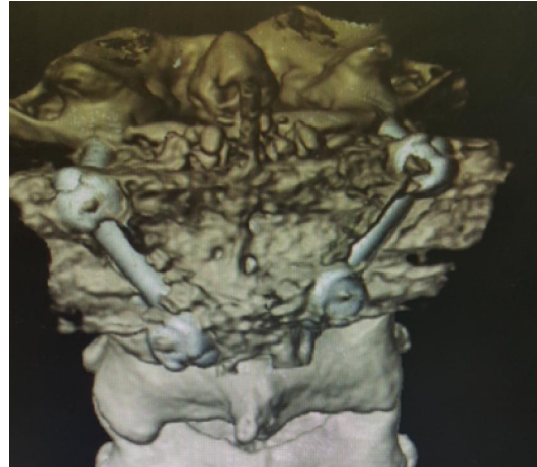

Fig. 3: 3D C1-C2 lamina graft

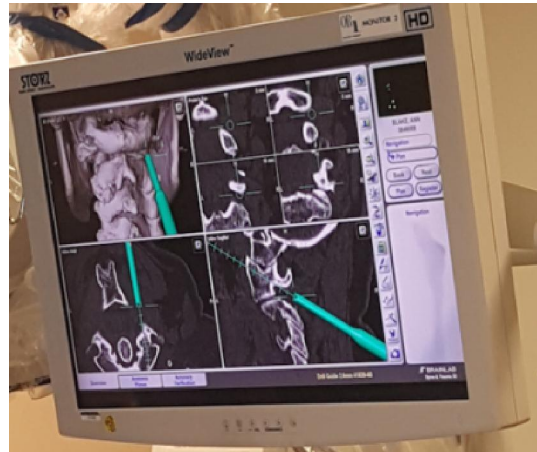

Fig. 4: Neuronavigation for Screw insertion

-Example of Occipitocervical Fusion as C1 metastatic lesion and C1 Jefferson fracture:

Position and surgical steps same as before, regarding instrumentation: -

The C1 lamina is exposed using the Penfield 1 and the curette. Lateral fluoroscopy confirms the spinal levels. The lateral masses of C3 are exposed using the Bovie. We then use a high-speed drill to drill entry sites into the C3 lateral mass directly within its center point. The hand drill was then used to aim approximately 25 degrees laterally and cephalad, and a pilot hole is created using this trajectory. The hole is then palpated and tapped. We then place a appropriate length screw at this level mostly 12 mm. We then place bilateral translamina screws at the C2 level. Using the high-speed drill, we create entry points at the lamina spinous process junction bilaterally. One of the entry sites is slightly more cephalad than the other. We then drill to a depth of approximately 18 mm. The holes are then palpated and then tapped. To make sure no evidence of any breach. Mostly 18 mm length screws are then placed.

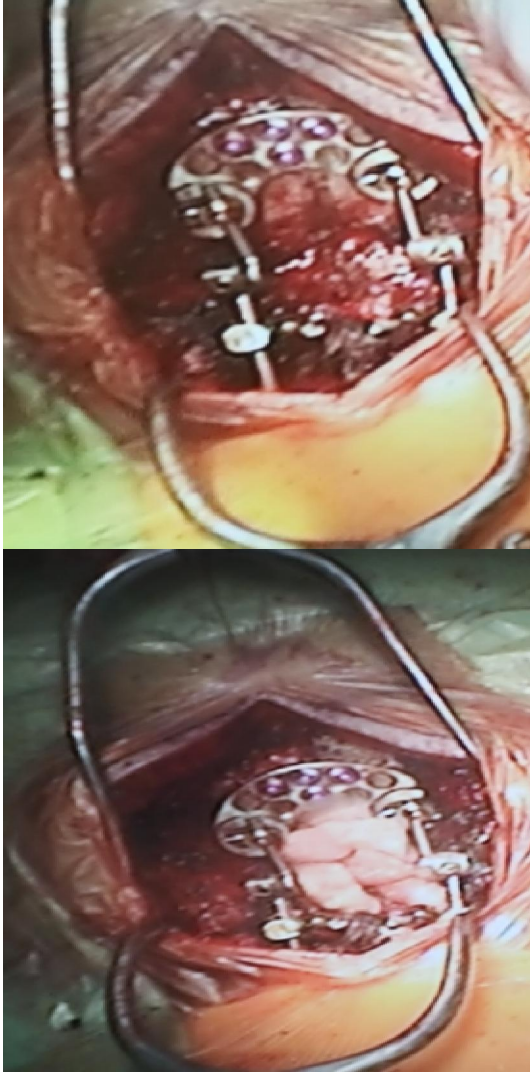


Fig. 5: Intraoperative images showing the occipitocervical fixation system and the used graft.

Satisfactory position is confirmed using lateral fluoroscopy. We then inspect the occipital and suboccipital region for placement of the occipital plate. We determine the location of the inion. We then fashioned the occipital plate to the contour of the skull and then placed it approximately 1.5 cm below the inion. We then drill holes in the skull through the plate using the hand drill. One of the holes is in the midline keyhole and just lateral to the keyhole. One of the holes is only 6 mm deep before reaching the dura. The other holes were 8 mm deep. The holes are then palpated and then tapped. We place one 6 mm screw and three 8 mm screws. The screws should have satisfactory bony purchase.

We then fashion the hinged rods to the contour and shape of the cervical screws and the occipital plate. We used a cross connector to attach the rod to the C2 translaminar screws. All of the screws were

then tightened to their final positions, and the construct was complete (Fig. 5 and 6). We decorticate the bony surfaces between the occiput and C3, and demineralize bone matrix, and allograft bone was placed over the decorticated regions.

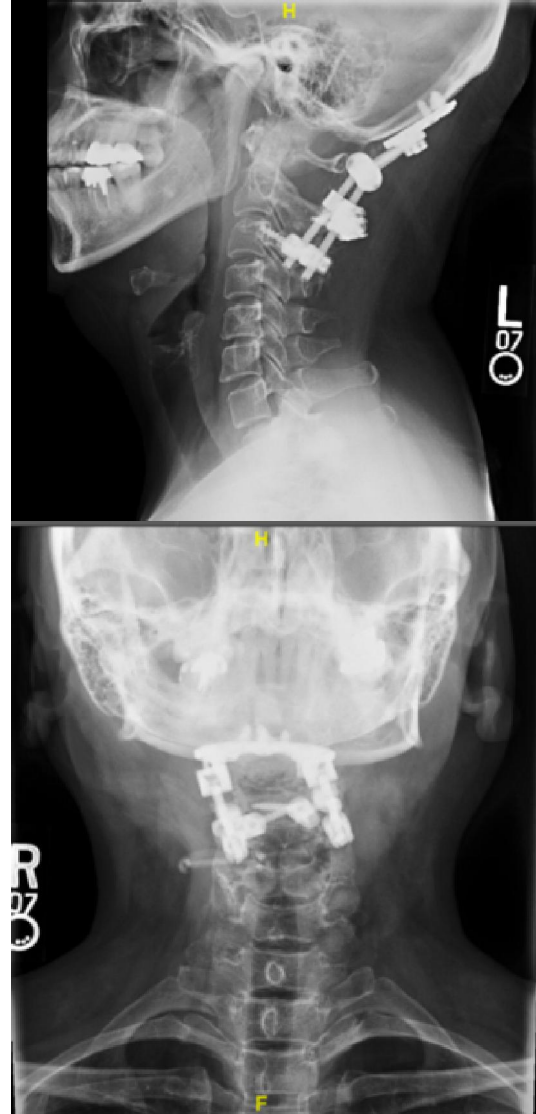


Fig. 6: Postoperative image of Occipitocervical fixation with good alignment.

Far Lateral Approach to the CCJ:

We used far lateral approach in this thesis in one case with large tumor extending from CPA area to the craniocervical region, Full description of the approach as follow:

Description of Procedure:

- Positioning: Body position lateral, left side up. Head placed in 3-point Mayfield head holder. Body parts were positioned and padded for protection.

- Neuro-navigation: Brain LAB registration obtained.

Incisions: New C-shaped incision line marked out from C3 toinion to behind pinna. Hair was clipped in a routine fashion.

- Prep: Preprep skin cleansing with soft hand scrub brushes. Routine Betadine prep. Sterile draping was placed. The incisions were infiltrated with 0.25% Marcaine 1: 200,000 dilution epinephrine.

- Approach:

The incision was opened. Rainey clips were applied for hemostasis. The dissection was carried down to the periosteum, elevating the nuchal musculature laterally on bloc to expose the suboccipital bone, posterior arch of C1, and continued laterally to the sulcus arteriosis. The cervical suboccipital dura was exposed. The scalp/muscle was retracted laterally. The scalp was padded, and retracted with fish hooks and rubber bands.

- Pericranial graft: None

- Craniotomy: Burr holes were placed and the craniotomy elevated using the high-speed drill. The dura was intact at opening. The posterior arch of C1 was removed. The condylar vein was coagulated, and a couple of mm of the condylar joint drilled down. The dura was adherent, and no dural tack ups were required.

- Dural opening: The dura was opened carefully.

The operating microscope was brought into the field

- Definitive procedure: The vertebral artery was located. Branches of 11th nerve were identified and swept off the tumor capsule. Using microdissection technique, the arachnoid was gently pulled away from the tumor capsule. Cottonoids were placed and this process continued circumferentially to free the margins. The tumor was centrally debulked using the ultrasonic aspirator. The dissection was continued as described above until the entire tumor was freed and removed. This involved identification and carefully sweeping away 7 through 12. Nerve stimulation was used throughout with intact function maintained. Tiny tumor pieces were left on CN branches if they were too adherent. Meticulous attention was placed to preserve cortical veins and arterioles.

Extent of resection: Near gross total, possible tiny residual along CNs

Resection cavity: Hemostasis was acquired

- Dural closure: The dura was closed primarily using 4-0 neuroilon interrupted sutures. A watertight dural closure was obtained. Tisseel was used. The wound was irrigated. Central tack ups were placed. The bone flap was returned, and anchored with titanium plates and screws. The muscle fascia was closed in layers with 0 and 3-0 Vicryl. The galea was closed with 3-0 Vicryl. The skin was closed with 3-0

nylon vertical mattress sutures. Sterile dressing was placed. The Mayfield was removed.

Anterior Approaches to the CCJ:

Anterior approaches to the craniocervical junction in our thesis consist of either Anterior odontoid screw insertion or Retropharyngeal approach. Transoral approach is out of our thesis due to reported complications by other authors and unfamiliarity with the approach.

-Anterior Odontoid Screw:

In managing cases of atlantoaxial instability in our cases and our concept to use this screw for cases of odontoid fracture type 3 or odontoid fracture type 2 with oblique fracture with minimal displacement and intact transverse ligament or after failure of fusion with Halo placement.

Position of the patient supine position, we mark our incision guided by Fluoro imaging aiming the level of C5-C6 cervical disc, Then after prep the incision site as usual way we make a horizontal incision usually in the right side of the neck, then we dissect and cut the platysma muscle and then we dissect the anterior strap muscles by blunt dissection aiming at the cervical spine, then we dissect the prevertebral fascia and by using spinal needle we confirm the level, better to use Apfelbaum retractor, slight dissection of the longus coli muscles on both sides, then we the electric drill to drill a hole in the lower anterior border of C2 in the midline guided an confirmed by the bi-plane fluoro imaging Anteroposterior and lateral views, then we tap the hole all the way to the odontoid tip guided by Biplane fluoro imaging, the application of the screw all the way in the track previously tapped and the length of the screw determined by measuring the distance from lower anterior C2 body border to the tip of the odontoid in preoperative CT imaging, hemostasis of the wound is achieved then closure of the platysma muscle with interruptedvicryl sutures, then closure of the subcutaneous and subcuticular layer with vicryl sutures, steristreps applied to the wound site.

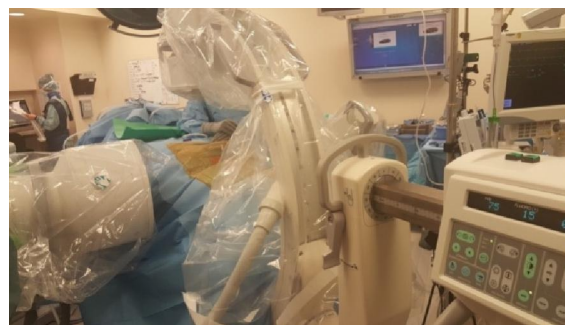

Fig. 7: Intraoperative image of the surgical room showing Biplane C-arm

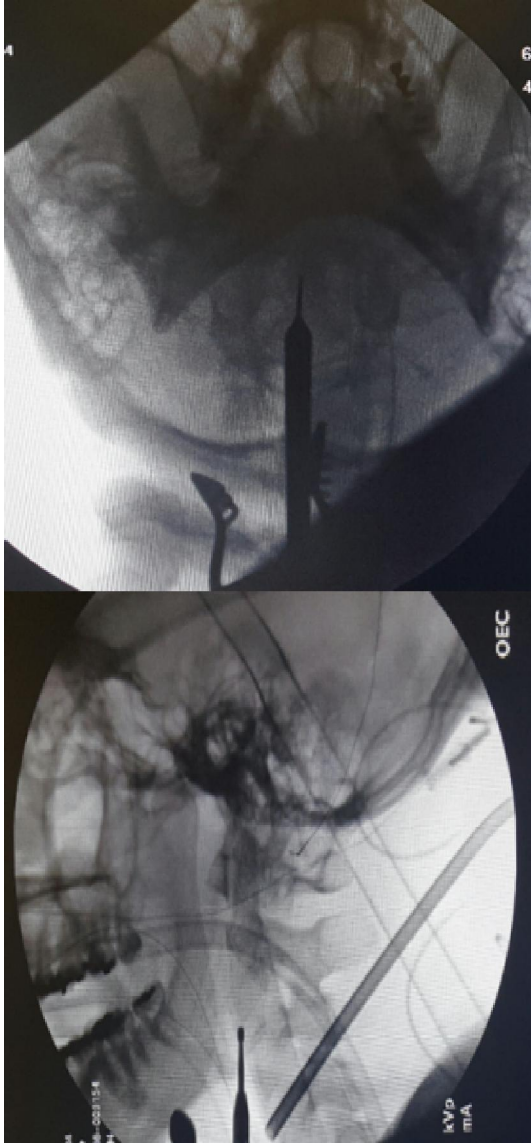


Fig. 8: Biplane Fluoro-imaging AP and Lateral views

-Submandibular Retropharyngeal Approach to the CCJ:

The patient's position is supine and the patient's head is extended approximately 15° and rotated 30° away from the surgeon. This results in elevation of the mandible out of the surgeon's line of sight to the surgical field. a transverse incision about 2 cm below the mandible, extending from the angle of the mandible to approximately 1 cm past the midline. Subcutaneous tissues are then dissected free from the underlying platysma muscle. In the midline, the vertically oriented fascial raphe of the platysma muscle is seen. The platysma muscle is elevated beginning at its medial edge, and a hole is cut into the medial fascial raphe. The opening of the raphe passes from the superficial to the middle fascial layer. This

opening is then extended in both a cephalad and caudal direction, thereby separating the platysma in the cervical midline.

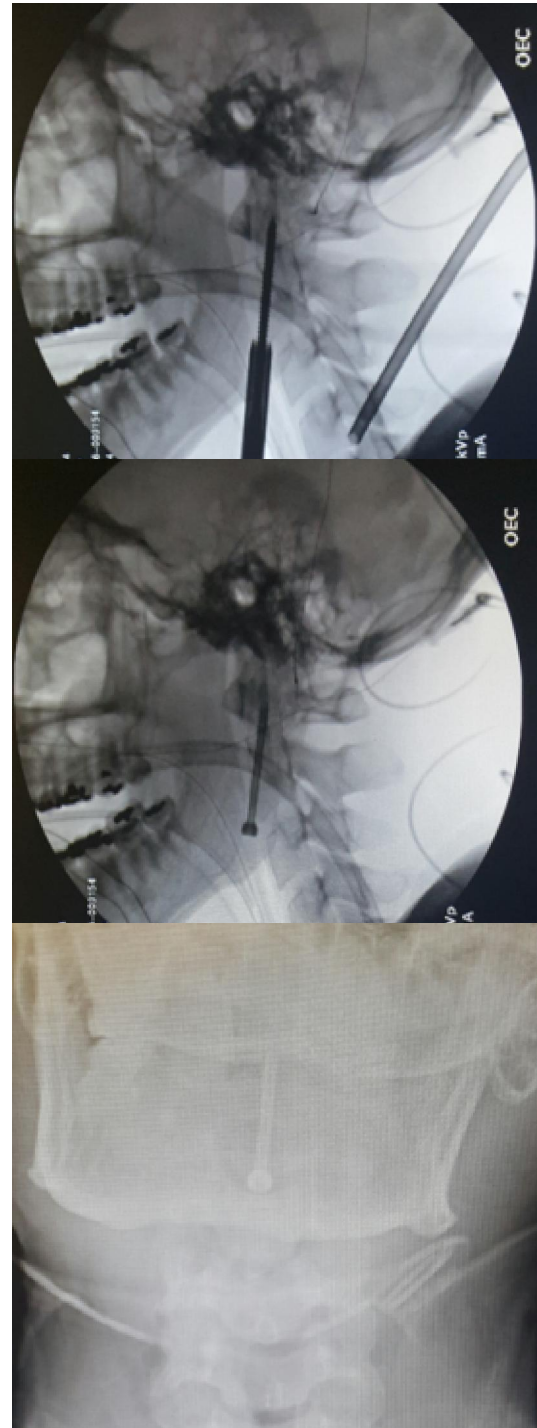


Fig. 9: Screw insertion lateral and AP views

This fascial raphe incision extends from the symphysis of the mandible to the level of the medial notch of the superior thyroid cartilage. This vertical access allows easier retraction of the deeper structures

of the neck. The undersurface of the platysma muscle is then dissected free from medial to lateral at the level of the midportion of the raphe. The muscle is then transected in line with the original skin incision. After elevation of the platysmal flaps, the superficial fascial investment of the submandibular gland is visualized. This is initially seen protruding from beneath the superficial layer of deep cervical fascia. The fascial capsule is opened and undermined inferiorly to allow elevation of the submandibular gland cephalad with the self-retaining retractor along with the skin edge. Deep and slightly inferior-lateral to the gland are the facial artery and vein. These vessels are dissected free along their visible course, thus extending the fascial opening. The facial vein can be suture-ligated and transected. The facial artery should still be preserved. Proximal dissection of the facial artery leads to identification of the reflection of alar fascia of the carotid sheath. This represents the lateral limit to the exposure.

After dissection of the facial vessels, the submandibular gland can be retracted further cephalad and the digastric tendon is visualized as a glistening white cord running horizontally through the field. There is a fascial sling tethering the tendon of the digastric muscle to the underlying hyoid bone. Transection of this fascial layer allows mobilization of the tendon and the two bellies of the digastric muscle. Dissection of the fascial planes of the digastric both medially and laterally permits its retraction rostrally. With elevation of the digastric tendon, the hypoglossal nerve can be seen through its fascial investment running in the same orientation as the digastric tendon. Careful dissection of this fascial layer from a medial to lateral direction will allow mobilization and elevation of the hypoglossal nerve. This dissection is continued to the level of the descending hypoglossal ramus, which also helps define the lateral extent of dissection. The hypoglossal nerve can then be retracted cephalad, exposing the hyoglossus muscle.

The anterior tubercle of C1 can be palpated rostrally. This assists in defining the midline. The longus coli muscles, which are converging toward the anterior tubercle of C1, are cauterized and dissected from the anterior and lateral surfaces of C2 and C3. Deep self-retaining retractors can then be inserted between the medial borders of the elevated longus coli muscles, similar to any anterior cervical dissection. With further retraction of the prevertebral muscles, the anterior arch of C1 can be identified. With this surgical approach, further longus capitus muscle dissection can lead to exposure of the clival basiocciput.

A retractor can then be inserted with its tip on

the superior surface of the anterior arch of C1. This retractor is attached to a restraint close to the operating field with rubber bands. If the C1 arch is absent, is involved in the pathologic process, or is part of the bone to be resected, a notch can be drilled into the basiocciput to provide a purchase site for the tip of the retractor. At this point the arch of C1, base of the dens, predental space, lateral mass articulations, ventral surface of C2 and C3 vertebral bodies, and the C2-3 intravertebral disk should be clearly in view. There is always significant bleeding from the epidural veins in the lateral recesses. This bleeding is controlled by resection of these lateral ligaments, bipolar electrocautery, and microfibrillary collagen tamponade. With gentle pressure with cottonoids and patience, this bleeding can be controlled.

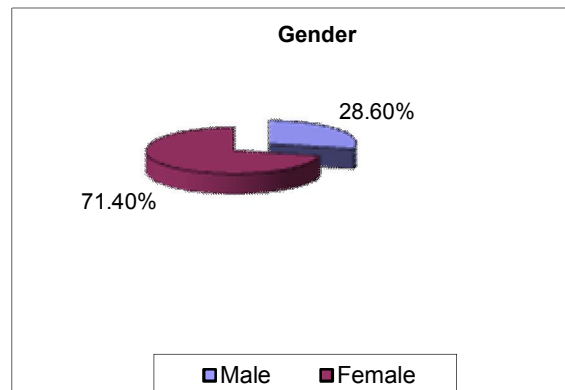
3. Results:

Age: Min- max: 2 – 93 y
 Mean ± SD = 51.23 ± 20.24

Table 1: Distribution of cases according to age groups.

Age	No	%
0-10	1	2.9
11-20	2	5.7
21-30	7	20
31-40	1	2.9
41-50	7	20
51-60	7	20
61-70	4	11.4
71-80	3	8.6
81-90	2	5.7
91-100	1	2.9
Mean ± SD	51.23 ± 20.24	

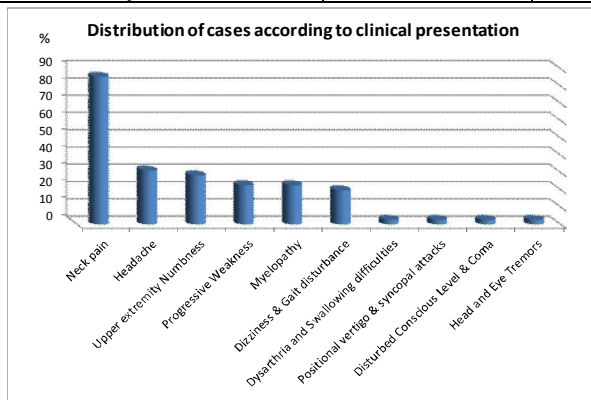
Gender: Male = 10 / 35 = 28.6 %
 Female = 25 / 35 = 71.4 %



Clinical Presentations:

Table 2: Distribution of cases according to clinical presentations.

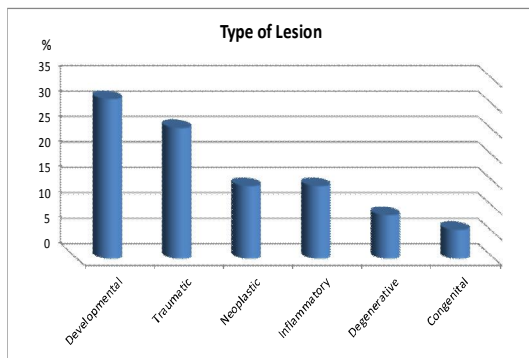
C/O	No of Cases (35)	%
Neck pain	30	85.7
Headache	11	31.4
Upper extremity Numbness	10	28.6
Progressive Weakness	8	22.9
Myelopathy	8	22.9
Dizziness & Gait disturbance	7	20
Dysarthria and Swallowing difficulties	1	2.9
Positional vertigo & syncopal attacks	1	2.9
Disturbed Conscious Level & Coma	1	2.9
Head and Eye Tremors	1	2.9



Type of Lesion:

Table 3: Distribution of cases according to type of lesion.

Type of Lesion	No	%
Developmental	11	31.4
Traumatic	9	25.7
Neoplastic	5	14.3
Inflammatory	5	14.3
Degenerative	3	8.6
Congenital	2	5.7

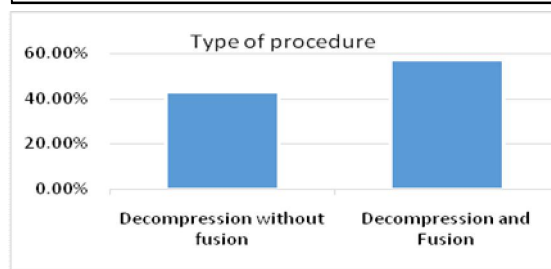
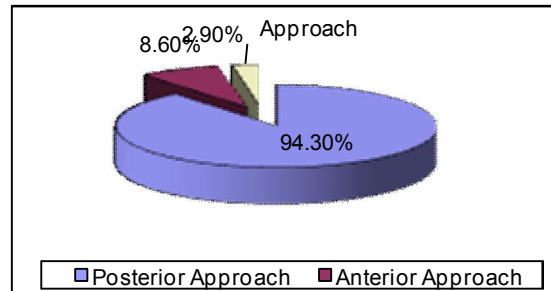


Approaches:

- Post Approach: 33 Case
- Anterior Approach: 3 cases: 1 odontoid screw and 2 Cases Retropharyngeal approach (1st stage of combined approach)
- Far lateral approach: 1 Case

Table 4: Distribution of cases according to Approaches.

Approaches	No	%
Posterior Approach	33	94.3
Anterior Approach	3	8.6
Far Lateral Approach	1	2.9

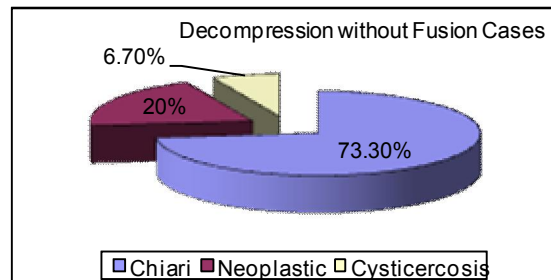


Decompression without Fusion (Non-fusion group):

- 15 Case: 15/35 = 42.9 %
- Chiari: 11 Case
- Cysticercosis: 1 Case
- Neoplastic: 3 Cases

Table 5: Distribution of cases in non-fusion group.

Decompression without Fusion Cases	No	%
Chiari	11	73.3
Neoplastic	3	20
Cysticercosis	1	6.7

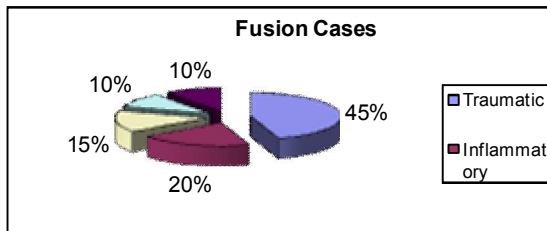


Fusion Cases: 20 Cases: 20/35 = 57.1 %

- Traumatic: 9 Cases
- Inflammatory: 4 Cases
- Degenerative: 3 Cases
- Congenital: 2 Cases
- Neoplastic: 2 Cases
-

Table. 6: Distribution of cases in fusion group.

Fusion Cases	No	%
Traumatic	9	45
Inflammatory	4	20
Degenerative	3	15
Congenital	2	10
Neoplastic	2	10

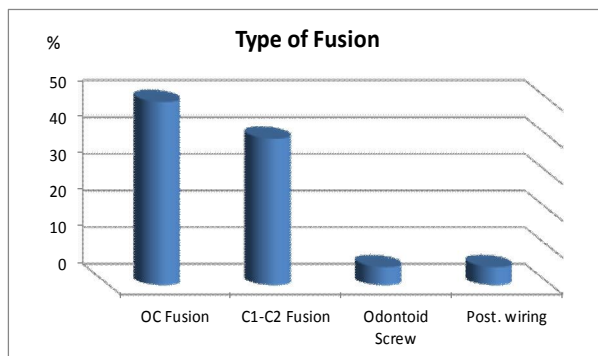


Type of Fusion: 20 Cases

- O-C Fusion: 10 Case
- C1-C2 Fusion: 8 Cases
- Odontoid Screw: 1 Case
- Post. Wiring: 1 Case

Table. 7: Distribution of cases according to type of fusion.

Type of Fusion	No	%
OC Fusion	10	50
C1-C2 Fusion	8	40
Odontoid Screw	1	5
Post. wiring	1	5



Outcome and Follow up:

All cases showed marked improvement postoperatively in comparison to preoperative presentation, and patients continued to improve in postoperative follow up visits at 2 weeks and 3-month visits, little neck pain and discomfort at surgical site improved postoperatively.

- Eleven Cases with Chiari malformations with a verity of symptoms including headache tussive in nature, Neck pain, dizziness, weakness with imaging showing Chiari malformation in the form of cerebellar tonsillar descent below foramen magnum with four cases showing Syrinx, all cases underwent suboccipital decompression and C1 laminectomy and tonsillar shrinkage by bipolar cauterization without resection of the tonsils, all cases show marked improvement postoperatively.

- Headache and upper extremity numbness encountered in Chiari patients and other pathologies improved markedly, transient less severe headache early postoperative for 2 weeks controlled by analgesics then relived, one case among Chiari cases showed Head and eye tremors who showed marked improvement postoperatively.

- one case with degenerative pannus and instability at the craniocervical junction presented with dysarthria and swallowing difficulties misdiagnosed before as stroke markedly improved postoperative.

- one case presented with positional vertigo and syncopal attacks when bending the head, the patient has Congenital Ehler-Danlos syndrome with hyper-laxity at the craniocervical junction, markedly improved after OC fusion

- Eight patients presented with progressive weakness and myelopathy and Seven Patients in our Thesis had Dizziness and gait disturbance who shown marked improvement of weakness and continue to improve with physical therapy and occupational therapy.

- Two cases of Rheumatoid Arthritis one of them was intact with severe neck pain with atlantoaxial subluxation and instability, C1-2 fusion was done, the second case presented with neck pain and quadriparesis grade II with imaging showed marked subluxation at the atlanto axial and atlanto occipital joint with basilar invagination and cord compression improved after traction and occipito-cervical fusion to motor power grade IV.

- Five neoplastic lesions at the craniocervical junction two of them Meningiomas one at CPA extending caudally to the craniocervical and one schwannoma bilaterally located at the foramen magnum and 2 cases with metastatic lesions at C2

level, in our series two cases managed by posterior approach only with no reported complications and one case by far lateral approach with mild hypoglossal dysfunction, the other two cases one of them managed by Combined anterior retropharyngeal approach for Biopsy and posterior Approach for fusion and the other one with known primary operated by posterior fusion and radiotherapy.

– Nine patients with traumatic lesions including: 7 patients with type II dense fracture and one case with Jefferson C1 fracture and one case Child presented with occipito -Atlanto -axial dissociation post Motor vehicle accident with Coma and, External ventricular drain was placed and ICU stabilization, then OC Fusion was done posteriorly and kept in ICU till weaned from EVD and continue to show improvement. Among the seven cases presented with type II dense fractures we used posterior approach in 6 cases for managing these cases and one case operated using Anterior approach in the form of Anterior odontoid screw and was intact.

– The posterior approach for fusion among these 6 cases was C1-2 fusion using C1 lateral mass and C2 Pedicle or Pars screws in 3 Cases and 2 cases we preferred Occipito cervical fusion as these cases have very small pedicles and the patients were old age and in one case was totally intact aged 93 years old we preferred wiring and graft fusion as a protective small maneuver.

– 3 cases traction was done and failed Halo fusion for 3 months prior to surgery and were intact motor power with Neck pain, and 3 cases presented with old neglected fracture with pannus compressing the cord and progressive neurologic deficit.

– The last case of the 9 trauma patients a case presented with Jefferson fracture operated with occipito-cervical fusion then after four months presented with failure of fusion, redo surgery for OC fusion was done using navigation guided cervical pedicle screws and extra rod.

– One case of craniocervical junction infection stated to be cysticercosis, in our patient the case presented at first with headache and dizziness and was diagnosed with hydrocephalic changes and being cysticercoid antibody positive, Albendazole therapy and shunt was done in other hospital, then presented to us with shunt malfunction with increasing symptoms with revision of shunt and repeated imaging, well-formed cyst at the craniocervical junction and fourth ventricle was seen, so suboccipital decompression and cyst removal was done with improved preoperative symptoms.

– One case presented with infection at the CVJ, presented with progressive quadriparesis, after antibiotic course and follow up imaging we found it

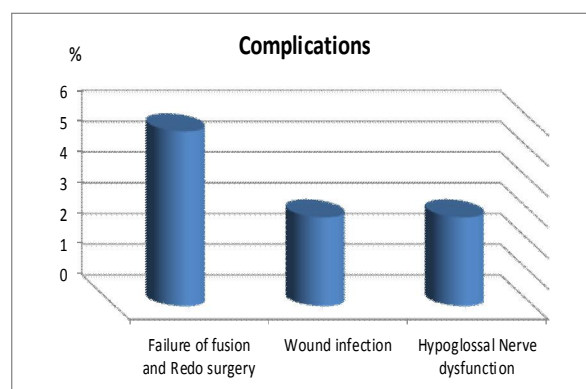
more favorable to the patient to drain the abscess by retropharyngeal submandibular approach and then in the same setting we did occipito cervical fusion posteriorly with significant postoperative improvement.

– Long term follow showed failure of fusion and Redo cases are mentioned in complications.

Complications:

Table 8: Complications.

Complications	No	%
Failure of fusion and Redo surgery	2	5.7
Wound infection	1	2.9
Hypoglossal Nerve dysfunction	1	2.9



Failure of fusion and Redo surgery: 2 cases with failed fusion 5.7%, the 1st one we Redo surgery in the form of OC- Cervical (pedicle screws) fusion and augmentation of fusion after 5 months of 1st surgery as occipito cervical fusion for Jefferson fracture, the 2nd Case Rheumatoid arthritis 4 month after surgery We Removed the system and kept in Hard collar. Wound infection: in one case 2.9%, the case was Rheumatoid with multi organ affection, osteoporosis and on high dose steroid therapy, infection of the wound, we Removed the system and kept in Hard collar. Hypoglossal Nerve dysfunction in one tumor Case 2.9%, in the form of tongue deviation, protrusion, swallowing difficulties and dysarthria, partially improved with conservative measures and speech therapy.

4. Discussion

The craniocervical junction region is affected by various pathological processes, that varies widely and involves congenital, developmental, acquired abnormalities and etc., which can result in

neurological deficit secondary to neurovascular compression, abnormal cerebrospinal fluid dynamics and vertebral instability. A physiological approach selection depends on understanding of the craniocervical junction dynamics, the site of encroachment and stability.[7]

In our presented study, we have included a variety of 35 cases of craniocervical junction lesions with different pathologies and different approaches to treat those lesions, the age varies widely of the candidates: Min- max: 2 – 93 y with Mean \pm SD = 51.23 \pm 20.24 and male: female ratio in our thesis is (28.6%: 71.4%).

We had in our series eleven cases with Chiari malformations with a variety of symptoms including headache, neck pain, dizziness, weakness with imaging showing Chiari malformation in the form of cerebellar tonsillar descent below foramen magnum with four cases showing syrinx, all cases underwent suboccipital decompression and C1 laminectomy and tonsillar shrinkage by minimal bipolar cauterization without resection of the tonsils, we always aim to keep the pia around the tonsils intact to avoid chemical meningitis from blood and adhesions, and close the defect with double layer of Gortex and pericranial graft from a separate incision, all cases showed marked improvement postoperatively. This technique we used was matching the same as Batzdorf et al 2013, as they reported 177 case with Chiari malformation including 97 cases with syringomyelia underwent posterior fossa decompressive surgery, both the dura and arachnoid were opened in 150 patients and 135 underwent reduction of cerebellar tonsils with the same technique we use for decompression and duroplasty with double layer Gortex and pericranial flap and they recorded the symptoms and signs and they measured the size of retrotonsillar and subtonsillar cisterns and syringomyelia cavities as well using scales on MRI image viewer and found that Clinical improvement is strongly related to enlargement of subarachnoid cisterns and enlargement of cisterns also correlated to reduction of syrinx cavity.[8]

Different other techniques were described for management of chiari malformation as Goldschagg et al 2017, who reported 14 Chiari cases with varying symptoms: headache, ataxia, hypo-/dysthesia and paresis all cases underwent suboccipital decompression and removal of one tonsil, they stated that marked improvement regarding preoperative complaints was obtained however he stated that 50% of patients had mild ocular motor dysfunction than preoperative recordings which shown to be asymptomatic. [9] Also Chotai et al 2014, reported 30 case with Chiari malformations with male: female ratio 1:14 (in our series 1:10) with mean age 35.5

years (in our series of eleven cases 32.9 years) with varying symptoms and he used wide suboccipital decompression and intentionally sparing Arachnoid opening, and the reason they explained that to prevent exposure of subarachnoid space and CSF leak so prevention of arachnoid scarring and adhesions and aseptic meningitis, they also used wider bony decompression (3.5-4.5 cm).[10]

There is lot of controversy regarding Chiari malformation surgeries and what is the best way to manage, and that each surgical modification increases the potential for improved surgical outcomes also subjects patients to certain additional surgical risks as reported by Baisden et al, for example they mentioned that, Sindou and Gimbert's meta-analysis of 12 studies involving adult patients with Chiari malformation without syringomyelia, they noted that 84% clinical improvement rate in patients underwent foramen magnum decompression accompanied by dural opening and/or duroplasty, but with preservation of the arachnoid (No superiority with arachnoid opening was identified) to enlarge the cisterna magna, and Clinical improvement was also noted for foramen magnum decompression, dural opening, arachnoid opening, and duroplasty; however, a higher complication rate was observed when the arachnoid was opened.[11]

Our bony decompression size was 2.5 to 3cm and our concept regarding that wide decompression may lead to cerebellar sagging and ptosis and limit improvement and the arachnoid opening with meticulous hemostasis to prevent adhesions and aseptic meningitis, none of our cases showed aseptic meningitis or CSF leak. Also, Baisden et al concluded that regarding the size of decompressive craniotomies. The smaller craniectomy group had shown clearly long term efficacy than large craniectomy group and also the syrinx size decreased more in smaller craniectomy group than larger craniotomies. [11] Regarding the craniectomy size, the bigger decompression may lead to cerebellar ptosis and decrease improvement with possible deterioration as reported by Holly and Batzdorf 2001, as they reported seven patients with cerebellar ptosis following craniocervical decompression, 5 cases with worsening intractable headache and 2 cases with neurological deficits caused by recurrent syringomyelia and reported the cause of that is wide suboccipital decompression about 4 x 4 cm which is about double needed decompression and they managed these patients with various measures including VP shunt, syringo-peritoneal shunt, partial suboccipital cranioplasty with reported improvement. [12] Also, Litvak et al 2013 also described in a retrospective cohort study that Dural splitting decompression was

equally effective, safer, and lower cost for treatment of Chiari I malformation without syringomyelia.[13]

In our series we had two cases of rheumatoid Arthritis one of them was intact complaining of severe neck pain with atlantoaxial subluxation and instability, C1-C2 fusion was done, the second case presented with neck pain and quadriplegia grade II with imaging showed marked subluxation at the atlanto axial and atlanto occipital joint with basilar invagination and cord compression improved after traction and occipito-cervical fusion to motor power grade IV. Wolfs et al, studied a clinical trial of rheumatoid craniocervical treatment which is an interventional- prognostic trial comparing early surgery and conservative treatment, and found that early surgery could prevent serious neurological deficits, and reported that surgical cervical fixation in patients with atlantoaxial pathology without neurological complaints early surgery in those patients has advantages of probable preservation of neurological function with higher degree of general functioning, and also the surgical fixation will be less extensive and easier to perform compared to surgery in later stage because of more pronounced destruction of joints and bones, and if neurological deficits are present before surgical fixation there is a little chance of full neurologic recovery.[14]

In our series, we had five neoplastic lesions at the craniocervical junction (two of them Meningiomas, one at CPA extending caudally to the craniocervical junction, one schwannoma bilaterally located at the foramen magnum and two cases with metastatic lesions at C2 level. In our series two cases managed by posterior approach only with no reported complications and one case by far lateral approach with mild hypoglossal dysfunction, the other two metastatic cases one of them managed by Combined anterior retropharyngeal approach for Biopsy and posterior Approach for fusion, the other one with known primary managed by posterior approach only for fusion and then radiotherapy. Duhrsen et al studied meningiomas at the craniocervical junction and follow up of 18 patients with craniocervical junction Meningiomas located at different sites in the craniocervical junction including 10 patients at CO and C2 and 3 patients at the level of foramen magnum and 5 patients located at the level of clivus and extending caudally, of the upper cervical tumors nine were located ventrally to the medulla and two lateral to it, and the surgical approaches they used included retro sigmoid in one case, sub occipital midline in eleven cases, sub occipital midline with lateral extension in six cases with additional laminectomy of C1. And they also concluded that cure can be achieved surgically in these benign lesions and because their exceptionally benign behavior, complete

resection should not be forced if limited access may complicate this attempt. And the sub occipital midline approach is associated with low rate of morbidity, therefore should be used to avoid surgery related complications.[15]

Shiban et al 2016, reported 21 cases operated for with far lateral or extreme lateral approach with unilateral chondylar resection by about 25% or less in 15 cases and 50% in one case and more than 75% in 5 patients and none of these cases shown any signs of instability or needed fusion later and considered that safe and accepted to remove more than 75% of unilateral chondyle without showing instability.[16] In our case we removed about one quarter of the condyle on one side with no signs of instability.

Ren et al 2014, reported a combined anterior retropharyngeal approach and posterior approach for resection and reconstruction of C2 metastatic tumours, A case report of 44 years old patient, they did posterior fusion then resection of the tumor anteriorly by retropharyngeal approach.[17] Colak, et al 2004 reported two staged operations for managing C2 neoplastic lesions, they performed anterior retropharyngeal resection of the lesion for decompression and then a second stage posterior fusion in 8 patients[18] in our cases we did anterior retropharyngeal approach for biopsy and confirming the diagnosis and in the same setting posterior fusion and follow up radiotherapy of these cases.

In our series, we included nine patients with traumatic lesions including: 7 patients with type II odontoid fracture and one case with Jefferson C1 fracture and one child in MVA presented with occipito-Atlanto-axial dissociation. Among the seven cases presented with type II dense fractures we used posterior approach in 6 cases for managing these cases and one case operated using Anterior approach in the form of Anterior odontoid screw and was intact. The posterior approach for fusion among these 6 cases was C1-2 fusion using C1 lateral mass and C2 Pedicle or Pars screws in 3 Cases and 2 cases we preferred Occipito cervical fusion as these cases have very small pedicles and the patients were old age and in one case was totally intact aged 93 years old we preferred wiring and graft fusion as a protective less risky maneuver. Three cases in which traction was done, they failed Halo fusion for 3 months prior to surgery and were intact motor power with neck pain, and -3 cases presented with old neglected fracture with pannus compressing the cord and progressive neurologic deficit. The case presented with Jefferson fracture operated with occipito-cervical fusion then after four months presented with failure of fusion, redo surgery for OC fusion was done using navigation guided cervical pedicle screws and extra rod, and the

case with occipitoatlanto axial dissociation fused using OC fusion posteriorly.

Type II odontoid fracture is the most common odontoid fracture (65%-74%) and is the most prevalent cervical fracture in patients >70 years old. Result in high percentage of non-unions, and is associated with a low prevalence of associated neurologic deficits (2%- 27%).[19]Falavigna et al 2017, studied a retrospective study of 88 patients with type II odontoid fractures between 2004 and 2015 in 8 Latin American centers including clinical and radiographic factors that influence surgical planning and found that surgery was the primary treatment in 65 patients (73.8 %) with anterior approach in 64.6 %and they reported that this approach is preferred in patients with posterior or horizontal oblique fracture line, local pain and smaller bone contact surface between odontoid and body of C2. And Posterior approach was chosen when distance between fractured bone fragments was > 2 mm or after failed conservative or anterior odontoid screw treatment in a symptomatic patient. These criteria are similar to our criteria for judging the selected approach in odontoid fracture type II patients as we used anterior odontoid screw in a case with minimal displacement and with oblique fracture, and the other cases we used posterior approach as these cases were failed Halo fusion or old neglected fracture with Pannus formation. The difference in percentage between Anterior versus posterior because our number of cases was small in comparison but the criteria for selection of the approach was the same.[19] Also, Faure et al 2017, studied the trends in the surgical management of odontoid fractures in patients above 75 years in a retrospective study of 70 cases and found that 22 patients underwent anterior odontoid screw fixation, 38 were treated using Harms technique and 10 patients with other procedures, and they concluded that Surgical treatment in elderly result in an excellent union rate and Harms technique has a lower risk of complication and better mechanical stability than anterior screw fixation, and they believe that Harms technique is probably the best choice for treating odontoid fractures in elderly. [20]Wagner et al 2017, studied the management of geriatric odontoid fractures in the literatures and found a lot of controversy and found that surgical intervention has been shown to improve functional outcomes when compared to non-surgical treatment, and they recommend posterior C1- C2 arthrodesis for geriatric type II odontoid fractures and the preferred treatment is C1 lateral mass and a C2 pars screw construct.[21] Munakomi et al 2016, reported the use of Anterior single odontoid screw in 15 patients with type II odontoid fracture being ideal option but with some modification on the usual approach as the use of

neuro-navigation or O-arm as the quality of C-arm images is an obstacle and they have some modifications as central small C2-3 discectomy to make sure they are exactly midline, With excellent outcome.[22]Anterior odontoid screw fixation can maintain cervical rotation, provides immediate stabilization and resulted in high fusion rates with rapid return to normal life.[23]We used in our case Bi-plane C-arm for AP open mouth and Lateral images with excellent outcome., our selection to anterior odontoid screw in this case because the fracture was oblique fracture extending from antero-superior to postero-inferior which was ideal to this technique to maintain the motion segment of C1-C2 complex instead posterior fusion which affect the mobility especially in axial rotation.

In our series we had a case of craniocervical junction infection proved to be cysticercosis, in our patient the patient presented at first with headache and dizziness and was diagnosed with hydrocephalic changes and being cysticercoid antibody positive, Albendazole therapy and shunt was done in other hospital, then presented to us with shunt malfunction with increasing symptoms one year later, with revision of shunt and repeated imaging, well-formed cyst at the craniocervical junction and fourth ventricle was seen, so suboccipital decompression and cyst removal was done with improved preoperative symptoms, the reason the shunt device was inserted at first because there was not yet a well formed cyst and presented with hydrocephalus from adhesions and granulation tissue from infection and once we noticed the well-formed cyst we removed it with suboccipital decompression and duroplasty with improvement of the preoperative symptoms. Wang et al 2015 reported a case with craniocervical junction with progressive loss of vision, headache and thoracic back pain and Chiari like symptoms with imaging showing obstructive hydrocephalus and cysticercosis cyst at the craniocervical junction and foramen magnum, they managed the case with suboccipital decompression and cyst removal and duroplasty and external ventricular drain which removed later without need for permanent CSF diversion and continued with Albendazole therapy.[24]

Also Amelot and Faillot 2014, reported 3 cases with Neurocysticercosis and the first case he presented had cystic lesion at the lower fourth ventricle and craniocervical removed surgically he explained direct relation of the cyst to hydrocephalic changes, and the other 2 cases shown calcifications in the occipital lobe and hydrocephalic changes, CSF diversion is inserted and he did explain other mechanisms for hydrocephalic changes as adhesions and inflammatory reactions to cysticercosis without finding of macroscopic parasitic cyst. [25]

In our presented study, we had one case with CVJ infection, after antibiotic course and follow up imaging we found it more favorable to the patient to drain the abscess by retropharyngeal submandibular approach and then in the same setting we did occipito cervical fusion posteriorly, the case was 45 years old and was intact complaining of worsening neck pain, with significant postoperative improvement. Goulart et al 2015 reported a 50 years old case of craniocervical junction instability following infection and retropharyngeal abscess managed by antibiotics at first, then developed deficit in hospital course then they did traction and then posterior craniocervical fusion with improvement of motor power and regain full strength back after 5 months. [26] Also, Xing et al 2016 concluded that the anterior cervical and retropharyngeal debridement combined with posterior occipito cervical fusion has been proved to be effective treatment of upper cervical tuberculosis, which plays an important role in removing the lesion, restoring stability, and anatomical reduction as they used this combine approach in eleven patients with upper cervical tuberculosis complicated with atlantoaxial dislocation. [27]

In our series, we had 10 patients underwent occipitocervical fusion with mean age of this series 51.4 years and 5 patients were males and the other 5 patients were females with different lesion in the craniocervical junction including: C2 infection (2 cases), Rheumatoid arthritis (1 case), old C2 odontoid fracture type 2 (2 cases), metastatic C2 lesion (1 case), C1 Jefferson fracture (1 case), Ehlerdanlossyndrome (1 case), os-odontoidum and klipplefiel syndrome (1 case), occipitoatlanto axial dissociation (1 case). Our results matched to the study of Tan et al, who reported 14 consecutive case of occipitocervical fixation 8 of them were men and 6 women with mean age 57 years and follow up 2 years were retrospectively reviewed, and the main indications for surgeries were rheumatoid in 6 cases and cervical metastasis in 4 cases with no neurologic deterioration in any of the cases or evidence of vertebral artery or spinal cord injury with one endured a superficial infection and two showed implant breakage and concluded that occipitocervical fixation is a viable option with favorable results in patients requiring stabilization of the craniocervical junction. [28]

Regarding to complications, none of the cases showed any neurological deterioration or vascular injury, although we had a case complicated with infection and hard ware removal, the case was rheumatoid arthritis with multi organ affection, osteoporosis and on high dose steroid therapy, infection of the wound, we removed the system and kept in hard collar, the second case was Jefferson fracture after lifting a heavy object and working out

with dumbbells four month after surgery patient felt severe neck pain and numbness in his hands, imaging showed failure of fusion of the occipitocervical fixation with hallow sign around screws and we had to revise and redo surgery with using neuro-navigation for cervical pedicle screws instead of lateral mass screws and augmentation of fusion.

Also, we had a case who developed tongue protrusion and dysarthria as hypoglossal nerve dysfunction after resection of large meningioma at the CVJ using far lateral approach although we had neurophysiological monitoring and cranial nerves were grossly intact, this may be due to manipulation during tumor removal affecting the function, the patient continued to improve by conservative treatment and speech therapy. Al-Mefty et al., reported that the most frequent surgical complications associated with far-lateral exposure for resection of FMMs are lower cranial nerves deficits, especially cranial nerves IX through XII. [29] Talacchi et al 2012, in a recently published series of 64 patients with ventral and ventrolateral FMMs, reported a high incidence of cranial nerve IX–X and XII dysfunctions postoperatively (44% and 33%, respectively). [30] At their final outcome assessment, however, 66% of the cranial nerve deficits had improved completely, and all but 2 patients had returned to normal productive life. Samii et al. 1996 reported an overall complication rate of 30%, with aspiration pneumonia occurring in 10% of the patients. [31] After multiple regression analysis, tumor recurrence, arachnoid scarring, degree of cranial extension, and absence of preoperative cranial nerve dysfunction were all significantly associated with an increased risk of aspiration pneumonia. [30][31]

5. Conclusion

- Posterior approach is safe and covers a wide range of management for most of the craniocervical junction lesions, and can be used to manage cases in need for either decompression as tumors posteriorly or poster laterally located or fusion for instability cases with minimal side effects.

- Anterior odontoid screw can be an alternative option to posterior C1-C2 fusion in selected recent odontoid fracture type II with oblique fracture and minimal displacement.

- Anterior retropharyngeal approach can be an option for accessing the craniocervical junction for either biopsy of lesion, drainage of abscess or other selected lesions.

- Far Lateral approach is the appropriate approach for anterior or anterolaterally located lesions and complications are common as cranial nerve dysfunction, use of Neuro-navigation, cranial nerves

monitoring and stimulation is helpful to decrease the risk of injury.

References:

1. Vender JR, McDonnell DE. Management of Lesions Involving the Craniocervical Junction. *Neurosurgery Quarterly* 2001; 11(2):151–171.
2. John IC, Menezes AH. Craniovertebral Abnormalities and Their Treatment. *Schmidek & Sweet Operative Neurosurgical techniques: Indications, Methodes and Results*, 2000; 2:1717–1728.
3. Dickman CA, Locantro J, Fessler RG. The influence of transoral odontoid resection on stability of the craniovertebral junction. *Journal of Neurosurgery* 1992; 77(4):525–530.
4. McDonnell DE. Anterolateral Cervical Approach To the Craniovertebral Junction. In: *Wilkins RH, Rengachary SS, eds. Neurosurgery*, McGraw-Hil. New York; 1996:136–153.
5. Bertalanffy H, Seeger W. The dorsolateral, suboccipital, transcondylar approach to the lower clivus and anterior portion of the craniocervical junction. *Neurosurgery* 1991; 29(6):815–821.
6. George B, Archilli M, Cornelius JF. Bone tumors at the cranio-cervical junction. Surgical management and results from a series of 41 cases. *Acta Neurochirurgica* 2006; 148(7):741–749.
7. Menezes AH. Decision making. *Child's Nervous System* 2008; 24(10):1147–1153.
8. Batzdorf U, McArthur DL, Bentson JR. Surgical treatment of Chiari malformation with and without syringomyelia: experience with 177 adult patients. *Journal of Neurosurgery* 2013; 118(2):232–242.
9. Goldschagg N, Feil K, Ihl F, et al. Decompression in Chiari Malformation: Clinical, Ocular Motor, Cerebellar, and Vestibular Outcome. *Frontiers in Neurology* 2017; 8.
10. Chotai S, Kshetry VR, Lamki T, Ammirati M. Surgical outcomes using wide suboccipital decompression for adult Chiari I malformation with and without syringomyelia. *Clinical Neurology and Neurosurgery* 2014; 120:129–135.
11. Baisden J. Controversies in Chiari I malformations. *Surgical Neurology International* 2012; 3(4):232.
12. Holly LT, Batzdorf U. Management of cerebellar ptosis following craniovertebral decompression for Chiari I malformation. *Journal of neurosurgery* 2001; 94(1):21–26.
13. Litvack ZN, Lindsay RA, Selden NR. Dura splitting decompression for Chiari I malformation in pediatric patients: Clinical outcomes, healthcare costs, and resource utilization. *Neurosurgery* 2013; 72(6):922–928.
14. Wolfs JFC, Peul WC, Boers M, et al. Rationale and design of The Delphi Trial--I (RCT)2: international randomized clinical trial of rheumatoid craniocervical treatment, an intervention-prognostic trial comparing “early” surgery with conservative treatment [ISRCTN65076841]. *BMC musculoskeletal disorders* 2006; 7:14.
15. Dührsen L, Emami P, Matschke J, Abboud T, Westphal M, Regelsberger J. Meningiomas of the Craniocervical Junction - A Distinctive Subgroup of Meningiomas. *PLoS ONE* 2016; 11(4).
16. Shiban E, Török E, Wostrack M, Meyer B, Lehmborg J. The far-lateral approach: destruction of the condyle does not necessarily result in clinically evident craniovertebral junction instability. *J Neurosurg* 2016; 125(July):196–201.
17. Ren XF, Xi YM, Zhang GQ, et al. Single-stage combined anterior retropharyngeal and posterior approach for the resection and reconstruction of C2 metastatic tumors: A case report. *Experimental and Therapeutic Medicine* 2014; 7(4):887–890.
18. Colak A, Kutlay M, Kibici K, Demircan MN, Akin ON. Two-staged operation on C2 neoplastic lesions: anterior excision and posterior stabilization. *Neurosurgical review* 2004; 27(3):189–193.
19. Falavigna A, Righesso O, da Silva PG, et al. Management of Type II Odontoid Fractures: Experience from Latin American Spine Centers. *World Neurosurgery* 2017; 98:673–681.
20. Faure A, Graillon T, Pesenti S, Tropiano P, Blondel B, Fuentes S. Trends in the surgical management of odontoid fractures in patients above 75 years of age: Retrospective study of 70 cases. *Orthopaedics & Traumatology: Surgery & Research* 2017.
21. Wagner SC, Schroeder GD, Kepler CK, et al. Controversies in the Management of Geriatric Odontoid Fractures. *Journal of Orthopaedic Trauma* 2017; 31(9):S44–S48.
22. Munakomi S, Tamrakar K, Chaudhary PK, Bhattarai B. Anterior single odontoid screw placement for type II odontoid fractures: our modified surgical technique and initial results in a cohort study of 15 patients. *F1000Research* 2016; 5(0):1681.
23. Dalvandi M, Mohamadi AR, Ahmadi SA. Anterior Single Lag Screw Fixation in Type II Odontoid Process Fractures: A Case Series with Literature Review. *Journal Of Iranian Clinical*

- Research* 2015; 1(2):62–66.
24. Wang DD, Huang MC. Cervicomedullary neurocysticercosis causing obstructive hydrocephalus. *Journal of Clinical Neuroscience* 2015; 22(9):1525–1528.
 25. Amelot A, Faillot T. Hydrocephalus and neurocysticercosis: Cases illustrative of three distinct mechanisms. *Journal of Clinical Neurology (Korea)* 2014; 10(4):363–366.
 26. Goulart CR, Mattei TA, Fiore ME, Thoman WJ, Mendel E. Retropharyngeal abscess with secondary osteomyelitis and epidural abscess: proposed pathophysiological mechanism of an underrecognized complication of unstable craniocervical injuries: case report. *J Neurosurg Spine* 2015; 24(January):1–9.
 27. Xing S, Gao Y, Gao K, Zhang G, Yu Z. Anterior Cervical Retropharyngeal Debridement Combined With Occipital Cervical Fusion to Upper Cervical Tuberculosis. *Spine* 2016; 41(2):104–110.
 28. Tan KJ, Hee HT. Neurological recovery after occipitocervical fixation. *Journal of orthopaedic surgery (Hong Kong)* 2007; 15(3):323–6.
 29. Arnautović KI, Al-Mefty O, Husain M. Ventral foramen magnum meningiomas. *Journal of neurosurgery* 2000; 92(1 Suppl):71–80.
 30. Talacchi A, Biroli A, Soda C, Masotto B, Bricolo A. Surgical management of ventral and ventrolateral foramen magnum meningiomas: report on a 64-case series and review of the literature. *Neurosurgical Review* 2012; 35(3):359–368.
 31. Samii M, Klekamp J, Carvalho G. Surgical Results for Meningiomas of the Craniocervical Junction. *Neurosurgery* 1996; 39(6):1086–1095.

1/4/2020