



## Functional and Structural Correlation in Wet Age Related Macular Degeneration after Ranibizumab Injection

Mai Barakat Al Helaly (MSCH), Tamer El-Sayed Wasfy (MD), Magdy Salah Moussa (MD), Yasser Ragab Serag (MD).

Ophthalmology Department, Faculty of Medicine, Tanta University, Tanta, Egypt

**Abstract: Background and aim:** Age related macular degeneration (AMD) is a major cause of visual impairment in the elderly in developed countries. Choroidal Neovascular Membrane (CNV) accounts for about 80% of severe vision loss in AMD patients. The aim of this study is to correlate macular structure assessed by optical coherence tomography (OCT) with macular function assessed by multifocal electroretinography (mfERG) and best corrected visual acuity (BCVA) in cases of neovascular age related macular degeneration (nvAMD) before and after intravitreal injection of Ranibizumab. **Patient and methods:** A prospective study was carried out on 30 eyes of 27 patients with nvAMD who underwent full ophthalmological evaluation including BCVA, macular SD-OCT and mfERG. Ellipsoid zone (EZ) was assessed at the fovea and 500 $\mu$  temporal, superior, nasal and inferior. mfERG responses were recorded in R1 and R2. BCVA, SD-OCT and mfERG were compared before and 1 month after 3 loading doses of intravitreal Ranibizumab injection. **Results:** BCVA improvement and EZ restoration were positively correlated but not statistically significant. Improvement of BCVA was correlated with the improvement in P1 response density and Avg P1+P2 amplitude in R1+R2. EZ restoration was associated with increased N1 amplitude in R1 and with increased Avg P1+P2 amplitude. BCVA and EZ were not correlated with P1 amplitude or P1 latency. **Conclusion:** mfERG is an objective test that has the potential to be used in the follow up of nvAMD cases after Ranibizumab injection.

[Mai Barakat Al Helaly, Tamer El-Sayed Wasfy, Magdy Salah Moussa, Yasser Ragab Serag. **Functional and Structural Correlation in Wet Age Related Macular Degeneration after Ranibizumab Injection.** *N Y Sci J* 2020;13(1):74-79]. ISSN 1554-0200 (print); ISSN 2375-723X (online). <http://www.sciencepub.net/newyork>. 10. doi:10.7537/marsnys130120.10.

**Key words:** neovascular age related macular degeneration, Ellipsoid zone, mfERG, BCVA

### 1. Introduction

Age-related macular degeneration (AMD) is a degenerative disorder affecting the macula. It was estimated that nearly 3 million people in the United States will suffer from AMD by 2020. AMD is classified into two general subgroups: non exudative and exudative forms of the disease. Although nvAMD is less prevalent than dry type, it is responsible for most cases of severe vision loss in AMD<sup>(1)</sup>.

The treatment of nvAMD has undergone major changes during the past decade. **The VEGF Inhibition Study in Ocular Neovascularization (VISION)** completed at the end of 2004 marked a new era for the treatment of nvAMD<sup>(2)</sup>. Ranibizumab is a humanized antigen-binding fragment (Fab) monoclonal antibody that binds VEGF-A its all isoforms and breakdown products. Ranibizumab was established as the first FDA-approved drug that prevents vision loss and improves vision in different subtypes of neovascular AMD<sup>(3)</sup>.

Optical coherence tomography (OCT) is one of the most commonly used imaging modalities in

ophthalmology. Since its appearance in 1991, OCT has developed greatly from Time domain (TD) OCT to spectral domain (SD) OCT. New techniques was developed to achieve better visualization of choroid. Thus, enhanced depth imaging (EDI) appeared to increase choroidal signal penetration<sup>(4)</sup>.

As OCT shows highly detailed information regarding the macula, it has become a cornerstone in decision making for the treatment and follow up of CNV in AMD cases. OCT also has a prognostic value as both severity of edema and photoreceptor integrity are correlated with final visual outcome. The central retinal thickness (CRT) has been widely used as a retreatment criteria in many clinical trials. However, reviews showed the poor reproducibility of CRT values. This aroused the need for other parameters in OCT for disease activity<sup>(5)</sup>.

mfERG is one of the electrophysiological test used to asses retinal function. mfERG was first developed by Sutter and Tran. mfERG allows topographic mapping of global retinal function. It allows studying disorders that affects the outer retinal

layers <sup>(6)</sup>. **Hood et al.** showed that the first-order response of the mfERG originates from photoreceptor and bipolar cells <sup>(7)</sup>. Studies performed in early AMD showed no significant affection of retinal function, while those performed in wet AMD showed reduced mfERG responses in AMD cases. mfERG responses remained largely unchanged in nvAMD cases after photodynamic therapy <sup>(8)</sup>.

Previous studies correlated the use of Ranibazumab in wet AMD patients with best corrected visual acuity (BCVA) as a subjective assessment of retinal function <sup>(9)</sup>. The use of mfERG was introduced recently for better objective study of retinal function.

#### **Aim**

The aim of this study is to correlate macular structure (ellipsoid zone (EZ)) assessed by optical coherence tomography (OCT) with function assessed by multifocal electroretinography (mfERG) and best corrected visual acuity (BCVA) in cases with neovascular age related macular degeneration (nvAMD) before and after intravitreal injection of Ranibazumab (antiVEGF).

## **2. Patient and methods**

A prospective study was carried out on 30 eyes of 27 patients attending ophthalmology outpatient clinic in Tanta University Hospital during the period of this study. Patients were diagnosed clinically as having neovascular AMD and confirmed by a recent fundus fluorescein angiography. Patients who have any other retinal diseases as diabetic retinopathy, performed previous intraocular intervention as intravitreal injection or laser, suffered from media opacity as dense cataract that could prevent imaging and those with BCVA less than 1/60 Patients or with macular scar following nvAMD were excluded from study. the study was performed in accordance with the declaration of Helsinki and its last amendment and was approved by the ethical committee of Faculty of medicine, Tanta university.

All patients received complete explanation of the nature and purpose of the study. An informed written consent was obtained from all participants in the research before inclusion. Names of the participants were hidden and replaced by a code number to maintain data privacy.

All participants were subjected to complete history taking. Also complete ophthalmological examination included measurement of best corrected visual acuity (BCVA) in logMAR notation, anterior segment examination using slit lamp biomicroscopy and posterior segment examination using indirect ophthalmoscopy and slit lamp biomicroscopy using +78.00 D Volk lens. Finally, adequate pharmacological mydriasis using a combination of cyclopentolate 1%, and phenylephrine 10%, was done

to perform fundus fluorescein angiography (FFA) imaging on Zeiss Visucam fundus camera (Carl Zeiss Meditec, Germany), and Optical Coherence Tomography (OCT) was done using a spectral domain OCT device Spectralis (Heidelberg Engineering, Heidelberg Germany). Horizontal and vertical line scans were performed using spectral domain OCT scan at macular region centered on the fovea. Macular ETDRS map analysis was used to measure Central foveal thickness (CFT). Ellipsoid zone (EZ) was determined at 5 regions including; fovea, 500µm superior, 500µm nasal, 500µm inferior and 500µm temporal parafoveal regions. Areas with intact EZ were described as X while others with absent EZ were described as Y. Data from 5 zones were analyzed and EZ was divided into 3groups **I** for intact, **D** for interrupted and **A** for absent EZ. Tracking technology was used in follow up images. Pre injection images were set as reference to insure precise follow up location.

mfERG was performed using Retimax System for Ocular Electrophysiology (RETIMAX advanced plus, C.S.O. srl (Firenze) – Italy according to the International Society for Clinical Electrophysiology of Vision (ISCEV) guidelines <sup>(10)</sup>. The stimulus consisted of 61 hexagonal elements, which switched on and off according to pseudorandom binary sequence. The procedure was explained clearly to all patients before testing. Pupil dilatation  $\geq 6$ mm was insured. All the patients were exposed to ordinary room lighting 15 min prior to test and full optical correction is used. The eye not under test was covered. The distance of examination was set at 30 cm. Under local anesthesia, activity of retina was recorded using HKLOOP Electrodes. Test was performed under dim light and repeated twice to insure that reproducible measures could be obtained. Data from mfERG was obtained from 2 central rings, R1 corresponding to the central 8° of the retina; R2 corresponding to area located between 8° and 24° representing fovea and parafoveal zone respectively. mfERG parameters including P1 amplitude, P1 implicit time, N1 amplitude, P1 response density and Average P1+P2 amplitude in R1+R2respectively were correlated with OCT and BCVA.

All the patients received 3 loading doses of intravitreal injection of 0.5 mg Ranibizumab (Lucentis) 4weeks apart as a part of their treatment protocol followed in Tanta university hospital. They were observed 1month later following last injection and BCVA, OCT and mfERG were repeated.

#### **Statistical analysis**

Data were analyzed using IBM SPSS version 20.0. (Armonk, NY: IBM Corp). Qualitative data were described using number and percentage. The Kolmogorov-Smirnov test was used to verify the

normality of distribution. Quantitative data were described using range (minimum and maximum), mean, standard deviation (SD) and median. Significance of the obtained results was judged at the 5% level.

### 3. Results

The mean age of the participants was  $70.27 \pm 8.00$ ys. Of them, 40.8% were males and 59.2% were females. Three patients had bilateral nvAMD. Seventeen patients had the Rt eye affected, while

seven patients had the Lt eye affected. According to CNV site based on FFA: 15 eyes had subfoveal, 12 eyes had juxtafoveal and 3 eyes had extrafoveal CNV.

After intravitreal Anti-VEGF, BCVA (LogMAR) showed a statistically significant improvement (P value  $<0.001$ ) with mean improvement ( $0.21 \pm 0.20$ ). Central foveal thickness (CFT) measured by SD-OCT showed also a statistically significant reduction (p  $<0.001$ ) and mean reduction of CFT ( $-146.0 \pm 148.78$ ). (Table 1).

**Table 1: Comparison between pre injection and 1 month post 3rd injection regarding BCVA & CFT (n = 30)**

|                                 | BCVA                 |                 |                 | CFT                  |                     |                     |
|---------------------------------|----------------------|-----------------|-----------------|----------------------|---------------------|---------------------|
|                                 | pre                  | post            | improvement     | pre                  | post                | improvement         |
| <b>Min – Max</b>                | 2.0 – 0.3            | 2.0 – 0.2       | 0.70 – 0.0      | 178.0– 1101.0        | 173.0 – 593.0       | -591.0 – -5.0       |
| <b>Mean <math>\pm</math> SD</b> | $1.39 \pm 0.65$      | $1.18 \pm 0.70$ | $0.21 \pm 0.20$ | $492.07 \pm 221.76$  | $346.07 \pm 139.32$ | $-146.0 \pm 148.78$ |
| <b>Median</b>                   | 1.30                 | 1.10            | 0.20            | 452.0                | 282.0               | -108.0              |
| <b>Z (p)</b>                    | 3.962* ( $<0.001$ *) |                 |                 | 4.784* ( $<0.001$ *) |                     |                     |

t: Paired t-test p: p value for comparing between pre and post\*: Statistically significant at  $p \leq 0.05$

The EZ showed significant changes after the injection. EZ was intact in 8 patients (26.7%), interrupted in 18 (60.0%) and absent in 4 (13.3%) with P value of improvement in comparison with Pre

injection  $<0.001$ . EZ analysis in 5 different zones showed statistically significant improvement of EZ at fovea (zone 1) with p value  $<0.001$  denoting restoration of EZ at fovea. (Table 2, p value  $<0.001$ ).

**Table 2: Distribution of the studied cases according to total Ellipsoid zone change. (n = 30)**

| OCT ellipsoid zone | Pre |      | Post |      | MH     | p          |
|--------------------|-----|------|------|------|--------|------------|
|                    | No. | %    | No.  | %    |        |            |
| Intact             | 0   | 0.0  | 8    | 26.7 |        |            |
| Disrupted          | 16  | 53.3 | 18   | 60.0 | 2.121* | $<0.001$ * |
| Absent             | 14  | 46.7 | 4    | 13.3 |        |            |

MH: Marginal Homogeneity Test p: p value for comparing between **pre** and **post** \*: Statistically significant at  $p \leq 0.05$

mfERG showed significant improvement in all parameters included in study after Ranibazumab injection. P1 amplitude showed significant increase with mean increase (0.41) (P  $<0.001$ ). The improvement in the Average P1+P2 amplitude, N1 amplitude were also statistically significant (P  $<0.001$ ). The mean increase in R1 response density was  $29.39 \mu\text{v}/\text{deg}^2$  and was statistically significant (p  $<0.001$ ). On the other hand, P1 implicit time showed a statistically significant reduction p value  $<0.001$ . The mean reduction in P1 implicit time was (5.83).

#### Correlation between variables:

The positive correlation between change in BCVA and change in Average P1+P2 amplitude was statistically significant (p  $<0.002$ ). BCVA was also positively and significantly correlated with Response

density at R1 (P value 0.021). Moreover, positive correlation was detected between BCVA, EZ, P1 amplitude and N1 amplitude. BCVA was negatively correlated with P1 implicit time but none of them was statistically significant. P value was 0.097, 0.102, 0.671 and 0.581 respectively.

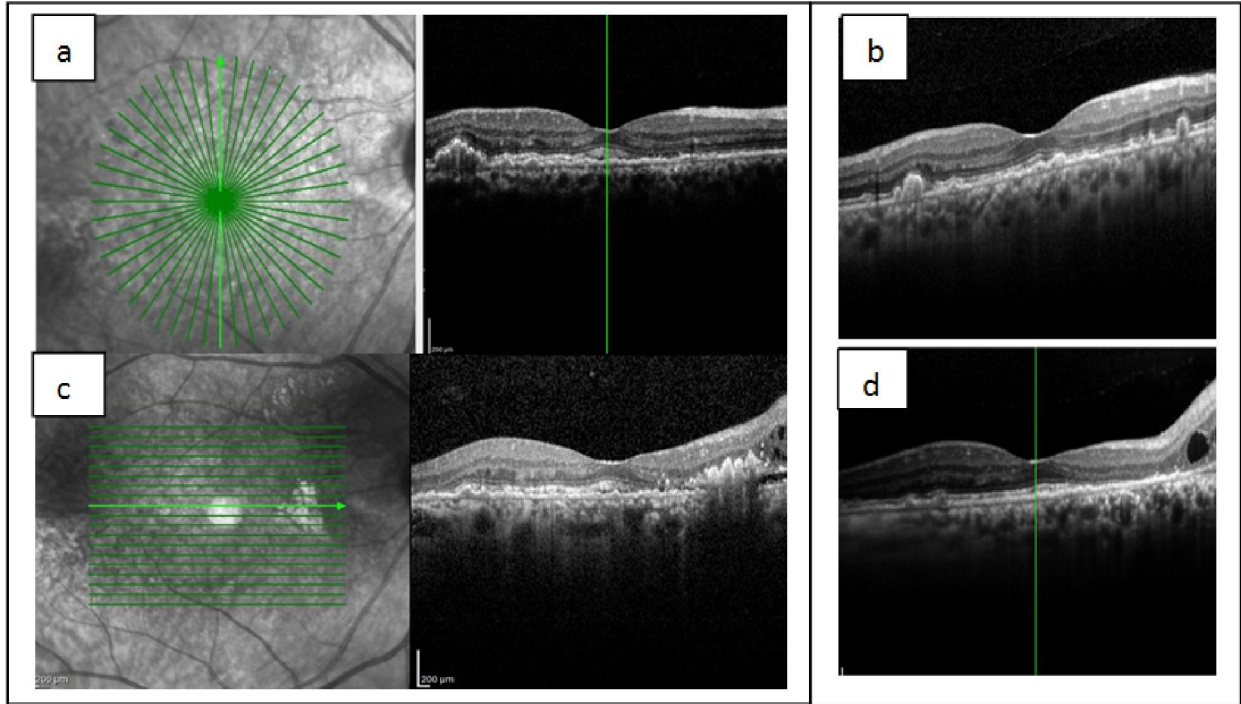
A statistically significant positive correlation (P 0.024) was found between foveal EZ and improvement in N1 amplitude. Foveal EZ was also positively and significantly correlated with average amplitude of P1+P2 (P value  $<0.001$ ).

Foveal EZ also positively correlated with Amplitude of P1, Amp of N1 and R1 response density and negatively correlated with P1 implicit time but it wasn't statistically significant. (Table 3).

**Table (3): Correlation between BCVA, OCT & mfERG parameters regarding improvement (n = 30)**

|               |                | EZ foveal | P1     | N1     | Avg.P1+P2 amplitude | P1 Implicit time | R1 response Density |
|---------------|----------------|-----------|--------|--------|---------------------|------------------|---------------------|
| BCVA          | r <sub>s</sub> | -0.63     | -0.304 | 0.081  | -0.542              | -0.105           | -0.421              |
|               | p              | 0.097     | 0.102  | 0.671  | 0.002*              | 0.581            | 0.021*              |
| OCT/EZ foveal | r <sub>s</sub> |           | 0.236  | 0.411  | 0.779               | -0.018           | 0.111               |
|               | p              |           | 0.209  | 0.024* | <0.001*             | 0.925            | 0.560               |
| ERG P1        | r <sub>s</sub> |           |        | -0.268 | 0.096               | 0.029            | -0.116              |
|               | p              |           |        | 0.152  | 0.612               | 0.881            | 0.541               |

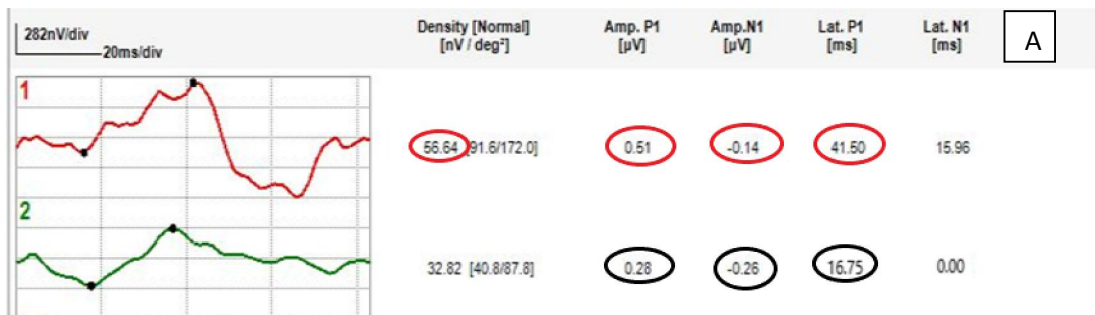
r<sub>s</sub>: Spearman coefficient \*: Statistically significant at p ≤ 0.05

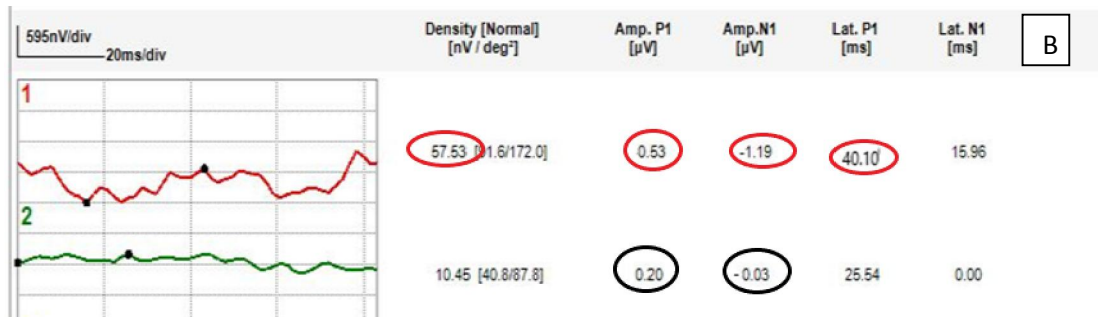


**Figure 1: SD-OCT in nvAMD, (a & c) before injection, (b & d) after injection.**

OCT before injection showings: subretinal and intraretinal fluid denoting CNV activity. EZ was disrupted in both vertical and horizontal scans. OCT also showed lower PED, after the injection: OCT

showed dry macula with restoration of normal EZ except nasally in horizontal scan where EZ was totally absent. Note decrease PED size in vertical scan





**Figure 2:** Ring analysis in mfERG (R1, R2), (A) before injection, (B) after injection mfERG after injection showings improved central ring in comparison to before injection, while the 2nd ring that corresponds to the perifoveal affected area with absent EZ, shows decreased response after injection.

#### 4. Discussion

Multiple studies correlated EZ integrity and final BCVA after anti-VEGF therapy in nvAMD. **Chhablani et al (2013)** stated that the integrity of both the IS/OS junction and ELM can predict the BCVA after treatment of wet AMD with bevacizumab<sup>(11)</sup>. Positive correlation was detected in current study between BCVA improvement and the change in EZ after intravitreal injection but it wasn't statistically significant ( P value =0.097). This finding can be explained by relatively small number of cases included in current study.

Interestingly, 2 cases in our study had almost complete loss of EZ that didn't improve after injection. Regardless, patient had adequate VA and even VA improved after injection. The same finding was detected by **Landa et al (2011)** in dry AMD cases where even after almost complete loss (90-100%) of IS-OS layer, many patients maintained BCVA of 20/40 and better<sup>(12)</sup>. This can be explained that EZ is not the only factor affecting visual acuity. Moreover, other retinal layers as ELM was superior to EZ as a predictor for visual outcome in other studies<sup>(13)</sup>.

Positive correlation in current study between BCVA and P1 response density with P value 0.021. These findings were consistent with those detected by **Campa et al (2011)** with P value <0.001<sup>(14)</sup>. BCVA was also strongly correlated with Avg P1+P2 amplitude in R1+R2 with P value 0.002. These findings matched results in study by **Flores □ Moreno et al (2017)** they found that better BCVA was correlated with the average of P1+P2 amplitude in R1 + R2 (P = 0.032)<sup>(15)</sup>.

Current study didn't find significant correlation between BCVA and P1 amplitude. This finding matched results detected in **Reinsberg et al (2017)** they explained that lack of P1 value correlation was due to unstable fixation during the measurements<sup>(16)</sup>, which is a problem in subjects with nvAMD and could be responsible for current findings also.

A statistically significant positive correlation between EZ and N1 amplitude in R1 was detected ( P

value=0.024). We also detected a strong positive correlation between EZ and Avg P1+P2 amplitude with P value <0.001. No correlation was detected between P1 amplitude or P1 implicit time with EZ in this study. **Wu et al (2013)** results was partially matching with our findings. They detected that The relative intensity of the EZ was correlated significantly with the mfERG P1 implicit time ( $r = -0.745$ ,  $P < 0.001$ )<sup>(17)</sup>, which couldn't be proved by our findings. While EZ didn't correlate with P1 amplitude ( $r = 0.144$ ,  $P = 0.281$ ) which is similar to current study results. We acknowledge other limitations of current study. The small number of cases is a major one. Also, assessment of EZ integrity was done subjectively. Poor fixation stability in nvAMD cases as a part of nature of disease was also a great obstacle against production of repeatable and reproducible results in mfERG in some cases.

#### Conclusion

Multifocal electroretinogram is an objective functional test that was found to be correlated with structure assessed by optical coherence tomography and the subjective function in the form of best corrected visual acuity in neovascular age related macular degeneration before and one month after three intravitreal injections of Ranibizumab. mfERG has the potential to be used as a follow up tool in nvAMD cases after Ranibizumab injection.

#### Financial support and sponsorship

Nil

#### Conflicts of interest

There are no conflicts of interest

#### References

1. Klein R, Klein BEK. The prevalence of age-related eye diseases and visual impairment in aging: current estimates. Invest Ophthalmol Vis Sci. 2013;54(14): ORSF5-ORSF13.

2. Gragoudas ES, Adamis AP, Cunningham ET, Jr., Feinsod M, Guyer DR. Pegaptanib for neovascular age-related macular degeneration. *NEJM*. 2004;351(27):2805-16.
3. Ferrara N, Damico L, Shams N, Lowman H, Kim R. Development of ranibizumab, an anti-vascular endothelial growth factor antigen binding fragment, as therapy for neovascular age-related macular degeneration. *Retina*. 2006;26(8):859-70.
4. de Boer JF, Leitgeb R, Wojtkowski M. Twenty-five years of optical coherence tomography: the paradigm shift in sensitivity and speed provided by Fourier domain OCT [Invited]. *Biomedical Optics Express*. 2017;8(7):3248-80.
5. Schmidt-Erfurth U, Chong V, Loewenstein A, Larsen M, Souied E, Schlingemann R, et al. Guidelines for the management of neovascular age-related macular degeneration by the European Society of Retina Specialists (EURETINA). *The BR J OPHTHALMOL*. 2014;98(9):1144-67.
6. Sutter EE, Tran D. The field topography of ERG components in man--I. The photopic luminance response. *Vision research*. 1992;32(3):433-46.
7. Hood DC. Assessing retinal function with the multifocal technique. *Prog Retin Eye Res*. 2000;19(5):607-46.
8. Feigl B, Brown B, Lovie-Kitchin J, Swann P. Monitoring retinal function in early age-related maculopathy: visual performance after 1 year. *Eye (London, England)*. 2005;19(11):1169-77.
9. Schauwvlieghe AME, Dijkman G, Hoymans JM, Verbraak FD, Hoyng CB, Dijkgraaf MGW, et al. Comparing the Effectiveness of Bevacizumab to Ranibizumab in Patients with Exudative Age-Related Macular Degeneration. The BRAMD Study. *PLoS ONE*. 2016;11(5):e0153052.
10. Hood DC, Bach M, Brigell M, Keating D, Kondo M, Lyons JS, et al. ISCEV standard for clinical multifocal electroretinography (mfERG) (2011 edition). *Documenta Ophthalmologica*. 2012;124(1):1-13.
11. Chhablani J, Kim JS, Freeman WR, Kozak I, Wang HY, Cheng L. Predictors of visual outcome in eyes with choroidal neovascularization secondary to age related macular degeneration treated with intravitreal bevacizumab monotherapy. *Int. J. Ophthalmol*. 2013;6(1):62-6.
12. Landa G, Su E, Garcia PM, Seiple WH, Rosen RB. Inner segment-outer segment junctional layer integrity and corresponding retinal sensitivity in dry and wet forms of age-related macular degeneration. *Retina*. 2011;31(2):364-70.
13. Coscas F, Coscas G, Lupidi M, Dirani A, Srour M, Semoun O, et al. Restoration of Outer Retinal Layers After Aflibercept Therapy in Exudative AMD: Prognostic Value. *Invest Ophthalmol Vis Sci*. 2015;56(6):4129-34.
14. Campa C, Hagan R, Sahni JN, Brown MC, Beare NA, Heimann H, et al. Early multifocal electroretinogram findings during intravitreal ranibizumab treatment for neovascular age-related macular degeneration. *Invest Ophthalmol Vis Sci*. 2011;52(6):3446-51.
15. Flores-Moreno I, Arias-Barquet L, Rubio-Caso MJ, Munoz-Blanco A, Vidal-Marti M, Catala-Mora J, et al. Structure versus function: correlation between outer retinal and choroidal thicknesses measured by swept-source OCT with multifocal electroretinography and visual acuity. *Int J Retina Vitreous*. 2017;3:29.
16. Reinsberg M, Hilgers R-D, Lüdeke I, Nassar K, Grisanti S, Grisanti S, et al. Testing the clinical value of multifocal electroretinography and microperimetry and the effects of intravitreal therapy with ranibizumab on macular function in the course of wet age-related macular degeneration: a 1-year prospective study. *Clinical ophthalmology (Auckland, NZ)*. 2017;11:621-9.
17. Wu Z, Ayton LN, Guymer RH, Luu CD. Relationship between the second reflective band on optical coherence tomography and multifocal electroretinography in age-related macular degeneration. *Invest Ophthalmol Vis Sci*. 2013;54(4):2800-6.

12/25/2019