



Hysteroscopy versus 3D Ultrasound in detecting uterine cavity abnormalities in infertile patients with Endometriosis

Islam Ibrahim Mashaal, M.Sc.; Safaa Kamal Marei, M.D.; Manal Fathy Hamisa, M.D. and Mohamed Ahmed Talat El Sharawy, M.D.

Department of Obstetrics and Gynecology, Faculty of Medicine, Tanta University, Egypt

Abstract: Objective: The objective of this study is to compare hysteroscopy versus 3D ultrasound, in detecting abnormal uterine cavity lesions in infertile women suffering from endometriosis. **Study design:** 3DTVUS was done followed by hysteroscopy for all cases (number=50). Data obtained were compared and analyzed to estimate the accuracy of 3DTVUS. **Results:** There was statistically significant agreement between 3D ultrasonography and hysteroscope in overall diagnosis of abnormal uterine findings (P value <0.001 and Kappa 0.794). As regards prediction of uterine anomalies, 3D U/S showed 73.7% sensitivity, 100% specificity, 100% positive predictive value (PPV), 89.7% negative predictive value (NPV), and 92% test accuracy. **Conclusion:** The 3D TVS is a sensitive method to diagnose the endometrial cavity lesions or abnormalities. It is relatively inexpensive, is not time-consuming, non-invasive and can be performed in settings. 3D sonography has a high level of accuracy for most uterine anomalies. Thus, routine use of three dimensional transvaginal ultrasound is a sensitive method to evaluate the endometrial cavity lesions or abnormalities, before resorting to invasive procedures such as hysteroscopy. Hysteroscopy should be resorted to in cases of doubtful lesions as it can detect small intrauterine lesions which could be missed by TVS. Moreover, hysteroscopy is the gold standard for evaluation of uterine causes of infertility as it allows direct visualization of the uterine cavity.

[Islam Ibrahim Mashaal, Safaa Kamal Marei, Manal Fathy Hamisa, and Mohamed Ahmed Talat El Sharawy. **Hysteroscopy versus 3D Ultrasound in detecting uterine cavity abnormalities in infertile patients with Endometriosis.** *N Y Sci J* 2020;13(1):56-66]. ISSN 1554-0200 (print); ISSN 2375-723X (online). <http://www.sciencepub.net/newyork>. 8. doi:[10.7537/marsnys130120.08](https://doi.org/10.7537/marsnys130120.08).

Keywords: 3DTVUS, hysteroscopy, uterine cavity, Endometriosis

1. Introduction

Endometriosis which is the presence of endometrial-like tissue (glands and stroma) outside the uterus induces a chronic inflammatory reaction, scar tissue, and adhesions that may distort a woman's pelvic anatomy. 10% of women during the reproductive years are complaining of endometriosis (1, 2).

More recent data indicates that the incidence of endometriosis has not increased in the last 30 years and remains at 2.37–2.49/1000/y, which equates to an approximate prevalence of 6–8%. The age between 25 and 29 years are the commonly presented age group (1, 3).

The most common symptoms are pain, infertility, or both, the frequency is 35–50%. Interference with oocyte development or early embryogenesis or reduced endometrial receptivity is the most common etiology of infertility. Also, several studies have suggested impairment of implantation which may be due to intrinsic deficiencies within the uterus (4-7).

Endometrial polyps are common gynecological disorders whose prevalence is increased in infertile

women. The intrinsic pathogenesis of these polyps can suggest a possible association. Other gynecological disorders and anatomical uterine malformations are also linked to endometriosis (8-10).

Uterine septum, the most common Mullerian duct anomaly, results in colicky uterine peristalsis and increased menstrual regurgitation through the fallopian tubes and endometriosis disseminated through the pelvic cavity. Hypoplastic uterus, a rare anomaly, may be also associated (11-13).

Both hysterosalpingogram and transvaginal ultrasonography are used to diagnose endometrial lesions but sometimes they are not enough. Hysteroscopy, the gold standard for evaluation of uterine causes of infertility, can detect small lesions that might not otherwise be detected by other methods (11, 14).

With 3D transvaginal ultrasound we obtain images in seconds without requiring contrast media. It does not require specific menstrual days. It is not painful and shows the front view of the uterus and all uterine layers. It is cheaper than other techniques. It also allows 3D vision of normal and pathological

morphology of vagina, cervix, uterus, tubes and ovaries (15, 16)

Aim of study

The objective of this study is to compare hysteroscopy versus 3D ultrasound, in detecting abnormal uterine cavity lesions in infertile women suffering from endometriosis.

2. Patients and Methods:-

This prospective observational study was conducted on (50) patients who attended inpatient and outpatient clinics in the department of Obstetrics & Gynecology in Tanta University Hospitals.

Criteria of patient selection:

Inclusion criteria were as follows:

Age between 20 to 40 years old.

Infertility.

Endometriosis diagnosed by laparoscopy (discrete endometriotic lesions, endometriomas, or adhesions) or transvaginal ultrasonography for endometriomas (cystic lesion with low level internal echoes, occasional thick septations and thickened wall).

Exclusion criteria were as follows:

History of any previous intrauterine cavity procedures.

History of any previous abdominal surgery.

Receiving any hormonal treatment in previous 6 months.

All patients were subjected to the following:

An informed written consent was obtained from all participants in this research. All patients submitted to the study were counseled thoroughly about the procedure including its value and hazards, and the aim of the study.

Full history taking with special inquiry about (age, gravidity, parity, menstrual history and previous surgery).

General, abdominal and pelvic examination including (bimanual assessment of the uterine size, position, mobility, adenexal evaluation and any cervical or vaginal abnormalities).

There was no classification of the patients according to their religion, culture, race or any other unrelated points in that study.

Methods:

(A) Transvaginal ultrasonography (TVS):

The ultrasonographic examinations were performed with Samsung H 60 using vaginal transducer with a frequency of 6.5 MHz and a CD facility (Samsung- Korea). Ultrasound was performed in the mid to late proliferative phase of the menstrual cycle.

The patient was asked to evacuate the bladder before examination. Then, examination was performed in the supine position with the knees flexed and the

lower limbs abducted. The probe was introduced into the vagina covered with a condom filled and covered with echo gel.

The uterus was examined in longitudinal & transverse planes (2D transvaginal ultrasound) and the 3 coronal planes (3D transvaginal ultrasound) by (the same probe) with changing the system to measure its diameters (length, width, height, volume, cervical length), endometrial thickness, and any suspected focal lesions appeared during the scan were determined. Adnexa was also examined. Scanned volume of the uterus was evaluated in multiplanar 3D and Multi-Slice View mode.

Once the B-mode was completed three-dimensional volume was recorded. The volume of the uterus was generated by the automatic rotation of the mechanical transducer 360 degrees. The probe was kept steady, the patient was asked to hold breath and volume mode was switched on. With the use of the medium line density, the typical acquisition time was between 4 and 10 seconds. Relation of any focal lesion (myoma or polyp) to the endometrium in the three planes was determined with their dimensions.

Steps of image evaluation:

1st opening and generating a region of interest box (ROI) on 2D ultrasound image.

2nd detecting contour of target object in (ROI) box.

3rd forming a 3D ultrasound image by rendering volume data existing in the detected contour.

(B) performing diagnostic hysteroscopy for the patients:

Patient under general anesthesia. The patient was placed in the dorsal lithotomy position then prepared and draped in a sterile manner. The patient's thighs were positioned at a 90° angle to the pelvis to create enough space to manipulate the hysteroscopy.

The patient's perineum just past the edge of the table, with the coccyx and sacrum well supported on the flat surface of the table. The patient's legs were secured in the leg stirrups to avoid any abrupt movements, which can cause nerve or muscle injury to the patient.

The surgeon seated with the operative field and hysteroscopy at the level of his abdomen. The bladder was emptied with a metal catheter by using sterile technique. Then bimanual examination performed before manipulation. If the cervix wide enough to insert the hysteroscopy, there was no need for dilatation, if not, cervical dilatation was needed. the cervix was dilated with hegar dilators to the same diameter as the outer diameter of the outer sheath of the hysteroscopy setup. A single-toothed or double toothed vollselum was placed on the anterior lip of the cervix while dilating to help straighten the cervix and uterus.

After the cervix is dilated, the hysteroscopy was inserted into the endocervical canal and advanced into the uterine cavity (with the distention medium flowing) under direct visualization to limit the risk of perforation. The volselum on the cervix was left in place to help in manipulating the uterus, and the vaginal speculum was removed to increase range of movement of the hysteroscope. Normal saline solution was used as a distention media and was instilled under the pressure of conventional blood pressure cuff. The hysteroscope was then gently introduced through cervical canal, internal os, and then into the uterine cavity.

Upon entering the uterine cavity, a systematic inspection was performed, including the uterine cornu, tubal ostia, uterine fundus, and lateral, anterior and posterior uterine walls.

Hysteroscopy findings were documented on a case record form. Appearance of cervical canal and endometrium and presence, size, and location of structural anomalies were recorded. In case of positive findings for uterine cavity lesion, surgical management options were done on the same setting.

Statistical Analysis:-

Once data was collected, a code sheet was developed. Organization, tabulation, presentation and analysis of data were performed by using SPSS V25 of IBM, USA.

Quantitative data (e.g. age) was presented as mean, standard deviation (SD) and range. Categorical data was presented as number and percentage (%).

The level of significance was adopted at p<0.05.

1- Mean value (X):

The sum of all observations divided by the number of observations

2- Standard Deviations (S.D.):

It measures the degree of scatter of individual varieties around their mean.

3- Evaluation of Diagnostic Prediction:

a) Diagnostic sensitivity:

It measures the incidence of true positive results in patients' groups.

$$Sensitivity = \frac{TP}{TP + FN} \times 100$$

Where: TP (true positive): number of diseased patients accurately classified by the test and, FN (false negative): number of diseased patients accurately misclassified by the test.

b) Diagnostic specificity:

It measures the incidence of true negative results in a non-diseased group.

$$Specificity = \frac{TN}{TN + FP} \times 100$$

Where: TN (true negative): number of non-diseased subjects correctly classified by the test, FP

(false positive): number of non-diseased patients misclassified by the test.

c) Positive Predictive value (PPV):

It is the percentage of true positive results among total positive results.

$$PPV = \frac{TP}{TP + FP} \times 100$$

d) Negative Predictive value (NPV):

It is the percentage of true negative results among total negative results.

$$NPV = \frac{TN}{TN + FN} \times 100$$

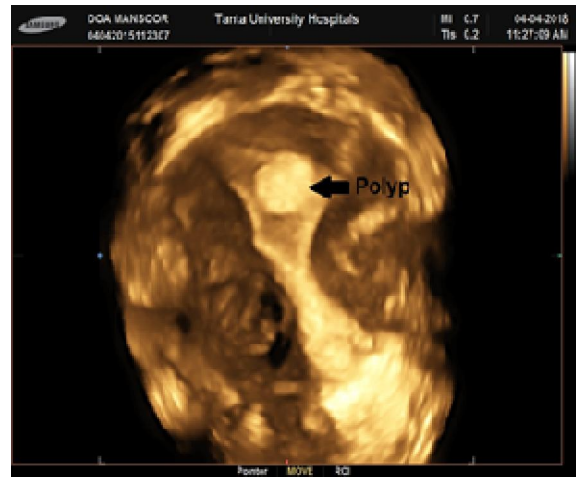
4- Inter-rater agreement analysis:

Kappa values < 0 indicates no agreement and 0–0.20 as slight, 0.21–0.40 as fair, 0.41–0.60 as moderate, 0.61–0.80 as substantial, and 0.81–1 as almost perfect agreement.

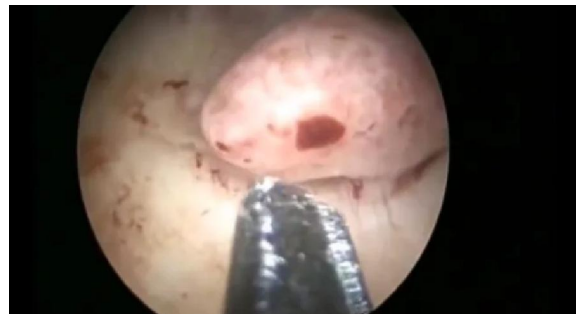Samples of lesions in selected cases

| | |
|--------------|-------------------|
| Age | 30 years old |
| Infertility | 1ry |
| 3DUSG | Endometrial Polyp |
| Hysteroscopy | Endometrial Polyp |

Final Diagnosis: Endometrial polyp



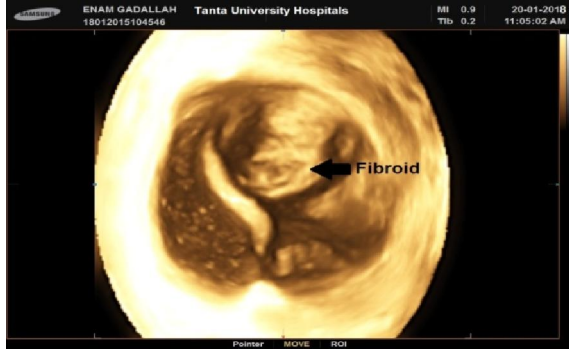
3D



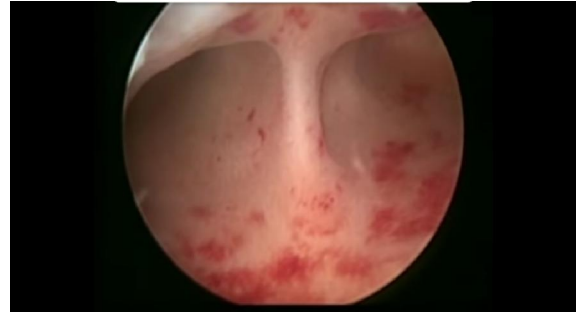
Hysteroscope

| | |
|--------------|--------------------|
| Age | 33 years old |
| Infertility | 2ry |
| 3DUSG | Sub-mucous Fibroid |
| Hysteroscopy | Sub-mucous Fibroid |

Final Diagnosis: Sub-mucous Fibroid



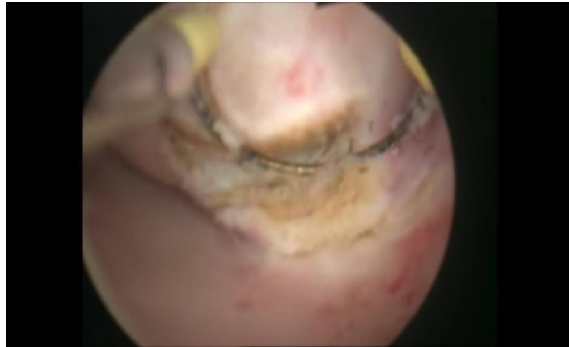3D



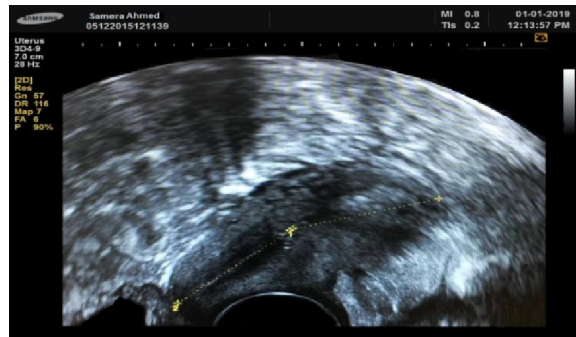
Hystroscope

| | |
|--------------|--------------------|
| Age | 22years old |
| Infertility | 1ry |
| 3DUSG | Hypoplastic uterus |
| Hysteroscopy | Small cavity |

Final Diagnosis: Hypoplastic uterus.



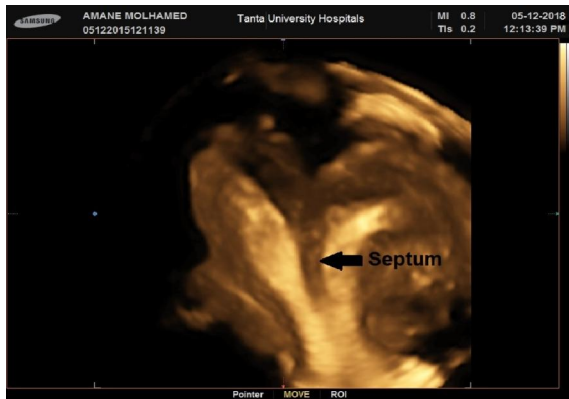
Hystroscope



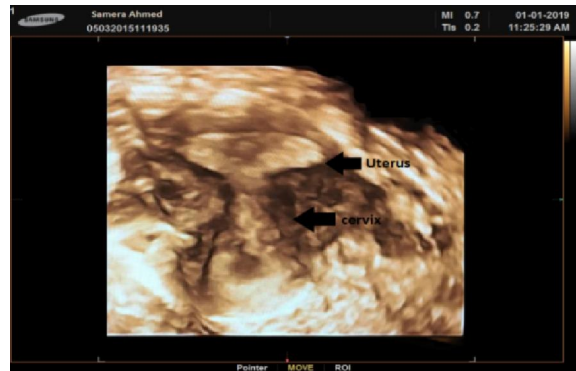
2D

| | |
|--------------|----------------|
| Age | 29years old |
| Infertility | 1ry |
| 3DUSG | Uterine Septum |
| Hysteroscopy | Uterine Septum |

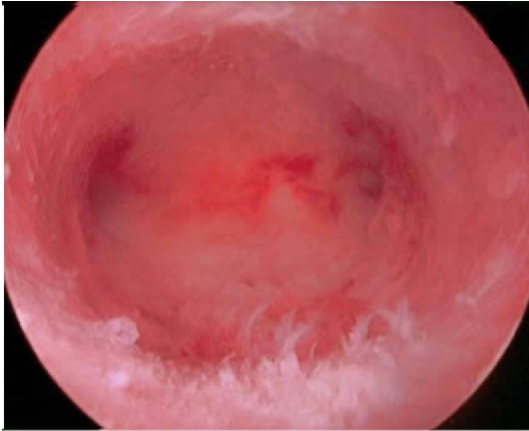
Final Diagnosis: Uterine Septum



3D



3D



Hysteroscopy

3. Results

This study was carried on 50 infertile patients with endometriosis who attended inpatient and outpatient Gynecology clinic in Tanta University Hospitals.

Table 1: The characteristic data of the studied patients:-

| | Age (years) | BMI (kg/m ²) |
|------------------------|--------------|--------------------------|
| Mean ± SD | 28.96 ± 5.52 | 26.76 ± 5.11 |
| Range (min-max) | 20 – 39 | 18 - 36 |

This table shows that the age of the studied patients ranged from 20-39 years with mean of 28.96±5.52 years and BMI ranged from 18 – 36 kg/m² with mean of 26.76 ± 5.11 kg/m².

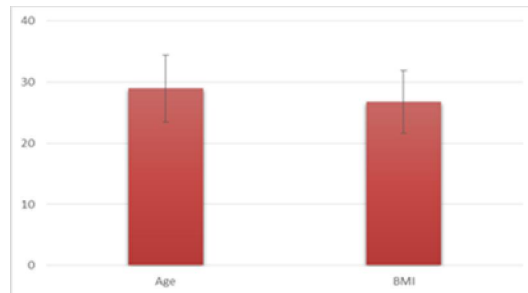


Figure 1: The characteristic data of the studied patients

Table 2: Infertility and presence of endometrioma in the studied patients:-

| | Infertility | | Endometrioma | | |
|-------------------|-------------|-----|----------------------|----------------------|--------|
| | 1ry | 2ry | With 1ry infertility | With 2ry infertility | Absent |
| Number | 39 | 11 | 32 | 6 | 12 |
| Percentage | 78% | 22% | 64% | 12% | 24% |

This table shows that 39 cases (78%) complained of 1ry infertility while 11 cases (22%) complained of 2ry infertility.

There were 38 cases (76%) that have endometriomas (32 cases with 1ry infertility and 6 cases with 2ry infertility) and 12 cases (24%) didn't have endometriomas.

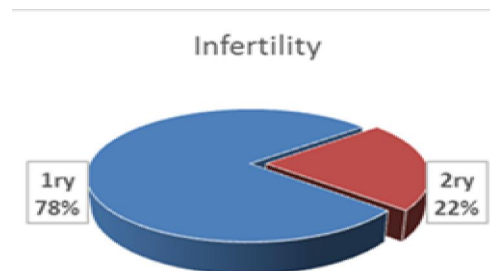


Figure 2: Infertility in the studied patients

Table 3: Overall diagnosis of uterine anomalies by hysteroscope and 3D ultrasonography:-

| | | Hysteroscope | | |
|---------|----------|--------------|----------|-----------|
| | | Negative | Positive | Total |
| 3D U/S | Negative | 35(70%) | 4(8%) | 39(78%) |
| | Positive | 0 | 11(22%) | 11(22%) |
| | Total | 35 (70%) | 15 (30%) | 50 (100%) |
| Kappa | | 0.794 | | |
| P value | | <0.001* | | |

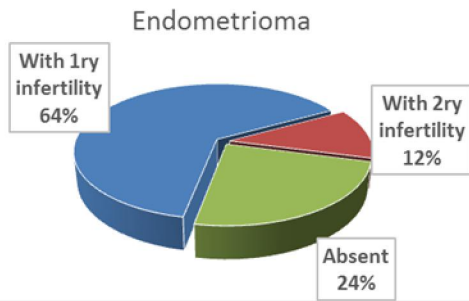


Figure 3: Endometrioma in the studied patients

This table shows that by 3D ultrasonography, there were abnormal uterine findings in 11 cases and this was confirmed by hysteroscopy (True positive), and on the contrary, 4 cases were completely normal by 3D ultrasonography but detected by hysteroscopy (False negative). All negative cases by hysteroscopy (35 cases) were b negative by 3D U/S (True negative). There were no false positive cases.

There was statistically significant agreement between 3D ultrasonography and hysteroscope in overall diagnosis of abnormal uterine findings (P value <0.001 and Kappa 0.794). As regards prediction of uterine anomalies, 3D U/S showed 73.7% sensitivity, 100% specificity, 100% positive predictive value (PPV), 89.7% negative predictive value (NPV), and 92% test accuracy.

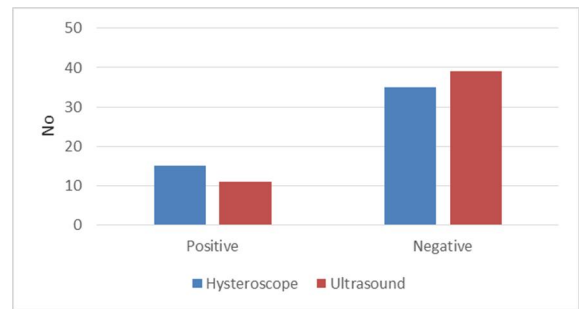


Figure 4: Illustrates table 3

Table 4: Endometrial polyps by hysteroscope and 3D ultrasonography:-

| | | Hysteroscope | | |
|---------|----------|--------------|----------|----------|
| | | Negative | Positive | Total |
| 3D U/S | Negative | 43(86%) | 2(4%) | 45(90%) |
| | Positive | 0(0%) | 5(10%) | 5(10%) |
| | Total | 43(86%) | 7(14%) | 50(100%) |
| Kappa | | 0.811 | | |
| P value | | <0.001* | | |

This table shows that by 3D ultrasonography, there were endometrial polyps in 5 cases and this was confirmed by hysteroscopy (True positive), and on the contrary, 2 cases were completely normal by 3D ultrasonography but detected by hysteroscopy (False negative). All negative cases by hysteroscopy (43 cases) were negative by 3D U/S (True negative). There were no false positive cases.

specificity, 100% positive predictive value (PPV), 95.6% negative predictive value and 96% accuracy.

There was statistically significant agreement between 3D ultrasonography and hysteroscope in diagnosis of endometrial polyps (P value <0.001 and Kappa is 0.811). As regards prediction of endometrial polyps, 3D U/S showed 71.4% sensitivity, 100%

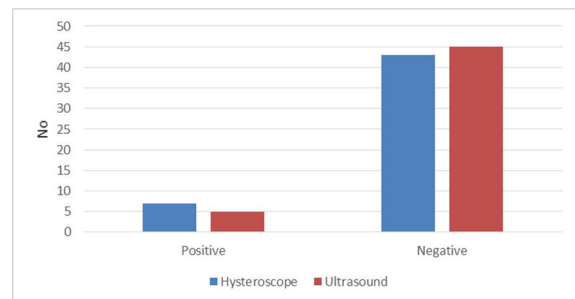


Figure 5: Illustrates table 4

Table 5: Uterine septum by hysteroscope and 3D ultrasonography:-

| | | Hysteroscope | | |
|---------|----------|--------------|----------|----------|
| | | Negative | Positive | Total |
| 3D U/S | Negative | 46(92%) | 2(4%) | 48(96%) |
| | Positive | 0(0%) | 2(4%) | 2(4%) |
| | Total | 46(92%) | 4(8%) | 50(100%) |
| Kappa | | 0.648 | | |
| P value | | <0.001* | | |

This table shows that by 3D ultrasonography, there was uterine septum in 2 cases, and this was confirmed by hysteroscopy (True positive), and on the contrary, 2 cases were completely normal by 3D ultrasonography but detected by hysteroscopy (False negative). All negative cases by hysteroscopy (46 cases) were negative by 3D U/S (True negative). There were no false positive cases.

There was statistically significant agreement between 3D ultrasonography and hysteroscope in diagnosis of uterine septum (P value <0.001 and Kappa 0.648). As regards prediction of uterine septum, 3D U/S showed 50% sensitivity, 100% specificity, 100% positive predictive value (PPV),

95.83% negative predictive value (NPV) & 96% accuracy.

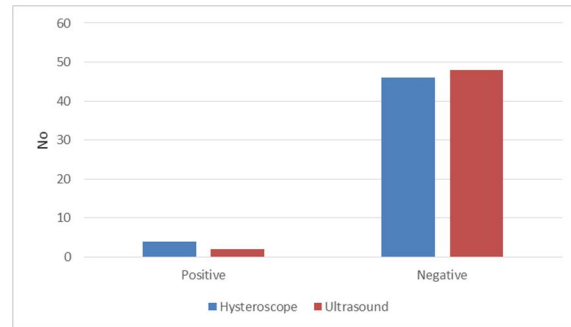


Figure 6: Illustrates table 5

Table 6: Hypoplastic uterus by hysteroscope and 3D ultrasonography:-

| | | Hysteroscope | | |
|---------|----------|--------------|----------|----------|
| | | Negative | Positive | Total |
| 3D U/S | Negative | 47(94%) | 0(0%) | 47(94%) |
| | Positive | 0(0%) | 3(6%) | 3(6%) |
| | Total | 47(94%) | 3(6%) | 50(100%) |
| Kappa | | 1 | | |
| P value | | <0.001* | | |

This table shows that all positive cases by hysteroscopy (3 cases) were positive by 3D U/S (True positive). All negative cases by hysteroscopy (47 cases) were negative by 3D U/S (True negative). There were no false positive nor false negative cases.

There was statistically significant agreement between 3D ultrasonography and hysteroscope in diagnosis of hypoplastic uterus P value <0.001 and Kappa is 1). As regards prediction of hypoplastic uterus, 3D U/S showed 100% sensitivity, specificity, PPV, NPV and test accuracy.

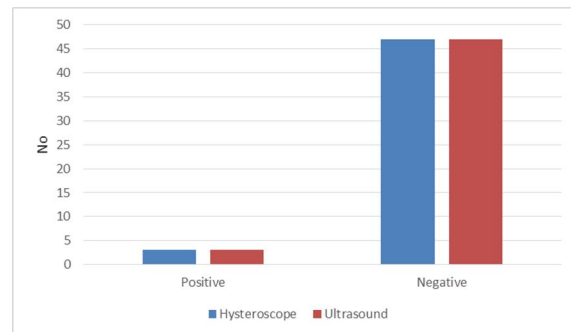


Figure 7: Illustrates table 6

Table 7: Submucous fibroid by hysteroscope and 3D ultrasonography:-

| | | Hysteroscope | | |
|---------|----------|--------------|----------|----------|
| | | Negative | Positive | Total |
| 3D U/S | Negative | 49(98%) | 0(0%) | 49(98%) |
| | Positive | 0(0%) | 1(2%) | 1(2%) |
| | Total | 49(98%) | 1(2%) | 50(100%) |
| Kappa | | 1 | | |
| P value | | <0.001* | | |

This table shows that all positive cases of submucous fibroid by hysteroscopy (1 case) were positive by 3D U/S (True positive). All negative cases by hysteroscopy (49 cases) were negative by 3D U/S (True negative). There were no false positive nor false negative cases.

There was statistically significant agreement between 3D ultrasonography and hysteroscope in diagnosis of submucous fibroid (P value <0.001 and Kappa is 1). As regards prediction of submucous fibroid, 3D U/S showed 100% sensitivity, 100% specificity, 100% positive predictive value (PPV), 100% negative predictive value (NPV) & accuracy.

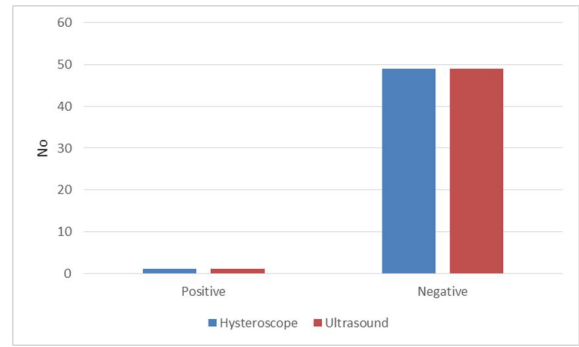


Figure 8: Illustrates table 7

Table 8: Diagnostic prediction of 3D ultrasonography compared to hysteroscope:

| | 3D US | | | | |
|--------------------|-------------|-------------|------|-------|----------|
| | Sensitivity | Specificity | PPV | NPV | Accuracy |
| Overall diagnosis | 73.3% | 100% | 100% | 89.7% | 92% |
| Endometrial polyp | 71.4% | 100% | 100% | 95.6% | 96% |
| Uterine septum | 50% | 100% | 100% | 95.8% | 96% |
| Hypoplastic uterus | 100% | 100% | 100% | 100% | 100% |
| Submucous fibroid | 100% | 100% | 100% | 100% | 100% |

This table shows that overall sensitivity of 3DUSG compared to hysteroscopy was 73.3%, specificity 100%, PPV 100%, NPV 89.7% and accuracy was 92%.

For diagnosis of endometrial polyp, 3DUSG showed 71.4% sensitivity, 100% specificity, 100% PPV, 95.6% NPV and 96% accuracy.

For diagnosis of uterine septum, 3DUSG showed 50% sensitivity, 100% specificity, 100% PPV, 95.8% NPV and 96% accuracy.

For diagnosis of hypoplastic uterus and submucous fibroid, 3DUSG showed 100% sensitivity, 100% specificity, 100% PPV, 95.6% NPV and 96% accuracy.

4. Discussion

It is estimated that endometriosis occurs in 10% of women during the reproductive years. Endometriosis is strongly associated with infertility, which is attributed to distorted adnexal anatomy and interference with oocyte development & early embryogenesis. Reduced endometrial receptivity may be contributory factor in impairment of implantation which may be due to intrinsic deficiencies within the uterus and structural or ultrastructural defects (4,6,17,18,19).

In the present study, the age of the studied patients ranged from 20-39 years with a mean of 28.96±5.52 years and BMI ranged from 18 – 36 kg/m² with a mean of 26.76 ± 5.11 kg/m². 39 cases (78%)

complained of 1ry infertility while 11 cases (22%) complained of 2ry infertility.

The overall diagnosis of abnormal uterine findings in the present study showed statistically significant agreement between 3DUSG and hysteroscope (P value <0.001 and Kappa 0.794). As regards prediction of uterine anomalies, 3D U/S showed 73.7% sensitivity, 100% specificity, 100% PPV, 89.7% NPV and 92% accuracy.

In agreement with the present study, Mohammad, et al, found that the sensitivity, specificity, PPV and NPV were 89.13%, 100%, 100% and 44.44% respectively and total overall accuracy of 3D-TVUS in relation to hysteroscopy for total abnormal findings was 90%. Also, Ayad & Mahmoud revealed that 3D TVUS in comparison with hysteroscopy had 97.57% diagnostic accuracy, 88.11% sensitivity, 99.17% specificity 94.6% PPV, and 98.02% NPV (20,21).

In addition, Abd El Fattah found in her study that 4D ultrasonography had sensitivity of 82.35% and specificity of 100% for diagnosing abnormal uterine findings with a PPV of 100% and a NPV of 91.67% and test accuracy of 94%. There was statistically significant agreement between hysteroscopy and 3D U/S in detecting uterine cavity abnormalities (P value<0.001 and Kappa 0.860) (22).

In contrast to this study, El Tagy, et al showed that 3D TVUS had 85% diagnostic accuracy, 68.2% sensitivity, 91.5% specificity, 79% PPV, and 86%

NPV in comparison with hysteroscopy. They found that hysteroscopy remains the preferred procedure for accurate detection and diagnosis of uterine cavity lesions. Also, Abo Haemila, et al concluded that compared to hysteroscopy, 3D US has a sensitivity of 63.2%, specificity of 80.8%, PPV of 54.6% and NPV of 85.7% and accuracy of 76.1%^(23,24).

Moreover, Apirakviriya, et al found that 3D TVUS in comparison with hysteroscopy had 84.1% diagnostic accuracy, 68.2% sensitivity, 91.5% specificity, 79% positive predictive value, and 86% negative predictive value⁽²⁵⁾.

Endometrial polyps are common gynecological disorder whose prevalence is increased in infertile women. The exact pathogenesis of these polyps is not yet known, but the similar pathological characteristics to endometriosis suggest a possible association^(26, 27).

As regards diagnosis of endometrial polyps, the present study showed statistically significant agreement between 3D ultrasonography and hysteroscope (P value <0.001 and Kappa is 0.811). As regards prediction of endometrial polyps, 3D U/S showed 71.4% sensitivity, 100% specificity, 100% PPV, 95.6% NPV and 96% test accuracy.

In agreement with this study, Abd El Fattah found that 4D ultrasonography had sensitivity of 80% and specificity of 95.24% for diagnosing endometrial polyps with a PPV of 80% and a NPV of 95.24% and test accuracy of 92.31%. There was statistically significant agreement between hysteroscopy and 3D U/S (P value <0.001 and Kappa 0.865)⁽²²⁾.

Also, Mohammad, et al found that the sensitivity, specificity, PPV, NPV were 80%, 100%, 100%, 95.24% respectively and accuracy of 3D-TVUS to detect endometrial polyps was 96%⁽²⁰⁾.

In contrast to this study, El Tagy et al revealed that for detection of endometrial polyps, 3D-TVS had 67.2% sensitivity, 88.3% specificity, PPV 63.1%, NPV 91.6% and 90% accuracy⁽¹¹⁾. Moreover, Apirakviriya, et al found that for detection of endometrial polyps, 3D-TVUS had low sensitivity 61.1%, low specificity 91.5%, PPV 73.3%, NPV 86% and 83.1% diagnostic accuracy⁽²⁵⁾.

Anatomical uterine malformations are also linked to endometriosis. Uterine septum, the most common Mullerian duct anomaly, results in colicky uterine peristalsis and increased menstrual regurgitation through the fallopian tubes. Hypoplastic uterus, a rare anomaly, may be also associated^(9, 28).

As regards diagnosis of uterine septum, the present study showed statistically significant agreement between 3D ultrasonography and hysteroscope (P value <0.001 and Kappa 0.648). As regards prediction of uterine septum, 3D U/S showed 50% sensitivity, 100% specificity, 100% PPV and 95.83% NPV and 96% test accuracy.

In agreement with this study, Abd El Fattah found that 4D ultrasonography had sensitivity of 80% and specificity of 100% for diagnosing septate uterus with a PPV of 100% and a NPV of 97.83% and test accuracy of 98%. They concluded that there was statistically significant agreement between hysteroscopy and 3d U/S (P value <0.001 and Kappa 0.878). Also, El Tagy, et al showed that for detection of septate uterus, 3D-TVUS had 95.7% sensitivity, 94.1% specificity, PPV 84.1%, NPV 94.2% and 91.3% test accuracy^(22,23).

In Mohammad, et al, 3DUS in detection of uterine septum has 100% sensitivity, 100% specificity, 100% PPV, 100% NPV and 100% accuracy⁽²⁰⁾.

As regards diagnosis of uterine septum, no previous studies concluded that 3d U/S has low accuracy in diagnosis of uterine septum.

As regards diagnosis of hypoplastic uterus, the present study showed statistically significant agreement between 3D ultrasonography and hysteroscope (P value <0.001 and Kappa is 1). For prediction of hypoplastic uterus, 3D U/S showed 100% sensitivity, specificity, PPV, NPV and 100% test accuracy.

In agreement with this study, Abd El Fattah found that 4D US had sensitivity and specificity of 100% for diagnosing hypoplastic uterus with a PPV and a NPV of 100% and an overall test accuracy of 100%. There was significant agreement between hysteroscopy and 3d U/S (P value <0.001 and Kappa 1)⁽²²⁾.

As regards diagnosis of hypoplastic uterus, no previous studies concluded that hysteroscopy is superior to 3d U/S in diagnosis of hypoplastic uterus.

As regards diagnosis of submucous fibroid, the present study showed statistically significant agreement between 3D ultrasonography and hysteroscope (P value <0.001 and Kappa is 1). As regards prediction of submucous fibroid, 3D U/S showed 100% sensitivity, 100% specificity, 100% PPV, 100% NPV and 100% test accuracy.

In agreement with this study, Mohammad et al study found that 3d U/S had 100% sensitivity, specificity, positive predictive value, negative predictive value and total accuracy for 3D-TVUS in diagnosis of submucous myomas. Also, El Tagy et al found that 3D-TVUS successfully detected every case of submucous myoma^(20,23).

As regards diagnosis of submucous fibroid, there were no previous studies concluded that hysteroscopy is superior to 3D U/S in diagnosis of submucous fibroids.

Conclusion and recommendation

▪ The 3D TVS is a sensitive method to diagnose the endometrial cavity lesions or

abnormalities. It is relatively inexpensive, is not time-consuming, non-invasive and can be performed in settings.

- 3D sonography has a high level of accuracy for most uterine anomalies. Thus, routine use of three dimensional transvaginal ultrasound is a sensitive method to evaluate the endometrial cavity lesions or abnormalities, before resorting to invasive procedures such as hysteroscopy.

- Hysteroscopy should be resorted to in cases of doubtful lesions as it can detect small intrauterine lesions which could be missed by TVS.

- Moreover, hysteroscopy is the gold standard for evaluation of uterine causes of infertility as it allows direct visualization of the uterine cavity.

References

1. Kennedy S, Bergqvist A, Chapron C, D'Hooghe T, Dunselman G and Saridogan E: ESHRE guideline for the diagnosis and treatment of endometriosis. *Human Reproduction*. 2005;20(10):2698-704.
2. Simoens S, Hummelshoj L and D'Hooghe T: Endometriosis: cost estimates and methodological perspective. *Human reproduction update*. 2007;13(4):395-404.
3. Hummelshoj L, Prentice A and Groothuis P: Update on endometriosis. *Women's health (London, England)*. 2006;2(1):53-6.
4. Garrido N, Navarro J, Garcia-Velasco J and Remohi J: The endometrium versus embryonic quality in endometriosis-related infertility. *Human reproduction update*. 2002;8(1):95-103.
5. Giudice LC and Kao LC: Endometriosis. *Lancet (London, England)*. 2004;364(9447):1789-99.
6. Kim JJ, Taylor H and Lu Z: Altered expression of HOXA10 in endometriosis: potential role in decidualization. *Molecular Human Reproduction Journal*. 2007;13(5):323-32.
7. Navarro J, Garrido N, Remohí J and Pellicer A: How does endometriosis affect infertility? *Obstetrics and Gynecology Clinics of North America*. 2003;30(1):181-92.
8. Karayalcin R, Ozcan S, Moraloglu O and Ozyer S: Results of 2500 office-based diagnostic hysteroscopies before IVF. *Reproductive BioMedicine Online*. 2010;20(5):689-93.
9. McBean JH, Gibson M and Brumsted JR: The association of intrauterine filling defects on hysterosalpingogram with endometriosis. *Fertility and sterility*. 1996;66(4):522-6.
10. Sanfilippo JS, Wakim NG, Schikler KN and Yussman MA: Endometriosis in association with uterine anomaly. *American Journal of Obstetrics & Gynecology*. 1986;154(1):39-43.
11. Soares SR, Barbosa dos Reis MM and Camargos AF: Diagnostic accuracy of sonohysterography, transvaginal sonography, and hysterosalpingography in patients with uterine cavity diseases. *Fertility and sterility*. 2000;73(2):406-11.
12. Sparac V, Kupesic S, Ilijas M and Zodan T: Histologic architecture and vascularization of hysteroscopically excised intrauterine septa. *The Journal of the American Association of Gynecologic Laparoscopists*. 2001;8(1):111-6.
13. Wold ASD, Pham N and Arici A. Anatomic factors in recurrent pregnancy loss. *Seminars in reproductive medicine*; 2006;24(1):25-32.
14. Cunha-Filho JS, De Souza CA, Salazar CC and Facin AC: Accuracy of hysterosalpingography and hysteroscopy for diagnosis of intrauterine lesions in infertile patients in an assisted fertilization programme. *Gynaecological Endoscopy*. 2001;10(1):45-8.
15. Behr SC, Courtier JL and Qayyum A: Imaging of mullerian duct anomalies. *Radiographics: a review publication of the Radiological Society of North America, Inc*. 2012;32(6): 233-50.
16. Bonilla-Musoles F, Raga F and Osborne NG: Three-dimensional ultrasound evaluation of ovarian masses. *Gynecologic Oncology*. 1995;59(1):129-35.
17. Gordts S, Puttemans P, Gordts S and Brosens I: Ovarian endometrioma in the adolescent: a plea for early-stage diagnosis and full surgical treatment. *Gynecological Surgery*. 2015;12(1):21-30.
18. Dunselman G, Vermeulen N and Becker C: ESHRE guideline: management of women with endometriosis. *Human Reproduction*. 2014;29(3):400-12.
19. Fedele L, Marchini M and Bianchi S: Structural and ultrastructural defects in preovulatory endometrium of normo-ovulating infertile women with minimal or mild endometriosis. *Fertility and sterility*. 1990;53(6):989-93.
20. Mohammad FA, Fattah ATA and Abd-Elrahman AM: Comparative Study between Three-Dimensional Transvaginal Ultrasonography and Hysteroscopy in the Diagnosis of Uterine Cavity Abnormalities. *The Egyptian journal of hospital medicine*. 2018;73(8):7350-7.
21. Ayad WA and Mahmoud MS: Comparative Study between Three Dimensional Ultrasonography and Office Hysteroscopy in Women with Abnormal Uterine Bleeding. *International Journal of Applied and Basic Medical Research*. 2017;7(1):39-42.
22. Abd El Fattah EA: Uterine Cavity Abnormalities in Patients with Endometriosis in Alexandria: A

- Diagnostic Test Accuracy Study. *Obstetrics and gynecology international*. 2017;2017:5869028.
23. El Tagy AH, El Motaal AOA and Awaly M: Comparison between 3D-Transvaginal Ultrasound and Hysteroscopy in Detecting Uterine Cavity Abnormalities. *The Egyptian journal of hospital medicine*. 2018;73(7):7160-4.
 24. Abo Haemila F, Youssef D, Hassan M and Soliman A: A prospective comparative study of 3-D ultrasonography and hysteroscopy in detecting uterine lesions in premenopausal bleeding. *Middle East Fertility Society Journal*. 2005;10(3):238-43.
 25. Apirakviriya C, Rungruxsirivorn T, Phupong V and Wisawasukmongchol W: Diagnostic accuracy of 3D-transvaginal ultrasound in detecting uterine cavity abnormalities in infertile patients as compared with hysteroscopy. *European journal of obstetrics, gynecology, and reproductive biology*. 2016;200:24-8.
 26. McBean JH, Gibson M and Brumsted JR: The association of intrauterine filling defects on hysterosalpingogram with endometriosis. *Fertil Steril*. 1996;66(4):522-6.
 27. Sparac V, Kupesic S, Ilijas M, Zodan T and Kurjak A: Histologic architecture and vascularization of hysteroscopically excised intrauterine septa. *The Journal of the American Association of Gynecologic Laparoscopists*. 2001;8(1):111-6.
 28. Devi Wold AS, Pham N and Arici A: Anatomic factors in recurrent pregnancy loss. *Seminars in reproductive medicine*. 2006;24(1):25-32.

12/25/2019