



Evaluation of Chorioretinal Changes in Posterior Uveitis Using Optical Coherence Tomography

Dalia Abd-El-Rahman El-Feky (MSCh), Hammouda Hamdy Ghoraba (MD), Hamdy Abd El- Azim El- Koumy (MD), Sharif Yousef El – Emam (MD)

Ophthalmology Department, Faculty of Medicine, Tanta University, Egypt

Abstract: Background: Posterior uveitis is a sight threatening condition worldwide particularly among the working-age population and it may be the first presentation of serious systemic disease. Etiologically, posterior uveitis may be the result of infectious, non-infectious or ‘masquerade’ causes as described by the international uveitis study group (IUSG). Noninfectious uveitis with no associated systemic disease or other precipitant is termed ‘idiopathic’. Involvement of posterior segment structures as described by the standardization of uveitis nomenclature (SUN) may be focal, multifocal, or diffuse. Due to a wide variety of phenotypic features, the diagnostic approach is not that simple including careful history taking, comprehensive review of systems, précised ocular examination, targeted laboratory workup, and tailored ocular imaging. Retinal & choroidal imaging is very important in diagnosing pathologies and monitoring inflammatory process and treatment of posterior uveitis. Fundus fluorescein angiography (FFA) and optical coherence tomography (OCT) are the most commonly used imaging techniques. **Aim of the study:** This controlled, selective, cross-sectional study aimed to evaluate chorioretinal changes in eyes with newly diagnosed posterior uveitis using swept source optical coherence tomography (SS-OCT). **Patients and Methods:** The study was performed on 44 eyes of 30 patients with freshly diagnosed acute posterior uveitis (in 14 patients, the disease was bilateral) and 30 eyes of 15 normal age/sex/refraction-matched individuals as control group. **Results:** The mean age of the patients was 32 years (range 12 to 56 years) and of the controls was 33 years (range 15 to 53 years). This study was conducted on 13 male and 17 female patients with 6 male and 9 female controls. In the study, 40.91% of cases showed posterior uveitis with spillover anterior uveitis. Best corrected visual acuity (BCVA) was measured in all participants using decimal notation and the mean (0.149 ± 0.141) was markedly decreased. A complete fundus examination, fundus photography and FFA were done to all patients and we documented a variable degree of vitritis in all eyes, retinitis in 11 eyes of 10 patients, choroiditis in 12 eyes of 6 patients, and chorioretinitis in 21 eyes of 14 patients. Retinal vasculitis was found in 15 eyes and 20 eyes had optic neuritis. Non-infectious uveitis was clinically diagnosed, with or without a definite entity classification, in 26 cases and 4 cases had infectious etiology (clinically and laboratory diagnosed). SS-OCT was done for all participants and we found that in acute posterior uveitis the structural changes were macular edema (ME) in all eyes (cystoid ME in 11 eyes and spongy ME in 33 eyes), neurosensory detachment (NSD) in 16 eyes, thickened choroid in all patients and interrupted photoreceptor layers in 19 eyes. Changes in the choroidal architecture were documented in 18 eyes and focal hyper-reflective thickening of the retinal pigment epithelium (RPE)/choriocapillaris complex was found in 13 eyes. Two SS-OCT parameters were measured in all participants retinal thickness (RT) using early treatment diabetes retinopathy study (ETDRS) map {in the form of central subfield (CSF), mean inner macular (MIM) and mean outer macular (MOM) thickness} and subfoveal choroidal thickening (SFCT). Our results revealed that both parameters were significantly greater in diseased than in control eyes. Interestingly, we detected significant topographical changes in the macula of our patients using ETDRS map, the thickest macular region was the parafoveal area (inner ring) followed by the peri foveal area (outer ring) and the CSF was least affected. Significant negative correlation was found between RT {CSF, MIM and MOM thickness} and BCVA and cystoid macular edema (CME) was associated with more reduction in BCVA than spongy ME. Also, NSD had negative significant relation with BCVA. Moreover, SFCT had a significant negative correlation with BCVA and a statically significant relation with NSD. A positive weak correlation between RT and SFCT was found but the result was statically insignificant. **Conclusion:** SS-OCT yields reasonable amount of data regarding morphological changes of the vitreoretinal interface, retina, and choroid in acute posterior uveitis.

[Dalia Abd-El-Rahman El-Feky, Hammouda Hamdy Ghoraba, Hamdy Abd El- Azim El- Koumy, Sharif Yousef El-Emam. **Evaluation of Chorioretinal Changes in Posterior Uveitis Using Optical Coherence Tomography.** *N Y Sci J* 2020;13(1):48-55]. ISSN 1554-0200 (print); ISSN 2375-723X (online). <http://www.sciencepub.net/newyork>. 7. doi:[10.7537/marsnys130120.07](https://doi.org/10.7537/marsnys130120.07).

Keywords: Chorioretinal Changes, Posterior Uveitis, Optical Coherence Tomography.

1. Introduction:

Uveitis is one of the leading causes of preventable blindness worldwide. It has been classified into various subdivisions according to the standardization of uveitis nomenclature (SUN) and international uveitis study group (IUSG) classification. It could be anterior, intermediate, posterior, or a panuveitis depending on the primary site of inflammation. It could also be classified based on etiology as infectious, noninfectious, or a masquerade. However, in many cases, the cause remains unknown (idiopathic uveitis) ⁽¹⁾.

Posterior uveitis is a major cause of ocular morbidity and visual loss worldwide. It includes various inflammatory disorders, affecting structures behind the posterior border of the vitreous base including the vitreous, retina, choroid, retinal blood vessels, or optic disc. In cases of multilevel involvement, discrimination of the initially or exclusively affected tissue allows a more precise classification into retinitis, choroiditis, or retinochoroiditis/chorioretinitis ⁽²⁾.

The diagnostic work-up of posterior uveitis is guided by several findings including age, sex, immune status of the patient, intra- and peri-ocular signs, associated systemic features obtained from direct questioning, clinical exam, laboratory tests, and imaging procedures ⁽³⁾.

Fundus Fluorescein Angiography (FFA) is an essential tool in the assessment of posterior uveitis. It plays an important role in detection of papillitis, retinal vasculitis, macular ischemia, macular edema (ME), retinal neovessels, subretinal pooling and changes in the retinal pigment epithelium (RPE). However, FFA is an invasive risky technique and is blocked by the RPE, giving little information on the choroidal circulation and the choroidal compartment ⁽⁴⁾.

Optical coherence tomography (OCT) is considered a standard non-invasive, reproducible, and sensitive tool for diagnosis of posterior uveitis. It is based on the principle of low-coherence interferometry and offers millimeter penetration with submicrometric axial and lateral resolution “optical biopsy”. Quantitative and qualitative assessment of the retinal and choroidal architecture provided by OCT can be used to diagnose their pathology, and the obtained data can be displayed in a false-color topographic map ⁽⁵⁾.

There are two main OCT methods: conventional time domain OCT (TD-OCT) and Fourier domain / spectral domain OCT (FD/SD-OCT) that can be implemented in two formats: Spectrometer based (SB) and Swept source (SS). SD-OCT obtains in-depth information from various retinal structures to create cross-sectional images. However, it provides only

partial information regarding the structure and function of the choroid. This is mainly due to signal loss and light scattering at the RPE layer that is highly reflective and blocks most signals from the choroid. With enhanced depth imaging (EDI), choroidal vasculature and thickness can be both qualitatively and quantitatively measured and this is particularly helpful in posterior uveitic conditions ⁽⁶⁾.

SS-OCT devices have several advantages compared to earlier generations such as faster scanning time, better signal-to-noise ratio and higher detection efficiencies which allow longer imaging range (both horizontally and vertically). Also, the longer wavelength of the laser allows deeper penetration as there is less signal loss from melanin in the RPE. So, deeper structures, such as the choroid-scleral interface (CSI), can be visualized more clearly ⁽⁷⁾.

SS-OCT plays an ever-increasing role in the assessment of posterior uveitis. Diagnostically, its ability to detect alteration in the reflectivity and thickness of retinal and choroidal architecture is invaluable in understanding the pathophysiology of some posterior uveitic conditions. It can also be used to detect the presence of complications as vitreomacular traction (VMT), epiretinal membrane (ERM), foveal atrophy and macular hole (MH) ⁽⁸⁾.

From a management perspective, OCT is useful in documenting longitudinal changes and resolution of complications, e.g. ME, subretinal fluid (SRF) and choroidal neovascular membrane (CNVM). Also, specific OCT changes associated with certain posterior uveitic conditions [e.g. hyper-reflectivity of the outer retina seen in acute posterior multifocal placoid pigment epitheliopathy (APMPPE)] often resolve with treatment, making OCT ideal for assessing treatment response. Prognostically, OCT can be used to predict visual outcome ⁽⁹⁾.

2. Patients and Methods:

This controlled, selective, cross-sectional study was carried out on 44 eyes of 30 patients presenting with newly diagnosed acute posterior uveitis attending Ophthalmology outpatient clinic in Tanta University Hospital between January, 2018 and May, 2019 and results were compared to 30 eyes of 15 normal age/sex/refraction-matched subjects not suffering from any ocular or systemic disease.

Inclusion criteria:

Any patient with clinically newly diagnosed acute posterior uveitis.

Exclusion criteria:

1. Patients with any media opacity as corneal opacity, dense cataract or severe vitritis obscuring adequate clinical evaluation and imaging.

2. Patients with extensive synechia as adequate pupil size is important to obtain reasonable images. A minimum of 3-mm pupil diameter is needed to ensure good image resolution.

3. Patients with poor or eccentric fixation that may cause difficult and unreliable imaging.

4. Patients with high myopia as staphylomatous changes are associated with thin choroid.

5. Patients diagnosed with diabetes mellitus or other retinal vascular diseases (as retinal vein occlusion) to avoid confusion of data.

6. Patients with previous ocular surgery (particularly vitreoretinal surgery).

7. Patients with any contraindication to intravenous fluorescein injection as renal impairment, hypersensitivity, etc.

8. Any mental handicap preventing adequate clinical evaluation and imaging.

9. Patients diagnosed with recurrent/chronic uveitis.

10. Patients under treatment for uveitis to eliminate the potential influence of previous treatment on the measurement of retinal and choroidal thickness.

Statistical analysis

- Sorting and analysis of data were performed by using IBM Statistical Package for Social Sciences (SPSS); Version 25.0. Armonk, NY: IBM Corp.

- Qualitative data were described using number and percent.

- Quantitative data were presented as mean and standard deviation (SD).

- Chi-square test was used for analysis of categorical variables.

- For analysis of means of quantitative data, T-test was used.

- Analysis of variance (ANOVA) was used to analyze the differences among group means.

3. Results:

This study was conducted on 13 male and 17 female patients with 6 male and 9 female controls. The mean age of the patients was 32 years (Range 12 to 56 years) and of the controls was 33 years (Range 15 to 53 years).

In 14 patients, posterior uveitis was bilateral and both eyes were included in the study.

The included studied 44 eyes were classified as 40 eyes of 26 patients with clinically diagnosed non-infectious uveitis with or without a definite entity classification & 4 eyes of 4 patients with infectious uveitis (clinically and laboratory diagnosed).

Regarding eyes with non-infectious uveitis, there were 12 eyes of 6 Behçet patients, 14 eyes of 7

patients of Vogt–Koyanagi–Harada disease (VKH) syndrome, 6 eyes of 5 patients with multifocal choroiditis (MFC), and 2 eyes of 2 patients with birdshot chorioretinopathy (BSCR). Non-infectious posterior uveitis without a definite diagnosis was found in 6 eyes of 6 patients and was classified as idiopathic posterior uveitis.

Regarding infectious etiology, toxoplasma was the cause in 3 eyes of 3 cases, and 1 eye had a herpetic viral etiology.

The mean BCVA in our cases was markedly decreased (0.149 ± 0.141) and the results were statistically significant ($P < 0.001$).

All cases showed varying degrees of vitritis. We detected retinitis in 11 eyes of 10 patients, choroiditis in 12 eyes of 6 patients, and chorioretinitis in 21 eyes of 14 patients. ME (focal, diffuse or cystoid) by FFA was found in 32 eyes. Retinal vasculitis was detected in 15 eyes and 20 eyes showed papillitis.

Table 1: Causes of posterior uveitis in the studied eyes

	N	%
Toxoplasma	3	6.82
Herpes virus	1	2.27
Behcet	12	27.27
VKH	14	31.82
MFC	6	13.64
BSCR	2	4.54
Idiopathic	6	13.64
Total	44	100.00

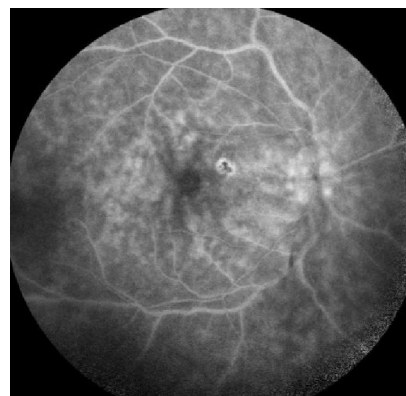


Fig. 1: FFA (late phase) showing vitritis, vasculitis, neuro retinitis & ME.

All eyes demonstrated varying degrees of vitritis (hyper-reflective dots within the vitreous and at the vitreoretinal interface), ME & choroidal thickening by SS-OCT.

Table 2: Chorioretinal changes detected by SS-OCT in the diseased eyes

	N	%
Diffuse ME	33	75.00
CME	11	25.00
NSD	16	36.36
Interrupted photoreceptor layer	19	43.18
Mosaic hypo-and hyper-reflectivity of the choroid	18	40.91
Focal hyper-reflective thickening of the RPE/choriocapillaris complex	13	29.55

RT was measured in all participants using Early Treatment Diabetes Retinopathy Study (ETDRS) mapping software of SS-OCT and the following data was recorded: - central subfield (CSF) retinal thickness, mean retinal thickness of the 4 quadrants in

the para foveal area (MIM, mean inner macula thickness) and mean retinal thickness of the 4 quadrants in the peri foveal area (MOM, mean outer macula thickness).

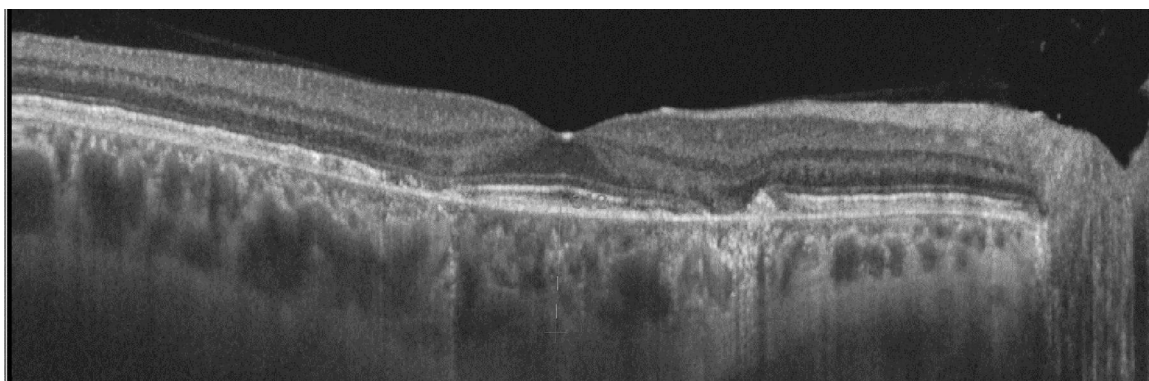


Fig.2: SS-OCT shows focal inflammatory infiltration within the choroid with hyper-reflective foci of the RPE and distorted photoreceptor layer.

Table 3: Central subfield, inner macula and outer macula thickness by ETDRS map in the study groups

ETDRS map		Groups				T-Test	
		Patients		Controls		t	P-value
CSF thickness	Range	208	- 1253	197	- 245	2.470	0.017*
	Mean ±SD	394.886	± 256.630	230.200	± 12.019		
MIM thickness	Range	205	- 989	200	- 250	3.204	0.002*
	Mean ±SD	396.273	± 190.809	237.400	± 12.872		
MOM thickness	Range	221	- 923	210	- 254	2.698	0.009*
	Mean ±SD	367.386	± 179.663	241.400	± 12.710		

Mean SFCT in 44 eyes of acute posterior uveitis was $367.932 \pm 35.172\mu\text{m}$ which was significantly greater than that in the control eyes ($P < 0.001$).

BCVA was slightly poorer in eyes with spillover anterior uveitis, but the difference was not significant and we did not find significant relation between anterior segment involvement and macular thickness or SFCT.

The visual acuities of eyes with retinal vasculitis were significantly poorer ($P = 0.008$). Similarly, eyes

with papillitis were associated with significant changes in BCVA ($P = 0.038$).

SFCT had a statically significant relation with NSD ($P = 0.041$) and a significant negative correlation between SFCT and BCVA was found in patients with acute posterior uveitis ($P = 0.043$).

In addition, SFCT in affected eyes showed a positive correlation with CSF, MIM, and MOM retinal thickness of ETDRS map, but this correlation did not reach a statically significant value ($P > 0.05$).

Table 4: Relation between BCVA and SS-OCT retinal changes

Retinal changes by OCT	BCVA				T-Test	
	N	Mean	±	SD	t	P-value
DME	33	0.154	±	0.145	0.373	0.711
CME	11	0.104	±	0.101	-1.251	0.218
NSD	16	0.084	±	0.080	-2.443	0.019*
Interrupted photoreceptor layer	19	0.167	±	0.155	0.716	0.478

4. Discussion:

Our study did not comment on the prevalence of different entities of posterior uveitis among one of the sexes and among age groups owing to the low number of eyes from each specific uveitis entity.

We found a significant drop in BCVA in our cases correlating with OCT macular findings ($P < 0.001$) and this result agreed with the results of **Grajewski, et al.**⁽⁹⁾ & **Matas, et al.**⁽¹⁰⁾.

Regardless of the etiology, we documented a variable degree of vitritis in all eyes, retinitis in 11 eyes of 10 patients, choroiditis in 12 eyes of 6 patients, and chorioretinitis in 21 eyes of 14 patients. Retinal vasculitis was found in 15 eyes and 20 eyes had papillitis. By using FFA, 32 eyes showed ME (focal, diffuse or cystoid). Non-infectious uveitis was diagnosed in 86.67% of our patients.

In our study, it was found that retinal vasculitis and papillitis had a statistically significant negative relation with BCVA ($P = 0.008$ and $= 0.038$ respectively). This result is consistent with the study of **Kim, et al.**⁽¹¹⁾ which showed that retinal vascular leakage (particularly posterior pole leakage) & optic disc hyper fluorescence were significantly associated with worse initial VA in Behcet's posterior uveitis.

Structural changes detected by SS-OCT in our patients were in the form of ME (with or without cysts), NSD, thickened choroid and distorted photoreceptor layer. Diffuse ME was detected in 75 % of studied eyes and the remaining 25 % showed CME. Subretinal fluid (SRF) or NSD was seen in 36 % of eyes and the IS/OS junction of the photoreceptor layer was interrupted in 43% of eyes.

Regarding ME & NSD, the studies of **Markomichelakis, et al.**⁽¹²⁾, **Al-Mezaine, et al.**⁽¹³⁾, **Iannetti, et al.**⁽¹⁴⁾, **Dick, et al.**⁽¹⁵⁾ & **Grajewski, et al.**⁽⁹⁾ were in agreement with our results and identified 3 different OCT patterns of fluid distribution in eyes with uveitic ME: DME and CME with and without coexistent NSD. Additionally, **Forooghian, et al.**⁽¹⁶⁾ & **Birnbaum, et al.**⁽¹⁷⁾ detected a disrupted photoreceptor layer in patients with acute posterior uveitis.

We found that CSF, MIM & MOM thickness was significantly greater in diseased than in healthy eyes ($P = 0.017$, $= 0.002$ and $= 0.009$ respectively). The

studies of **Taylor, et al.**⁽¹⁸⁾, **Grajewski, et al.**⁽⁹⁾, **Kang, et al.**⁽¹⁹⁾ & **Matas, et al.**⁽¹⁰⁾ agreed with our results and revealed significant increase in macular thickness in patients with posterior uveitis.

In the current study using ETDRS map, we observed significant topographical changes of RT as the thickest macular region was the parafoveal area (inner ring) followed by the peri foveal area (outer ring) and the CSF was least affected and these results come in agree with the study of **Géhl, et al.**⁽²⁰⁾ that concluded that RT was substantially higher in both the 3 mm and the 6 mm rings.

Regarding SFCT, we found that SFCT was significantly greater in diseased than in healthy eyes ($P < 0.001$). In accordance with our results, the studies of **MARUKO, et al.**⁽²¹⁾, **NAKAYAMA, et al.**⁽²²⁾, **Ishibazawa, et al.**⁽²³⁾ & **Garcia-Garcia, et al.**⁽²⁴⁾ demonstrated marked increase of the SFCT in patients with acute VKH disease and **Aoyagi R, et al.**⁽²⁵⁾ also noticed that in acute phase of MEWDS, there was a thickening in the subfoveal choroid in the involved eyes. In like manner, **Kim, et al.**⁽²⁶⁾, **Ishikawa, et al.**⁽²⁷⁾ & **Shirahama, et al.**⁽²⁸⁾ agreed with our results and found that SFCT was significantly greater in acute phase of Behcet's posterior uveitis.

Regarding choroidal morphology, all 44 eyes showed thickened choroid and we detected mosaic hypo-and hyper-reflectivity of the choroid in 18 eyes. Also, focal hyper-reflective thickening of the RPE/choriocapillaris complex was identified in 13 eyes. Many previous studies as **Goldenberg, et al.**⁽²⁹⁾ & **Sakata, et al.**⁽³⁰⁾ supported our findings and demonstrated these morphological changes of the choroid in acute posterior uveitis.

Our results showed that there was a strong statically significant negative correlation between CSF, MIM and MOM thickness and BCVA ($P = 0.008$, $= 0.015$ and $= 0.011$ respectively). CSF thickness was found to have the strongest negative correlation with BCVA and these results come in agree with the studies of **Markomichelakis, et al.**⁽¹²⁾, **Iannetti, et al.**⁽¹⁴⁾ & **Matas, et al.**⁽¹⁰⁾.

Furthermore, our study showed that eyes with CME had poorer VA than those with DME and the studies of **Al-Mezaine, et al.**⁽¹³⁾, **Payne, et al.**⁽³¹⁾ & **Taylor, et al.**⁽⁵⁴⁾ agreed with our results.

Regarding NSD, we found a negative significant relation with BCVA ($P=0.019$) and the same result was found in the studies of **Lehpamer, et al.**⁽³²⁾ & **Grajewski, et al.**⁽⁹⁾.

Interestingly, we noticed that SFCT had a statically significant relation with NSD ($P=0.041$) and this could be explained as that both of them were related to inflammation and increased vascular leakage. This result is consistent with **MARUKO, et al.**⁽²¹⁾ who noticed that increased CT might represent the precursor state to SRD and with **NAKAYAMA, et al.**⁽²²⁾ who demonstrated that decreased CT correlated with improvement in the NSD during the course of treatment.

In addition, our results showed a significant negative correlation between SFCT and BCVA ($P=0.043$). This result is consistent with **NAKAYAMA, et al.**⁽²²⁾ & **Garcia-Garcia, et al.**⁽²⁴⁾.

On the contrary, **Ishikawa, et al.**⁽²⁷⁾ found that SFCT didn't correlate with BCVA in patients with BD, but the authors suggested that VA in these patients may be affected by factors independent of ocular inflammation activity.

Finally, a positive weak correlation between CSF, MIM and MOM thickness and SFCT was found in our study but this correlation did not reach a statically significant value ($P>0.05$). This result comes in agree with the study of **Géhl, et al.**⁽²⁰⁾ that revealed no significant correlation between retinal and choroidal thickness in the corresponding fields in uveitic patients.

Conclusion:

SS-OCT is quick, easy, noninvasive tool that yields reasonable amount of data regarding morphological changes of the vitreoretinal interface, retina, and choroid in acute posterior uveitis and it can be performed repeatedly without any complications. Unlike ordinary OCT, SS-OCT with longer wavelength enables better wider field imaging of deeper structure and improves detection of the choroid-sclera border with greater sensitivity at scanning the deep choroidal structures and the superficial retinal layers in the same image.

As well, SS-OCT is very sensitive for revealing the distribution of fluid and morphology of uveitic macular edema (UME) with great ability to detect minimal subretinal fluid., The results of SS-OCT are also quantitative, and thus it can be performed to evaluate the activity of posterior uveitis and to quantify the degree of inflammation.

In SS-OCT, enhanced visualization and *in vivo* measurement of retinal and choroidal thickness are allowed and that is important in diagnosis of active posterior uveitis. An additional important SS-OCT finding in posterior uveitis is the integrity of

photoreceptors and RPE which may predict the prognosis of the condition and the response to treatment. Moreover, SS-OCT can allow detection of disease complications as ERM, VMT, MH, CNV or foveal atrophy.

Interestingly, retinal and choroidal thickness may be promising parameters that can be used to characterize different disease entities and monitor resolution of posterior pole inflammatory disorders and efficacy of treatment. Also, they may potentially be useful in predicting prognosis of condition.

Furthermore, increased retinal and choroidal thickness may be a clue for detection of subclinical inflammatory activity of the retina and choroid during the quiescent phase, which could exacerbate, leading to an acute recurrent attack of uveitis.

Additionally, SS-OCT can be used to correlate the morphologic changes of macula, retinal and choroidal thickness with VA in patients with posterior uveitis. Thus, serial imaging of the macula and correlation with change in VA may help to predict the prognosis and allow for more accurate follow-up of response to treatment.

In this respect, SS-OCT (in the appropriate clinical context) may add a great deal of information not only in the diagnosis, but also in management and follow-up of the inflammatory process of the retina and choroid in posterior uveitis. As well, it could be used as an adjunctive tool for screening of certain posterior uveitis entities.

References:

1. Choi RY, Rivera-grana E, Rosenbaum JT. Reclassifying Idiopathic Uveitis: Lessons from a Tertiary Uveitis Center. *Am J Ophthalmol.* 2019;198:193–9.
2. Sudharshan S, Ganesh SK, Biswas J. Current approach in the diagnosis and management of posterior uveitis. *Indian J Ophthalmol.* 2010;58(1):29–43.
3. Ahmed AS, Biswas J. Uveitis: A search for a cause. *Taiwan J Ophthalmol.* 2013;3(4):134–40.
4. Robert N. Johnson, Arthur D. Fu, H. Richard McDonald, J. Michael Jumper, Everett Ai, Emmett T. Cunningham, *et al.* Fluorescein Angiography: Basic Principles and Interpretation. In: Stephen J. Ryan, Srinivas R. Sadda, David R. Hinton, Andrew P. Schachat, Srinivas R. Sadda, C.P. Wilkinson, *et al.* (eds). *Retina* (5th ed), W.B. Saunders; 2013:2-50.e1.
5. Nazari H, Rao N. Recent Advances in Ocular Imaging in Management of Uveitis and Related Intraocular Inflammations. *Advances in Ophthalmology and Optometry.* 2017;2(1):435-57.

6. Kim JS, Knickelbein JE, Jaworski L, Kaushal P, Vitale S, Nussenblatt RB, *et al.* Enhanced Depth Imaging Optical Coherence Tomography in Uveitis: An Intravital and Interobserver Reproducibility Study. *Am J Ophthalmol.* 2016;164:49–56.
7. Kishi S. Impact of swept source optical coherence tomography on ophthalmology. *Taiwan J Ophthalmol.* 2016;6(2):58–68.
8. Fardeau C, Champion E, Massamba N, Lehoang P. Uveitic macular edema. *EYE.* 2016;30(10):1277–92.
9. Grajewski RS, Boelke AC, Adler W, Meyer S, Caramoy A, Kirchhof B, *et al.* Spectral-domain optical coherence tomography findings of the macula in 500 consecutive patients with uveitis. *Eye (Lond).* 2016;30(11):1415-23.
10. Matas J, Llorenc V, Fonollosa A, Esquinas C, Diaz-Valle D, Berasategui B, *et al.* Predictors for functional and anatomic outcomes in macular edema secondary to non-infectious uveitis. *PLoS One.* 2019;14(1):e0210799.
11. Kim M, Kwon H J, Choi EY, Kim, SS, Koh HJ, & Lee SC. Correlation between Fluorescein Angiographic Findings and Visual Acuity in Behçet Retinal Vasculitis. *Yonsei Med J.* 2015; 56(4): 1087–1096.
12. Markomichelakis NN, Halkiadakis I, Pantelia E, Peponis V, Patelis A, Theodossiadis P, *et al.* Patterns of macular edema in patients with uveitis: qualitative and quantitative assessment using optical coherence tomography. *Ophthalmology.* 2004;111(5):946-53.
13. Al-Mezaine HS, Al-Muammar A, Kangave D, Abu El-Asrar AM. Clinical and optical coherence tomographic findings and outcome of treatment in patients with presumed tuberculous uveitis. *Int Ophthalmol.* 2008;28(6):413-23.
14. Iannetti L, Accorinti M, Liverani M, Caggiano C, Abdulaziz R, Pivetti-Pezzi P. Optical coherence tomography for classification and clinical evaluation of macular edema in patients with uveitis. *Ocul Immunol Inflamm.* 2008;16(4):155-60.
15. Dick AD, Tundia N, Sorg R, Zhao C, Chao J, Joshi A, *et al.* Risk of Ocular Complications in Patients with Noninfectious Intermediate Uveitis, Posterior Uveitis, or Panuveitis. *Ophthalmology.* 2016;123(3):655-62.
16. Forooghian F, Yeh S, Faia LJ, Nussenblatt RB. Uveitic foveal atrophy: clinical features and associations. *Arch Ophthalmol.* 2009;127(2):179-86.
17. Birnbaum AD, Fawzi AA, Rademaker A, Goldstein DA. Correlation between clinical signs and optical coherence tomography with enhanced depth imaging findings in patients with birdshot chorioretinopathy. *JAMA Ophthalmol.* 2014;132(8):929-35.
18. Taylor SR, Lightman SL, Sugar EA, Jaffe GJ, Freeman WR, Altaweel MM, *et al.* The Impact of Macular Edema on Visual Function in Intermediate, Posterior, and Panuveitis. *Ocul Immunol Inflamm.* 2012;20(3):171–81.
19. Kang HM, Koh HJ, Lee SC. Spectral domain optical coherence tomography as an adjunctive tool for screening Behcet uveitis. *PLoS One.* 2018;13(12):e0208254.
20. Géhl Z, Kulcsár K, Kiss HJ, Németh J, Maneschg OA, Resch MD. Retinal and choroidal thickness measurements using spectral domain optical coherence tomography in anterior and intermediate uveitis. *BMC Ophthalmol.* 2014;14:103.
21. Maruko I, Iida T, Sugano Y, Oyamada H, Sekiryu T, Fujiwara T, *et al.* Subfoveal choroidal thickness after treatment of Vogt-Koyanagi-Harada disease. *Retina.* 2011;31(3):510-7.
22. Nakayama M, Keino H, Okada AA, Watanabe T, Taki W, Inoue M, *et al.* Enhanced depth imaging optical coherence tomography of the choroid in Vogt-Koyanagi-Harada disease. *Retina.* 2012;32(10):2061-9.
23. Ishibazawa A, Kinouchi R, Minami Y, Katada A, Yoshida A. Recurrent Vogt–Koyanagi–Harada disease with sensorineural hearing loss and choroidal thickening. *Int Ophthalmol.* 2014;34(3):679-84.
24. Garcia-Garcia O, Jordan-Cumplido S, Subira-Gonzalez O, Garcia-Bru P, Arias L, Caminal JM. Automatic Measurement of Choroidal Thickness with Swept-Source Optical Coherence Tomography for Clinical Follow-Up in Acute Vogt-Koyanagi-Harada Disease. *J Clin Exp Ophthalmol.* 2016; 7:579.
25. Aoyagi R, Hayashi T, Masai A, Mitooka K, Gekka T, Kozaki K, *et al.* Subfoveal choroidal thickness in multiple evanescent white dot syndrome. *Clin Exp Optom.* 2012;95(2):212-7.
26. Kim M, Kim H, Kwon HJ, Kim SS, Koh HJ, Lee SC. Choroidal thickness in Behcet's uveitis: an enhanced depth imaging-optical coherence tomography and its association with angiographic changes. *Invest Ophthalmol Vis Sci.* 2013;54(9):6033-9.
27. Ishikawa S, Taguchi M, Muraoka T, Sakurai Y, Kanda T, Takeuchi M. Changes in subfoveal choroidal thickness associated with uveitis activity in patients with Behcet's disease. *Br J Ophthalmol.* 2014;98(11):1508-13.
28. Shirahama S, Kaburaki T, Nakahara H, Tanaka R, Komae K. Association between subfoveal

- choroidal thickness and leakage site on fluorescein angiography in Behçet's uveitis. *Sci Rep.* 2019;1–6.
29. Goldenberg D, Goldstein M, Loewenstein A, Habot-Wilner Z. Vitreal, retinal, and choroidal findings in active and scarred toxoplasmosis lesions: a prospective study by spectral-domain optical coherence tomography. *Graefes Arch Clin Exp Ophthalmol.* 2013;251(8):2037-45.
 30. Sakata VM, da Silva FT, Hirata CE, Takahashi WY, Costa RA, Yamamoto JH. Choroidal bulging in patients with Vogt-Koyanagi-Harada disease in the non-acute uveitic stage. *J Ophthalmic Inflamm Infect.* 2014 Feb 18;4(1):6.
 31. Payne JF, Bruce BB, Lee LB, Yeh S. Logarithmic transformation of spectral-domain optical coherence tomography data in uveitis-associated macular edema. *Invest Ophthalmol Vis Sci.* 2011;52(12):8939-43.
 32. Lehpamer B, Moshier E, Goldberg N, Ackert J, Godbold J, Jabs DA. Subretinal fluid in uveitic macular edema: effect on vision and response to therapy. *Am J Ophthalmol.* 2013;155(1):143-9.

12/25/2019