



Electrophysiological assessment of central retina following intravitreal injection of Ranibizumab in cases of diabetic macular edema

Mina Wahid Sabry Nassif (MSCh), Osama Elsaied Shalaby (MD), Mohamed Hosny El-Bradey (MD), Heba Mohamed Shafik (MD)

Ophthalmology Department, Faculty of Medicine, Tanta University, Egypt

Abstract: Background: Diabetic retinopathy (DR) is one of the leading reasons of blindness throughout the world, and diabetic macular edema (DME) is a major complication of DR which leads to visual acuity loss, so early diagnosis and adequate treatment is a must to overcome this disaster. **The aim of this study** is to evaluate electrophysiological responses of central retina following intravitreal injection of Ranibizumab in cases of diabetic macular edema in correlation with optical coherence tomography (OCT). **Patients and Methods:** A prospective, observational study involved 24 eyes of 20 patients suffering from diabetic macular edema. All the study participants underwent full ophthalmological assessment with measuring central foveal thickness (CFT) using Heidelberg Optical Coherence Tomography (OCT spectralis). Multifocal electroretinography (mfERG) was performed using RetiMax device in accordance with the ISCEV guidelines. Patients were examined at baseline (pre-injection) and one month after three intravitreal injections of Ranibizumab at monthly intervals (post-injection). The mfERG parameters our study focused on included, relative retinal density of response, P1 wave amplitude and implicit time in the central ring R1. **Results:** The results showed that intravitreal injection of Ranibizumab is accompanied by improvement in BCVA, reduction in central foveal thickness as seen in OCT and improvement in mfERG parameters in the form of increased relative retinal density of response, increased P1 wave amplitude and decreased P1 wave implicit time in the central ring R1. So according to our study multifocal ERG can be used as an effective method in the follow up of patients with central-involved diabetic macular edema after intravitreal injection of Ranibizumab. It can also be used to detect the patient's response to injection. It is obvious that mfERG has a potential role in demonstrating functional retinal impairment in patients with diabetic macular edema. Also our study showed that intravitreal Ranibizumab is not only able to reduce macular edema, but also can aid in the recovery of inner retinal cell function. Thus effectiveness of Ranibizumab in diabetic macular edema (DME) is demonstrated structurally and functionally as it improved the electrophysiological profile in eyes with DME by improving the macular function. **Conclusions:** Functional changes in the retina of patients with central-involved diabetic macular edema assessed by mfERG can complement OCT findings.

[Mina Wahid Sabry Nassif, Osama Elsaied Shalaby, Mohamed Hosny El-Bradey, Heba Mohamed Shafik. **Electrophysiological assessment of central retina following intravitreal injection of Ranibizumab in cases of diabetic macular edema.** *N Y Sci J* 2020;13(1):6-13]. ISSN 1554-0200 (print); ISSN 2375-723X (online). <http://www.sciencepub.net/newyork>. 2. doi: [10.7537/marsnys130120.02](https://doi.org/10.7537/marsnys130120.02).

Keyword: Electrophysiological, central retina, Ranibizumab, diabetic macular edema.

1. Introduction:

In many countries, diabetes mellitus is manifested by diabetic retinopathy which is a major cause of visual loss globally. Vision loss occurs only in advanced stages that shows diabetic macular edema (DME) and/or proliferative diabetic retinopathy (PDR) or their consequences.⁽¹⁾

Diabetic retinopathy represents a microvascular lesion that predominantly affects the small vessels in the form of microvascular occlusion and microvascular leakage. This is postulated to be a result of multiple factors including the selective loss of pericytes, basement membrane thickening and endothelial cell degeneration leading to capillary non perfusion.⁽²⁾

The subsequent retinal hypoxia alters the balance between angiogenic and anti angiogenic growth factors promoting an angiogenic response. It also alters the blood retinal barrier resulting in increased vascular permeability and fluid accumulation with secondary disruption of the retinal microarchitecture.⁽²⁾

A noninvasive imaging modality known as optical coherence tomography (OCT) has been emerged for the evaluation and management of retinal diseases. Optical coherence tomography has the ability to image intraocular structures in vivo with resolution approaching that of histological sections so it acquired ability for detection and quantification of macular and optic nerve head pathologies.⁽³⁾

It allows obtaining cross sectional, high resolution, three dimensional images of the macula. So it's a perfect method for assessment of macular structural changes.⁽³⁾

Electrophysiological tests including full-field flash electroretinography and multifocal electroretinography (mfERG) are important objective tests identifying functional changes of the retina in early phases of diabetic retinopathy.⁽⁴⁾

Multifocal electroretinography (mfERG) was developed by Sutter and Tran in 1992 for recording responses from many regions of the retina. This objective measurement was introduced because full-field flash electroretinography records mass responses from the whole retina.⁽⁵⁾

Currently, the majority of treatments for DME target VEGF to block its action. Ranibizumab is a selective anti-VEGF drug used in this treatment. The current standard methods for evaluating the effectiveness of the anti-VEGF treatment are visual acuity (VA) and optical coherence tomography (OCT).⁽⁶⁾

2. Patients and Methods:

The study involved 24 eyes of 20 patients suffering from diabetic macular edema. All the study participants underwent full ophthalmological assessment with measuring central foveal thickness (CFT) using Heidelberg Optical Coherence Tomography (OCT spectralis). Multifocal electroretinography (mfERG) was performed using RetiMax device in accordance with the ISCEV guidelines.

Patients were examined at baseline (pre-injection) and one month after three intravitreal injections of Ranibizumab at monthly intervals (post-injection).

The mfERG parameters our study focused on included, relative retinal density of response, P1 wave amplitude and implicit time in the central ring R1.

Inclusion criteria:

Diabetic patients with central-involved diabetic macular edema as seen by optical coherence tomography (OCT) planned to receive intravitreal injection of Ranibizumab.

Exclusion criteria:

1. Patients with any media opacity as dense cataract obscuring adequate clinical evaluation or investigations.
2. Patients with severe complications of diabetic retinopathy or retinal vein occlusions as vitreous hemorrhage or neovascular glaucoma.
3. Patients with optic nerve disease such as Glaucoma.

4. Patients suffering from any physical and or mental handicap preventing electrophysiology testing or OCT.

All patients were subjected to:

- 1) Complete history taking.
- 2) Complete ophthalmological examination including:
- 3) Investigations:

Statistical analysis:

Sorting and analysis of data were performed by using Statistical Package for Social Sciences (SPSS) version 20.0 (Armonk, NY: IBM Corp). (Paired t-test, Wilcoxon signed ranks test, Spearman coefficient)

Results:

The study was conducted on 24 eyes of 20 diabetic patients with diabetic macular edema before and after receiving three intravitreal injections of Ranibizumab at monthly intervals as a part of their treatment regimen.

A) Socio-demographic data:

The patients included 8 males (40%) and 12 females (60%), with mean age of 56.65 years and range from 26.0 to 77.0 years. About 55% of the patients were younger than 60 years old while 45% were older than or equal to 60 years old.

B) Clinical data:

All of the enrolled patients were known to be diabetics. One patient had type 1 DM on the other hand 19 patients had type 2 DM. 15 patients were on insulin treatment at time of history taking while 5 patients were on oral hypoglycemic medications (OHGs). The mean known duration of DM for the patients was 18.15 years (range 10-30 years), 20% of the patients were also known to be hypertensive. None of the patients was known to have kidney disease and 80% of them had no co-morbidities. Due to the unavailability of full medical records, records of HbA1C and lipid profiles couldn't be obtained. 8.33 % of the eyes had history of previous laser treatment in the form of panretinal photocoagulation (PRP), while 91.67 % of them were naïve to any type of eye intervention.

C) Clinical results:

1- Best corrected visual acuity (BCVA):

There was 83.3% improvement in BCVA one month after three intravitreal injections of Ranibizumab at monthly intervals compared to baseline.

2- Optical coherence tomography (OCT):

Using SD-OCT Spectralis device (Heidelberg engineering, Heidelberg, Germany), central foveal thickness (CFT) was measured using thickness map in all the patients. There was 26.6% improvement in CRT one month after three intravitreal injections of Ranibizumab at monthly intervals compared to baseline.

Table (1): Comparison between pre-injection and post-injection (after 3 loading doses) according to BCVA (n = 24)

BCVA	Pre-injection	Post-injection	Difference
Min. – Max.	0.05 – 0.40	0.20 – 0.50	0.0 – 0.45
Mean ± SD.	0.18 ± 0.10	0.33 ± 0.11	0.15 ± 0.12
Median	0.15	0.30	0.13
Z (p)	3.979* (<0.001*)		

Z: Wilcoxon signed ranks test p: p value for comparing between pre and post

*: Statistically significant at $p \leq 0.05$

Table (2): Comparison between pre-injection and post-injection (after 3 loading doses) according to OCT CFT (n = 24)

OCT CFT/ μm	Pre	Post	Difference
Min. – Max.	259.0 – 744.0	230.0 – 490.0	-79.0 – 513.0
Mean ± SD.	445.71 ± 125.18	327.21 ± 76.14	118.50 ± 134.10
Median	402.50	312.50	72.50
t (p)	4.329* (<0.001*)		

t: Paired t-test p: p value for comparing between pre and post

*: Statistically significant at $p \leq 0.05$

3- Multifocal electroretinography (mfERG):

Using RetiMax device (CSO, Pisa, Italy) multifocal electroretinogram (mfERG) was performed for all subjects in accordance with International Society for Clinical Electrophysiology of Vision (ISCEV) guidelines. MfERG results were recorded at baseline and one month after three intravitreal injections of Ranibizumab. We focused on mfERG results in the central ring R1 as it is the most affected in diabetic macular edema.

I. Relative retinal density of response:

There was 54.8% improvement in relative retinal density of response in the central ring R1 one month

after three intravitreal injections of Ranibizumab at monthly intervals compared to baseline.

II. P1 wave amplitude:

There was 104.7% improvement in P1 wave amplitude in the central ring R1 one month after three intravitreal injections of Ranibizumab at monthly intervals compared to baseline.

III. P1 wave implicit time:

There was 18 % improvement in P1 wave implicit time in the central ring R1 one month after three intravitreal injections of Ranibizumab at monthly intervals compared to baseline.

Table (3): Comparison between pre-injection and post-injection (after 3 loading doses) according to mfERG parameters in the central ring R1 (n = 24)

Relative retinal density of response nV/deg^2	Pre	Post	Difference
R1			
Min. – Max.	3.65 – 69.76	16.17 – 116.77	-42.07 – 63.42
Mean ± SD.	40.39 ± 18.28	62.50 ± 25.95	22.12 ± 24.80
Median	35.60	59.24	18.74
Z (p)	3.457* (0.001*)		
mfERG P1 amplitude μV	Pre	Post	Difference
P1 R1			
Min. – Max.	-0.24 – 0.66	-0.06 – 0.75	-0.45 – 0.85
Mean ± SD.	0.21 ± 0.23	0.42 ± 0.25	0.22 ± 0.30
Median	0.17	0.43	0.23
Z (p)	2.886* (0.004*)		
mfERG P1 implicit time/ms	Pre	Post	Difference
P1 R1			
Min. – Max.	20.75 – 54.27	20.75 – 54.27	-28.73 – 31.92
Mean ± SD.	44.69 ± 8.84	36.58 ± 10.61	8.11 ± 13.33
Median	46.29	36.71	6.39
t (p)	2.982* (0.007*)		

Z: Wilcoxon signed ranks test

t: Paired t-test

p: p value for comparing between pre and post

*: Statistically significant at $p \leq 0.05$

Correlation between OCT CFT, BCVA and different mfERG parameters:

The correlation between OCT CFT, BCVA and different parameters of mfERG was studied; results are summarized in **Table 4**.

Table (4): Correlation between OCT CFT, BCVA and different parameters of mfERG (n = 24)

Improvement	OCT CFT/ μm		BCVA	
	r_s	p	r_s	p
BCVA	0.665*	<0.001*	-	-
Retinal density nV/deg ²				
R1	0.252	0.234	0.441*	0.031*
mfERG P1 amplitude/ μV				
P1 R1	0.349	0.095	0.362	0.082
mfERG P1 implicit time/ms				
P1 R1	0.241	0.256	0.159	0.457

r_s : Spearman coefficient

*: Statistically significant at $p \leq 0.05$

1) Correlation between OCT CFT and BCVA:

A statistically significant positive correlation was found between the improvement (decrease) in central foveal thickness (μm) as seen in OCT one month after three intravitreal injections of Ranibizumab (Post-injection) and the improvement (increase) in BCVA (decimal) post-injection $r_s = 0.665$, $p < 0.001$. (**Figure 1**).

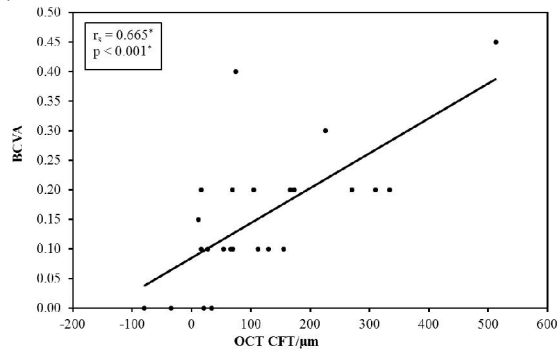


Figure (1): The positive correlation between the improvement in OCT CFT/ μm and the improvement in BCVA (decimal) (n = 24)

2) Correlation between OCT CFT and different mfERG parameters:

No statistically significant correlation was found between the improvement (decrease) in central foveal thickness (μm) as seen in OCT one month after three intravitreal injections of Ranibizumab (Post-injection) and the improvement (increase) in relative retinal density of response (nV/deg²) post-injection in ring 1 (R1: $r_s = 0.252$, $p = 0.234$), the improvement (increase) in P1 wave amplitude (μV) post-injection in ring 1 (R1: $r_s = 0.349$, $p = 0.095$) and the improvement (decrease) in P1 wave implicit time (ms) post-injection in ring 1 (R1: $r_s = 0.241$, $p = 0.256$).

3) Correlation between BCVA and different mfERG parameters:

A- BCVA and relative retinal density of response:

A statistically significant positive correlation was found between the improvement (increase) in BCVA (decimal) one month after three intravitreal injections of Ranibizumab (Post-injection) and the improvement (increase) in relative retinal density of response (nV/deg²) post-injection in ring 1 (R1: $r_s = 0.441$, $p = 0.031$). (**Figure 2**).

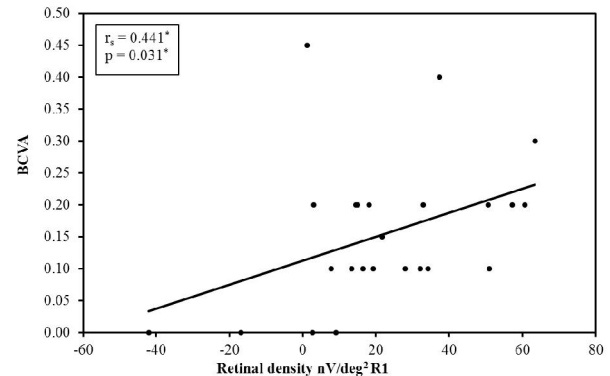


Figure (2): The positive correlation between the improvement in BCVA (decimal) and the improvement in relative retinal density of response (nV/deg²) in R1 (n = 24)

B- BCVA and P1 wave amplitude:

No statistically significant correlation was found between the improvement (increase) in BCVA (decimal) one month after three intravitreal injections of Ranibizumab (Post-injection) and the improvement (increase) in P1 wave amplitude (μV) post-injection in either ring 1 (R1: $r_s = 0.362$, $p = 0.082$).

C- BCVA and P1 wave implicit time:

No statistically significant correlation was found between the improvement (increase) in BCVA (decimal) one month after three intravitreal injections of Ranibizumab (Post-injection) and the improvement

(decrease) in P1 wave implicit time (ms) post-injection in either ring 1 (R1: $r_s = 0.159$, $p = 0.457$).

4. Discussion:

Diabetic retinopathy (DR) is the most common microvascular complication of diabetes mellitus; it is considered the leading cause of vision loss in the general population in many countries, including the adult working population and the elderly.⁽⁷⁾

The Current study highlights diabetic macular edema (DME) which is one of the major causes of impairment of vision in diabetic retinopathy. DME is a complicated process associated with multiple factors; the pathogenesis is thought to be due to altered permeability of the blood-retinal barrier, which results in fluid accumulation at the macula.

Our study is based mainly on electrophysiology in the form of multifocal electroretinography (mfERG). Multifocal electroretinography (mfERG) is a technique that through simultaneous stimulation of different regions of the retina, retinal function can be mapped in the posterior pole. It has been used for recording local electrophysiological responses of different retinal regions.⁽⁸⁾

A standard mfERG is largely a response of bipolar cells. A disease process that substantially decreases the mfERG amplitude must be acting at, or before, the bipolar cells.⁽⁹⁾ A large delay in the timing of mfERG is associated with damage to the photoreceptors or outer plexiform layer.⁽¹⁰⁾ The mfERG has been used to study vascular retinal diseases, post macular surgery changes, and toxicity of drugs such as chloroquine and Vigabatrin.⁽¹¹⁾

Multifocal ERG can also be used to separate retinal diseases from neurological-related eye disorders. A good example is the comparison of mfERGs results to optical coherence tomography (OCT) measurements in order to correlate functional (mfERG) to morphological (OCT) changes as done in our study.

The multifocal electroretinogram is also used as a noninvasive and sensitive method to study the functional status of the macula divided into rings in an objective manner. It is therefore very useful for monitoring diseases affecting the macular area, such as diabetic macular edema and assist in monitoring any abnormalities due to drug toxicity.⁽⁶⁾

Yamamoto et al. (2001)⁽¹²⁾ showed that mfERG readings from the macular area were a good objective indicator of macular function in patients with DME and were strongly correlated with morphologic changes in the macula.

The typical waveform of the primary mfERG response is a biphasic wave with an initial negative deflection followed by a positive peak. There may be a second negative deflection after the peak. The

preferred designation is to label these three peaks N1, P1 and N2 respectively.⁽¹³⁾

The mfERG waveform is largely shaped by bipolar cell activity with smaller contributions from the photoreceptor cells and inner retinal cells (e.g., amacrine and ganglion). **Hood et al. (2002)**⁽⁹⁾ described a model of how the cells of the outer retina contribute to produce the mfERG waveform.

Only damage at or before the bipolar cells will substantially decrease the amplitude of the mfERG. Inner retinal damage to amacrine and/or ganglion cells can affect the waveform of the human mfERG. However, these effects are subtle and do not include a significant decrease in the amplitude of the mfERG.⁽¹⁴⁾

Greenstein et al. (2000)⁽¹⁵⁾ reported decreased amplitude and significantly increased implicit time in patients with CSME. In contrast recent study by **Harrison et al. (2011)**⁽¹⁶⁾ emphasizes the importance of both mfERG characteristics (implicit time and amplitude) in identifying retinal effects in DM. So it seems that mfERG characteristics could be used to examine outer retinal function and monitor impairment of the photoreceptors. These previous reports on retinal electrophysiology usually present data from the response density and the implicit time of the P1 wave in the five rings from the center of the retina.

Our study focused on evaluating these two electrophysiological parameters in addition to P1 amplitude in the central ring R1 because it is commonly affected in cases of central-involved DME.

Our study was based on assessment of central-involved diabetic macular edema from both anatomical aspect using optical coherence tomography (OCT) and electrophysiological aspect using multifocal electroretinography (mfERG). All patients were examined and data were recorded at baseline and one month after three loading doses of intravitreal injections of Ranibizumab at monthly intervals.

We observed that intravitreal Ranibizumab significantly improved BCVA from baseline with a mean difference of (0.15) ($p < 0.001$) between pre-injection and post-injection. At the same time there was significant reduction (improvement) in central foveal thickness (measured in μm by OCT) after the three loading doses of intravitreal Ranibizumab with a mean difference of (118.50 μm) ($p < 0.001$).

The significant improvement in BCVA was due to the reduction in macular edema and vascular leakage as seen in central foveal thickness (CFT). This proves effectiveness of intravitreal Ranibizumab. Our findings are in accordance with previous studies showing the relationship between central retinal thickness and visual acuity after intravitreal Ranibizumab as done by **Nguyen et al. (2010)**.⁽¹⁷⁾

In the current study, a statistically significant correlation was found between BCVA (decimal) and central foveal thickness (measured in μm by OCT). ($r_s = 0.665$, $p = <0.001$).

At the same time, we also found that, in four eyes, macular thickness decreased significantly post-injection as observed by OCT but the visual acuity was not significantly improved; a decrease in macular thickness without any improvement in vision shows a discrepancy between OCT findings and visual function.

These four eyes had a mean difference in BCVA (decimal) of (0.025) between pre-injection and post-injection. However, their mean difference in OCT CFT (μm) between pre-injection and post-injection was (155 μm).

Intravitreal Ranibizumab can effectively alleviate macular edema and increase BCVA in DME. However, most of the current studies have focused on the relationship between visual acuity and central retinal structure, and the direct effects of intravitreal Ranibizumab on the function of the central retina are not fully understood.

Browning et al. (2007)⁽¹⁸⁾ mentioned that although there is correlation between BCVA and CFT there was a great change in visual acuity at any given retinal thickness. Many eyes with thickened macula had excellent visual acuity, and many eyes with normal CFT had decreased visual acuity. Therefore OCT measurement solely may not be a nice replacement for visual acuity in researches on DME. OCT can only record the degree of edema; the duration of edema but the damage to cells cannot be evaluated.

Here comes the significance of multifocal electroretinography (mfERG) as one of the electrophysiological tests that help in the assessment of the central retinal function.

In this study the recorded mfERG data included the retinal response density, P1 wave amplitude and implicit time in the central ring R1. We observed significantly reduced amplitude of mfERG P1 wave and delayed implicit time in patients with DME indicating functional impairments in the outer retina.

Our results demonstrate also low levels of the response density in eyes with DME at baseline in the central ring, at 40% of the normal value (91.6-172.0), with mean response density of (40.39 ± 18.28) These levels were higher than reported in the **LUCIDATE study**⁽¹⁹⁾, which found a 70% reduction in 33 eyes with DME.

Difference in the inclusion criteria between both studies might explain these differences, although both found functional changes in patients with DME.

The results have also shown that, in addition to improvement in BCVA and reduction in CFT,

intravitreal injections of Ranibizumab improved macular function as assessed by mfERG in diabetic patients. The improvement was significant in the form of increased retinal response density, increased P1 amplitude and decreased P1 implicit time in the central ring R1 compared with baseline, after intravitreal Ranibizumab.

We observed improvement (increase) in retinal response density (measured in nV/deg^2) after the three loading doses of intravitreal Ranibizumab with a mean difference of (22.12 ± 24.80) ($p = 0.001$) in R1 between pre-injection and post-injection.

A statistically significant positive correlation was found between the increase (improvement) in BCVA (decimal) and the increase (improvement) in relative retinal density of response (nV/deg^2) post-injection in ring 1 (R1: $r_s = 0.441$, $p = 0.031$).

These results are coinciding with what **Baget-Bernaldiz et al. (2017)**⁽⁶⁾ mentioned in their results where they also observed a positive relationship between the response density and the preservation of the ellipsoid zone and ELM layers in the fovea (R1–R2).

The difference is that in our study we didn't depend only on the relative retinal density of response but we added also the P1 wave amplitude. We noticed improvement (increase) in P1 wave amplitude (measured in μV) after the three loading doses of intravitreal Ranibizumab with a mean difference of (0.22 ± 0.30) ($p = 0.004$) in R1 between pre-injection and post-injection. This showed that intravitreal Ranibizumab is not only able to reduce macular edema, but also can aid in the recovery of inner retinal cell function. Thus effectiveness of Ranibizumab in diabetic macular edema (DME) is demonstrated structurally and electrophysiologically.

We also recorded the P1 wave implicit time in the central ring. An obvious improvement (reduction) in P1 wave implicit time was seen (measured in ms) after the three loading doses of intravitreal Ranibizumab with a mean difference of (8.11 ± 13.33) ($p = 0.007$) in R1 between pre-injection and post-injection.

Holm et al. (2015)⁽²⁰⁾ found that BCVA and CFT were improved after intravitreal Ranibizumab treatment, but there was no difference in mf-ERG results when compared with baseline; this is not consistent with our findings. It may be related to the frequency of intravitreal injection of Ranibizumab. Most researchers believe that the injection project of 3 + PRN is the best scheme for intravitreal Ranibizumab.⁽²¹⁾

Our study results showed statistically significant positive correlation between BCVA and mfERG relative retinal density, So we agree that both OCT and mfERG are complementary to each other. For

example mfERG tends to miss small local abnormalities that are detectable on OCT. On the other hand, OCT can appear normal in the face of clearly abnormal mfERG results. In some cases, functional damage may appear on mfERG before structural change is detected on OCT.

In our study for example, in 4 eyes with still reduced BCVA post-injection, central foveal thickness became within normal range, whereas mfERG parameters were still abnormal, therefore suggesting retinal function impairment in spite of normal anatomy.

So based on our study we believe that multifocal ERG can be used as an effective method in the follow up of patients with central-involved diabetic macular edema after intravitreal injection of Ranibizumab. It can also be used to detect the patient's response to injection and to determine whether to continue injection at the same frequency or not. The most sensitive mfERG parameter to use in the follow up according to our study is the relative retinal density of response in ring 1 (R1).

There are some limitations of the study which include the relative small number of cases, short term follow up and absence of correlation between macular ischemia and mfERG responses.

Recommendations:

Multifocal electroretinography (mfERG) is recommended to be done as an assessment tool to detect early alterations in retinal function in cases of diabetic retinopathy before appearance of structural changes in OCT. Caution should be taken in the exclusive use of structural data from OCT imaging only as it may be misleading in reflecting the retinal function or effects of treatment. Therefore OCT and mfERG should be used together to better demonstrate both structural and functional retinal impairment. Relative retinal density of response is the most important parameter for interpretation of multifocal electroretinography (mfERG) results. Also conducting larger studies that overcome the limitations of this study especially regarding the sample size is recommended.

Financial support and sponsorship

Nil.

Conflicts of interest

There are no conflicts of interest.

References:

1. Group ETDRSR. Grading diabetic retinopathy from stereoscopic color fundus photographs—an extension of the modified Airlie House classification. ETDRS report number 10. *Ophthalmology*. 1991;98(5 Suppl):786-806.
2. Stewart MW. Pathophysiology of Diabetic Retinopathy. In: Browning DJ, editor. *Diabetic Retinopathy: Evidence-Based Management*. New York, NY: Springer New York; 2010. p. 1-30.
3. Grover S, Murthy RK, Brar VS, Chalam KV. Normative data for macular thickness by high-definition spectral-domain optical coherence tomography (spectralis). *American Journal of Ophthalmology*. 2009;148(2):266-71.
4. Lung JC, Swann PG, Chan HH. Early local functional changes in the human diabetic retina: a global flash multifocal electroretinogram study. *Graefes's archive for clinical and experimental ophthalmology = Albrecht von Graefes Archiv fur klinische und experimentelle Ophthalmologie*. 2012;250(12):1745-54.
5. Tehrani NM, Riazi-Esfahani H, Jafarzadehpour E, Mirzajani A, Talebi H, Amini A, et al. Multifocal Electroretinogram in Diabetic Macular Edema; Correlation with Visual Acuity and Optical Coherence Tomography. *J Ophthalmic Vis Res*. 2015;10(2):165-71.
6. Baget-Bernaldiz M, Romero-Aroca P, Bautista-Perez A, Mercado J. Multifocal electroretinography changes at the 1-year follow-up in a cohort of diabetic macular edema patients treated with ranibizumab. *Documenta ophthalmologica Advances in Ophthalmology*. 2017;135(2):85-96.
7. Antonetti DA, Klein R, Gardner TW. Diabetic retinopathy. *The New England Journal of Medicine*. 2012;366(13):1227-39.
8. Sutter EE, Tran D. The field topography of ERG components in man—I. The photopic luminance response. *Vision Research*. 1992;32(3):433-46.
9. Hood DC, Frishman LJ, Saszik S, Viswanathan S. Retinal origins of the primate multifocal ERG: implications for the human response. *Investigative Ophthalmology & Visual Science*. 2002;43(5):1673-85.
10. Hood DC. Assessing retinal function with the multifocal technique. *Progress in Retinal and Eye Research*. 2000;19(5):607-46.
11. Palmowski AM, Sutter EE, Bearnse MA, Jr., Fung W. Mapping of retinal function in diabetic retinopathy using the multifocal electroretinogram. *Investigative Ophthalmology & Visual Science*. 1997;38(12):2586-96.
12. Yamamoto S, Yamamoto T, Hayashi M, Takeuchi S. Morphological and functional analyses of diabetic macular edema by optical coherence tomography and multifocal electroretinograms. *Graefes's archive for clinical and experimental ophthalmology = Albrecht von Graefes Archiv fur klinische und experimentelle Ophthalmologie*. 2001;239(2):96-101.

13. Maiti A, Uparkar M, Natarajan S, Borse N, Walinjar J. Principal components' analysis of multifocal electroretinogram in retinitis pigmentosa. *Indian J Ophthalmol.* 2011;59(5):353-7.
14. Hasegawa S, Takagi M, Usui T, Takada R, Abe H. Waveform changes of the first-order multifocal electroretinogram in patients with glaucoma. *Investigative Ophthalmology & Visual Science.* 2000;41(6):1597-603.
15. Greenstein VC, Holopigian K, Hood DC, Seiple W, Carr RE. The nature and extent of retinal dysfunction associated with diabetic macular edema. *Investigative Ophthalmology & Visual Science.* 2000;41(11):3643-54.
16. Harrison WW, Bearnse MA, Jr., Schneck ME, Wolff BE, Jewell NP, Barez S, et al. Prediction, by retinal location, of the onset of diabetic edema in patients with nonproliferative diabetic retinopathy. *Investigative Ophthalmology & Visual Science.* 2011;52(9):6825-31.
17. Nguyen QD, Shah SM, Khwaja AA, Channa R, Hatf E, Do DV, et al. Two-year outcomes of the ranibizumab for edema of the macula in diabetes (READ-2) study. *Ophthalmology.* 2010;117(11):2146-51.
18. Browning D, Glassman A, Aiello L, Beck R, Brown D, Fong D. Diabetic Retinopathy Clinical Research Network Relationship between optical coherence tomography-measured central retinal thickness and visual acuity in diabetic macular edema. *Ophthalmology.* 2007;114(3):525-36.
19. Comyn O, Sivaprasad S, Peto T, Neveu MM, Holder GE, Xing W, et al. A randomized trial to assess functional and structural effects of ranibizumab versus laser in diabetic macular edema (the LUCIDATE study). *American Journal of Ophthalmology.* 2014;157(5):960-70.
20. Holm K, Schroeder M, Lovestam Adrian M. Peripheral retinal function assessed with 30-Hz flicker seems to improve after treatment with Lucentis in patients with diabetic macular oedema. *Documenta Ophthalmologica Advances in Ophthalmology.* 2015;131(1):43-51.
21. Campochiaro PA, Brown DM, Awh CC, Lee SY, Gray S, Saroj N, et al. Sustained benefits from ranibizumab for macular edema following central retinal vein occlusion: twelve-month outcomes of a phase III study. *Ophthalmology.* 2011;118(10):2041-9.

12/21/2019