



Assessment of Left ventricular function in patients with mitral valve incompetence before and after mitral replacement

Nourhan Hossam Elden Msc, Mohamed Elsaid Elseteiha MD, Mona Adel Elsaidy MD, Amany M. El Lithy MD.

Cardiology Department, Faculty of Medicine, Tanta University, Egypt

Abstract: Background: The mitral valve repair or replacement is indicated for patients with symptomatic mitral incompetence. When operative treatment is being considered, the chronic and often slowly but relentlessly progressive nature of MR must be weighed against the immediate risks and long-term uncertainties attendant on surgery, especially if mitral valve replacement (MVR) is required. **Aim of study:** study and assess the left ventricular function in patients with mitral valve incompetence before and after mitral replacement. **Materials and Methods:** This study included 25 patients with mitral valve incompetence before and after MVR followed up in the outpatient department, cardiology department, Tanta University or admitted to cardiology department **from June 2018 to June 2019. Intervention:** All patients underwent mitral valve replacement. **Outcome Measurements and Statistical Analysis:** Data were expressed as mean \pm standard deviation, ranges or percentages. P value was considered significant if <0.05 . The relation between LVEF preoperative to LVEF (3 and 6 months postoperative) was demonstrated using ANOVA test. **Results:** There was significant statistical difference with reduction of mean LVEF by Simpson method from 50.67 to 43.42 in comparison between preoperative and after 3 months with P value <0.001 . Also, between preoperative and after 6 months measurement there was reduction of mean EF from 50.67 to 43.17 with P value <0.001 . There was significant statistical difference in comparison of mean GLS between preoperative and after 3 months from -19.3 to -15.5 with P value <0.001 . Also, between preoperative and after 6 months measurement there was reduction of mean GLS from -19.3 to -15.33 with P value <0.001 **Conclusions:** In MR there is an increase in the volume overload of LV which keeps the EF in the normal range when contractility is already impaired. After replacement of the mitral valve this is reduction of the LVEF with the internal dimensions after relieving the overload. Using other echocardiographic parameters like pulmonary artery pressure, LA volume help in determining the time of intervention especially in asymptomatic patients.

[Nourhan Hossam Elden, Mohamed Elsaid Elseteiha, Mona Adel Elsaidy, Amany M. El Lithy. **Assessment of Left ventricular function in patients with mitral valve incompetence before and after mitral replacement.** *N Y Sci J* 2019;12(12):80-89]. ISSN 1554-0200 (print); ISSN 2375-723X (online). <http://www.sciencepub.net/newyork>. 11. doi:[10.7537/marsnys121219.11](https://doi.org/10.7537/marsnys121219.11).

Keywords: Assessment; Left ventricular; function; patient; mitral valve incompetence; mitral replacement

1. Introduction

The predominance of valvular disease has shifted from a rheumatic to a degenerative etiology in industrialized countries, leading to important changes in patient characteristics and in the distribution of the type of valvular lesions [1]. Conversely, in developing countries valvular disease is still mainly caused by rheumatic heart disease (RHD) [2].

The field of mitral valve disease diagnosis and management is rapidly changing. New understanding of disease pathology and progression, with improvements in and increased use of sophisticated imaging modalities, have led to early diagnosis and complex treatment [3].

In severe primary mitral regurgitation, the chronic elevation of wall stress caused by the resulting volume overload leads to structural remodelling of the muscular, vascular and extracellular matrix

components of the myocardium. These changes are initially compensatory but in the long term have detrimental effects, which ultimately result in heart failure. Understanding the changes that occur in the myocardium due to volume overload at the molecular and cellular level may lead to medical interventions, which potentially could delay or prevent the adverse left ventricular remodelling associated with primary mitral regurgitation [4].

The mitral valve repair or replacement is indicated for symptomatic patients. When operative treatment is being considered, the chronic and often slowly but relentlessly progressive nature of MR must be weighed against the immediate risks and long-term uncertainties attendant on surgery, especially if mitral valve replacement (MVR) is required [5].

2. Materials and Methods

Our local ethical committee approval was obtained under the number 31867/11/17. A detailed informed consent with guarantee of confidentiality was obtained from the guardians of all participants. All data were expressed as mean \pm standard deviation (SD), median and range or percentages. Statistical analysis was done using the student's t, Mann-Whitney and chi-square tests. Probability value (P) was considered significant at $P < 0.05$.

This study included 25 patients with mitral valve incompetence before and after MVR followed up in the outpatient department, cardiology department, Tanta University or admitted to cardiology department. We included patients with significant MR who underwent MVR: Rheumatic mitral incompetence, degenerative mitral valve disease or mitral valve prolapse. We also excluded patients with LV systolic dysfunction, EF $< 30\%$, Ischemic heart disease needing revascularization, aortic valve diseases more than mild degree, MS more than mild degree, pericardial surgery, myocardial surgery, congenital heart disease surgery, chronic kidney disease and previous mitral valve intervention.

All patients underwent the following.

1- Full history taking included:

Personal, present history, complaint in the form of shortness of breath, awareness of heart beats, fatigue and assessment of functional class.

Clinical examination:

A: General examination:

Includes colour and vital signs assessment, edema, congested neck veins and fine basal crepitation. Right heart failure may manifest as oedema, right hypochondrial pain (liver distension), abdominal swelling (ascites), loss of appetite, and rarely, malabsorption (bowel oedema) [6].

B: Local examination of mitral incompetence:

Inspection and palpation may detect a brisk apical impulse and sustained left parasternal movement due to systolic expansion of an enlarged LA. An LV impulse that is not sustained, enlarged, and displaced downward and to the left suggests LV hypertrophy and dilation. A diffuse precordial lift occurs with severe MR because the LA enlarges, causing anterior cardiac displacement [7].

2. Auscultation:

For examining the heart sound, added sounds and murmurs.

Electrocardiography (ECG):

Standard 12-lead ECG was obtained including (limb lead I, II, III, aVR, aVL, aVF) and chest leads from V1 to v6 for all patients.

Chest x-ray:

For detection of cardiomegaly, lung congestion and mechanical valve movement.

Echocardiography:

An Echocardiogram was done using vivid- E9 echocardiography (GE) Horton Norway medical systems equipped with M5S probe (frequency 1.7–3.3 MHz) for echocardiography. For data acquisition, three complete cardiac cycles were collected and stored in a cine-loop format. Data were acquired with the subjects at rest, lying in the left lateral supine position. Data were stored in a digital format and transferred to the Echo Pac for analysis. Echo examination was performed by an experienced operator and reviewed by another experienced operator on using (Echo Pac110.1.2), from standard apical and parasternal views the following parameters were assessed.

A-Routine assessment of mitral valve incompetence:

1. 2D views echocardiography for evaluation of MV anatomy.

2. Colour flow jet of MR:

A colour Doppler imaging MR jet indicates the presence of MR with appropriate gain to avoid underestimation and overestimation of MR severity. It can help in understanding the mechanism of MR through the direction of the MR jet [8].

Measurement of the MR jet area alone or indexed by LA area is not valid for the severity because the jet area is very dependent on the mechanism of MR and usually underestimates the severity with the eccentric jet [8].

In case of a normal MV structure, normal LV and LA size, a small central jet area of $< 4.0\text{cm}^2$ (or $< 10\%$ of LA area) in multiple views is usually mild MR [8].

3. Density of MR signals:

Using continuous wave Doppler, if the signal is similar in density to that of antegrade flow, this suggests significant MR, whereas a faint signal or an incomplete envelope is typical of mild MR, whereas complete with dense signal indicates severe MR [9].

4. Vena Contracta:

Was measured the VC in a long-axis imaging plane perpendicular to the mitral leaflet closure which independent of flow rate and driving pressure.

A VC width $< 0.3\text{cm}$ denotes mild MR and a VC width $> 0.7\text{cm}$ is specific for severe MR. Intermediate values of VC width (0.3-0.7cm).

5. PISA:

With a central regurgitant jet, RV and orifice area can be calculated by the PISA approach.

6. Pulmonary venous flow reversal

B-Measurement of LA diameter:

Measurement the anteroposterior dimension of the LA at end systole in the parasternal long-axis view from a line drawn through the plane of the aortic valve. (M- Mode).

Normally, the LA diameter is below 4.1Cm in male and below 3.9 in female.

C-Measurement of estimated pulmonary artery pressure (ESPAP)

Continuous wave (CW) Doppler of the tricuspid regurgitation (TR) trace is used to measure the difference in pressures between the right ventricle and right atrium¹⁰.

peak velocity of the envelope is measured (TRmax). A value of ≤ 2.8 m/s suggests low probability, a value of 2.9–3.4 m/s indicates intermediate probability, and a value > 3.4 m/s suggests a high probability for pulmonary hypertension¹⁰.

D-Measurement of LVEF:

Teichholz Method:

The most commonly used measure of cardiac function is the left ventricular EF. This is simply the proportion of blood pumped out of the left ventricle during each cardiac cycle. Therefore to calculate EF we have to estimate the volume of the left ventricle at the end of diastole and systole [11].

Calculation is based on the LV internal diameter at end-diastole and end-systole [11].

$$\text{Ejection fraction} = \frac{\text{EDV} - \text{ESV}}{\text{EDV}} \times 100$$

EF normally $\geq 50\%$.

Mid-range EF is between 40-49%.

Impaired EF is $< 40\%$

Simpson's method:

The apical biplane approach requires tracing of endocardial borders at end-diastole and end-systole in both four-chamber and two-chamber views [12].

End-diastolic volume is calculated from end-diastolic images, and end-systolic volume is calculated from end-systolic images [12].

MAPSE:

Using M-mode echocardiography in an apical view from four sites of the atrioventricular plane corresponding to the septal, lateral, anterior, and posterior walls using the apical four- and two-chamber views by M-mode [13].

The M-mode cursor should always be aligned parallel to the LV walls. The systolic excursion of mitral annulus should be measured from the lowest point at end-diastole to aortic valve closure (end of the T-wave on the electrocardiogram) [14].

The average normal value of MAPSE derived from previous studies for the four annular regions

(septal, anterior, lateral, and posterior) ranged between 12 and 15 mm [15,16].

2D strain (GLS):

The apical long-axis image (i.e three-chamber view) is analysed first. In this view, the movement of aortic valve leaflet helps in timing the aortic valve closure which is essential for the software to be able to perform the deformation analysis, the software automatically defined the end-systolic frame of the cardiac cycle. If the automated frame selection seems inaccurate the same could be adjusted manually in end-systolic frame, endocardial border is tracer manually in its entirety from the beginning at one end of the mitral annulus and ending at the other end.

Region-of-interest (ROI) was adjusted to include the entire myocardial thickness, The width of the ROI can be manually adjusted as required. Care should be taken to avoid including bright echogenic pericardium in the ROI.

The software then tracked the myocardial speckles frame-by- frame and generates moving images displaying the tracking. Visual inspection of the moving image allows the operator to determine the adequacy of the tracking. If the tracking does not seem to be accurate, one can go back and readjust the ROI or select an altogether new ROI. Once the satisfactory tracking is achieved, the same is approved by clicking on the approve button.

The software then divided the LV myocardium into six segments and generates segmental and global longitudinal strain, strain rate, velocity and displacement curves. As the myocardium usually shortens in longitudinal direction during systole, the longitudinal strain and strain rate curves are displayed below the baseline. From these curves **peak-systolic longitudinal strain** could be recorded for each of the myocardial segments. A color-coded parametric image that provides quick visual impression of the timing and the extent of segmental myocardial deformation was also generated by same systems.

The same process is then repeated with the apical four chambers and two- chamber images also. The strain values for all the segments are recorded and averaged to obtain the global longitudinal strain (GLS) presented by white dotted line, Bull's eye displayed the regional and global longitudinal strain as a single comprehensive image.

Tissue Doppler Imaging (TDI):

The TDI cursor was placed at the lateral side of the mitral annulus. In normal myocardium, a Doppler velocity range of -20 to 20 cm/sec is recommended, three major velocities can be recorded: the positive systolic velocity when the mitral ring moves toward the apex (Sm) and two negative diastolic velocities when the mitral annulus moves away from the apex (one during the early phase of diastole [Em] and

another in the late phase of diastole [Am]). By moving the sample volume to the septal site of the mitral annulus, systolic and diastolic velocities of the LV septal wall can be recorded

Normally, S wave is ≥ 8 mm septally and ≥ 10 mm laterally.

Ratio of Trans mitral blood flow velocity to tissue Doppler velocity (E/e ')

E wave was measured by pulsed wave Doppler and e' through tissue Doppler **Normally, this ratio below 8 and above 15 (indicates that there is increase in filling pressure).**

3. Results

The age in this study ranged from 28 to 67 with mean 42.44 ± 10.46 .

Ten of the study population were males (40%) while 15 were females (60%).

Etiology in this study was divided into RHD, degenerative heart disease and mitral valve prolapse with their percentage 72%, 8% and 20% respectively.

Ten cases were on long acting penicillin in the study population (40%).

Associated other medical history that presented in this study are DM, hypertension and dyslipidemia with their percentage: 44%, 60% and 16% respectively.

Table 1: Baseline characteristics and demographic data.

		Mean \pm SD	(Min-Max)
Age		42.44 \pm 10.46	(28 – 67)
HR		98.6 \pm 17.35	(75 – 130)
Systolic Blood Pressure		117.2 \pm 20.92	(75 – 130)
Diastolic Blood Pressure		78.8 \pm 13.01	(60 – 100)
		Number of frequency	Percentage
Sex	Male	10	40 %
	Female	15	60 %
Etiology	RHD	18	72 %
	Degenerative	2	8 %
	Prolapse	5	20 %
Association of another valve lesion	Absent	12	48 %
	mild mitral stenosis	2	14 %
	Mild tricuspid regurge	2	10%
	Moderate tricuspid regurge	3	12 %
	Mild aortic stenosis	2	10 %
	Mild aortic regurge	1	6 %
long acting penicillin		10	40 %
DM		11	44 %
HTN		15	60 %
Dyslipidemia		4	16 %
Dyspnea		16	64 %
Palpitation		15	60 %
Lower limb edema		14	56 %
Easy fatigability		8	32 %
Atrial fibrillation		10	40 %
S1	Diminished	14	56 %
	Normal	11	44 %
S2	Normal	15	60 %
	Accentuated	10	40 %
Pan-systolic murmur		14	56 %

Table 2: Echocardiographic parameters (preoperative) n (25).

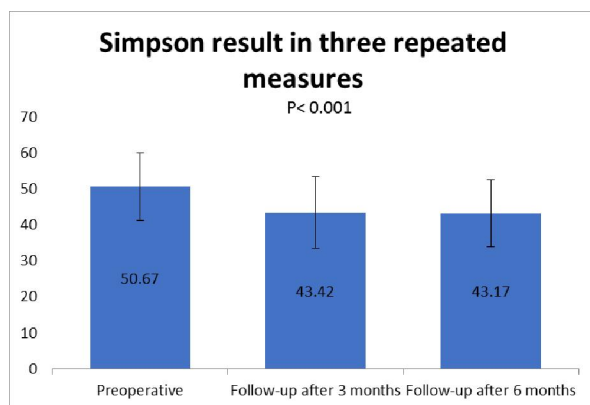
	Mean±SD		(Min- Max)
LA diameter	43.64	± 4.27	(37 – 50)
ESPAP	42.36	± 8.89	(28 – 56)
EDD	55.12	± 4.6	(47 – 63)
ESD	47.52	± 4.7	(37 – 55)
LVEF by Simpson	50.2	± 9.55	(32 – 67)
MAPSE	11.48	± 4.33	(4 – 18)
E/e' ratio	12.7	± 4.39	(6 – 19)
S wave	10.8	± 3.55	(5 – 17)
Global Longitudinal strain	-19.04	± 4.83	(-26 – -10)
Peak systolic strain	-19.7	± 4.05	(-27 – 25)

Table 3: Echocardiographic parameters (3-month postoperative) n (25).

	Mean ± SD		(Min-Max)
LA diameter	40	± 3.38	(36 – 50)
ESPAP	31.58	± 10.79	(13 – 53)
EDD	49.32	± 3.37	(43 – 56)
ESD	43.72	± 3.8	(36 – 50)
LVEF by Simpson	43.42	± 10.01	(22 – 60)
E/e' ratio	10.42	± 2.79	(7-15)
S wave	8.5	± 2.84	(5 – 16)
Global Longitudinal strain	-15.54	± 5.31	(-23 – -6)
Peak systolic strain	-14.7	± 4.4	(-20– -6)

Table 4: Echocardiographic Parameters after 6 months n (25).

	Mean ± SD		(Min-Max)
LA diameter	40.21	± 3.31	(36 – 50)
ESPAP	31.38	± 10.73	(14 – 50)
EDD	49.52	± 3.44	(43 – 55)
ESD	43.52	± 3.7	(37 – 49)
LVEF by Simpson	43.17	± 9.35	(22 – 60)
E/e' ratio	10.4	± 2.65	(6 – 15)
S wave	8.58	± 2.99	(4 – 15)
Global Longitudinal strain	-15.33	± 5.25	(-24 – -6)
Peak systolic strain	-14.58	± 4.5	(-20 – -6)

**Figure 1: showing EF results by Simpson method in three settings (preoperative - 3 and 6 months postoperative).**

There was significant statistical difference with reduction of mean EF by Simpson method from 50.67 to 43.42 in comparison between preoperative and after 3 months with P value <math>< 0.001</math>.

Also, between preoperative and after 6 months measurement there was reduction of mean EF from 50.67 to 43.17 with P value <math>< 0.001</math>.

There was significant statistical difference in comparison of mean GLS between preoperative and after 3 months from -19.3 to -15.5 with P value <math>< 0.001</math>.

Also, between preoperative and after 6 months measurement there was reduction of mean GLS from -19.3 to -15.33 with P value <math>< 0.001</math>.

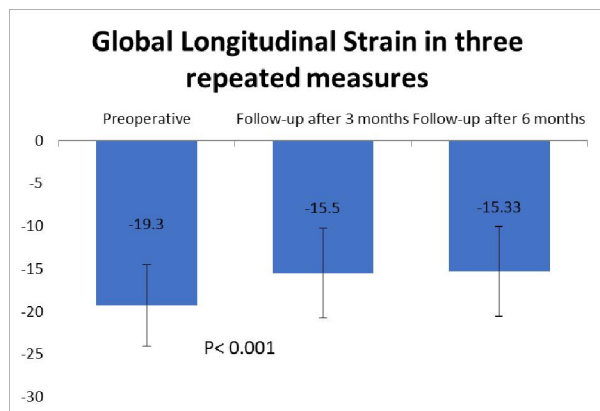


Figure 2: Showing LV EF results by 2D global longitudinal strain in three settings (preoperative - 3 and 6 months postoperative).

4. Discussion

This study included 25 patients with chronic MR who presented to Tanta university hospital during the period from June 2018 to June 2019 (18 with rheumatic heart disease (72%), 2 with degenerative mitral valve disease (8%) and 5 with mitral valve prolapse (20%). They underwent MVR.

Echocardiography assessment was performed using 2D and TDI techniques to the study population preoperative and then after MVR, follow up echocardiographic assessment was done after three months and after six months from the day of the operation.

This study demonstrated that mitral valve replacement was associated with progressive reduction of both LV dimensions and systolic function as measured by standard echocardiography, tissue Doppler imaging and GLS analysis. These changes persisted in the follow up period [up to 6 months postoperatively].

Adaptation of the LV to chronic volume overload occurs with gradual enlargement of the chamber and an increase in myocardial mass through the **Frank-Starling** mechanism. This response progresses slowly with a change in geometry, a rearrangement and slippage of myofibrils, and the addition of new sarcomeres. As a result, there is little change in midwall sarcomere length and in this manner; the myocardium maintains a normal preload reserve. The compensatory increase in LV mass prevents the development of large increments in systolic wall stress, which, in turn allows muscle shortening to remain normal and increased LV SV is generated simply by the large EDV [17].

In compensated MR, systolic wall stress is normal or near normal and shortening is preserved, despite substantial LV enlargement [17,18].

In decompensated MR, LV enlargement is marked, systolic wall stress is elevated and shortening is well below normal.

So, after MVR in chronic compensated MR, the end-diastolic dimension and systolic wall stress decreased to normal despite this favourable change in wall stress, shortening decreased significantly. It thus appears that the postoperative decrease in shortening cannot be explained on the basis of an increase in LV after load (“after load excess”). In such patients, the valve replacement (with loss of integrity of papillary muscles and chordae, and a tethering of posterior basal wall motion by the prosthesis) is most likely responsible for the postoperative decline in fiber shortening and EF [17,18].

In decompensated MR, after valve replacement there is persistent LV enlargement, a further increase in end-systolic stress and a considerable decrease in shortening [18].

In a similar study performed by **Rakesh M. Suri et al.** [19], ((861 patients with mitral valve prolapse who underwent mitral valve repair or replacement were evaluated preoperative (within 6 months) and 5 days postoperatively)). demonstrated that LVEF declined from ($62.9 \pm 9.9\%$ to $53.1 \pm 11.3\%$) soon after surgical correction of mitral regurgitation either by mitral valve repair or mitral valve replacement (P value < 0.001) [19]. Beside EF there was also significant reduction in the EDD from mean (69.9 ± 7.6 mm to 53.1 ± 7.7 mm) (P value < 0.001) [19].

Similarly, regarding internal dimensions in the study performed by **Alexis E. Shafii et al.** [20], (included 2,778 patients with isolated degenerative mitral valve disease underwent valve repair or replacement and had >1 postoperative echocardiography). There was a sharp decrease in LV end-diastolic and end-systolic diameters during the first year after surgery, with a more rapid decline in end-diastolic than end-systolic diameter. The mean end-diastolic diameter decreased from (5.7 ± 0.80 cm to 4.9 ± 1.6 cm) ($P < 0.0001$) within the first 6 months after surgery [20]. the mean end-systolic diameter also decreased, but more gradually from (3.4 ± 0.71 cm to 3.2 ± 1.4 cm) ($P < 0.0001$) within the first 6 postoperative months [20].

But on the opposite side, in a previous study there was increase in the EF post replacement which may be explained by reverse remodeling.

Their hypotheses was that: patients most likely to achieve favourable reverse remodelling were those who did not exhibit preoperative changes consistent with long-standing disease, such as LV dilation, LA enlargement, and LV dysfunction [20], which was not the case with our patients.

The study performed by **Sophie Mascle et al.** [21], (88 patients with severe degenerative mitral

regurgitation were included) and echocardiography was performed before and 6 ± 1 months after mitral valve surgery. They divided their patients into two groups: group A (postoperative LVEF $\geq 50\%$) and group B (postoperative LVEF $< 50\%$) and showed that GLS was a good predictor in the assessment of LVEF postoperative MVR (mean $-19.1 \pm 3.6\%$ to $-19.6 \pm 3.6\%$ vs. $-17 \pm 2.8\%$) also, found out that ESD mildly decreased after replacement in postoperative EF $\geq 50\%$ ($36 \pm 6.1\text{mm}$ to $35 \pm 5.8\text{mm}$) P value (0.001) but increased in postoperative EF $< 50\%$ (36 ± 6.1 to 40.6 ± 5.3) P value (0.002) [21]. cause of the coronary artery disease that wasn't excluded in this study with high percentage in group B (20%) comparing to group A (13%).

Whereas, EDD was decreased after replacement whatever EF post replacement from (52.3 ± 23.3 to 54.7 ± 7.8 vs. 61.5 ± 6.6).

In a similar study conducted by **Antônio Sérgio Cordeiro da Rocha et al.** [22] (11 patients were studied in the preoperative period, (median of 36 days) in the early postoperative period (median of 9 days) and in the late postoperative period (mean of 38.5 ± 37.6 months). illustrated that EDD was markedly decreased from mean (79 ± 6 to 63 ± 9 vs. 64.5 ± 14) P value (0.001) whereas ESD and EF decreased without significant value [23].

Regarding LA diameter and ESPAP:

There was a marvellous reduction of both LA diameter and ESPAP in the evaluation 3 and 6 months post MVR.

LA diameter decreased from (43.64 ± 4.27 to 40 ± 3.38) P value = (0.001) and from (43.64 ± 4.27 to 40.21 ± 3.31) P value= 0.005 post 3 and 6 months of the replacement respectively.

ESPAP decreased from ($42.36 \pm 8.89\text{mmHg}$ to $31.58 \pm 10.79\text{mmHg}$) P value $< (0.001)$ and ($42.36 \pm 8.89\text{mmHg}$ to $31.38 \pm 10.73\text{mmHg}$) P value $< (0.001)$ 3 and 6 months after replacement respectively.

The increased LA pressure in MV disease is passively transmitted to the pulmonary vasculature and can lead to an increase in peripheral vascular resistance (PVR). Some other factors such as reactive pulmonary vasoconstriction and organic changes in pulmonary vasculature are also responsible for this increase in PVR²⁴. Following MV surgery, LA loading can be adequately decompressed. This decompression is very influential in the regression of pulmonary hypertension [25].

In a similar study performed by **Shady E. Elwany et al.** [25], (The study included 30 patients with a baseline systolic pulmonary artery pressure of at least 40 mmHg who underwent elective MVR for rheumatic mitral valve regurgitation).

Came in agreement with our result in the improvement of LA diameter post replacement from mean (70mm to 65mm) P value=0.001 and ESPAP declined from mean (55 to 17mmHg) P<0.001 [23].

In a contrary study conducted by **Alexis E. Shafii et al.** [20], Came with different result with marked LA dilatation post-operatively ($4.9 \pm 0.90\text{cm}$ to $5.3 \pm 1.02\text{cm}$) P value=(0.001)²⁰. The effect of increased preoperative LA size on functional and morphologic ventricular recovery also supports the use of early surgery. Considering that structural changes in the left atrium relate to the chronicity of exposure to abnormal filling pressures and volumes²⁶, dilation portends negatively on ventricular reverse remodeling²⁰. The aging of this study population which was represented with mean 57 ± 13 while in our study was 42.44 ± 10.46 . The pathologic changes in the LA with aging are an aggravation of atrial fibrosis with cellular hypertrophy, and the development of extensive collagenous septa. These pathologic changes may contribute to the age-related difference in LA reverse remodelling which approved in the study conducted by **Deok-Kyu Cho et al** [27].

While, the study conducted by **Sophie Mascle et al.**²¹, found out that the reduction of ESPAP related to LVEF postoperative P value (0.009) and this may be explained by the aetiology of the MR and the result of LVEF that below 50% that gave that significant result [21].

Regarding LV filling pressure by E/e' ratio:

There is no correlation between LVEF and E/e' ratio which was approved in the study conducted by Jeffrey J. Olson et al. [28] without significant P value.

Also, in our study we found out that there was significant decrease of E/e' ratio despite of decrease of LVEF post replacement with P value (0.02) post 3 months and P value (0.009) post 6 months which indicated that there was improvement of the congestive symptoms despite of reduction of EF.

Cause of LV filling pressure is related to the condition of the patient and can be relieved after adjustment of medical treatment including diuretics.

Regarding the demographics in this study:

We found out in this study that males represent 40% while females represent 60% with mean age 42.44 ± 10.46 .

The chronic MR was considered to be the result of rheumatic fever in 18 patients (72%), 2 patients (8%) had degenerative heart disease and 5 patients (20%) had mitral prolapse.

This came in disagreement with the study conducted by **Alexis E. Shafii et al.** [20] women represented 35% of the cases with mean age 57 ± 13 all with isolated degenerative mitral valve incompetence [20].

In a similar study performed by **Shady E. Elwany et al.**²⁵ Thirty patients (11 men and 19 women), median age 31 years (range:16–52), were included in the study and all with rheumatic mitral valve regurgitation [²⁵].

This came in disagreement in the study conducted by **Alexis E. Shafii et al.** [²⁰] women represented 35% of the cases with mean age 57 ± 13 all with isolated degenerative MR [²⁰].

In a similar study conducted by **J Shuhaiber et al.** [²⁹], the rheumatic fever was the most common cause in chronic MR [²⁹].

Also, **Maurice Enriquez-Sarano et al.** [³⁰] that found out that (Rheumatic fever represent 2-5% while primary myxomatous, flail mitral and annular calcification represent 60-70%) [³⁰].

Sophie Mascle et al. [²¹], also discovered that degenerative heart disease represent most common cause of the MR [²¹]. The study was conducted on 88 patients representing to University hospital Rennes, France. In most developed countries, there in regression of the incidence of rheumatic Valvular affection.

This conflict appears to be accepted regarding the country in which the study was done, in developing countries the RHD still present and represent the major cause till now this is related to poor hygiene, overcrowding and malnutrition [²¹].

Regarding clinical finding and symptomatology:

Ten patients (40%) had AF while 15 patients presented with sinus rhythm. About 64% of the cases in this study complained of dyspnea with effort, (60%) palpitation and (56%) lower limb edema.

In comparison with the study conducted by **HV Huikuri et al.** [³¹], there were 6 patients had AF while 5 patients were sinus rhythm and all of them had dyspnea [¹⁷]. In the study performed by **Alexis E. Shafii et al.** [²⁰], 12% of the cases had AF while symptoms of heart failure presented only in 23% [²⁰].

Conclusion

In MR there is an increase in the volume overload of LV which keeps the EF in the normal range when contractility is already impaired.

After replacement of the mitral valve this is reduction of the LVEF with the internal dimensions after relieving the overload.

Using other echocardiographic parameters like pulmonary artery pressure, LA volume help in determining the time of intervention especially in asymptomatic patients.

Therefore, early diagnosis and treatment with early intervention play an important effect in preservation of the EF with good outcomes.

References

1. Lung B, Vahanian A. Epidemiology of valvular heart disease in the adult. *Nat Rev Cardiol.* 2011;8(3):162-172. doi:10.1038/nrcardio.2010.202.
2. Carapetis JR, Steer AC, Mulholland EK, Weber M. The Global Burden of Group A Streptococcus Disease. *Lancet Infect Dis.* 2005;5(11):685-694. doi:10.1016/S1473-3099(05)70267-X.
3. Nishimura R, Vahanian A, Eleid M, Lancet MM-T, 2016 undefined. Mitral valve disease—current management and future challenges. Elsevier. <https://www.sciencedirect.com/science/article/pii/S0140673616005584>. Accessed August 14, 2019.
4. Keir M, Africa MP-C journal of, 2018 undefined. Left ventricular remodelling in chronic primary mitral regurgitation: implications for medical therapy. ncbi.nlm.nih.gov. <https://www.ncbi.nlm.nih.gov/pmc/articles/PMC6002796/>. Accessed August 14, 2019.
5. Gaasch WH, Meyer TE. Left Ventricular Response to Mitral Regurgitation. *Circulation.* 2008;118(22):2298-2303. doi:10.1161/CIRCULATIONAHA.107.755942
6. Watson R, Gibbs C, Journal GL-BBM, 2000 undefined. ABC of heart failure: clinical features and complications. ncbi.nlm.nih.gov. <https://www.ncbi.nlm.nih.gov/pmc/articles/pmc1117436/>. Accessed April 20, 2019.
7. Бабак О, Фадєєнко Г, Зайченко О. Management of patient with a heart murmur. 2012. <http://repo.knmu.edu.ua/handle/123456789/2464>. Accessed April 20, 2019.
8. Zoghbi W, Adams D,... RB-J of the, 2017 undefined. Recommendations for noninvasive evaluation of native valvular regurgitation: a report from the American Society of Echocardiography developed in collaboration with. onlinejase.com. [https://www.onlinejase.com/article/S0894-7317\(17\)30007-X/abstract](https://www.onlinejase.com/article/S0894-7317(17)30007-X/abstract). Accessed April 20, 2019.
9. Sawonik S, Prasał M, Geça R,... AW-, 2019 undefined. Current techniques for echocardiographic imaging of the mitral regurgitation. medical-technologies.eu. http://www.medical-technologies.eu/upload/current_techniques_for_echocardiographic_imaging_-_sawonik.pdf. Accessed April 20, 2019.
10. Parasuraman S, Walker S, Loudon B,... NG-IH &, 2016 undefined. Assessment of pulmonary artery pressure by echocardiography—a comprehensive review. Elsevier.

- <https://www.sciencedirect.com/science/article/pii/S2352906716300379>. Accessed August 15, 2019.
11. Ryding A. *Essential Echocardiography*; 2013.
 12. Otto C. *Textbook Of Clinical Echocardiography*.
 13. Carlhäll C, Wigström L, Heiberg E, Karlsson M, Bolger AF, Nylander E. Contribution of mitral annular excursion and shape dynamics to total left ventricular volume change. *Am J Physiol Circ Physiol*. 2004;287(4): H1836-H1841. doi:10.1152/ajpheart.00103.2004.
 14. Claus P, Weidemann F, Dommke C,... VB-U in medicine, 2007 undefined. Mechanisms of postsystolic thickening in ischemic myocardium: mathematical modelling and comparison with experimental ischemic substrates. Elsevier. <https://www.sciencedirect.com/science/article/pii/S030156290700275X>. Accessed April 20, 2019.
 15. Adel W, Roushdy AM, Nabil M. Mitral Annular Plane Systolic Excursion-Derived Ejection Fraction: A Simple and Valid Tool in Adult Males With Left Ventricular Systolic Dysfunction. *Echocardiography*. 2016;33(2):179-184. doi:10.1111/echo.13009.
 16. ALAM M, HÖGLUND C, THORSTRAND C, PHILIP A. Atrioventricular plane displacement in severe congestive heart failure following dilated cardiomyopathy or myocardial infarction. *J Intern Med*. 1990;228(6):569-575. doi:10.1111/j.1365-2796.1990.tb00281.x.
 17. Kim H, Cho G, Hwang I, Choi H,... JP-JC, 2018 undefined. Myocardial strain in prediction of outcomes after surgery for severe mitral regurgitation. Elsevier. <https://www.sciencedirect.com/science/article/pii/S1936878X18302973>. Accessed July 4, 2019.
 18. Gaasch W, journal MZ-E heart, 1991 undefined. Left ventricular function after surgical correction of chronic mitral regurgitation. academic.oup.com. https://academic.oup.com/eurheartj/article-abstract/12/suppl_B/48/433270. Accessed July 5, 2019.
 19. Suri R, Schaff H, Dearani J,... TSI-TJ of thoracic, 2008 undefined. Determinants of early decline in ejection fraction after surgical correction of mitral regurgitation. Elsevier. <https://www.sciencedirect.com/science/article/pii/S0022522307019678>. Accessed July 4, 2019.
 20. Shafii A, Gillinov A, Mihaljevic T,... WS-TA journal of, 2012 undefined. Changes in left ventricular morphology and function after mitral valve surgery. Elsevier. <https://www.sciencedirect.com/science/article/pii/S0002914912010570>. Accessed June 30, 2019.
 21. Masclé S, Schnell F, Thebault C,... HC-J of the A, 2012 undefined. Predictive value of global longitudinal strain in a surgical population of organic mitral regurgitation. Elsevier. <https://www.sciencedirect.com/science/article/pii/S0894731712003525>. Accessed May 23, 2019.
 22. Rocha A, Rocha N,... RS-A brasileiros, 2003 undefined. Improvement in left ventricular dysfunction after surgical correction of mitral regurgitation. *SciELO Bras*. http://www.scielo.br/scielo.php?pid=S0066-782X2003000100002&script=sci_arttext&tlng=pt. Accessed May 30, 2019.
 23. Corciova F, Corciova C,... CG-HS, 2012 undefined. Echocardiographic predictors of adverse short-term outcomes after heart surgery in patients with mitral regurgitation and pulmonary hypertension. https://www.researchgate.net/profile/F_Corciova/publication/225373486_Echocardiographic_Predictors_of_Adverse_Short-term_Outcomes_after_Heart_Surgery_in_Patients_with_Mitral_Regurgitation_and_Pulmonary_Hypertension/links/5bb7854f92851c7fde2f1291/Echocardiographic-Predictors-of-Adverse-Short-term-Outcomes-after-Heart-Surgery-in-Patients-with-Mitral-Regurgitation-and-Pulmonary-Hypertension.pdf. Accessed June 30, 2019.
 24. Lafçı G, Diken A, Gedik H,... KK-A of the, 2012 undefined. Alterations in pulmonary artery pressure following mitral valve replacement. [journalagent.com](http://www.journalagent.com). <http://www.journalagent.com/z4/jvi.asp?pdire=tkd&plng=eng&un=TKDA-02328&look4=>. Accessed June 30, 2019.
 25. Elwany S, Mohamed A, of AE-H-TEJ, 2013 undefined. Outcome after mitral valve replacement in patients with rheumatic mitral valve regurgitation and severe pulmonary hypertension. ejca.eg.net. <http://ejca.eg.net/article.asp?issn=1687-9090;year=2013;volume=7;issue=2;spage=74;epage=78;aulast=Elwany>. Accessed May 23, 2019.
 26. Abhayaratna W, Seward J,... CA-J of the, 2006 undefined. Left atrial size: physiologic determinants and clinical applications. [onlinejacc.org](http://www.onlinejacc.org). <http://www.onlinejacc.org/content/47/12/2357.abstract>. Accessed June 30, 2019.
 27. Cho D, Ha J, Chang B, Lee S,... SY-TA journal of, 2008 undefined. Factors determining early left atrial reverse remodeling after mitral valve surgery. Elsevier. <https://www.sciencedirect.com/science/article/pii/S0002914907019248>. Accessed July 8, 2019.
 28. Bruch C, Stypmann J, Gradaus R,... GB-TA journal of, 2004 undefined. Usefulness of tissue

- Doppler imaging for estimation of filling pressures in patients with primary or secondary pure mitral regurgitation. Elsevier. <https://www.sciencedirect.com/science/article/pii/S0002914903014887>. Accessed May 23, 2019.
29. Shuhaiber J, Cardio RA-EJ of, 2007 undefined. Meta-analysis of clinical outcomes following surgical mitral valve repair or replacement. academic.oup.com. <https://academic.oup.com/ejcts/article-abstract/31/2/267/453708>. Accessed May 23, 2019.
30. Enriquez-Sarano M, Nkomo VT, Michelena HI. Mitral Regurgitation. In: Valvular Heart Disease. Totowa, NJ: Humana Press; 2009:221-246. doi:10.1007/978-1-59745-411-7_10.
31. Heart HH-, 1983 undefined. Effect of mitral valve replacement on left ventricular function in mitral regurgitation. heart.bmj.com. <https://heart.bmj.com/content/49/4/328.short>. Accessed May 23, 2019.

12/17/2019