



The effect of *Nigella sativa* gel as an adjunctive therapy in patients with chronic periodontitis: A clinical and histological study

Maram Albarrak¹, Samah Alaqeel¹, Ghada Bassiouny², Shokria Ghneim³

¹Graduated student, Collage of dentistry, Qassim University, Saudi

²Associate Professor In periodontology and Oral medicine, Collage of dentistry, Qassim University, Saudi Arabia and faculty of Dentistry, Alexandria University, Egypt

³Professor in Oral pathology, Collage of dentistry, Tanta University, Egypt
maram.albarrak@qudent.org

Abstract: **Aim:** *Nigella Sativa* gel in the treatment of chronic periodontitis. **Background:** Periodontitis is a destructive, inflammatory, pathological condition that affects the periodontium. It's characterized by an extreme host reaction to gram negative tooth related pathogens, which destroys the surrounding tooth supporting tissues. World is increasingly trying to replace the synthetic drugs with the therapeutic effect of the natural herbal products. *Nigella sativa* is an annual flowering plant that has been used from a long time as a herbal medicine that promote tissue healing and modulate host responses. **Purpose:** the aim of this study was to evaluate the effect of *Nigella Sativa* (thymoquinone) gel in the treatment of chronic periodontitis. **Methodology:** Forty periodontal sites in twenty patients with mild to moderate chronic periodontitis aged between 35 and 45 years were included in this study. Full mouth scaling and root planning (SRP) was provided, then subgingival application of the thymoquinone gel to the experimental sites compared to (SRP) only in control sites. The clinical parameters, bleeding index (BI), gingival index (GI) plaque index were recorded at baseline and after 6 weeks post gel application. The anti-inflammatory effect of the *Nigella sativa* gel was also evaluated by the histological examination of the gingival biopsy. **Results:** Significant reduction in mean of (BI), (GI) and (PI) was observed from baseline to 6th week post-gel application. The histological results proved that thymoquinone gel was effective in reduction of the inflammatory cells in experimental sites more than the control sites. **Conclusion:** Local application of thymoquinone gel in conjunction with SRP showed anti-inflammatory effect both clinically and histologically.

[Maram Albarrak, Samah Alaqeel, Ghada Bassiouny, Shokria Ghneim. **The effect of *Nigella sativa* gel as an adjunctive therapy in patients with chronic periodontitis: A clinical and histological study.** *N Y Sci J* 2019;12(12):27-34]. ISSN 1554-0200 (print); ISSN 2375-723X (online). <http://www.sciencepub.net/newyork>. 4. doi:[10.7537/marsnys121219.04](https://doi.org/10.7537/marsnys121219.04).

Key word: Periodontitis- *Nigella sativa*.

Abbreviations: *Nigella Sativa* (NS)

1. Introduction

Periodontitis is a destructive, inflammatory condition that affects the periodontium of the teeth. (1) It is characterized by an extreme host reaction to gram-negative tooth-related pathogens, which destroys the surrounding cells and tooth-supporting tissues, include the alveolar bone, periodontal ligaments and at the end lead to tooth loss. (2-3)

Despite the fact that oral bacteria, and toxins, are considered to be the main causative factors for the initiation of the inflammatory processes, the host inflammatory response is primarily responsible for the progression of the disease and for most of the breakdown of dental connective tissues. (4-5)

Mechanical and surgical therapy approaches, along with antibacterial therapy, have been carried out for a generation. Contemporary treatment modalities

and traditional modalities have also been examined in detail. (6) Therefore, many immune-response modulatory agents, including antioxidant and anti-inflammatory agents, were investigated in the hope of preventing and eliminating the deterioration of tooth-supporting tissues. (7-8)

Non-surgical mechanical therapy is an important method of periodontal treatment. However, the increase in the pocket depth and complicating anatomical factors limit the potency of scaling and root planing (SRP), thus compromising the results. (9-10)

In addition to the well-known chemotherapeutic antimicrobials and biomaterials, there are a lot of substances belong to the alternative complementary therapeutic agents have gained special interest, and

also, have the potential to augment results of periodontal therapy. (11)

Nowadays the world is increasingly trying to replace synthetic drugs with the therapeutic effect of natural products. Interest in medicinal plants has increased due to expanded efficiency of new plant-derived drugs and the growing interest in natural products. (12)

As a result of the side effects of the conventional medicine, the use of natural and herbal products as an alternative to conventional treatment in healing and treatment of various diseases become popular in the last few decades. (13)

Numerous remarkable helping plants surfaced began to be of interest in home-grown medications. One of these plants was *Nigella sativa* generally known as the black seed. (14) Distributed reports that explored the effect of *Nigella sativa* (NS) and its dynamic constituent, thymoquinone (TQ) uncovered that black seed has a potential helpful impact on oral health and diseases management. Such outcomes are empowering for the consolidation of these plants in dental therapeutics and oral hygiene items. (15)

Nigella sativa is an annual flowering plant. It is 20–30 cm (7.9–11.8 inch) tall with linear-lanceolate leaves. The gentle flowers have 5-10 petals with multiple colors. It has large fruit and inflated capsule composed of 3-7 united follicles; each follicle is filled with numerous seeds. (16) The nutritional compositions of *N. Sativa* are carbohydrates, vitamins, fats, mineral elements and proteins with eight to nine essential amino acids. (17)

This mild aromatic herb belongs to the Middle East and it has been used as a traditional home remedy for many years. (18)

In Islamic religion, it is utilized so extensively and it is known as the seed of blessing "Habbatul Barakah. Its therapeutic use was initiated by Prophet Mohammed (peace be upon him) when made reference to its helpful capability of treatment when he said that "The black seed is a cure for every disease except for death". (19)

The chemical composition contains multiple volatile and non-volatile oils in addition to numerous other active ingredients like minerals, coumarins, saponins, alkaloids, phenolic compounds, and steroidal compounds. (20-21-22-23)

The pharmacological investigation of the seed extracts reveals abroad spectrum of activities including anti-inflammatory, immunopotential, antitumor, antihypertensive, antidiabetic, antihistaminic, antibacterial, antiparasitic, and antifungal and antioxidant. (24-25) Therefore, the present research was designed to study the effect of *Nigella Sativa* gel in the treatment of chronic periodontitis by comparing healing of chronic

periodontitis and level of inflammation between two sides of the mouth.

2. Materials and methods:

Study Design and Sample Selection:

After taking the ethical approval number (EA/F-4002-19) from the ethics committee at the college of dentistry, Qassim University, a randomized experimental longitudinal study (split mouth design) was conducted on female patients attending the Dental clinics, college of dentistry, Qassim University, KSA. In this study, 40 sites in 20 chronic periodontitis female patients were selected. A written informed consent was taken from the patients before their participation in the study. Inclusion criteria for the study were patients with mild to moderate chronic periodontitis based on the classification of periodontal diseases by the International Workshop for Classification of Periodontal Diseases and Conditions of the American Academy of Periodontology in 1999(15), adequate attached gingiva, and age range between 35 to 45 years and have 3 pockets at least in both sides with 2 teeth in contralateral sides indicated for gingivectomy for therapeutic or prosthetic reasons.

Medically compromised patients, pregnant and lactating women and women who are taking contraceptive drugs or antibiotics were excluded from the study. This was confirmed by taking the medical history and by doing general and oral examination.

Thymoquinone gel preparation:

Pure thymoquinone was converted to powdered form using a mortar and pestle. The gel was prepared by 14 gm of Carbopol mixed with 485 ml of hot water heated at a temperature of 80–90 C and stirred for 30 min to facilitate hydration. 1 gm of Thymol-quinone was added to the mixture to attain a 0.3% concentration of Thymoquinone and was stirred until homogenization. The pH of the gel was adjusted to 7.0. Then the mixture was cooled at the room temperature (35 C).

Study Protocol:

Baseline visit:

Periodontal pocket depth (PPD) was measured first to aid in the diagnosis of chronic periodontitis.

Selected sites were divided randomly into control and experimental sites. The Clinical parameters including, Gingival Index (GI) Bleeding Index (BI) (16,17) and Plaque index were recorded for full mouth using UNC 15 mm probe.

Then the patients received a full mouth supra and subgingival scaling and root planing followed by partial isolation using gauze for the experimental sites, then thymoquinone gel was applied subgingivally to the experimental sites also using a disposable syringe

with a 25- wide gauge needle assuring that the tip reached the depth of the pockets, then the sites covered by periodontal pack for 5 days to increase the retention of the gel inside the pockets.

The patients were given the instruction to keep the pack in place as long as possible in conjunction with the routine oral hygiene instructions.

2nd visit (6th w):

After 6 weeks the patients recalled again, the clinical parameter: GI, BI and PI were recorded again, Then a small gingival biopsy of 1mm width and 1mm length was taken from the control and experimental sites under infiltration anesthesia as usual.

The samples were fixed immediately in 10% nature buffered formalin for 12 hours, then it was embedded in paraffin wax and sliced into 6um thickness slice for the histopathological evaluation. The specimens were stained with hematoxylin and eosin (H & E).

Statistical analysis:

All collected data were analyzed using the Statistical program for Social Science (SPSS) Version 20 using paired Sample T-test, which was used to compare Statistics of different groups with Significance set at P <0.05.

3. Results:

In this study, 40 sites in 20 females with mild to moderate chronic periodontitis were selected. The experimental site received the thymoquinone gel after SRP, while the control site received SRP only.

Data obtained were subjected to appropriate statistical analysis. At the time of baseline examination, no significant differences were observed in GI, BI and PI in the test and control groups allowing the assumption of homogeneity of the samples.

However, the results of both control and experimental sites were significant when compared to the baseline visit, because the mean of GI, BI and PI decreased in both groups with the favor to test group.

Table1: Clinical Parameters for experimental and control group at baseline (0) visit

	Baseline visit (0) Experimental	Baseline visit (0) Control
GI	1.90	1.80
BI	1.40	1.30
PI	1.80	1.60

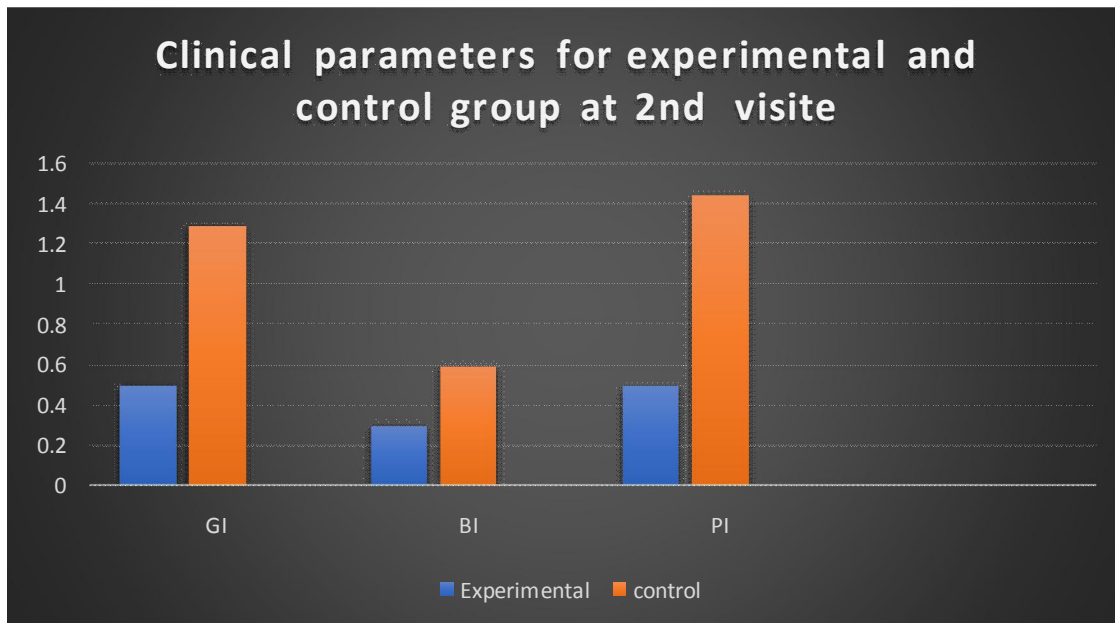


Chart 1: Clinical parameters for experimental and control group at 2nd visit

Table 2: Paired Samples Test

		Paired Differences				t	Sig. (2-tailed)
		Mean	Std. Deviation	95% Confidence Interval of the Difference			
				Lower	Upper		
Pair 1	GI before - GI_test after	1.400	.672	1.185	1.615	13.181	.0000
Pair 2	BI before - BI_test after	1.100	.545	.926	1.274	12.756	.0000
Pair 3	PI before - PI_test after	1.300	.464	1.152	1.448	17.716	.0000

Table3: Paired Samples Test

		Paired Differences				t	Sig. (2-tailed)
		Mean	Std. Deviation	95% Confidence Interval of the Difference			
				Lower	Upper		
Pair 1	GI before - GI_control after	.600	.672	.385	.815	5.649	.0000
Pair 2	BI before - BI_control after	.800	.405	.670	.930	12.490	.0000
Pair 3	PI before - PI_control after	.350	.483	.196	.504	4.583	.0000

Table 4: Paired Samples Test

		Paired Differences				t	Sig. (2-tailed)
		Mean	Std. Deviation	95% Confidence Interval of the Difference			
				Lower	Upper		
Pair 1	GI_test after - GI_control after	-.800	.405	-.930	-.670	-12.490	.000
Pair 2	BI_test after - BI_control after	-.300	.464	-.448	-.152	-4.088	.000
Pair 3	PI_test after - PI_control after	-.950	.815	-1.211	-.689	-7.373	.000

H & E results:

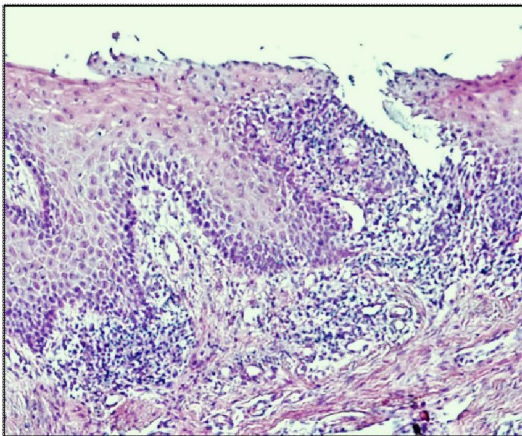


Fig. 1: Photomicrograph of the gingival tissue in the control group showing intense chronic inflammatory reaction. (H & E) x200

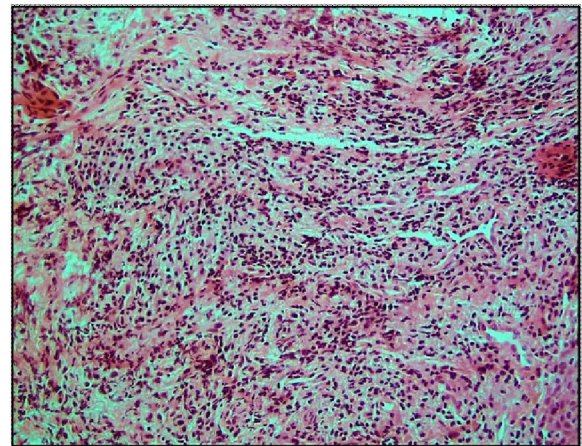


Fig. 2: Destroyed gingival tissue in the control group showing collagen fibers and heavy infiltration of lymphocytes. (H & E X200).

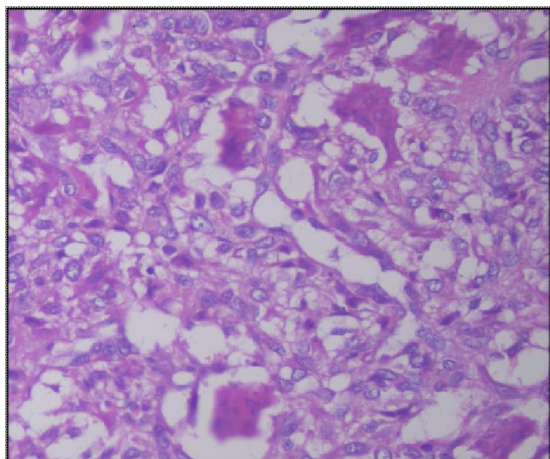


Fig. 3: Higher magnification of the gingival tissue in the control group displaying numerous macrophages. (H & E x400).

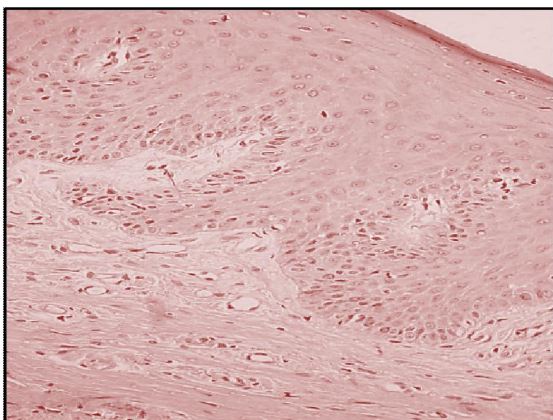


Fig. 4: The gingival tissues of the experimental site showing nearly normal connective tissue as well as hyperplastic parakeratinized st.sq.epith. (H & E X 400)

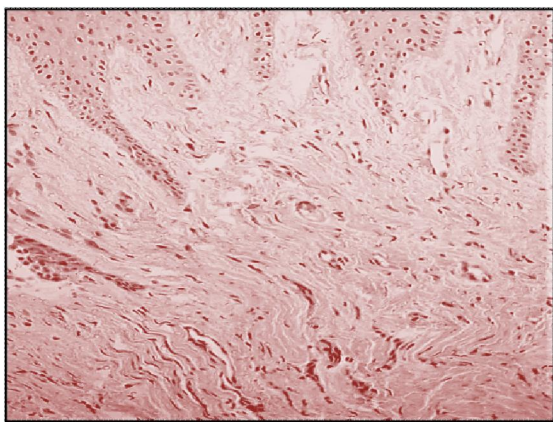


Fig. 5: The experimental group illustrating more collagen fibers; "Yellow arrow"; fibroblasts "blue arrow" & new blood capillaries. (H & E x200)

Histologically, there were a difference between the control and the experimental sites, the control has destructive epithelium and the connective tissue has a lot of inflammatory cells (Figures 1, 2, 3). While the experimental site has more continuous epithelium and less inflammatory cells in the connective tissue (Figure 4 and 5).

4. Discussion

Periodontitis is a complicated and multifactorial disorder, one of these factors is the inflammatory cells accumulation induced by the microorganisms in the gingival connective tissues. The majority of bacteria are occupied in the periodontal pocket and do not invade the periodontal tissues; therefore, it is difficult to be removed effectively by the host immune system. (26)

Mechanical and surgical therapy approaches, along with the antibacterial therapy, have been used for many years. (27)

Local subgingival applications of phytotherapeutic agents have developed and gain special interest as adjunctive modalities to reinforce the clinical outcomes of mechanical debridement. (28)

The use of traditional herbal medicine in the treatment and management of many diseases started in the earliest years of man's evolution. (29)

Nigella sativa (N.S) has long been used in folk medicine to improve good health and for disease management. According to recent studies, it was suggested that extracts of *Nigella sativa*; thymoquinone in particular, which is the active component of N.S has several therapeutic effects, including antioxidant, anti-inflammatory and antimicrobial activity. (30)

As a result of its rich and diverse chemical composition, we hypothesized that N.S may play a role in the improvement of the gingival and periodontal health. Therefore, we aimed to explore the effects of subgingival administration of thymoquinone in a patient with chronic periodontitis.

Previous studies confirmed the pharmacological effects of *Nigella sativa* seed with multiple benefits including suppression of pro-inflammatory cytokines, pro-oxidants, and elevation of some anti-inflammatory cytokines such as IL-10 in animal models (Umar et al., 2012). (31)

Mohammed H. et. al in 2012 concluded that *Nigella sativa* seems to promote differentiation and proliferation of progenitor cells to specialized bone formative cells, with no signs of inflammation.

No allergic mucosal reaction or toxins effects have been reported with N.S. gel usage. (32)

The present study showed a significant reduction in the GI and PI in both the test and the control group after 6 weeks from the baseline.

Comparable results were reported by Al-Wafi. H In 2013 in an experimental study done on rats models. (33)

In addition, our results go in agreement with a study done by Kapil H, et al in 2018 concluded that there was a statistically significant reduction in the GI and PI, in both groups at 6 weeks compared to baseline. (34)

In comparison between the test and the control groups, our results showed that there is a significant difference in the GI and PI which demonstrate more reduction in the test group.

These results go in consequence with the Al-Wafi.H study results when he reported that the plaque index in the N.S gel treated group was significantly lower compared to the control group ($p=0.02$). (33)

In contrast to the previous studies Kapil H, et al found that using 0.2% of Thymoquinone show no significant differences in GI and PI between the test and the control groups at 6 weeks. (34)

Our data also showed a significant decrease in BI for both studied groups with the favor in the test group. Histologically; our results revealed that an improvement in gingival health with minimal signs of inflammation was recorded in the test group more than that of control group. These findings are in agreement with previously published reports showed that Thymoquinone diminishes periodontal inflammation due to its anti-inflammatory and antioxidant properties. Al-Wafi.H reported that animals who received Thymoquinone either as an oral gel or mixed with their drinking water show no bleeding on probing. (33)

Histological examination of the gingival tissue confirmed what was observed clinically. In the test group, there were less inflammatory cells compared to the control group. However, Thymoquinone has been a source of debate for various researchers to have anti-inflammatory potential (Tekeoglu et al., 2007). (35)

The results show improvement in the PPD in the test group after 6 months follow-up due to the potential properties and the capability of N.S for inhibiting the expression of pro-inflammatory cytokines. Thus, preventing the initiation and progression of periodontitis (Ozdemir et al., 2012). (36)

In a recent, clinical study by Al-Bayaty et al. (2013) a New Biodegradable Periodontal Chip Containing Thymoquinone in a Chitosan Base was used for the management of Chronic Periodontitis, the authors reported that; a significant improvement in clinical parameters was recorded for the group treated with thymoquinone chips. They recommended the use of thymoquinone chips as an adjunct to scaling and root planing for the treatment of chronic periodontitis. (37)

5. Conclusion

We can conclude that N.S enhanced the results of SRP by improving the clinical and histological parameters. furthermore, it also helped in preventing progression of the periodontal lesion as a result of its anti-inflammatory properties. (13) Future trials are needed with adjustment of the methodology by increasing the sample size and extending of the duration of the follow-up period for better exploration of the results.

Conflict of interest

The authors declare that there are no conflict of interest.

Ethical statement

All the ethical concerns are taken into consideration before submitting the above-mentioned manuscript.

Acknowledgements

The authors thank Prof. Eman Mustafa, Department of Pharmacy, for her assistance in the gel preparation.

Corresponding Author:

Maram Albarrak Collage of dentistry, Qassim University, Saudi
Telephone: 0553729121
E-mail: maram.albarrak@qudent.org

References:

1. Duang X, Wang Q, Zhou X, Huang D. Mangiferin: A possible strategy for periodontal disease to therapy. *Medical Hypotheses*. 2011;76(4):486-488.
2. Brotto RS, Vendramini RC, Brunetti IL, Marcantonio RA, Ramos AP, Pepato MT. Lack of correlation between peri-odontitis and renal dysfunction in systemically healthy patients. *Eur J Dent* 2011;5:8-18.
3. Breivik T, Gundersen Y, Osmundsen H, Fonnum F, Opstad P. Neonatal dexamethasone and chronic tianeptine treatment inhibit ligature-induced periodontitis in adult rats. *Journal of Periodontal Research*. 2006;41(1):23-32.
4. Di Paola R, Mazzon E, Zito D, Maiere D, Britti D, Genovese T et al. Effects of Tempol, a membrane-permeable radical scavenger, in a rodent model periodontitis. *Journal of Clinical Periodontology*. 2005;32(10):1062-1068.
5. Bendyk A, Marino V, Zilm P, Howe P, Bartold P. Effect of dietary omega-3 polyunsaturated fatty acids on experimental periodontitis in the

- mouse. *Journal of Periodontal Research*. 2009;44(2):211-216.
6. Caton J, Ryan M. Clinical studies on the management of periodontal diseases utilizing subantimicrobial dose doxycycline (SDD). *Pharmacological Research*. 2011;63(2):114-120.
 7. Cheng W, Huang R, Chiang C, Chen J, Liu C, Chu C et al. Ameliorative effect of quercetin on the destruction caused by experimental periodontitis in rats. *Journal of Periodontal Research*. 2010;45(6):788-795.
 8. Ku S, Cho H, Sung Y, Kang S, Lee Y. Effects of Calcium Gluconate on Experimental.
 9. Periodontitis and Alveolar Bone Loss in Rats. *Basic & Clinical Pharmacology & Toxicology*. 2010;108(4):241-250.
 10. Obeid P, D'hoore W, Bercy P. Comparative clinical responses related to the use of various periodontal instrumentation. *Journal of Clinical Periodontology*. 2004;31(3):193-199.
 11. Serino G, Rosling B, Ramberg P, Socransky S, Lindhe J. Initial outcome and long-term effect of surgical and non-surgical treatment of advanced periodontal disease. *Journal of Clinical Periodontology*. 2001;28(10):910-916.
 12. Peter I, Jacobsen, Richard P. Cohan. Alternative dental products. *Journal of the California dental association*. 1998; 62: 101-10.
 13. Forouzanfar F., Bazzaz B. and Hossein Hosseinzadeh H. Black cumin (*Nigella sativa*) and its constituent (thymoquinone): a review on antimicrobial effects. *Iranian Journal Of Basic Medical Science*. 2014;17:929-938.
 14. Tambekar D, Dahikar S. Antibacterial activity of some Indian ayurvedic preparations against enteric bacterial pathogens. *Journal of Advanced Pharmaceutical Technology & Research*. 2011;2(1):24.
 15. Seif AA. *Nigella Sativa* reverses osteoporosis in ovariectomized rats. *BMC Complementary and Alternative Medicine*. 2014;14(1).
 16. Chaudhry H, Fatima N, Ahmad IZ. Evaluation of Antioxidant and Antibacterial Potentials of *Nigella sativa* L. Suspension Cultures under Elicitation. *BioMed Research International*. 2015;2015:1-13.
 17. Farimah Beheshti M. Neuropharmacological effects of *Nigella sativa* [Internet]. PubMed Central (PMC). 2019 [cited 5 March 2019].
 18. Khan MA. Chemical composition and medicinal properties of *Nigella sativa* Linn. *Inflammopharmacology*. 1999;7(1):15-35.
 19. Tariq M. *Nigella sativa* seeds: Folklore treatment in modern day medicine. *Saudi Journal of Gastroenterology*. 2008;14(3):105.
 20. Paarakh P.M., *Nigella sativa* Linn. A comprehensive review. *Indian journal of natural products and resources*. 2010;1(4): 409-29.
 21. Ahmad A, Husain A, Mujeeb M, Khan S, Najmi A, Siddique N, et al. A review on therapeutic potential of *Nigella sativa*: a miracle herb. *Asian Pac J Trop Biomed*. 2013;3:337-352.
 22. Shrivastava R, Agrawal R, Parveen Z. A review on therapeutic applications of *Nigella Sativa*. *Journal of Chemistry and Chemical Sciences*. 2011;1:241-248.
 23. Gaur S, Shrivastava B, Gaur S, Bhardwaj R, Khanchandani R. Medicinal and therapeutical potential of *Nigella sativa*. *International Journal of Medical and Applied Sciences Research*. 2014;1:32-39.
 24. Tembhurne S, Feroz S, More B, Sakarkar D. A review on therapeutic potential of *Nigella sativa* (kalonji) seeds. *Journal of Medicinal Plants Research*. 2014;8:167-177.
 25. Hanafy M, Hatem M. Studies on the antimicrobial activity of *Nigella sativa* seed (black cumin). *Journal of Ethnopharmacology*. 1991;34(2-3):275-8.
 26. Burits M, Bucar F. Antioxidant activity of *Nigella sativa* essential oil. *Phytotherapy Research*. 2000;14(5):323-8.
 27. Henderson B, Kaiser F. Bacterial modulators of bone remodeling in the periodontal pocket. *Periodontology 2000*. 2017;76(1):97-108.
 28. Zhang J, Zhang A-M, Zhang Z-M, Jia J-L, Sui X-X, Yu L-R, et al. Efficacy of combined orthodontic-periodontic treatment for patients with periodontitis and its effect on inflammatory cytokines: A comparative study. *American Journal of Orthodontics and Dentofacial Orthopedics*. 2017;152(4):494-500.
 29. Braatz, L., Garrett, S., Claffey, N. and Egelberg, J. (1985), Antimicrobial irrigation of deep pockets to supplement non-surgical periodontal therapy. *Journal of Clinical Periodontology*, 12: 630-638.
 30. Karygianni L, Al-Ahmad A, Argyropoulou A, Hellwig E, Anderson AC, Skaltsounis AL. Natural Antimicrobials and Oral Microorganisms: A Systematic Review on Herbal Interventions for the Eradication of Multispecies Oral Biofilms. *Frontiers in Microbiology*. 2016;6.
 31. Shuid AN, Mohamed N, Mohamed IN, Othman F, Suhaimi F, Ramli ESM, et al. *Nigella sativa*: A Potential Antiosteoporotic Agent. *Evidence-Based Complementary and Alternative Medicine*. 2012;2012:1-6.
 32. Umar S, Zargan J, Umar K, Ahmad S, Katiyar CK, Khan HA. Modulation of the oxidative

- stress and inflammatory cytokine response by thymoquinone in the collagen induced arthritis in Wistar rats. *Chem Biol Interact.* 2012;197:40–46.
33. Mohammed H, Al-Hijazi A. Evaluation of the effect of *Nigella sativa* oil and powder on healing process, histologically and radiographically (An experimental study on rabbit). *Journal of Baghdad College of Dentistry.* 2012;24(1):48-52.
34. Al-Wafi.H. Benefits of Thymoquinone, a *Nigella Sativa* Extract in Preventing Dental Caries Initiation and Improving Gingival Health. Tufts University. 2013.
35. 21. Kapil H, Suresh D, Bathla S, Arora K. Assessment of clinical efficacy of locally delivered 0.2% Thymoquinone gel in the treatment of periodontitis. *The Saudi Dental Journal.* 2018;30(4):348-354.
36. Tekeoglu I, Dogan A, Ediz L, Budancamanak M, Demirel A. Effects of thymoquinone (volatile oil of black cummin) on rheumatoid arthritis in rat models. *Phytotherapy Research.* 2007;21(9):895-897.
37. Ozdemir, H., Kara, M., Erciyas, K., Ozer, H. and Ay, S. Preventive effects of thymoquinone in a rat periodontitis model: a morphometric and histopathological study. *Journal of Periodontal Research,* (2012). 47(1), pp.74-80.
38. Al-Bayaty F, Kamaruddin A, Ismail M, Abdulla M. Formulation and Evaluation of a New Biodegradable Periodontal Chip Containing Thymoquinone in a Chitosan Base for the Management of Chronic Periodontitis. *Journal of Nanomaterials.* 2013;2013:1-5.

12/7/2019