

Use of Transcranial Sonography for Assessment of Brain Midline Shift In Neurocritical Patients: A Systematic Review

Prof. Dr. Sameh Michel Hakim, Dr. Ayman Ahmad El Sayed Abdellatif, Dr. Mona Ahmed Mohammed Abdelmotaleb Ammar and Muhammad Ibrahim Reyad Ali

Anaesthesia, Intensive Care and Pain Management, Faculty of Medicine, Ain Shams University, Egypt
Hamzareyad2015@hotmail.com

Abstract: Brain midline shift (MLS) in neurocritical patients is a life-threatening condition that requires urgent diagnosis and treatment. The early detection of MLS in neurocritical patient is thus very important because it allows starting an appropriate treatment plan to improve morbidity and mortality. Head CT is considered to be the gold standard tool to diagnose MLS. Transcranial sonography (TCS) is a bedside neuroimaging technique which is safe, painless and accurate. The aim of this study is comparing the accuracy of TCS in measuring brain MLS in neurocritical patient to Head CT. In this systematic review we selected 10 studies were published in the last 20 years that compared TCS to head CT as a tool in measuring MLS in neurocritical patients and we found that TCS can detect and monitor MLS with only a small difference in comparison to head CT. So, it provides a cheap, accurate and non-invasive bedside tool for diagnosis and monitoring of brain MLS.

[Sameh Michel Hakim, Ayman Ahmad El Sayed Abdellatif, Mona Ahmed Mohammed Abdelmotaleb Ammar and Muhammad Ibrahim Reyad Ali. **Use of Transcranial Sonography for Assessment of Brain Midline Shift In Neurocritical Patients: A Systematic Review.** *N Y Sci J* 2019;12(8):44-51]. ISSN 1554-0200 (print); ISSN 2375-723X (online). <http://www.sciencepub.net/newyork>. 6. doi: [10.7537/marsnys120819.06](https://doi.org/10.7537/marsnys120819.06).

Keywords: Transcranial; Sonography; Assessment; Brain; Midline; Shift; Neurocritical Patients; Systematic

1. Introduction

Brain Midline Shift (MLS)

MLS on computed tomography (CT) has been found to be correlated with the Glasgow coma score, morbidity and mortality in neurocritical patients.

The horizontal brain midline shift caused by acute unilateral mass lesions correlated closely with consciousness. The MLS has been also correlated with other CT signs of injury severity. Significant correlation was found between midline shift, cerebral contusions in CT scans and results of surgery. Patients with bigger midline shift or presence of focal cerebral contusion revealed higher mortality and worse outcome than patients with smaller shift and no cerebral contusion in CT Scans (*Eisenberg et al., 1990, Fearnside et al., 1993, Kotwica and Brzezinski 1993, Yanaka et al., 1993*).

A CT scan classification based on data from the Traumatic Coma Data Bank was proposed by *Marshall et al. (1991)* including a MLS >0.5 cm as one of the main CT criteria for the severity of traumatic brain injury (TBI) (*Marshall et al., 1991, Maas et al., 2005*) and a multivariate analysis of a cohort of over 10, 000 TBI patients showed that the compression of the third ventricle and a MLS >0.5 cm were both major predictors of mortality within the first 15 days after injury (*Perel et al., 2008*).

The early detection of a MLS in neurosurgical intensive care unit (ICU) patients is thus very important because it allows the implementation of an appropriate treatment plan (North American recommendations

from 2006 call for a surgical evacuation in the case of a MLS >0.5 cm in the presence of severe TBI, extradural, subdural or intracerebral hematoma) (*Bullock et al., 2006*).

Head CT is considered to be the gold standard to diagnose MLS. However, serial CTs in neurosurgical ICU patients can be associated with significant morbidity and secondary brain injuries post-transfer related to their transport (*Andrews et al., 1990*). So, adequate resuscitation before moving the patient is important. The head CT scan is an integral part of the diagnosis and management of the patient with head injuries, but the utility of repeated head CT scans performed solely for routine follow-up in the patient with blunt head trauma has not been defined. In the absence of clinical indications, routinely repeated head CT scans, even in patients with significant brain injuries, does not contribute to patient care (*Kaups et al., 2004*).

Transcranial sonography (TCS)

A head ultrasound examination produces images of the brain and the cerebrospinal fluid that flows and is contained within its ventricles, the fluid filled cavities located in the deep portion of the brain. Since ultrasound waves do not pass through bone easily, this exam is most commonly performed on infants, whose skulls have not completely formed. The gaps between those skull bones provide a "window" allowing the ultrasound beam to freely pass into and back from the brain. The ultrasound probe and some gel are placed on

the outside of the head in one of those regions without bone (Walter, 2012).

Ultrasound is safe and painless, and produces pictures of the inside of the body using sound waves. Ultrasound imaging, also called ultrasound scanning or sonography, involves the use of a small transducer (probe) and ultrasound gel placed directly on the skin. High-frequency sound waves are transmitted from the probe through the gel into the body. The transducer collects the sounds that bounce back and a computer then uses those sound waves to create an image. Ultrasound examinations do not use ionizing radiation (as used in x-rays), thus there is no radiation exposure to the patient. Because ultrasound images are captured in real-time, they can show the structure and movement of the body's internal organs, as well as blood flowing through blood vessels (Walter, 2012).

TCS is a neuroimaging technique that displays the brain parenchyma and the intracranial ventricular system through the intact skull. Its different imaging principle allows visualization of characteristic changes in several neurodegenerative diseases that can hardly be visualized with other imaging methods, such as substantia nigra (SN) hyperechogenicity in Parkinson's disease (PD) (Walter et al., 2007 and Berg et al., 2008).

While TCS has been performed in children already in the 1980s and 1990s of the last century, the clinical application of TCS in adults has developed only subsequently since the TCS imaging conditions are much more difficult in adults because of the thickening of temporal bones with increasing age (Wijnhoud et al., 2008).

Aim of the Systematic Review

The aim of this systematic review was to assess the exact diagnostic accuracy of transcranial sonography in detecting MLS in neurocritical patients.

2. Methodology

Search methods for identification of studies

We systematically searched the following electronic databases {PubMed, Scopus, and the Cochrane Central, EMBASE, Web of Science (WOS) and Google scholar} for all published English-language studies concerned with the use of TCCS in assessment of brain MLS and its accuracy in relation to head computed tomography.

The search strategy included terms of the clinical condition and intervention as well as their synonyms.

Data collection and analysis

Two reviewers independently analysed the titles and abstracts of publications obtained by search to exclude duplicates and select studies that met our inclusion criteria. Disagreements were resolved by consensus.

Inclusion criteria for studies were as follows;

- **Types of studies:** Observational studies.
- **Types of participants:** Neurocritical patients with brain midline shift.
- **Types of interventions:** Transcranial sonography and head computed tomography (CT).
- **Types of outcome measures:** The accuracy of transcranial sonography in detecting midline shift in neurocritical patients when compared to computed tomography.

Table (1): The process of conducting research

Database	Search Terms	Results
Pubmed	Midline shift [Title] AND "humans"[MeSH Terms]	51
	Transcranial [Title/Abstract] AND midline shift [Title/Abstract] AND "humans"[MeSH Terms]	34
SCOPUS	(transcranial AND sonography AND midline AND shift)	31
Cochrane Central	"transcranial Doppler sonography" in Abstract'	41
EMBASE	"transcranial Doppler sonography" in Abstract'	17
WOS	TITLE: (transcranial sonography) AND TOPIC: (midline shift) Timespan: All years. Indexes: SCI-EXPANDED, SSCI, A & HCI, CPCI- S, CPCI-SSH, BKCI-S, BKCI-SSH, ESCI.	16
Google Scholar	TITLE: transcranial sonography	18

Assessment of Methodological Quality

Two review authors independently assessed the methodological quality of each included study using the Quality Assessment of Diagnostic Accuracy Studies-2 (QUADAS-2), a recent modified version of QUADAS (*Whiting et al., 2011*).

QUADAS is a checklist for assessment of the methodological quality of studies included in systematic reviews of diagnostic accuracy, and was developed by the NHS Centre for Reviews and Dissemination at the University of York; UK. The QUADAS-2 comprises 4 domains:

- Participant selection.
- Index test.
- Reference standard.
- Flow of participants through the study and timing of the tests and reference standard (flow and timing).

Each domain is assessed for risk of bias, and the first three domains are also assessed for concerns regarding applicability. Risk of bias and concerns about applicability are judged as 'low', 'high' or 'unclear'. We will add signalling questions, specific to this review topic, separately.

The following figure summarises QUADAS-2 and lists all signalling, risk of bias and applicability rating questions.

3. Results

The search strategy retrieved 208 studies across all electronic databases. We excluded duplicate references and thus retrieved 88 studies. Of these studies, we excluded a further 70, on the basis of study design and English language. From the remaining 18 studies we excluded 1 study that lack outcome of interest, another 7 studies were excluded because they don't meet our inclusion criteria, lack of results and different patient population. Finally the remaining 10 studies were included in our review.

Assessment of Methodological Quality

As recommended by the Cochrane Collaboration (<http://www.cochrane.org/>), the QUADAS-2 tool was used to assess the risk of bias of each primary study that reported both sensitivity and specificity measures (*Macaskill et al., 2010 and Whiting et al., 2011*). The two reviewers independently evaluated QUADAS-2 items, and conflicts were resolved by consensus. Fig (6) shows the risk of bias of the included studies.

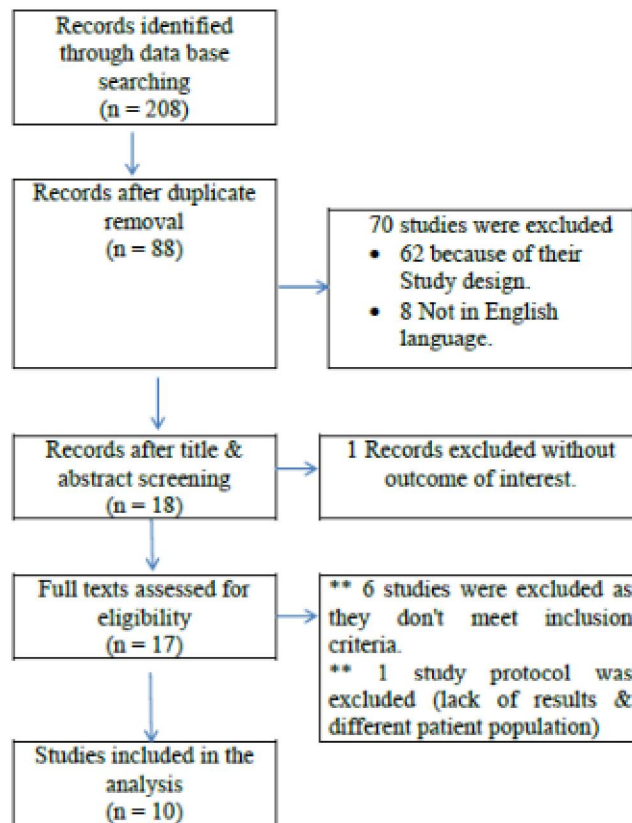


Fig. (5): PRISMA Flow chart diagram presenting the selection of eligible studies.

Table (3): Results of full text screening

Year	Title	Author
1999	Comparison of Transcranial Color-Coded Duplex Sonography and Cranial CT Measurements for Determining Third Ventricle Midline Shift in Space-Occupying Stroke	(Stolz et al., 1999)
2004	Monitoring midline shift by transcranial color-coded sonography in traumatic brain injury. A comparison with cranial computerized tomography	(Llompert Pou et al., 2004)
2006	Third Ventricle Midline Shift Due to Spontaneous Supratentorial Intracerebral Hemorrhage Evaluated by Transcranial Color-Coded Sonography	(Tang et al., 2006)
2012	Imaging of spontaneous intracerebral haemorrhages by means of transcranial color-coded sonography	(Kukulkska- Pawluczuk et al., 2012)
2013	Preliminary experience of assessment of intracranial lesions by ultrasound in multiple trauma patients undergoing craniectomy	(Lu et al., 2013)
2014	(ABSTRACT) Accuracy of Midline Shift and Third Ventricle Measures by Transcranial Sonography Compared to Computed Tomography.	(Grousseau and de Souza Neto 2014)
2014	Assessment of brain midline shift using sonography in neurosurgical ICU patients.	(Motuel et al., 2014)
2017	Transcranial Duplex Sonography Predicts Outcome Following an Intracerebral Hemorrhage	(Camps- Renom et al., 2017)
2017	Transcranial color-coded duplex sonography for Evaluation of Midline-shift After chronic-Subdural hematoma Evacuation (TEMASE)	(Cattalani et al., 2017)
2017	Comparison between Brain Computed Tomography Scan and Transcranial Sonography to Evaluate Third Ventricle Width, Peri- Mesencephalic Cistern, and Sylvian Fissure in Traumatic Brain-Injured Patients	(Oliveira et al., 2017)

Assessment of methodological quality of the included studies:

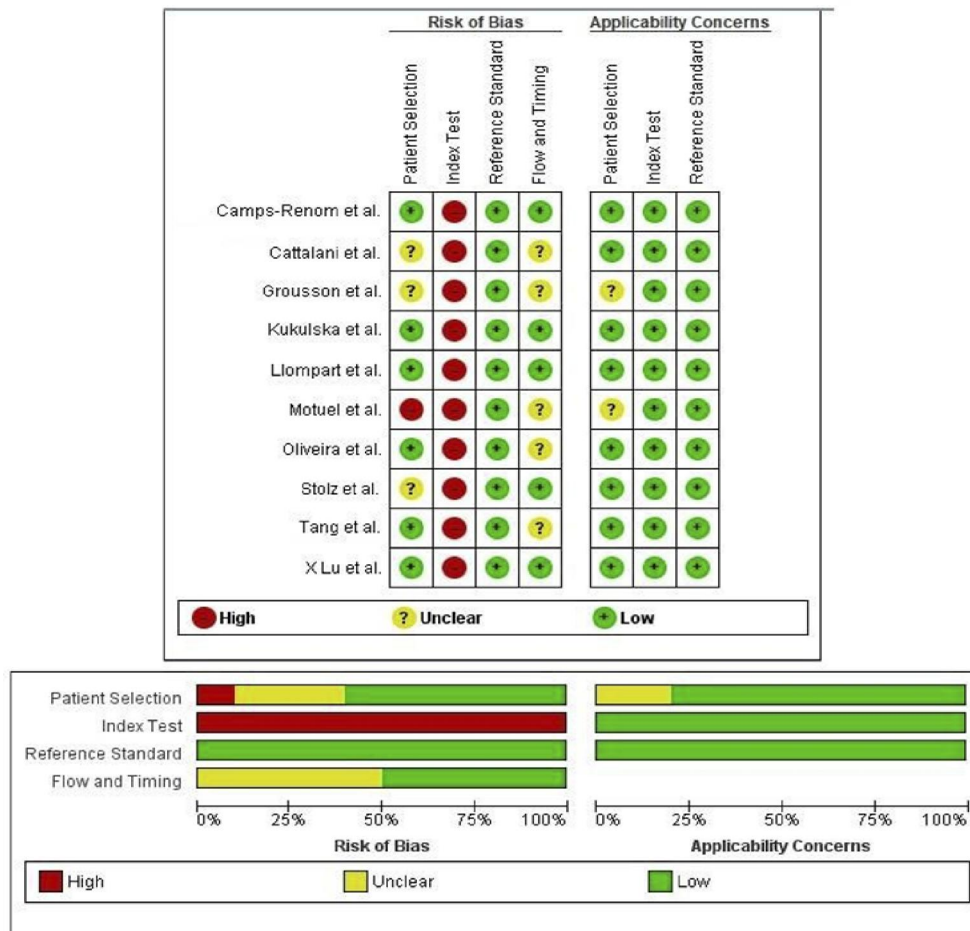


Fig. (6): Risk of bias of the included studies

Qualitative analysis of the included studies:

In Stolz et al., One hundred twenty-two data pairs of TCS and cranial CT MLS measurements were correlated within the 12-hour time window. TCS and cranial CT measurements of MLS correlated both in the total patient group and in the different subgroups with coefficients of over 0.9. The 2-SD confidence interval of the difference between the TCD measurements and the respective means of both methods in the total patient collective was ± 1.78 mm.

In Liompart et al., the coefficient of correlation between MLS measured by CT and TCD was 0.88, the bias was 0.12 mm, the precision was 1.08 mm and the limits of agreement were +2.33 to -2.07 mm. There were no statistically significant differences in MLS measured by the two techniques in terms of: sex, age or type of lesion according to the Traumatic Coma Data Bank classification.

In Tang et al., There were 51 patients with spontaneous supratentorial ICH who received CT and TCCS studies within a 12 - hour window. Correlation between MLS by TCCS (mean \pm SD, 3.2 ± 2.6 mm) and CT (3.0 ± 2.4 mm) was high ($\gamma = 0.91$; $P < .01$). There was also a good linear correlation between hematoma volume and MLS by TCS ($\gamma = 0.81$; $P < .01$). Compared with ICH volume less than 25 mL, those with greater volume had more severe MLS and a higher PI of the ipsilateral middle cerebral artery ($P < .001$). Midline shift by TCCS was more sensitive and specific than the PI in detecting large ICH (accuracy = 0.82 if $MLS \geq 2.5$ mm), and it was also a significant predictor of poor outcome (odds ratio, 2.09 by 1 - mm increase; 95% confidence interval, 1.06–4.13).

In Kukulska- Pawluczuk et al., TCS revealed ICHs in 34 patients, including 29 and 5 with supra- and infratentorial localization, respectively. Moreover, it showed 12 cases (35.3%) of intraventricular hemorrhage (IVH) and 16 cases of a midline shift (MLS). No significant differences were found between the measurements of hemorrhagic foci or MLS obtained by TCS and CT. There was a significant correlation between the volumes of hemorrhagic foci or MLS values measured by both methods analyzed ($R = 0.99$ or $R = 0.98$, respectively). Additionally, MLS was shown to increase significantly with the volume of hemorrhagic foci ($R = 0.90$).

In Lu et al., Ultrasonography revealed 18 pathological changes in the 13 patients. CT and a second operation helped to identify 23 pathological changes. The results of B-mode ultrasound were compared with those of CT and the coincidence rate was 78.3%, with no significant difference in the diagnosis of delayed haematoma or midline shift (Kappa=0.898, $p < 0.05$).

In Grousson and de Souza Neto, 133 and 143 TCS-CT pairs were analyzed for MLS and DV3

respectively, in 126 patients (among which 14 were studied more than once). CT and TCS measures were respectively 2.8 ± 3 and 3.1 ± 2.8 mm for MLS and 5.3 ± 3.6 mm and 6.1 ± 3.4 mm for third ventricle (DV3). Bland-Altman comparison for MLS measures show a bias of 0.44 (95% confidence interval: 0.15-0.73) and 0.72 (95% confidence interval: 0.57- 0.88) for DV3. MLS duration was estimated at 11 ± 5 min and CT-TCS delay was 88 ± 74 min.

In Motuel et al., A total of 52 neurosurgical ICU patients were included. The MLS (mean \pm SD) was 0.32 ± 0.36 cm using TCS and 0.47 ± 0.67 cm using CT. The Pearson's correlation coefficient (r^2) between TCS and CT scan was 0.65 ($P < 0.001$). The bias was 0.09 cm and the limits of agreements were 1.10 and -0.92 cm. The area under the ROC curve for detecting a significant MLS with TCS was 0.86 (95% CI = 0.74 to 0.94), and, using 0.35 cm as a cut-off, the sensitivity was 84.2%, the specificity 84.8% and the positive likelihood ratio was 5.56.

In Camps-Renom et al., included 35 patients with a mean age of 72.2 ± 12.8 years. Median baseline hematoma volume was 9.85 mL (interquartile range, 2.74–68.29 mL). They found good agreement and excellent correlation between transcranial duplex sonography and CT when measuring hematoma volume ($r = 0.791$; $P < .001$) and midline shift ($r = 0.827$; $P < .001$). The logistic regression analysis with transcranial duplex sonography measurements showed that hematoma volume was an independent predictor of early neurologic deterioration (OR, 1.078; 95% CI, 1.023–1.135) and mortality (OR, 1.089; 95% CI, 1.020–1.160). A second regression analysis with CT variables also demonstrated that hematoma volume was associated with early neurologic deterioration and mortality. When they compared the rating operation curves of both models, their predictive power was similar.

In Cattalani et al., 64 data pairs of MLS values obtained by TCS and CT were analysed. Bland-Altman diagrams did not show any systematic bias of the data and linear regression indicated a significant correlation between the two measures both before and after hematoma evacuation.

In Oliveira et al., Overall, 15 consecutive patients were included (80% male, 42 ± 23 years of age, Glasgow Coma Score 5 [4, 6]). The mean difference between the brain CT scan and TCCS in measuring the midline shift was 0.30 ± 2.1 mm (interclass correlation coefficient: 0.93; $p < 0.01$). An excellent correlation was also observed between the methods in assessing the third ventricle width (intraclass correlation coefficient: 0.88; $p < 0.01$). Bland-Altman plots did not show any systematic bias in either agreement analysis. TCCS showed good accuracy in predicting non-compressed peri-mesencephalic cisterns (AUC:

0.83, 95% CI 0.46–1.0) and the presence of the Sylvian fissure (AUC: 0.91, 95% CI 0.73–1.0) on CT scan.

4. Discussion

Midline shift is a serious medical condition that requires early diagnosis, management and follows up as it is often associated with many neurological conditions such as intracerebral haemorrhage, brain

tumours, ischemic strokes and any brain pathology that cause increased intracranial pressure. Poor neurological outcome can be associated with a clinically significant midline shift of as little as 0.5mm. Being a sign of increased intracranial pressure, MLS is also an indicator of reduced brain perfusion caused by an intracranial mass or mass effect.

Table (4): Criteria and results of the included studies (quantitative analysis):

Study	Stolz et al., 1999	Llompert et al., 2004	Tang et al., 2006	Kukulka-pauluzuk et al., 2012	X-Lu et al., 2013	Grusson et al., 2014	Moutel et al., 2014	Camps-renom et al., 2017	Cattalmi et al., 2017	Olivera et al., 2017	
Inclusion criteria	No.	61	41	51	39	13	126	52	35	32	15
	Age	62±15	16-81	57±13.7	67.5±14	>18	-	47.1±23.3	72.2±12.8	79.75±8.9	42±23
	Type of study	Prospective single center study	Prospective observational study	Prospective single center study	Prospective single center study	Retrospective single center study	prospective observational monocentric study	prospective single centre study centre	Prospective study	Prospective single center study	Cross-sectional retrospective observational study
Methods	Type of patients	Patients with supratentorial ischemic infarction or intracranial hemorrhage	TBI adult patients admitted into the ICU adult	Patients with spontaneous supratentorial ICH	Patients with spontaneous intracerebral hemorrhage	Trauma patients with severe head injury	Neurocritical care after acute brain injury patients after acute brain	Neurosurgical ICU patients who underwent a head CT	Patients with spontaneous intracerebral hemorrhage	Patients with chronic subdural hematoma who underwent surgical evacuation	All patients with severe TBI
	Type of probe	2.5-2 MHz probe	Not mentioned	2 MHz pulsed wave Doppler transducer	2-5 MHz sector array probe	2-5 MHz C6 probe	Not mentioned	2-4 MHz probe	2-5 MHz sectorial probe	2-5 MHz probe	2.5 MHz phased array transducer probe
Results	Timing interval bet. CT & TCS	3-12 hrs	322±216 min.	12 hrs	-	2 hrs	88±74 mins	-	-	>2 hrs	6 hrs
	TCS mean ±SD	2.18±2.5 mm			1.5±2.02 mm	3.2±2.6 mm	0.9-20.8 mm	-	3.1 ± 2.8 mm	0.13±2.56 mm	3.6±4.5 mm
	CT mean ±SD	2.15±2.6 mm	1.6±2.24 mm	3.0±2.4 mm	0.8-25 mm	-	3.8±3.0 mm	0.46±0.67 mm	-	1.24±3.21 Mm	3.3±4.17 mm
	Correlation coefficient	0.93	0.88	0.91	0.98	-----	-----	0.65	0.827	0.59	-----
	P value	<.0001	< 0.0001	< 0.01	< 0.001	<0.05	-----	< 0.001	<.001	<0.01	<0.01
	Limits of agreement	1.755, -1.805	+2.33 to -2.07	-----	-----	-----	-----	1.10 to -0.92 cm	-----	0.68 to -0.5 cm	-----
	Interclass correlation coefficient	-----	-----	-----	-----	-----	-----	-----	-----	-----	0.93
	AUC	-----	-----	-----	-----	-----	-----	0.86	-----	-----	-----
	95% CI	-----	0.15 to 0.41 mm	-----	-----	-----	0.15 to 0.73	0.74 to 0.94	-----	-----	0.81 to 0.98
	sensitivity	-----	-----	78% (2.5 mm as a cut-off)	-----	-----	-----	84.2% (0.35 cm as a cut-off)	-----	-----	-----
	Specificity	-----	-----	89% (2.5 mm as a cut-off)	-----	-----	-----	84.8% (0.35 cm as a cut-off)	-----	-----	-----
	PPV	-----	-----	0.86	-----	-----	-----	-----	-----	-----	-----
NPV	-----	-----	0.83	-----	-----	-----	-----	-----	-----	-----	
Kappa	-----	-----	-----	-----	0.898	-----	-----	-----	-----	-----	

Midline shift detection and measurement can be done by various radiological methods such as CT brain "the gold standard tool for this purpose", MRI and transcranial sonography.

In this study we focused on TCS as a new, safe and bedside modality for assessment of MLS.

TCCS could facilitate early diagnosis and treatment for patients with significant intracranial mass effect without risks associated with transportation and radiation dosages with a serial CT scan approach.

In addition, TCCS is an important early predictor of outcome as it is a useful imaging tool that can differentiate between many brain pathologies such as

ICH and ischemic stroke if head CT is not readily available.

Another finding is the efficacy in predicting non-compressed peri-mesencephalic cisterns with high sensitivity and specificity. Thus, TCS can lead to obtaining a valuable data regarding the intracranial pressure status.

This systematic review of 10 prospective studies involving 465 participant with brain MLS caused by different brain pathologies and they were examined using TCS and compared the results to CT brain results, some participants were examined more than one time in some studies for follow up purpose and we found that it is possible to detect MLS with a reasonable accuracy in

neurosurgical ICU patients with various intracranial pathologies.

The 10 studies applied in that systematic review were assessed for methodological quality and risk of bias using QUADAS checklist. Two reviewers independently evaluated QUADAS-2 items, and conflicts were resolved by consensus.

Despite the heterogeneity of the methods of assessment of accuracy of TCS in measuring the MLS in neurocritical patients in each study (correlation, agreement, etc.) they all confirmed the reliability of TCS as a tool for assessment of MLS in neurocritical patients. All quantitative parameters, related to the main outcome (mean, median, standard deviations and mean difference) were collected using an excel sheet.

Current study confirms previously reported data concerning the strong correlation between TDS and CT scan regarding the assessment of brain MLS.

Ultrasound is easy to access, bedside, safe, and free of radiation widely used tool for assessment of brain midline shift in neurocritical patients.

Study limitations

This study has several limitations. First, the small number of published studies, The heterogeneity of methods of measuring the relation between TCCS and head CT in assessment of brain MLS in the included studies was an obstacle to perform quantitative analysis "Meta-analysis" to estimate the overall accuracy of TCS in measuring MLS when compared to cranial CT.

Conclusion

In the light of the current evidence, in neurocritically ill patients, transcranial sonography (TCS) is a reliable tool to detect midline shift (MLS) with reasonable accuracy, although it could not be quantitatively estimated from the available data. TCS could serve as a bedside tool to facilitate early diagnosis and treatment for patients with a significant intracranial mass effect. Although this technique is not a substitute for cranial CT, it is especially useful in monitoring these patients after the initial CT, because it is non-invasive and easily applicable in routine practice at the patient's bedside, avoiding the risks involved in transporting the patient to the radiology department. The results obtained will select patients at high risk of complications and guide us concerning the best moment to realize a new cranial CT.

Recommendations

More non-inferiority studies of TCS compared to CT should be considered to propose a systematic bedside sonographic monitoring for neurocritical patients and more standard training should be imparted to the operators to improve their skills. More data are necessary to validate these results; the harmless and

non-invasive nature of TCS provides the feasibility to add it to the imaging armamentarium for the management.

References

1. Andrews PJD, Piper IR, Dearden NM and Miller JD: Secondary insults during intrahospital transport of head-injured patients. *Lancet*, 1990; 335(8685): 327-330.
2. Becker G, Winkler J, Hofmann E, Bogdahn U: Differentiation between ischemic and hemorrhagic stroke by transcranial color-coded real-time sonography. *Journal of Neuroimaging*, 1993; 3(1): 41-47.
3. Berg D, Godau J, Walter u: Transcranial sonography in movement disorders. *Lancet Neurology*, 2008; 7(11): 1044-1055.
4. Bullock MR, Chesnut R, Ghajar J, Gordon D, Hartl R, Newell DW, Servadei F, Walters BC and Wilberger J: Surgical management of traumatic parenchymal lesions. *Neurosurgery*, 2006; 58(3 Suppl): S7-46; discussion Si-iv.
5. Camps-Renom P, Mendez J, Granell E, Casoni F, Prats-Sanchez L, Martinez-domeno A, Guisado-Alonso DMarti-Fabregas J and Delgado-Mederos R: Transcranial Duplex Sonography Predicts Outcome following an Intracerebral Hemorrhage. *American Journal of Neuroradiology*, 2017; 18(7): 1672-1675.
6. Cattalani A, Grasso VM, Vitali M, Gallesio I, Magrassi L and Barbanera A: Transcranial color-coded duplex sonography for evaluation of midline-shift after chronic-subdural hematoma evacuation (TEMASE): a prospective study. *Clinical neurology and neurosurgery*, 2017; 162: 101-107.
7. Eisenberg HM, Gary Jr HE, Aldrich EF, Saydjari C, Turner B, Foulkes MA, Jane JA, Marmarou A, Marshall LF and Young HF: Initial CT findings in 753 patients with severe head injury. A report from the NIH Traumatic Coma Data Bank. *Journal of Neurosurgery*, 1990; 73(5): 688-698.
8. Fearnside MR, Cook RJ, McDougall P and McNeil RJ: The Westmead Head Injury Project outcome in severe head injury. A comparative analysis of pre-hospital, clinical and CT variables. *British Journal of Neurosurgery*, 1993; 7(3): 267-279.
9. Grousson S and EP de Souza Neto: Accuracy of Midline Shift and Third Ventricle Measures by Transcranial Sonography Compared to Computed Tomography. 2014.
10. Kaups KL, Davis JW and Parks SN: Routinely repeated computed tomography after blunt head trauma: does it benefit patients? *Journal of*

- Trauma, 2004; 56(3): 475-480; discussion 480-471.
11. Kotwica Z and Brzezinski J: Acute subdural haematoma in adults: an analysis of outcome in comatose patients. *Acta Neurochirurgica*, 1993; 121(3-4): 95-99.
 12. Kukulska-Pawluczuk B, Ksiazkiewicz B and Nowaczewska M: Imaging of spontaneous intracerebral hemorrhages by means of transcranial color-coded sonography. *European journal of radiology*, 2012; 81(6): 1253-1258.
 13. Llompart Pou JA, Centellas JM, Sans MP, Barcena JP, Vivas MC, Ramirez JH and Juve I: Monitoring midline shift by transcranial color-coded sonography in traumatic brain injury. A comparison with cranial computerized tomography. *Intensive Care Medicine*, 2004; 30(8): 1672-1675.
 14. Lu X, Zhang M, Yang JX, Xu SX and Gan JX: Preliminary experience of assessment of intracranial lesions by ultrasound in multiple trauma patients undergoing craniectomy. *Hong Kong Journal of Emergency Medicine*, 2013; 20(1): 34-39.
 15. Maas AIR, Hukkelhoven CWPM, Marshall LF and Steyerberg EW: Prediction of outcome in traumatic brain injury with computed tomographic characteristics: a comparison between the computed tomographic classification and combinations of computed tomographic predictors. *Neurosurgery*, 2005; 57(6): 1173-1182; discussion 1173-1182.
 16. Macaskill P, Gatsonis C, Deeks J, Harebord R and Takwoingi Y: *Cochrane handbook for systematic reviews of diagnostic test accuracy.* Version 0.9.0. London: The Cochrane Collaboration, 2010.
 17. Marshall LF, Marshall SB, Klauber MR, Clark MB, Eisenberg HM, Jane JA, Luerssen TG, Marmarou A and Foulkes MA: A new classification of head injury based on computerized tomography. *Journal of Neurosurgery*, 1991; 75(1S): S14-20.
 18. Motuel J, Biette I, Srairi M, Mrozek S, Kurrek MM, Chaynes P, Cognard C, Fourcade O and Geeraerts T: Assessment of brain midline shift using sonography in neurosurgical ICU patients. *Critical Care*, 2014; 18(6): 676.
 19. Oliveira RAG, Lima MO, Paiva WS, Malbouisson LM, Teixeira MJ and Bor-seng-shu E: Comparison between brain computed tomography scan and transcranial sonography to evaluate third ventricle width, peri-mesencephalic cistern, and sylvian fissure in traumatic brain-injured patients. *Frontiers in neurology*, 2017; 8: 44.
 20. Perel PA: Predicting outcome after traumatic brain injury: practical prognostic models based on large cohort of international patients. *BMJ*, 2008; 336(7641): 425-429.
 21. Stolz E, Gerriets T, Fiss I, Babacan SS, Seidel G and Kaps M: Comparison of transcranial color-coded duplex sonography and cranial CT measurements for determining third ventricle midline shift in space-occupying stroke. *American Journal of Neuroradiology*, 1999; 20(8): 1567-1571.
 22. Tang SC, Huang SJ, Jeng JS and Yip PK: Third ventricle midline shift due to spontaneous supratentorial intracerebral haemorrhage evaluated by transcranial color-coded sonography. *Journal of ultrasound in medicine* 2006; 25(2): 203-209.
 23. Walter U, Behnke S, Eyding J, Niehaus L, Postert T, Seidel G and Berg D: "Transcranial brain parenchyma sonography in movement disorders: state of the art." *Ultrasound in Medicine and Biology* 2007; 33(1): 15-25.
 24. Walter U: "Transcranial sonography of the cerebral parenchyma: update on clinically relevant applications." *Perspectives in Medicine* 2012; 1(1-12): 334-343.
 25. Whiting PF, Rutjes AW, Westwood ME, Mallett S, Deeks JJ, Reitsma JB, Leeflang MM, Sterne JA and Bossuyt PM: "QUADAS-2: a revised tool for the quality assessment of diagnostic accuracy studies." *Annals of Internal Medicine* 2011; 155(8): 529-536.
 26. Wijnhoud AD, Franckena M, van der Lugt A and Koudsteal PJ: "Inadequate acoustical temporal bone window in patients with a transient ischemic attack or minor stroke: role of skull thickness and bone density." *Ultrasound in Medicine and Biology* 2008; 34(6): 923-929.
 27. Yanaka K, Kamezaki, T., Yamada, T., Takano, S., Meguro, K., and Nose, T.: "Acute subdural hematoma-prediction of outcome with a linear discriminant function."

7/29/2019