



## Management of chronic tibial osteomyelitis with one stage debridement and implantation of antibiotic-impregnated calcium sulfate

Ahmed M. Abdel Aleem

Orthopedic Department Sheben Elkom Teaching Hospital, Egypt

Email: [drahmedortho18@gmail.com](mailto:drahmedortho18@gmail.com)

**Abstract:** The treatment of chronic tibial osteomyelitis remains a problem, however many methods have been mention. In our study we aim to evaluate a unique approach of management using local debridement and antibiotic loaded calcium sulphate implantation for managing localized tibial chronic osteomyelitis.

[Ahmed M. Abdel Aleem. **Management of chronic tibial osteomyelitis with one stage debridement and implantation of antibiotic-impregnated calcium sulfate** Nat Sci 2023, 21(4):21-26]. ISSN 1545-0740 (print); ISSN 2375-7167 (online). <http://www.sciencepub.net/nature> 04.doi:[10.7537/marsnsj210423.04](https://doi.org/10.7537/marsnsj210423.04).

**Keywords:** chronic osteomyelitis, one stage management, tibia

### 1. Background:

Chronic osteomyelitis is defined as long standing infection associated with low grad inflammation with sequestrum formation or fistulous tract [1].

It is commonly associated with accidents, failed application of implants, or chronic hematogenous infection. Other than it is not common to be faced in our practice. With such type of infection, patients are suffering from annoying complications like recurrent fracture, nonunion and delayed healing or even amputation, therefor appropriate treatment is mandatory. chronic tibial osteomyelitis remains a resistant disease even with standard treatment protocols, with obvious recurrence rate of 20 to 30% [2].

A standard classification system based on physiological and anatomical aspects was introduced by Cierny and Mader in 1985 in order to help planning surgical treatment and also to improve its effects [3].

It is now considered as a standard classification for chronic long bone osteomyelitis [4].

Primarily, Cierny et al. divided chronic osteomyelitis into four types on anatomical base: medullary type I (involving only the medullary cavity), superficial type II (involving the superficial cortex), localized type III (involving part localized of cortex and medulla), and diffused type IV, and further classified patients into three groups based on physiological base 1-healthy patients (group A), 2-compromised patients (group B), and 3-patients who were too weak to receive surgery (group C).

The localized type of osteomyelitis is not as the diffused one (type IV), but still has its unique features. That is because the extent of infection is still limited, the clinical manifestations and signs might be less

severe as the diffused type, which means a forgiving prognosis could be reached if treated appropriately.

Local debridement without bone resection which occurred in the standard surgical technique avoids more bone loss and hence, secondary reconstruction to restore the length of the tibia is easier[5, 6].

Regarding the dead space created after bone resection, second-stage by muscle flaps or autogenous cancellous bone grafts after a time of systemic antibiotics is the standard approach which is effective in most cases [6, 7].

But, with drawbacks including the necessity of multiple sessions of surgical management, lon time of systemic antibiotics application, risk of severe donor sites problems. All these drawbacks have bad effects on both physicians and patients. In an attempt to decrease theses effects topical antibiotics use with co-carrier is a promising method. Calcium sulfate as the most common and effective antibiotic-impregnated material is widely used in management of osteomyelitis, and the final results were satisfying [8, 9].

This technique has great advantages as it is characterized by higher local antibiotic concentration in comparison with other technique in addition less side effects of longer treatment duration as well as its potential osteoconductive role [10, 11].

Statistically, tibia is the most common site to be affected by chronic osteomyelitis [7, 12].

Which may be due to its poor vascularity especially the distal part of tibia, the less soft tissue coverage especially on the medial surface, higher rate of trauma, and lastly the inappropriate surgical managements.

Chronic tibial localized osteomyelitis Type III has less attention as type IV. In our study we tried to

evaluate the effectiveness of local debridement accompanied with autogenous bone and antibiotic-loaded calcium sulfate, as one treatment approach of localized tibial osteomyelitis.

## 2. Patients and methods

From January 2019 to December 2022, we operated many cases of chronic osteomyelitis only 10 cases who met our inclusion criteria which are included in our study 1- diagnosed as localized chronic osteomyelitis in tibia 2- complete follow up to 12 months 3-surgery was performed by aggressive debridement combined with antibiotic loaded calcium sulphate. Other types of chronic osteomyelitis were excluded.

Total cases of 10, 10 limbs, 6 men and 4 women, with average age of 35years old, were included in our assessment. There were 7 (70%) local osteomyelitis on left tibias, and 3 cases (30%) on the right side. one patient was recorded to be smoker, and one to have

hypertension. Regarding the physiologic status of the patients, we classified the ten cases as 7 who were type IIIA and 3 patients as type IIIB. the main presenting complaints were pain, sinus discharging, swelling and non-weight bearing. little of them came with pain and redness only. The diagnosis was made by clinical presentation in form of recurrent pain hotness at localized area of the tibia combined with raised inflammatory markers as well as imaging studies. On physical examination there were no sever soft tissue compromise. On history talking Trauma and inappropriate treatment was the number one cause for infection which could further be divided into open tibial fracture (4 limbs, who received debridement and internal fixations) and closed fracture with ORIF (5 limbs). Hematogenous infection as the second common cause of infection was generally recorded in 1 case.

Table (1): characteristics and follow-up data of the patients.

	Age/ sex	Side	Cause	Smoking	Hospital stay(days)	Follow up(months)	Outcome
1-	30/M	LT	Trauma	no	7	24	remission
2-	33/F	LT	Trauma	no	5	30	remission
3-	35/F	RT	Trauma	no	4	36	remission
4-	37/M	LT	Trauma	no	7	34	remission
5-	38/F	RT	Trauma	yes	4	36	remission
6-	33/f	LT	Trauma	no	7	30	Slight pain
7-	36/M	LT	Blood born	no	5	30	redebridement
8-	37/M	RT	Trauma	no	6	36	remission
9-	35/M	LT	Trauma	no	7	30	remission
10-	36/M	LT	Trauma	no	7	32	remission

Clinical examinations, X-rays, and laboratory tests are applied to all patients when admitted to inpatient department in standard way. MRI may be requested in some patients especially those without implants to determine the extent of infection. Empirical antibiotics are not administrated until samples are sent for culture and sensitivity testing.

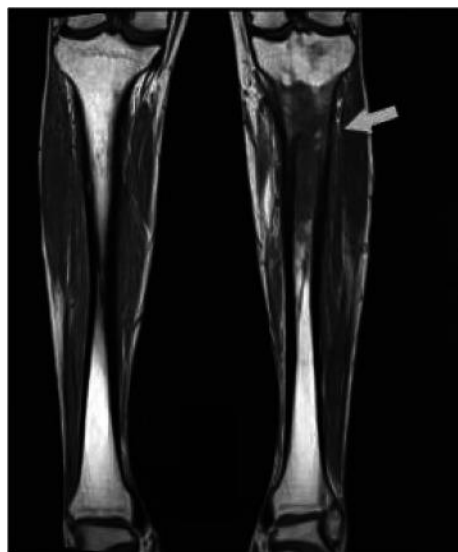


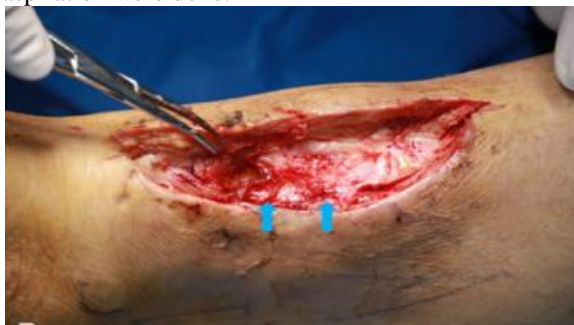Figure 1 preop MRI coronal views show the infection and help to determine the extent of debridement

Laboratory investigation preoperatively were as follow ESR= 23.22 mm/h, CRP = 3.41 mg/L and mean white blood cell was within normal values. Topical vancomycin and gentamicin were used intraoperatively to cover both gram +ve and gram -ve organisms

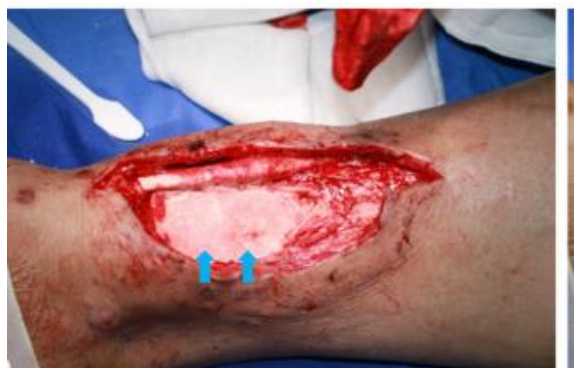### Surgical Technique

After spinal anesthesia which applied in all cases any sinuses or scars were removed, followed by extensive debridement of all necrotic tissues even those including the covering tendons and muscles surrounding the bone area to reach the infected cortex. fenestration and intramedullary debridement were done after removal of any remnant hardware. Fenestration was done with help of sharp osteotome and high speed burr. “Paprika sign” is dependable sign intraoperative to define the extent of infection and hence the extent of fenestration. For safety n debridement was done to the infected area and 5mm of health bone. (13)

After fenestration has been completed intramedullary debridement to remove any granulation tissues and sequestra by rongeur. samples were collected for laboratory examination. For adequate debridement intramedullary reaming, irrigation, and aspiration were done.



**Figure 2** Intra-operative views show debridement with calcium sulfate loaded with antibiotics



**Figure (3):** Intra-operative views of antibiotic-loaded calcium sulfate implanted into the bony cavity. The wounds were sutured directly. Flaps were used in the wounds with sever soft tissue defects.

### Postoperative management

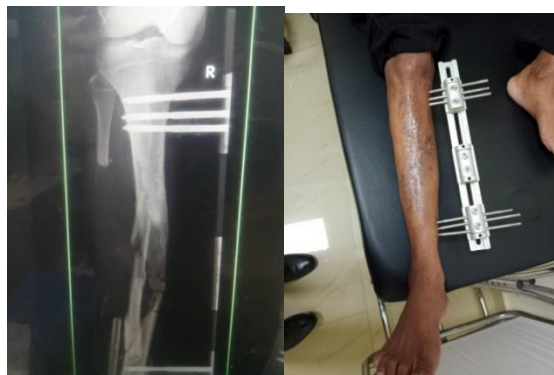Postoperatively empirical antibiotics were administered in early days till results of cultures and sensitivity appear then continue to not more than 2 weeks. wound dressings every 2 days. full weight bearing was encouraged in early few days after postoperative pain subsided. Follow up x-ray continue every 3 weeks to assess complete union.

Postoperative evaluation is dependent on subjective and objective factors subjective from patient complaint regarding pain sensation especially on weight bearing, objectively as regarding clinical examination radiological and laboratory assessment. Main outcomes were focused on infection remission or recurrence bony union. infection remission was defined as complete absence of osteomyelitis signs and healed wounds confirmed by laboratory and radiological assessment.

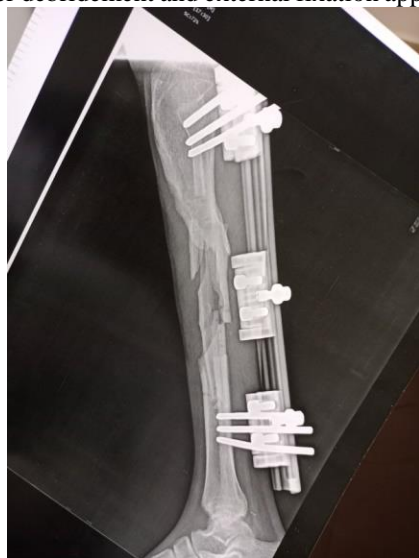### 3. Results

The extent of tibial debridement was determined roughly by radiological examination. 20.9 cm<sup>2</sup> (range, 2.5 to 49.8 cm<sup>2</sup>) was the average excised area from tibia. the vacant area determined the amount of antibiotic-loaded calcium sulfate which used, potential toxic effects as well as patient’s economic situation. Mean volume of calcium sulphate used in our study was 25 cc. this high concentration helps to decrease the duration of systemic antibiotics used not more than 2 weeks (the standard protocol was 2 weeks for parental route followed by 4 weeks for oral use.

Histological examination of all specimens confirmed the diagnosis of chronic tibial osteomyelitis. Staphylococcus aureus is the most common pathogen isolated by culture. However, in one case it was a polymicrobial infection. During a mean follow-up of 36 months we found 80 % limbs achieved complete infection remission without any relapse. Only 20% suffered from infection recurrence within 3 years of follow up. The treatment of these cases was segmental bone resection and bone transport by ilizarof external fixator. The main complication noticed during the follow up were aseptic drainage, pain after a long-distance, scar formation and limb weakness or discomfort. During the follow-up no cases of tibial fracture or malalignment. External fixation was applied in all cases to provide stability and avoid tibial fracture. adequate bone formation was achieved in all operated limbs According to X-ray examination.



**Figure (4):** 33 years old male early postoperative x-ray after debridement and external fixation application



**Figure 5:** same patient after 6 months show union progression without signs of remission

#### 4. Discussion

Chronic tibial Type III osteomyelitis involves the cortical bone and medullary cavity, which may convert to a diffuse type if not properly treated. However, conservative antibiotic treatment alone to achieve satisfying outcomes is so difficult due to impaired local blood supply on bone sclerosis and sequestrum formation, even with a long time of administration. In addition, biofilm formation commonly associated with *Staphylococcus aureus* the most frequent pathogen detected in osteomyelitis, which binds firmly to the outer surface of the bone as well as the internal implants used for fixation, causing the infection to be so difficult for eradication [14].

So, surgical intervention is the method of choice for treating osteomyelitis. Not only to remove the necrotic and dead tissues but also to eradicate the biofilm caused by virulent pathogens. There for improving the vascularity and enhancing the effectiveness of antibiotics.

The main principles of proper surgical treatment of osteomyelitis requires debridement of any dead tissues with some adjacent healthy bone to create a relatively clean environment for subsequent reconstruction. On other hand to preserve as much as healthy bone to prevent the incidence of postoperative fractures or deformities. Therefore, massive debridement and subsequent bone resection is unsuitable for the treating the localized type of tibial osteomyelitis like diffuse osteomyelitis. To properly achieve these targets, local debridement including decortication as well as intramedullary debridement is documented as the standard treatment of localized tibial osteomyelitis and the effects are satisfying.

In a previous study done by Beals and Bryant operated 30 consecutive cases with tibial osteomyelitis localized type, which included 1 case with Cierny-Mader type IIIA and the other 8 cases with type IIIB. The treatment methods included local debridement which is done only in 5 cases, local debridement plus muscle flaps coverage done by plastic surgeon in 2 cases, and debridement in multiple sessions and bone graft in 1 case. All the patients have good outcomes at the end of follow-up [15].

Kinik and Karaduman have operated on 26 cases with localized tibial osteomyelitis. All patients have treated with decortication and local debridement, with irrigation, antibiotic-impregnated polymethylmethacrylate (PMMA) beads implantation at first stage, followed by second stage of re-debridement, and PMMA beads removal 6 to 8 weeks after the first one. With a mean follow-up of 3.6 years all patients have had good outcomes regarding infection control with normal clinical parameters with exception of 3 patients had to received additional re-debridement in the interval [6].

The main difference In our series is the replacement of antibiotic-impregnated PMMA beads or autogenous bone grafts by biodegradable calcium sulfate impregnated with antibiotic, Which has high local antibiotic concentration and relatively longer curative duration may extend to several weeks to months [5, 16, 17].

This may be helpful in decreasing the duration of systemic antibiotics but also eliminates more residual pathogens. Moreover, the osteo-conductivity property of calcium sulfate provides scaffold for osteoblasts and other mesenchymal cells for the repair process. All these advantages allow the orthopedists to do debridement and reconstruction in one stage

At the end of follow up of all cases in our study we have achieved satisfying results. This is proven by 80% of our cases have had complete infection remission after the first operation. Even for the 2 cases showed recurrence only second debridement was enough to achieve good outcomes. Similar study by



Ferguson et al which involved 144 cases with type III chronic osteomyelitis of tibia treated with local debridement and calcium sulfate impregnated with tobramycin antibiotic. Their conclusion was that 7.6% of cases have recurrence within the follow up in 3.7 years, while most of cases cured completely [19].

Ferrando et al in another study have a relatively similar result after using of antibiotic implanted topically in chronic osteomyelitis. They compared between bioglass and calcium sulfate beads in treating chronic infection of the bone. 12 patients of 13 patients with antibiotic-loaded calcium sulfate implantation, have complete healing and infection eradication [19].

Associated complications other than infection recurrence are also of considerable attention. The first is prolonged aseptic discharge was the most common complication documented, which is proportional to the volume of calcium sulfate implanted into the cavity and the integrity of overlying soft tissues. Commonly seen in cases with poor soft tissue cover especially on the medial surface of distal tibia, and those with previous scar. It is greatly variables between different studies. In study by Kallala et al it was 4.2% incidence after calcium sulfate implantation [8].

Compared to the higher incidence of 15.4% [18], in study by Ferguson JY et al. It may reach higher incidence 27% [20] in other studies.

Of note, isolated prolonged aseptic drainage alone should not be diagnosed as a sign of recurrence, as it is commonly related to calcium sulphate degradation however it is so simple but should managed adequately. Though it is sterile, but may cause wound infection. It is simply managed by regular dressing and wound care. Another complication is non-self-restored shape of tibia which may be due to misrelation between calcium sulfate degradation and osteoblasts growth. there is no evidence in the literatures explain the mechanism of such complication but we did not notice any fracture or even bowing during the follow-up. This means that the tibia restored the normal strength for weight bearing.

Our study become one of rare studies to evaluate the outcomes of this technique in treating chronic tibial osteomyelitis in a single-stage way. Finally, we included different forms of infection caused by traumatic injuries and related treatment modalities, hematogenous infection, and penetrating injuries in our study. However, the cause of infection whether by fracture, hematogenous route, or direct inoculation, the treatment protocols were similar in all circumstances—local debridement with calcium sulfate loaded by antibiotics.

## Conclusion

Aggressive debridement together with implantation of calcium sulfate- antibiotic mix as a single-stage technique is a promising treatment modality of chronic tibial infection.

## References

- [1]. Jiang N, Ma Y, Jiang Y, Zhao X, Xie G, Hu Y, Qin C, Yu B. Clinical characteristics and treatment of extremity chronic osteomyelitis in Southern China. *Medicine*. 2015;94(42):e1874.
- [2]. Bhattacharya R, Kundu B, Nandi SK, Basu D. Systematic approach to treat chronic osteomyelitis through localized drug delivery system: bench to bed side. *Mater Sci Eng C*. 2013;33(7):3986–3993.
- [3]. Cierny GR, Mader JT, Penninck JJ. A clinical staging system for adult osteomyelitis. *Clin Orthop Relat Res*. 2003;414:7–24.
- [4]. Parsons B, Strauss E. Surgical management of chronic osteomyelitis. *Am J Surg*. 2004;188(1):57–66.
- [5]. Wahl P, Guidi M, Benninger E, Ronn K, Gautier E, Buclin T, Magnin JL, Livio F. The levels of vancomycin in the blood and the wound after the local treatment of bone and soft-tissue infection with antibiotic-loaded calcium sulphate as carrier material. *Bone Joint J*. 2017;99-B(11):1537–1544.
- [6]. Kinik H, Karaduman M. Cierny-Mader type III chronic osteomyelitis: the results of patients treated with debridement, irrigation, vancomycin beads and systemic antibiotics. *Int Orthop*. 2008;32(4):551–558.
- [7]. Zumiotti AV, Teng HW, Ferreira MC. Treatment of post-traumatic tibial osteomyelitis using microsurgical flaps. *J Reconstr Microsurg*. 2003;19(3):163.
- [8]. Kallala R, Harris WE, Ibrahim M, Dipane M, McPherson E. Use of stimulan absorbable calcium sulphate beads in revision lower limb arthroplasty: safety profile and complication rates. *Bone Joint Res*. 2018;7(10):570–579.
- [9]. Qin CH, Zhang HA, Chee YH, Pitarini A, Adem AA. Comparison of the use of antibiotic-loaded calcium sulphate and wound irrigation-suction in the treatment of lower limb chronic osteomyelitis. *Injury*. 2019;50(2):508–514.
- [10]. Beuerlein MJ, McKee MD. Calcium sulfates: what is the evidence? *J Orthop Trauma*. 2010;24 (Suppl 1):S46–S51.
- [11]. De Long WJ, Einhorn TA, Koval K, McKee M, Smith W, Sanders R, Watson T. Bone grafts and bone graft substitutes in orthopaedic

- trauma surgery. A critical analysis. *J Bone Joint Surg Am.* 2007;89(3):649–658.
- [12]. Yikemu X, Tuxun A, Nuermaimaiti M, Abudukeyimu A, Shayiti A. Effects of vacuum sealing drainage combined with Ilizarov bone transport technique in the treatment of tibial traumatic osteomyelitis. *Med Sci Monitor.* 2019;25:6864–6871.
- [13]. Simpson AH, Deakin M, Latham JM. Chronic osteomyelitis. The effect of the extent of surgical resection on infection-free survival. *J Bone Joint Surg Br.* 2001;83(3):403–407.
- [14]. Donlan RM. Biofilms: microbial life on surfaces. *Emerg Infect Dis.* 2002;8(9):881–890.
- [15]. Beals RK, Bryant RE: The treatment of chronic open osteomyelitis of the tibia in adults. *Clin Orthop Relat R* 2005, &NA;(433):212-217.
- [16]. Miclau T, Dahners LE, Lindsey RW. In vitro pharmacokinetics of antibiotic release from locally implantable materials. *J Orthop Res.* 1993;11(5):627–632.
- [17]. Cooper JJ, Florance H, McKinnon JL, Laycock PA, Aiken SS. Elution profiles of tobramycin and vancomycin from high-purity calcium sulphate beads incubated in a range of simulated body fluids. *J Biomater Appl.* 2016;31(3):357–365.
- [18]. Ferguson JY, Dudareva M, Riley ND, Stubbs D, Atkins BL, McNally MA. The use of a biodegradable antibiotic-loaded calcium sulphate carrier containing tobramycin for the treatment of chronic osteomyelitis: a series of 195 cases. *Bone Joint J.* 2014;96-B(6):829–836.
- [19]. Ferrando A, Part J, Baeza J. Treatment of cavitary bone defects in chronic osteomyelitis: bioactive glass S53P4 vs. calcium sulphate antibiotic beads. *Journal of Bone and Joint Infection.* 2017;2(4):194–201
- [20]. Romano CL, Logoluso N, Meani E, Romano D, De Vecchi E, Vassena C, Drago L. A comparative study of the use of bioactive glass S53P4 and antibiotic-loaded calcium-based bone substitutes in the treatment of chronic osteomyelitis: a retrospective comparative study. *Bone Joint J.* 2014;96-B(6):845–850.

5/20/2023