

## Comparative Study between 3D / 4D Ultrasound an Hysteroscopy in Evaluation of Cases of Recurrent Abortion

Abdel Samee Hassan Khalifa<sup>1</sup>, Mohamed Mohamed Ibrahim Farahat<sup>1</sup> and Yusuf Haggag Abdo Mohamed<sup>2</sup>

<sup>1</sup>Department of Obstetrics and Gynecology, Faculty of Medicine, Al-Azhar University, Cairo, Egypt

<sup>2</sup>Department of Obstetrics and Gynecology, El- Matarya Teaching Hospital, Cairo, Egypt

[dr.joe01148904361@gmail.com](mailto:dr.joe01148904361@gmail.com)

**Abstract: Background:** This study aimed to compare between 3D / 4D Ultrasound an Hysteroscopy in Evaluation of Cases of Recurrent Abortion. **Methods:** This clinical trial was conducted at Al-Azhar University hospitals (Hussien & Said Galal) for women with recurrent pregnancy loss on 100 on 100 women divided in two groups each group 50 womens. **Results:** There was significant difference between two groups regarding to 3D and Hysteroscopy, but 4D and hysteroscopy there was non significance difference value. **Conclusion:** 3D and 4D TVS is both sensitive and specific in diagnosing uterine polyps and submucus fibroids, but with a low PPV, both in first trimester and second trimester RPL groups with hysteroscopy taken as a reference. However, 3D and 4D TVS has a moderate sensitivity in the diagnosis of a double-cavity uterus in the first trimester RPL group, and a low sensitivity in the diagnosis of the same condition in the second trimester RPL group. Hysteroscopy is a minimally invasive, highly accurate and efficient diagnostic method in the detection of uterine anomalies.

[Abdel Samee Hassan Khalifa, Mohamed Mohamed Ibrahim Farahat and Yusuf Haggag Abdo Mohamed. **Comparative Study between 3D / 4D Ultrasound an Hysteroscopy in Evaluation of Cases of Recurrent Abortion.** *Nat Sci* 2019;17(3):52-57]. ISSN 1545-0740 (print); ISSN 2375-7167 (online). <http://www.sciencepub.net/nature>. 9. doi:10.7537/marsnsj170319.09.

**Keywords:** 3D and 4D – Hysteroscopy – Recurrent abortion.

### 1. Introduction

Defining RPL as a clinical entity requiring diagnostic testing and therapeutic intervention rests on knowledge of the elevation of risk for subsequent fetal loss and the probability of finding a treatable etiology for the disorder. Although no reliable published data have estimated the probability of finding an etiology for RPL in a population with 2 versus 3 or more miscarriages, the best available data suggest that the risk of miscarriage in subsequent pregnancies is 30% after 2 losses, compared with 33% after 3 losses among patients without a history of a live birth. (ACOG., 2001) .

Hysteroscopy is a minimally invasive, highly accurate and efficient diagnostic method in the detection of uterine anomalies.

3D and 4D TVS is both sensitive and specific in diagnosing uterine polyps and submucus fibroids.

#### Causes of recurrent pregnancy loss:

- 1-Genetic Etiologies
- 2-Anatomic Etiologies
- 3-Endocrine Etiologies
- 4-Infectious Etiologies
- 5-Immunologic Etiologies
- 6-Thrombotic Etiologies
- 7-Environmental Etiologies
- 8-Unexplained Etiologies
- 9- Mullarian duct agencies such as
  - Bicornut uterus

- Septate uterus as it considered most common cause of recurrent pregnancy loss

#### Prognosis:

The prognosis for RPL is encouraging. Even with the diagnosis of RPL and as many as 4 to 5 prior losses, a patient is more likely to carry her next pregnancy to term than to have another loss (**Clifford K, et al.,1997**).

### 2. Patient and methods:

This cross-sectional study was conducted at Al-Azhar University Hospital (Al- Hussien and Al-Sayed Galal).

A total of 100 patients having a history of 2 or more recurrent pregnancy loss were recruited from the out-patient clinics of Gynecology and Obstetrics department of the Al-Azhar University Hospital (Al-Hussien and Al-Sayed Galal).

#### Patients included in the study were divided into two groups:

**Group (1):** Two RPL 42% which having congenital malformation of the uterus which diagnosed before by 3D and 4D ultrasounds.

**Group (2):** > Three RPL 58 % which having congenital malformation of the uterus which diagnosed before by 3D and 4D ultrasounds.

#### Inclusion criteria:

1. Women with history of two recurrent pregnancy loss or more first trimester abortions.
2. Women with history of > three recurrent

pregnancy loss or more second trimester abortions.

The history of previous abortion should be documented by a positive pregnancy test or the history of expulsion of products of conception (in first trimester abortion) or the expulsion of a fetus (in second trimester abortion).

**Exclusion criteria:**

**The following were not considered in line with the definition of spontaneous abortion i.e. were excluded from our study:**

1. Molar pregnancy.
2. Ectopic pregnancy.
3. Induced abortion.

According to the medical ethics, the steps of the work and the details of the procedures were explained to the patients.

After obtaining an informed consent, each patient was submitted to the following:

**1. Full history taking:**

With special focus on the age, medical, obstetric and genetic history and pedigree analysis. The detailed history of previous pregnancy losses and the presence of potential risk factors in the preconception period were taken.

**2. Thorough examination including:**

**General examination**

Local examination: vaginal examination for detection of uterine size by bimanual examination and detection of any vaginal septae or cervical abnormalities.

Was performed by a single investigator after the patient was instructed to empty her bladder. The uterus was scanned in the sagittal plane. The double-layer endometrial thickness was measured at the widest point between the endometrial-myometrial interfaces in the sagittal plane by using electronic calipers.

**Hysteroscopy Examination:**

Was performed during the follicular phase of the cycle (between days 5 and 13). The procedure was done on an out-patient setting with anesthesia by an investigator who was blinded to the ultrasound findings. A 30 degree forward-oblique lens telescope and a 5 mm outer diameter rigid continuous flow hysteroscope (Tekno, GmbH, Germany) were used. In the presence of a narrow cervical canal, 400 µg misoprostol (Cytotec® 200 µg tablets, Pharmacia, Kent, UK) were administered vaginally two hours before the procedure.

**3. Results:**

The results of the present study are demonstrated in the following tables and figures:

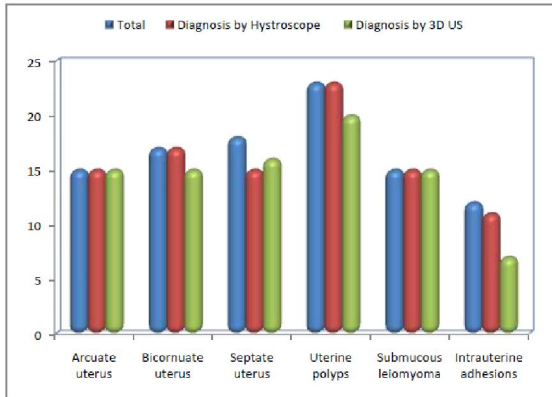
**Table (1):** Comparison between diagnosis by hysteroscopy and diagnosis by 3D US according to etiology factors.

Etiology of repeated pregnancy loss	Total (n=100)	Diagnosis by Hysteroscopy		Diagnosis by 3D US	
		Yes	No	Yes	No
Arcuate uterus	15	15	0	15	0
Bicornuate uterus	17	17	0	15	2
Septate uterus	18	15	3	16	2
Uterine polyps	23	23	0	20	3
Submucous leiomyoma	15	15	0	15	0
Intrauterine adhesions	12	11	1	7	5
Total	100	96	4	88	12
<b>Kapp test</b>		0.840			
<b>p-value</b>		<b>0.024*</b>			

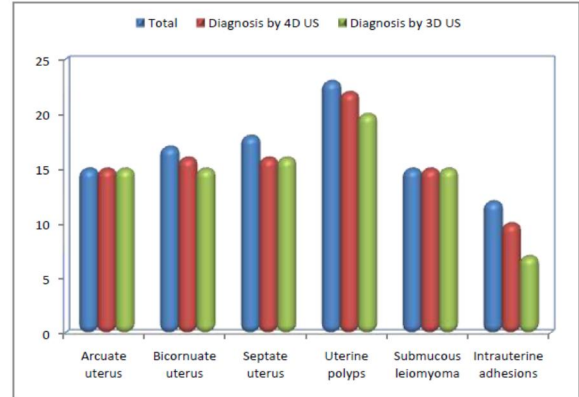
The inter-method agreement between diagnosis by hysteroscope and diagnosis by 4D US less than  $\kappa=1$ . There is a slight difference in favor of hysteroscopy.

**Table (2):** Comparison between diagnosis by 4D US and diagnosis by 3D US according to etiology factors.

Etiology of repeated pregnancy loss	Total (n=100)	Diagnosis by 4D US		Diagnosis by 3D US	
		Yes	No	Yes	No
Arcuate uterus	15	15	0	15	0
Bicornuate uterus	17	16	1	15	2
Septate uterus	18	16	2	16	2
Uterine polyps	23	22	1	20	3
Submucous leiomyoma	15	15	0	15	0
Intrauterine adhesions	12	10	2	7	5
Total	100	94	6	88	12
<b>Kapp test</b>		0.820			
<b>p-value</b>		<b>0.038*</b>			



**Figure (1):** Bar chart between diagnosis by hysteroscopy and diagnosis by 3D US according to etiology factors.



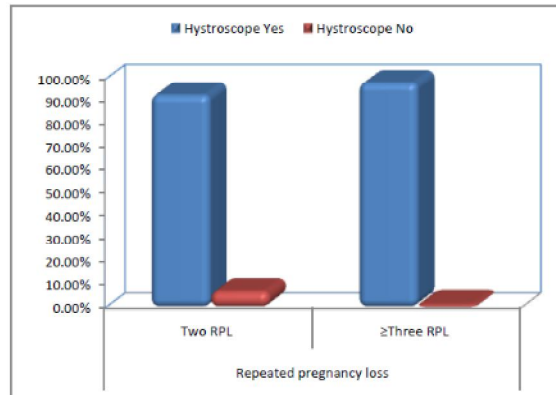
**Figure (2):** Bar chart between diagnosis by 4D US and diagnosis by 3D US according to etiology factors.

The inter-method agreement between diagnosis by hysteroscope and diagnosis by 4D US less than  $\kappa = 1$ . There is a slight difference in favor of 4D US.

**Table (3):** Relation between diagnosis by hysteroscopy and repeated pregnancy loss.

Repeated pregnancy loss	Diagnosis by Hysteroscopy				Chi-square test	
	Yes		No		x2	p-value
	No.	%	No.	%		
Two RPL (n=42)	39	92.9%	3	7.1%	0.719	0.396
≥Three RPL (n=58)	57	98.3%	1	1.7%		
Total	96	96.0%	4	4.0%		

The table shows no statistically significant relation between diagnosis by hysteroscopy and repeated pregnancy loss.

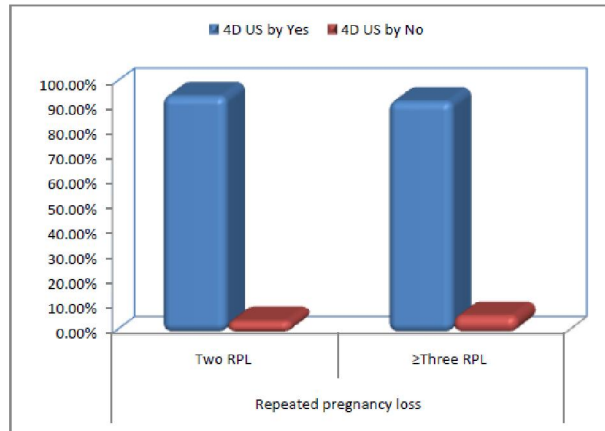


**Figure (3):** Bar chart between diagnosis by hysteroscopy and repeated pregnancy loss.

**Table (4):** Relation between diagnosis by 4D US and repeated pregnancy loss.

Repeated pregnancy loss	Diagnosis by 4D US				Chi-square test	
	Yes		No		x2	p-value
	No.	%	No.	%		
Two RPL (n=42)	40	95.2%	2	4.8%	0.107	0.744
≥Three RPL (n=58)	54	93.1%	4	6.9%		
Total	94	94.0%	6	6.0%		

The table shows no statistically significant relation between diagnosis by 4D US and repeated pregnancy loss.

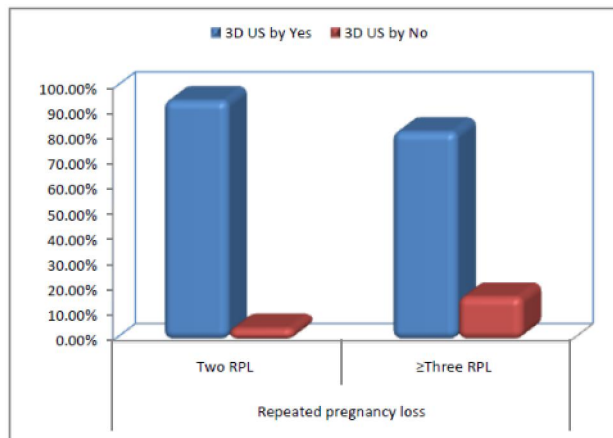


**Figure (4):** Bar chart relation between diagnosis by 4D US and repeated pregnancy loss.

**Table (5):** Relation between diagnosis by 3D US and repeated pregnancy loss.

Repeated pregnancy loss	Diagnosis by 3D US				Chi-square test	
	Yes		No		x2	p-value
	No.	%	No.	%		
Two RPL (n=42)	40	95.2%	2	4.8%	2.508	0.113
≥Three RPL (n=58)	48	82.8%	10	17.2%		
Total	88	88.0%	12	12.0%		

The table shows no statistically significant relation between diagnosis by 3D US and repeated pregnancy loss.



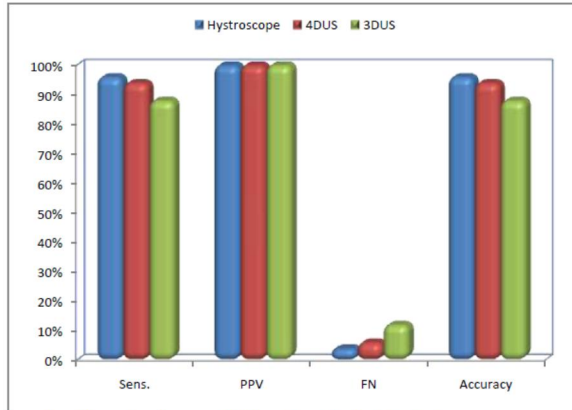
**Figure (5):** Bar chart relation between diagnosis by 3D US and repeated pregnancy loss.

**Table (6):** Diagnostic Performance of etiology factors in Discrimination between hystroscopy, 4D US and 3D US.

Diagnostic	Sens.	PPV	FN	Accuracy
Hystroscopy	96%	100%	4%	96%
4DUS	94%	100%	6%	94%
3DUS	88%	100%	12%	88%

**Diagnostic performance of etiology factors in discrimination by:**

- **Hystroscopy:** Sensitivity 95%, PPV 100%, FN 4% and accuracy 96%.
- **4D US:** Sensitivity 94%, PPV 100%, FN 6% and accuracy 94%.
- **3D US:** Sensitivity 88%, PPV 100%, FN 12% and accuracy 88%.



**Figure (6):** Bar chart diagnostic Performance of etiology factors in Discrimination between hysteroscopy, 4D US and 3D US.

#### 4. Discussion

Various etiologies have been proposed as contributing to RPL; these include genetic abnormalities, congenital and acquired uterine anomalies, endocrine and autoimmune diseases, thrombophilic disorders, and certain infections (Li et al., 2002; Jauniaux et al., 2006).

Congenital uterine anomalies result from abnormal formation, fusion or resorption of the Mullerian ducts during fetal life (Moore et al., 2008). These anomalies have been associated with an increased rate of miscarriage, preterm delivery and other adverse fetal outcomes (Green and Harris, 1976; Rock and Schlaff, 1985; Acien, 1993; Raga et al., 1997; Grimbizis et al., 2001; Tomazevic et al., 2007).

The definition of recurrent miscarriage fluctuates between two or three consecutive losses. For our study, we have chosen to include two miscarriages, taking into account comments made by Stirrat (1990) that two losses justified investigation as there was a significant rise in the risk of subsequent miscarriage (Stirrat, 1990).

The prevalence of anatomic uterine defects in the study groups as diagnosed by hysteroscopy with complementary 3D/4D.

**Diagnostic performance of etiology factors in discrimination by Hysteroscopy:** Sensitivity 96 %, PPV 100%, FN 4% and accuracy 96%. **4D US:** Sensitivity 94%, PPV 100%, FN 6% and accuracy 94%. **3D US:** Sensitivity 88%, PPV 100%, FN 12% and accuracy 88%.

In the current study, when we considered congenital and acquired uterine defects as separate entities, we found that the prevalence of congenital anatomic defects in the two RPL 42%, acquired uterine defects in the three RPL > 58%.

The most common congenital uterine anomaly reported in this study in both first trimester RPL and second trimester RPL was the uterine septum.

Pooled data from reports comparing 3D, 4D US and hysteroscopy suggest high sensitivities nearly (100%) (Valenzano et al., 2006; Traina et al., 2004; Soares et al., 2000).

There seems to be a pattern of low sensitivities coupled with high specificities with 3D, 4D US and hysteroscopy imaging. This suggests that although 3D, 4D US and hysteroscopy can only identify about half of the congenital uterine anomalies present; its diagnosis is very likely to be correct. Therefore, it could prove to be a very effective screening tool in conjunction with HSG since they are both widely available (Sarvelos et al., 2008).

Hysteroscopy is considered to be the most reliable modality for assessment of the uterine cavity. It shows a high sensitivity and specificity when compared to surgical and histopathologic findings. It is superior to hysterosalpingography for identification of intrauterine pathology. Moreover, it has a therapeutic role in the management of anatomic uterine defects (Emanuel et al., 1995; Nguyen et al., 1997; Homer et al., 2000).

Hysteroscopy allows direct visualization of the intrauterine cavity and ostia. It is therefore very accurate in identifying congenital uterine anomalies and is often used to establish a definitive diagnosis after an abnormal HSG finding (Leterie, 1998; Soares et al., 2000; Homer et al., 2000). However, it does not allow for the evaluation of the external contour of the uterus and is therefore often inadequate in differentiating between different anomaly types.

Consequently, for the correct differentiation between bicornuate and septate uteri, further investigation is required, most commonly a diagnostic laparoscopy.

Some authors consider this combination (hysteroscopy/laparoscopy) to be the gold standard in evaluating congenital uterine anomalies (Hamilton et al., 1998; Letterie, 1998; Homer et al., 2000; Grimbizis et al., 2001; Taylor and Gomel, 2008).

Hysteroscopy with laparoscopy offers the added advantage of concurrent treatment, as in the case of a uterine septum resection.

Laparoscopy allows direct visualization of the contour of the uterus and offers the advantage of concurrent diagnosis and treatment. Therefore, we performed laparoscopy for the differential diagnosis of a septate or bicornuate uterus.

Hysteroscopy is a minimally invasive, highly accurate and efficient diagnostic method in the detection of uterine anomalies. Carrying out the procedure in an outpatient setting with anesthesia. (Cogendez et al., 2011; Dendinos et al., 2008).

**References**

1. Abalovich M, Gutierrez S, Alcaraz G, et al.: Overt and subclinical hypothyroidism complicating pregnancy. *Thyroid*. 2002; 12:63—68.
2. ACOG practice bulletin (2001). Management of recurrent pregnancy loss. Number 24, February 2001. (Replaces Technical Bulletin Number 212, September 1995). American College of Obstetricians and Gynecologists. *Int J Gynaecol Obstet*. 2002 Aug;78(2):179-90.
3. Alborzi S, Dehbashi S, Parsanezhad ME.: Differential diagnosis of septate and bicornuate uterus by sonohysterography eliminates the need for laparoscopy. *Fertil Steril*. 2002; 78(1):176-178.
4. Faivre E, Fernandez H, Deffieux X et al.: Accuracy of three-dimensional ultrasonography in differential diagnosis of septate and bicornuate uterus compared with office hysteroscopy and pelvic magnetic resonance imaging. *J Minim Invasive Gynecol*. 2012 Jan-Feb;19(1):101-6.
5. Ghi T, Casadio P, Kuleva M, Perrone AM, Savelli L, Gianchi S, Pelusi C, Pelusi G. Accuracy of three-dimensional ultrasound in diagnosis and classification of congenital uterine anomalies. *Fertil Steril* 2012;92:808-813.
6. Gurnee Y, Crystal L, Advanced Fertility Center of Chicago.
7. Gurnee & Crystal Lake, Illinois *Ultrasound Obstet Gynecol*. Apr 2007;5(4):233-7.
8. Heard MJ, Pierce A, Carson SA, et al.: Pregnancies following use of metformin for ovulation induction in patients with polycystic ovary syndrome. *Fertil Steril* 2002; 77:669-673.
9. Kaufman Y, Lam A. The pelvic uterus-like mass-a primary or secondary Müllerian system anomaly?. *J Minim Invasive Gynecol*. Jul-Aug 2008;15(4):494-7.
10. Kovalevsky G, Gracia CR, Berlin JA, et al: Evaluation of the association between hereditary thrombophilias and recurrent pregnancy loss: a meta-analysis. *Arch Intern Med*. 2004;164:558—563.
11. Ludwin A, Ludwin I, Pityriski K, Banas T, Jach R. Role of morphologic characteristics of the uterine septum in the prediction and prevention of abnormal healing outcomes after hysteroscopicmetroplasty. *Hum Reprod* 2014;16:1-12.
12. Sara Zieher. *Ultrasound of the uterus, Current Clinical and Technical Concepts: A Sonographer's perspective*. *Fertil Steril*. Jan 2008;47(1):89-93.
13. Simpson WL Jr, Beitia LG, Mester J. *Hysterosalpingography: areemerging study*. *Radiographics* 2006;26:419-431.

1/1/2019