

## Immunological Expression of Heat Shock Protein 70 in Vitiligo

Wafaa Afify Mahmoud<sup>1</sup>, Naglaa Abdallah Ahmed<sup>1</sup>, Naglaa Samir Ahmed<sup>2</sup>, Mervat Ahmed Swelam<sup>1</sup> and Noha Ahmed Mahmoud<sup>1</sup>

Dermatology Department, Faculty of Medicine, Al Azhar University, Egypt

Pathology Department, Faculty of Medicine, Ain Shams University, Egypt

[neho.noha@yahoo.com](mailto:neho.noha@yahoo.com)

**Abstract: Background:** Vitiligo is a progressive depigmenting disorder characterized by the loss of functional melanocytes from the epidermis. Heat shock proteins (HSPs) are prime candidates to connect stress to the skin. HSPs were found to be implicated in autoimmune diseases such as rheumatoid arthritis and other skin disorders as psoriasis. **Objectives:** The aim of this study was to investigate the expression of Hsp70 in vitiliginous and normal skin by immunohistochemistry to declare its role in the pathogenesis and activity of vitiligo. **Materials and Methods:** This study included 30 patients with vitiligo, 30 age and gender matched healthy controls. Skin biopsies were taken from the controls, lesional and perilesional skin of all cases. Two sections from each block of lesional biopsies were taken. One was stained with hematoxylin and eosin for routine histopathologic examination. The other section was stained immuno- histochemically for HSP-70 .One section from each block of perilesional and normal biopsies was stained immuno- histochemically for HSP-70. **Results:** Intense and diffuse expression of Hsp70 was in favor of lesional vitiligo skin compared to nonlesional skin biopsies from vitiligo patients ( $P < 0.001$ ) and compared to skin biopsies from healthy controls ( $P < 0.001$ ). The intensity of HSP70 expression is significantly high in the more active form of the disease. The nuclear form of Hsp70 was only seen in vitiligo cases. **Conclusions:** HSP-70 play a role in the pathogenesis of vitiligo and may enhance the immune response in active disease. Nuclear localization of HSP 70 may be important, beside it may be related to progression of the disease.

[Wafaa Afify Mahmoud, Naglaa Abdallah Ahmed, Naglaa Samir Ahmed, Mervat Ahmed Swelam and Noha Ahmed Mahmoud **Immunological Expression of Heat Shock Protein 70 in Vitiligo.** *Nat Sci* 2018;16(12):96-100]. ISSN 1545-0740 (print); ISSN 2375-7167 (online).<http://www.sciencepub.net/nature>. 16. doi:[10.7537/marsnsj161218.16](https://doi.org/10.7537/marsnsj161218.16).

**Keywords:** Vitiligo, Hsp70, Immunohistochemistry.

### 1. Introduction:

Vitiligo is an aquired depigmenting disorder characterized by the loss of functional melanocytes from the epidermis [1], and is characterized by depigmented macules and patches of skin [2]. It affects about 1 to 2 percent of the world's population, vitiligo occurs in localized, generalized, or segmental patterns, and can run a rapidly progressive course or remain stationary [3].

Heat shock proteins (HSPs) are certain proteins that are expressed under variety of stresses including heat, heavy metals, toxins, oxidants, and infections and play a major role in protecting cells against damage under stressful conditions [4].

Extracellular located HSP-70 mediates the immunological response to proteins and peptides derived from the cells under stress through activation of lymphocytes and macrophages, activation and maturation of dendritic cells as an antigen presenting cells and initiating the release of cytokines, including tumor necrosis factor- $\alpha$ , interleukin (IL)-1 $\beta$ , IL-12, and IL-6 which are apoptosis mediators and melanocytes proliferation and melanogenesis inhibitor leading to vitiligo [5,6].

### 2. Patients and methods:

This study included 30 patients with vitiligo (20 females and 10 males) , 30 age and gender matched healthy volunteers as a control. The patients were recruited from Dermatology Outpatient Clinic, whereas controls were selected from Plastic Surgery Clinic, Faculty of Medicine, Al Zahraa University Hospital during the period from January 2014 and November 2016. The purpose of this study was explained for each patient. A written informed consent was taken from each patient.

#### Inclusion criteria:

- 1- Age : over 15 years old and both sexes were included
- 2- Patients not receiving any systemic for 12 months or topical treatment for vitiligo for 6 months before the study.
- 3- Type of vitiligo : segmental and non segmental vitiligo

#### Exclusion criteria:

- 1- patients and controls with malignancies, autoimmune diseases other than vitiligo
- 2- More than 60-years-old
- 3- Pregnancy and lactation

Each of the selected patients was subjected Complete history taking ,general examination,

dermatological examination for the type, extent, and site of vitiliginous lesion and Histopathologic examination.

Assessment of the disease severity by vitiligo disease activity (VIDA) score [7]

Skin biopsies were taken from the controls, lesional and perilesional skin of all cases. Each biopsy was submitted to routine tissue processing and paraffin-embedded blocks formation. Two 5-mm-thick sections from each block of lesional biopsies were taken. One was stained with hematoxylin and eosin for routine histopathologic examination. The other section was mounted on Superfrost Plus slides, to be stained immunohistochemically for HSP-70. One 5-mm-thick section from each block of perilesional and normal biopsies was taken and was stained immunohistochemically for HSP-70.

#### **Immunohistochemical staining for Hsp70**

Slides were submitted to subsequent steps of deparaffinization, rehydration, blocking of endogenous peroxidase activity, and antigen retrieval by boiling in 10-mM citrate buffer, pH 6.0, for 10 minutes.

The slides were then incubated overnight at room temperature with primary antibody (at a dilution 1: 100) (mouse monoclonal antibody [Clone W27] raised against HSP-70 Ab2 [LabVision, Fremont, CA]).

The detection kit was the ultravision detection system anti-polyvalent horse radish peroxidase/diaminobenzidine (ready to use, Lab Vision, Fremont, CA).

#### **Interpretation of Hsp70 expression**

The presence of cytoplasmic stain with or without nuclear stain is required to assign the positivity for Hsp70.

- According to pattern of Hsp70 expression, cases were divided into those expressing cytoplasmic pattern and others expressing both cytoplasmic and nuclear pattern of expression.
- The intensity of HSP 70 was evaluated as mild (+), moderate (++), and strong (+++).
- The extent of HSP 70 was evaluated as percentage of its expression (mean, median, and range).

#### **Statistical analysis**

Data were collected, tabulated, and statistically analyzed using a personal computer with SPSS program version 11.  $\chi^2$  And Fisher exact tests were used in comparison between qualitative variables. Mann-Whitney U and Kruskal-Wallis (K) tests were used in comparison between quantitative variables. Spearman correlation coefficient (r) was used to assess correlation between 2

quantitative variants.  $P \leq .05$  was considered significant.

### **3. Results:**

#### **Immunohistochemical staining of Hsp70 in the control normal skin**

HSP70 was expressed in 27 cases (90.0%) with only 3 cases (10.0%) showed negative expression. The percentage of Hsp70 expression in control normal skin ranged from 0% to 100% with a mean  $\pm$  SD  $13.33 \pm 6.794$ . All control cases who expressed HSP 70 (100%) showed cytoplasmic pattern. The intensity of HSP 70 expression varied from mild in 24 cases (88.8%) to moderate in 3 cases (11.1%). (Table 1)

#### **Immunohistochemical staining of Hsp70 in the lesional vitiligo skin**

HSP70 was expressed in 30 patients (100%). The percentage of Hsp70 expression in vitiligo lesions ranged from 0% to 100% with a mean  $\pm$  SD  $70.17 \pm 17.448$ . Twenty patients (66.7%) showed nucleocytoplasmic pattern of HSP 70 while 10 patients (27.0%) showed cytoplasmic pattern. The intensity of HSP 70 expression varied from mild in 3 cases (10.0%), moderate in 16 cases (53.3%) to strong in 11 cases (19.0%). (Table 1)

#### **Immunohistochemical staining of Hsp70 in the perilesional skin in vitiligo**

HSP70 was expressed in 28 patients (93.33%) with only 2 patients (6.66%) showed negative expression. The percentage of Hsp70 expression in vitiligo lesions ranged from 0% to 100% with a mean  $\pm$  SD  $47.33 \pm 23.479$ . Sixteen patients (57.14%) showed cytoplasmic pattern of HSP 70 while 12 patients (42.85%) showed nucleocytoplasmic pattern. The intensity of HSP 70 expression varied from mild in 15 cases (53.571%), moderate in 7 cases (25.0%) to strong in 6 cases (21.428%). (Table 2). HSP70 was more diffuse in vitiligo skin compared with normal skin because The extent (percentage of expression) of HSP 70 was significantly higher in the lesional biopsies from vitiligo patients than in the control group (mean  $\pm$  SD:  $70.17 \pm 17.448$  vs  $13.33 \pm 6.794$ ),  $p < 0.01$ , and in non lesional biopsies than the normal control biopsies (mean  $\pm$  SD:  $47.33 \pm 23.479$  vs  $13.33 \pm 6.794$ ),  $p < 0.01$ . (Table 3)

Nucleocytoplasmic pattern was only seen in vitiligo cases (66.7% of lesional skin biopsies and 39.3% of perilesional skin biopsies) compared with control cases that were devoid of nuclear pattern (100% showed cytoplasmic pattern. (P value=0.000). Nucleocytoplasmic pattern of HSP 70 was significantly high in more severe form of the disease (P value <0.05). (Table 4)

**Table (1):** Immunohistochemical staining of Hsp70 in lesional skin in vitiligo and control normal skin

Parameters	Cases (n=30)		Control (n=30)		Test of significance	P value
	n	%	n	%		
<b>Expression</b>						
+ve	30	100.0%	27	90.0%	Fisher exact test	<i>P</i> =0.119
-ve	0	0.0%	3	10.0%		>0.05 NS
<b>Intensity</b>						
Mild	3	10.0%	24	88.8%	Pearson Chi- square test	<i>P</i> =0.000
Moderate	16	53.3%	3	11.1%		<0.01
Strong	11	19.0%	0	0.0%		HS
<b>Pattern</b>						
Nucleocytoplasmic	20	66.7%	0	0.0%	Fisher exact test	<i>P</i> =0.000
Cytoplasmic	10	27.0%	27	100.0%		<0.01 HS
<b>Percentage of expression</b>	70.0±17.448		13.33±6.794			
Mean±SD	30		10		Mann-Whitney <i>U</i>	<i>P</i> =0.000
Minimum	95		30			<0.01
Maximum Median	70.00		10.00			HS

HS=highly significant, NS=non significant

**Table (2):** Immunohistochemical staining of Hsp70 in the perilesional skin in vitiligo & control cases

Parameters	Cases (n=30)		Control (n=30)		Test of significance	P value
	n	%	n	%		
<b>Expression</b>						
+ve	28	93.3%	27	90.0%	Fisher exact test	<i>P</i> =0.2
-ve	2	6.6%	3	10.0%		>0.05 NS
<b>Intensity</b>						
Mild	15	53.5%	24	88.8%	Chi-square tests	<i>P</i> <0.01
Moderate	7	25.0%	3	11.1%		HS
Strong	6	21.4%	0	0.0%		
<b>Pattern</b>						
Nucleo-cytoplasmic	12	42.8%	0	0.0%	Fisher exact test	<i>P</i> =0.000
Cytoplasmic	16	57.1%	27	100.0%		<0.01 HS
<b>Percentage of expression</b>	47.33±23.479		13.33±6.794			
Mean±SD	20		10		Mann-Whitney <i>U</i>	<i>P</i> =0.000
Minimum	90		30			<0.01
Maximum Median	37.50		10.00			HS

HS=highly significant, NS=non significant

**Differences between vitiligo cases and controls as regards percentage of Hsp70 expression (*P*<0.001), intensity (*P*<0.001), pattern (*P*<0.001),**

There were significant differences between vitiligo cases and controls as regards percentage of Hsp70 expression (*P*<0.001), intensity (*P*<0.001), pattern (*P*<0.001),

**Table (3):** Mean values of the extent (percentage of expression) of HSP70 between vitiligo cases and control group

	Percentage of expression of HSP70 in lesional biopsies	Percentage of expression of HSP70 in perilesional biopsies	Percentage of expression of HSP70 in control biopsies	P-value
Mean ±SD	70.17±17.448	47.33±23.479	13.33±6.794	<i>p</i> <0.01

**Table (4):** Correlation of vitiligo disease activity with the pattern of HSP- 70 expression in skin biopsies from vitiligo patients

	Nucleocytoplasmic pattern		Cytoplasmic pattern		P value	
	Lesional	Perilesiona l	Lesional	Perilesiona l	lesiona l	perilesiona l
Vitilig o disease activity (VIDA score)	2.47±0.51 3	1.62±0.106	1.77±0.84 3	1.06±0.112	0.02	0.04

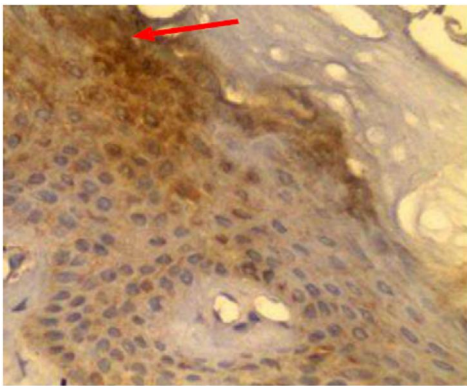
P value <0.05 (significant)

**Table (5):** Correlation between disease activity and intensity of HSP70 expression

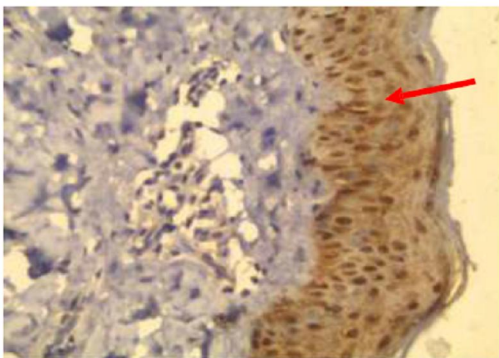
	Mild intensity Mean±SD	Moderate intensity Mean±SD	Strong intensity Mean±SD	P value
Disease activity (VIDA score)	1±0.000	2.38±0.619	2.6±0.516	0.010

The intensity of HSP70 expression is significantly high in the more active form of the disease. P value =0.010 **Table 5**

There was no significant correlation between HSP-70 expression (in both lesional and nonlesional skin biopsies) and the age, family history, vitiligo type and the pathological parameters (*Pvalue* > 0.05).



**Fig. 1** Perilesional skin biopsy of vitiligo patient (immunohistochemical stain, magnification ×400) showed moderate cytoplasmic expression of HSP70.



**Fig. 2** Lesional skin biopsy of vitiliginous patch (immunohistochemical stain, magnification ×200) showed strong nucleocytoplasmic expression of HSP70.

#### 4. Discussion

Vitiligo is a progressive depigmenting disorder due to loss of functional melanocytes from the epidermis [1], characterized by well defined, irregular shaped white macules or

Patches [2]. The etiology of vitiligo is not clear, but different theories are suggested such as autoimmune[8,9], genetic disorders [10,11], toxic metabolites, and oxidative stress theories [12,13,14].

Heat shock protein 70 are prime candidates to connect stress to the skin. Some studies have suggested that Hsp70 could play a role in the immunological mechanism leading to vitiligo through activation of lymphocytes and macrophages, activation and maturation of dendritic cells as an antigen presenting cells and initiating the release of cytokines, including tumor necrosis factor- $\alpha$ , interleukin (IL)-1 $\beta$ , IL-12, and IL-6 which are apoptosis mediators and melanocytes proliferation and melanogenesis inhibitor leading to vitiligo [15, 16].

This study aims to investigate the expression of Hsp70 in vitiliginous and normal skin by immunohistochemistry to declare its role in the pathogenesis and activity of vitiligo.

The results revealed that intense and diffuse expression of Hsp70 was in favor of lesional vitiligo skin compared to nonlesional skin biopsies from vitiligo patients and control cases. This data is inconsistent with *Doss et al. (2016)*, who found a significantly higher expression of HSP-70 mRNA in lesional skin biopsies from vitiligo patients compared to nonlesional skin biopsies from vitiligo patients and compared to skin biopsies from healthy controls using quantitative real-time polymerase chain reaction.

The expression of HSP70 is significantly high in the more active form of the disease. Similarly, our results are inconsistent with *Abdou et al. (2013)* who used immunohistochemistry to detect the expression of HSP-70 in the nuclei and cytoplasm of keratinocytes from the epidermis of vitiliginous



lesions and found that the expression of HSP70 was intensified and diffused with more prominent nuclear pattern in the active lesions.

Nucleocytoplasmic pattern was only seen in vitiligo cases (66.7% of lesional skin biopsies and 39.3% of perilesional skin biopsies) compared with control cases that were devoid of nuclear pattern and was significantly high in more severe form of the disease. These findings are in agreement with the study done by *Abdou et al. (2013)*, Who found that the nuclear pattern of HSP 70 may be blamed in pathogenesis of vitiligo because this pattern was completely absent in normal skin and started to appear in one perilesional biopsy and expressed in more than half of vitiliginous lesions. Furthermore, this pattern tended to be associated with increased progression of disease.

There was no significant correlation between HSP-70 expression (in both lesional and nonlesional skin biopsies) and the age, family history, vitiligo type and the pathological parameters ( $P > 0.05$ ). These findings are in agreement with *Abdou et al. (2013) and Doss et al. (2016)* studies which proved that the expression of HSP70 was not affected by gender, age, family history, vitiligo type or pathologic parameters.

### Conclusion

Heat Shock Protein70, in the form of its intense and diffuse expression, may play a role in pathogenesis of vitiligo. Nuclear localization of HSP 70 may be related to progression of the disease.

### References

- 1- Ezzedine K, Eleftheriadou V, Whitton M, van Geel N: Vitiligo. *Lancet* 2015;4:386(9988):74–84.
- 2-Ezzedine K and Silverberg N: A Practical Approach to the Diagnosis and Treatment of Vitiligo in Children. *Pediatrics* 2016;138(1).
- 3- Yuhui Z, Yunfei C, Meihui S et al.: The Prevalence of Vitiligo: A Meta-Analysis. *PLOS One* 2016; 11(9): e0163806.
- 4-Sottile ML and Nadin SB: Heat shock proteins and DNA repair mechanisms: an updated overview. *Cell Stress and Chaperones* 2018; 23(3): 303-15.
- 5- Jacquemin C, Rambert J, Guillet S, Ezzedine K et al : Heat shock protein 70 potentiates interferon alpha production by plasmacytoid

- dendritic cells: relevance for cutaneous lupus and vitiligo pathogenesis. *British Journal of dermatology* 2017;177(5): 1367-1375.
- 6- Shevtsov I and Multhoff G: Heat Shock Protein–Peptide and HSP-Based immunotherapies for the Treatment of Cancer. *Front Immunol* 2016; 29(7):171
- 7- Bhor U and Pande S : Scoring systems in dermatology. *Indian J Dermatol Venereol Lepro* 2006; 72 (4): 315-321.
- 8-Kaur M, Bagga P, Kaur T and Kataria A: *Evaluation of Histologically and Histochemically Proven Cases of Vitiligo and its Correlation with CD4+ and CD8+ Lymphocyte Counts using Flow Cytometry.* *J Clin Diagn Res* 2017; 11(5): 9–12.
- 9-Rodrigues M, Ezzedine K, Hamzavi I, Pandya A and Harris J: New discoveries in the pathogenesis and classification of vitiligo. *J Am Acad Dermatol* 2017; 77(1): 1-13.
- 10- Spritz R and Andersen G : Genetics of Vitiligo. *Dermatol Clin* 2017;35(2):245-255.
- 11-Birlea S, Jin Y, Bennett D et al.: Comprehensive association analysis of candidate genes for generalized vitiligo supports XBP1, FOXP3, and TSLP. *J Invest Dermat* 2011; 131(2): 371-81.
- 12-Speeckaert R, Dugardin J, Lambert J, Verhaeghe E, Marijn Speeckaert M and van Geel N: Critical appraisal of the oxidative stress pathway in vitiligo : a systematic review and meta-analysis. *Journal of the European Academy of Dermatology and Venereology* 2018;32(7):1089-1098.
- 13-Pande S and Gupta M: Study of oxidative stress in vitiligo. *Panacea Journal of Medical Sciences* 2017; 7(2): 89-91.
- 14- Al Dhubaibi M, Mohammed G and Gomaa A: Highlights in pathogenesis of vitiligo. *Word J Clin Cases* 2015; 3(3): 221–230.
- 15- Doss R, El-Rifaie A, Abdel-Wahab A, Gohary Y and Rashed L: Heat Shock Protein-70 Expression in Vitiligo and its Relation to the Disease Activity. *Indian J Dermatol* 2016 ; 61(4): 408– 412.
- 16- Abdou A, Maraee A and Reyad W (2013): Immuno- histochemical expression of heat shock protein 70 in vitiligo. *Annals of Diagnostic Pathology*; 17(3): 245-9.

9/30/2018