

## Protective Effect of Vitamin E on Colchicine Affected Testes of Adult Albino Rats

Gamal Sayed Ahmad Desouky M.D, Ashraf Abd El-Rahman Mohamed M.D, Sobhy Hassan Ewis M.D and ELSayed ELSayed Hamed Jahin M.S.c.

Human Anatomy and Embryology, Faculty of Medicine, AL-Azhar University, Egypt.

[ah\\_agaba@yahoo.com](mailto:ah_agaba@yahoo.com)

**Abstract: Introduction:** The harmful effects of colchicine on male fertility have been reported in experimental and clinical studies. However, the protective effect of vitamin E against this toxicity and the reversibility of colchicine induced testicular toxicity after its withdrawal is still a matter of controversy. **Aim of the Work:** to examine the effect of nicotine administration on albino rat testis and to study the potential role of nicotine withdrawal and vitamin E on the amelioration of the nicotine effect on the testis. **Material and Methods:** Twenty adult male Wister albino rats of 8-10 weeks and weighting 200-250 gm were used. The animals were obtained from the animal house, Faculty of Medicine, Cairo University. All experiments were carried out according to the guidelines of the Institutional Animal Ethics Committee. The outcome of this study shows that the toxic effect of colchicine was improved and concomitant administration vitamin E, so, it is advisable to give vit E as early as possible for avoiding damage of the testicular tissue.

[Gamal Sayed Ahmad Desouky, Ashraf Abd El-Rahman Mohamed, Sobhy Hassan Ewis and ELSayed ELSayed Hamed Jahin. **Protective Effect of Vitamin E on Colchicine Affected Testes of Adult Albino Rats.** *Nat Sci* 2018;16(7):52-58]. ISSN 1545-0740 (print); ISSN 2375-7167 (online). <http://www.sciencepub.net/nature>. 9. doi:[10.7537/marsnj160718.09](https://doi.org/10.7537/marsnj160718.09).

**Key Words:** Colchicine, Vitamin E, Testis.

### 1. Introduction

Colchicine is a natural alkaloid with weak anti-inflammatory activity. It has been used extensively for gout treatment from centuries and also been recommended in preventing attacks of familial Mediterranean fever, treatment of primary biliary cirrhosis; amyloidosis and condyloma acuminata (*Güven et al., 2002*).

It is an anti-mitotic agent and can be either cytotoxic or protective against cytotoxicity, but it has a direct toxicity on cells of skeletal muscle. Colchicine has been reported to protect against a variety of hepatotoxic insults and improve survival in a clinical trial for The testis is the primary sex organ of the male genital system. It is a compound tubular mixed gland, performing both endocrine and exocrine function. It is formed mainly of stroma and parenchyma alcoholic cirrhosis (*Maxwell et al., 2002*).

Although colchicine's medicinal properties have been recognized for centuries, the drug was first approved in 2009, under the United States Food and Drug Administration (FDA) (*Research C for DE. Accessed May 28, 2014*). FDA approval brought changes in colchicine dosing regimens, and a greater emphasis on safety in the context of co-morbidities and drug-drug interactions. Even before FDA approval, investigations had begun to widen colchicine's range of clinical use, from gout and familial Mediterranean fever to a variety of rheumatologic and cardiovascular applications.

The testis is the primary sex organ of the male genital system. It is a compound tubular mixed gland, performing both endocrine and exocrine function. It is formed mainly of stroma and parenchyma.

According to Hess et al. (1993), sperm morphogenesis is a complex process. Germ and Sertoli cells contain numerous microtubules which are essential for normal morphogenetic processes of spermatogenesis. Colchicine interacts with microtubules inducing sperm structural abnormalities.

Natural antioxidants as polyphenols of vitamin E have received much attention for the treatment of oxidative-stress-related pathological conditions (*Yokozawa et al., 2004*).

Vitamin E is a natural antioxidant its ameliorating effect on genital organs was reported by (*Ogura et al., 2008*). Vitamin E's main function in the body is to work as an antioxidant, scavenging loose electrons —so-called “free radicals”— that can damage cells. Antioxidants, including vitamin E, came to public attention in the 1980s, when scientists began to understand that free radical damage was involved in the early stages of artery-clogging atherosclerosis, and might also contribute to cancer, vision loss, and a host of other chronic conditions. Studies since then have dimmed some of the promise of using high dose vitamin E to prevent chronic diseases.

### 2. Material and Methods

#### Animal Used:

Twenty adult male Wister albino rats of 8-10

weeks and weighting 200-250 gm were used. The animals were obtained from the animal house, Faculty of Medicine, Cairo University. They were housed in spacious wire mesh cages in a well-ventilated room, and were kept under a constant day/night cycle in a climate controlled condition with free access to food and water. All experiments were carried out according to the guidelines of the Institutional Animal Ethics Committee.

#### Chemicals:

The chemicals in this experiment were colchicine and vitamin E. Colchicine was supplied as a white tablets containing 500 mcg colchicine, colchicine is an alkaloid isolated from *colchicum autumnale*. Vitamin E extract was supplied as a 100 ml solution containing 1 gm vitamin E was obtained from Faculty of Pharmacy, AL-Azhar University, Egypt.

#### Experimental Design:

After two weeks of acclimatization, the rats were randomly divided into control and experimental groups:

##### 1- The control group (Group I):

- Formed of 4 rats.
- They received 1 ml 0.9 % sodium chloride (NaCl) intraperitoneal (IP) daily throughout the duration of the study.

##### 2- The experimental groups:

- Formed of 16 rats.
- They further subdivided into the following subgroups:

**Group II (Colchicine toxicity):** Animals injected (IP) with colchicine 2mg/kg/day for 2 months and scarified at day 59.

**Group III (Protection group):** Animals injected (IP) with colchicine 2mg/kg/day with vitamin E from the start for 2 months.

**Group IV (Curative group):** Animals injected IP with colchicine 2mg/kg/day for one month then vitamin E 100 mg/kg/day for another one month.

**Group V:** Animals injected IP with colchicine 2mg/kg/day for one month then another one month free.

#### Specimens collection:

At the assigned times, the rats were anaesthetized using ether inhalation, and blood samples were obtained by direct eye puncture for serum testosterone measurement. Then the testes were dissected out, preserved in 10% buffered formalin and then processed for paraffin sections.

#### Processing of the specimens for light microscopic examination:

The specimens were processed for paraffin sections by gradual dehydration using ascending graded concentrations of alcohol, cleared in xylene and embedded in soft and then in hard paraffin wax.

Transverse sections were cut at 5-6  $\mu$ m and

treated as follows:

Some sections were stained with Hematoxylin and Eosin (H & E) for evaluation of histopathological changes.

Other sections were stained with AgNOR for detection of mitotic activity.

#### Testosterone level assessment:

At the end of the experiment serum testosterone was measured in Tabarak Laboratory, Cairo, Egypt for all groups by VIDAS Testosterone. It is an automated quantitative test for use on the instruments of VIDAS family for the enzyme immunoassay measure of total testosterone in serum or plasma, using the ELFA technique (Enzyme Linked Fluorescent Assay). It is intended in the diagnosis and management of conditions involving excess or deficiency of this androgen.

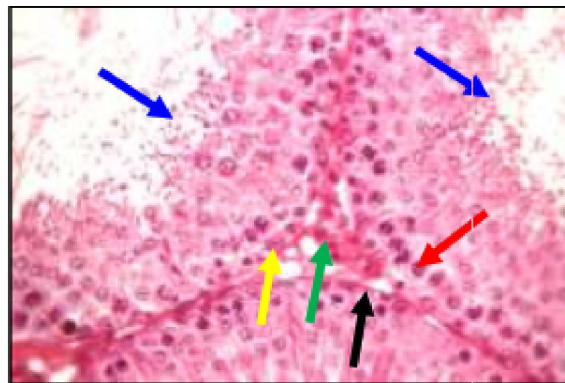
### 3. Results

#### Histological results:

##### I. Hematoxylin and Eosin stained sections

##### 1. Control group:

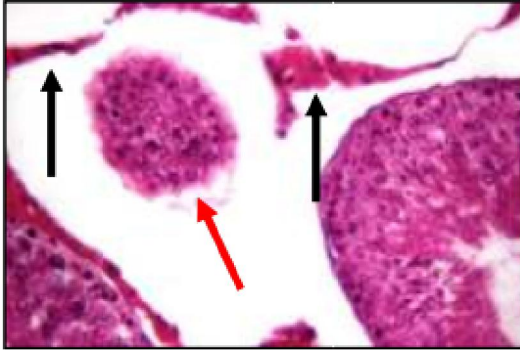
The testicular tissue of adult albino rat of control group showed well circumscribed circular seminiferous tubules separated by interstitial tissues. The seminiferous tubules were lined by 5 -10 rows of stratified epithelium composed of two categories of cells, spermatogenic cells and Sertoli cells resting on a clear basement membrane, average sized tubules with complete spermatogenesis with average interstitium. The section of the testis showing seminiferous tubules with average BM, Sertoli cell, average germinal lining with primary spermatocytes, many spermatozoa, and average interstitium showing Leydig cells (Fig. 1).



**Fig. 1:** A photomicrograph of a section of the testis of control adult albino rat showing seminiferous tubules with average BM (black arrow), Sertoli cell (yellow arrow), average germinal lining with primary spermatocytes (red arrow), many spermatozoa (blue arrows), and average interstitium showing Leydig cells (green arrow). (H & E X 400)

## 2. Colchicine treated group for two month:

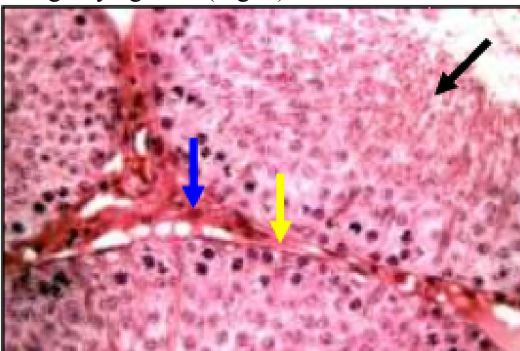
The testicular tissue of adult albino rat colchicine treated group showed widely-spaced small-sized and distorted tubules, with marked sub capsular edema. The testicular tissue showing widely-spaced distorted tubule, and other tubules showing full spermatogenesis with marked interstitial edema. The testicular tissue showing seminiferous tubule with thick disrupted basement membrane, with marked interstitial edema. The testicular tissue showing widely-spaced markedly distorted tubule, with shredded interstitial tissue (Fig. 2).



**Fig. 2:** A photomicrograph of a section of the testis of adult rat treated with colchicine for 2 months (toxic dose of colchicine) another view of previous slide showing widely-spaced markedly distorted tubule (red arrow), with shredded interstitial tissue (black arrows). (H & E X 400)

## 3. Protection group which received colchicine and vitamin E from the start for 2 months:

The testicular tissue showing mildly-separated average sized tubules with average lining, with mild/moderate interstitial and sub-capsular edema. Also, testicular tissue showing average sized tubules with average lining and full spermatogenesis with mild/moderate interstitial edema showing shredded interstitial tissue. The testicular tissue showing average basement membrane with average interstitium showing Leydig cells (Fig. 3).



**Fig. 3:** A photomicrograph of a section of the testis of adult rat treated with colchicine with vitamin E from the start for 2 months with high power view of

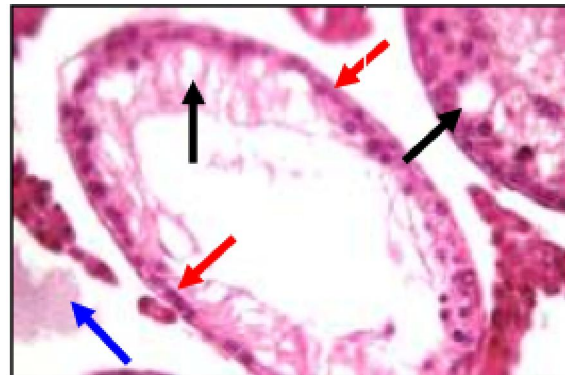
previous slide showing seminiferous tubules with average lining and full spermatogenesis (black arrows), average basement membrane (yellow arrow) with average interstitium showing Leydig cells (blue arrow). (H & E X 400)

## 4. Curative group which received colchicine for one month then vitamin E for another one month:

Testicular tissue showing widely-spaced small-sized and markedly distorted tubules, with marked interstitial and sub capsular edema. Higher power view of previous slide showing distorted seminiferous tubule with thin epithelial lining, marked cystic degeneration and thick basement membrane, with marked interstitial edema showing shredded interstitial tissue (Fig. 4).

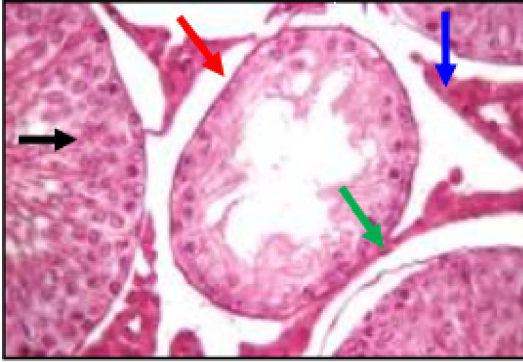
## 5. Group V which received colchicine for one month then another one month free:

The testicular tissue showing mildly-separated average sized tubules with average lining, another small-sized empty tubules with mild interstitial edema. The testicular tissue showing of seminiferous tubules with average lining, another tubule showing thick irregular basement membrane (red arrow) with mild cystic degeneration (green arrow), and mild interstitial edema. The testicular tissue showing seminiferous tubules with average lining, another small-sized tubule showing thin epithelial lining with thick irregular separated basement membrane, and mild interstitial edema with prominent interstitial tissue (Fig. 5).



**Fig. 4:** A photomicrograph of a section of the testis of adult rat treated with colchicin for one month then vitamin E for another monthanother view of previous slide showing seminiferous tubule with thin epithelial lining (red arrows), marked cystic degeneration (black arrows), with marked interstitial edema showing shredded interstitial tissue (blue arrow). (H & E X 400)





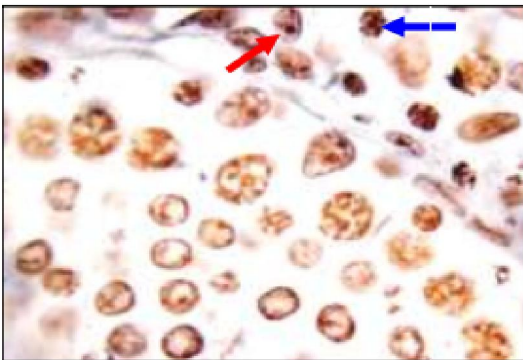
**Fig. 5:** A photomicrograph of a section of the testis of adult rat treated with colchicine for one month then another one month free another view of previous slide showing seminiferous tubules with average lining (black arrow), another small-sized tubule showing thin epithelial lining (red arrow) with thick irregular separated basement membrane (green arrow), and mild interstitial edema (blue arrow). (H & E X 400)

## II. AgNOR stained sections:

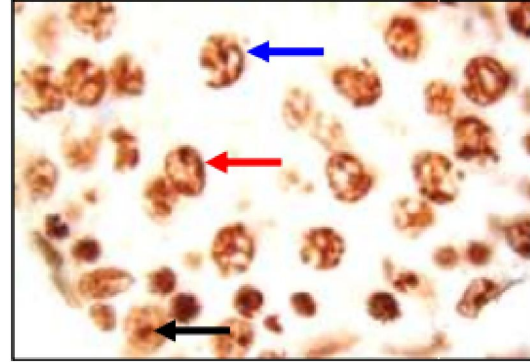
The NORs appeared as well-defined black dots within the orange colored nuclear background. AgNOR dots were located strictly within the nuclei of the spermatocytes. They were visible as faint black dots in nuclei of control group (Fig. 6).

The least number of AgNOR dots was present in colchicine treated group for one month then another one month free indicating mitotic arrest and decreased cell proliferation (Fig. 10).

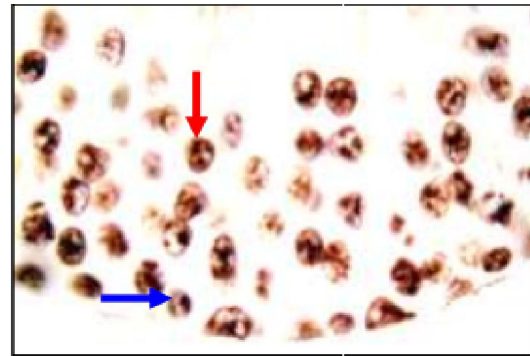
The largest number of AgNOR dots was present in colchicine treated group with vitamin E from the start for 2 months (Fig. 8). Also, AgNOR dots were clearly visible as black dots in colchicine and vitamin E treated with variable number more than that of colchicine treated group indicating better cellular proliferation (Figs. 7 & 9).



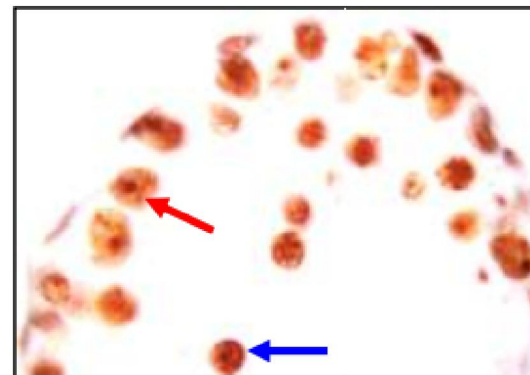
**Fig. 6:** A photomicrograph of a section of the testis of adult albino rat showing 2 dots/nucleus (red arrow), and another one showing 7 dots/nucleus (blue arrow). (AgNOR stain X 1000)



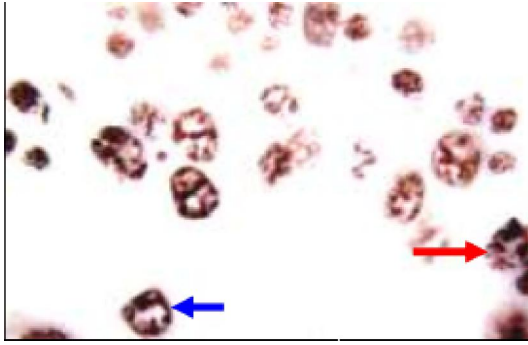
**Fig. 7:** A photomicrograph of a section of the testis of adult albino rat treated with colchicine for 2 months (toxic dose of colchicine) most of germinal cells showing 3 dot/nucleus (red arrow), other one showing 7 dots/nucleus (blue arrow), and few showing 1 dot/nucleus (black arrow). (AgNOR stain X 1000)



**Fig. 8:** A photomicrograph of a section of the testis of adult rat treated with colchicine with vitamin E from the start for 2 months showing 3 dots/nucleus (red arrow), other one showing 1 dot/nucleus (blue arrow). (AgNOR stain X 1000)



**Fig. 9:** A photomicrograph of a section of the testis of adult rat treated with colchicine for one month then vitamin E for another one month showing germinal cells showing 1 dot/nucleus (red arrow), other one showing 4 dots/nucleus (blue arrow). (AgNOR stain X 1000)



**Fig. 10:** A photomicrograph of a section of the testis of adult rat treated with colchicine for one month then another one month fresh showing 4 dots/nucleus (red arrow), other one showing 5 dots/nucleus (blue arrow) (AgNOR stain X 1000).

#### 4. Discussion

Colchicine administration induces changes in gonadal functional cycles over the sperm affected cells after the present work aimed to study the more closely effect of this widely used substance either under medical supervision or not in order to put the bases for the best way of use of this drug either to avoid many hazards that may develop due to uncontrolled use of this substance.

The adult albino rat was used in this study due to its similarity to testicular architecture of human, the onset of puberty is around the age of 7- 9 weeks and when the average weight is about 200 gm (*Hansel & Convey, 1983*).

Vitamin E was used due to its ability to reduce oxidative stress induced by toxic substances such as nicotine.

The literature is repleted by studies on clinical and biochemical effects of the drug on the male reproductive system. However, there is a paucity of information about the effect of the drug on the histological structure on the testis.

In the present study the specimens were stained by Haematoxylin & Eosin and AgNOR stain for histological study. Haematoxylin and Eosin stain is the best stain that can demonstrate the acidophilic and basophilic components of the cell, and AgNOR was used to demonstrate mitotic activity and cellular proliferation.

All animals were kept in animal house under the same environmental condition and were allowed to move freely in their cages. The rats were fed on daily diet composed of milk powder, bread and vegetables.

In the present work, the animals exposed to some general signs of ill-health including loss of appetite (anorexia), diminished movement (lethargy), recurrent attacks of diarrhea, vomiting and reduction of weight, all these signs appeared in the colchicine treated group only.

The testicular tissue of the colchicine treated rats

showing widely-spaced small-sized and distorted tubules, with marked sub capsular edema, some tubules show decrease in spermatogenesis and other tubules showing full spermatogenesis, with marked interstitial edema, seminiferous tubule with thick disrupted basement membrane.

The less affected tubules showed thickening of their basement membrane with some degenerated and abnormal cells with low number of spermatozoa in the center of tubules. The other tubules however appeared with normal architecture, and the spermatogenic and Sertoli cells appeared more or less normal in these tubules.

The interstitial cells of Leydig appeared few in number and atrophied if compared with the control group. The primary spermatocytes of the treated group showed marked nuclear changes where its nuclear membrane is ill-defined and disrupted. The primary spermatids and spermatozoa appeared more or less deformed.

AgNOR reactive dots could be demonstrated in the nuclei of colchicine treated animals showed decreased number when compared with control group, which indicates arrest of their mitotic activity.

In the present study, the testes of the treated group showed at the higher doses, most seminiferous tubules were atrophic or had undergone mineralization, although some seminiferous tubules were partially populated. These results are in agreement with (*Allard et al., 1993*). There was no change in testis weight in small dose but there was a dose-related decrease in testis weight.

These results are in agreement with (*Tepperberg et al., 1999*) Colchicine-induced loss of the more heavily damaged cells from the seminiferous tubule, Colchicine was shown to disrupt the microtubular framework of the Sertoli cells, causing these cells to change shape. At the same time, abnormal separation of Sertoli cells from the attached syncytial germinal cells was observed Detached Sertoli cells and germ cells are cast off into the lumen of the seminiferous tubule in agreement with (*Tepperberg et al., 1997*)

High dose of colchicine occurs concurrently with the disturbance of the microtubules network of Sertoli cell similar to the result from study in (*Correa et al., 2002; ALLARD ET AL., 1993; Russel et al., 1981*).

Also, our results were in agreement with the results obtained by (*ALLARD et al., 1993*) who observed a decrease in seminiferous tubule diameter in rats exposed to colchicine which can be considered as the cause of the reported decrease testosterone level.

The basement membrane of all seminiferous tubules of the present study appeared thickened. Our results were in agreement with (*Nelson and Patanelli, 1998*). They reported similar results and explained

these changes due to the increased number of the abnormal and degenerated cells in man and rat testes as a result of systemic toxicity of the drug. Another suggestion by the same authors was that alteration in the basement membrane structure and / or function could lead to blockage of free flow of nutrients across the barrier, thus adversely affecting the germinal cells.

The interstitial cells of Leydig appeared few in number and atrophied if compared with the control group. Our results were in agreement with the results obtained by *(Kim et al., 2005)* who showed that destruction of Leydig cells cause testicular atrophy, gonadal dysfunction, erectile dysfunction and male infertility.

The testosterone hormone level in this study is markedly decreased. This can be due to affection of the interstitial cells of Leydig in addition to impairment of the hypothalamic-pituitary-testicular axis. Our results were in agreement with the results obtained by *(Oyeyemi et al., 2015; Oyeyipo, 2010; Kavitharaj and Vijayammal, 1999)* who reported that serum level of testosterone was significantly decreased in a dose dependent manner when compared with those of the control rats. In disagreement with the results obtained by *(Wang et al., 2000; Mittler et al., 1983)* who have reported that decrease in testosterone level as attributed to increased activity of hydroxylase, an enzyme known to increase testosterone level metabolism.

In this study giving colchicine with vit E results in improvement of the testicular histology in the form of complete spermatogenesis with normal spermatogonia, primary spermatocytes, spermatids and spermatozoa in addition to prominent improvement of serum testosterone level. This is in agreement with *(Oyeyipo, 2010)* who reported that there were both regeneration of the germinal epithelium and restructuring of the interstitium towards normal in the recovery groups. The results suggest that colchicine has deleterious effect on the male reproductive organ of albino rats.

Our study demonstrated that vitamin E results in improvement of the testicular histology in the form of complete spermatogenesis with normal spermatogonia, primary spermatocytes, spermatids and spermatozoa in addition to prominent improvement of serum testosterone level. This is in agreement with *(Kuladip et al., 2016; Oyeyemi et al., 2015)*.

The beneficial effect of vitamin E is mostly due to its antioxidant potentials. It is a lipid soluble antioxidant which plays a major protective role against oxidative stress and prevents the of lipid peroxides. Moreover, it is essential in maintaining the physiological integrity of testes, epididymis and accessory glands *(Cerolini et al., 2006)*, which has vital role in spermatogenesis and sperm maturation

consequently improving sperm quality and quantity. Also, significant increase in serum testosterone *(Oyeyemi et al., 2015)*.

In agreement with *(Oyeyemi et al., 2015)* vitamin E improved the reduction in sperm characteristics, hormone levels and testicular alterations. The study shows that colchicine exerts significant deleterious effects on male reproductive system and the concurrent administration of vitamin E ameliorated these detrimental effects.

Vitamin E is the most effective chain-breaking, lipid soluble antioxidant present in cell membranes and it is considered likely that it plays a major role in maintaining cell membrane integrity *(Latchoumycandaneand Mathur, 2002)*.

In the present study the combined treatment of colchicine and vitamin E caused increase in the testosterone level and improvement of the histological and immunohistochemical changes in the testicular tissue. This was almost, also, observed in animals groups which treated with Vit E and colchicine.

The ameliorating effect of vitamin E noticed in the present study may be attributed to its antioxidant properties as reported by *(Patra et al., 2008)*.

Natural antioxidants as polyphenols of vitamin E have received much attention for treatment of oxidative-stress-related pathological conditions *(Yokozawa et al., 2004)*.

*(Ogura et al., 2008)* reported that vitamin E is a rich source of polyphenols, which are antioxidants having an ameliorating effect in genital organs. *Hakim et al. (2003)* suggested that the ameliorating effect of vitamin E on Leydig cells was due to its antioxidant activity.

Our study show agreement with several studies have shown that vitamin E reduce the oxidative stress induced by toxic substances in the testis *(Luck, 1995; Raji et al., 2003; Krishnamoorthy et al., 2007; Kutlubay et al., 2007)*.

## 5. Conclusion

The outcome of this study shows that the toxic effect of colchicine was improved and concomitant administration vitamin E, so, it is advisable to give vit E as early as possible for avoiding damage of the testicular tissue.

## References

1. Akim, I. A., Harris, R. B., Brown, P. S., Chow, H. H. and Wiseman, S. D., (2003): Effect of increased vitamin E consumption on oxidative DNA damage among smokers: a randomized controlled study. *J Nutr* 133: pp. 3303S-3309S.
2. Allard E. K., Johnson K. J. and Boekelheide K. (1993): Colchicine Disrupts the Cytoskeleton of Rat Testis Seminiferous Epithelium in a Stage-



- Dependent Manner. *Biology of Reproduction*, 48: 143-153.
3. Cerolini, S., Zaniboni, I., Maldjian, A. and Gliozzi, T. (2006): Effect of docosahexanoic acid and  $\alpha$ -tocopherol enrichment in chicken sperm on semen quality, sperm lipid composition and susceptibility to peroxidation. *Theriogenology*, 66: 877-886.
  4. Guven AG, Bahat E, Akman S and Atran, EM Late diagnosis of severe colchicine intoxication. *Pediatrics*, (2002), 109 (5):971-3.
  5. Hess, R. A. Cooke, P, S. Bunick, D, I. Kirby, J, D. (1993): Adult testicular enlargement induced by neonatal hypothyroidism is accompanied by increases Sertoil and germ cell number. *Endocrinology*, 132(6):2607-2613.
  6. Kavitharaj, N. K. and Vijayammal, P. L., (1999): Nicotine administration induced changes in the gonadal functions in malerats. *Pharmacology*, 58: pp. 2-7.
  7. Kim, I. S., Ariyaratne, H. B. and Mendis, S. M., (2005): Changes in the Testis Interstitium of Brown Norway Ratswith Aging and Effects of nicotine on the Aged Testes in Enhancing the Steroidogenic Potential. *Biol Reprod.*, 66(5); pp. 1359- 1366.
  8. Krishnamoorthy, G., Venkataraman, P., Arunkumar, A., Vignesh, R. C., Aruldas, M. M. and Arunakaran, J. (2007). Ameliorative effect of vitamins (alphatocopherol and ascorbic acid) on PCB (Aroclor 1254) induced oxidative stress in rat epididymal sperm. *Reproductive Toxicology*, 23: 239-245.
  9. Kuladip, J. D., Prabhat, K. S. and Dipak, K. D., (2016): Nicotine Diminishes Testicular Gametogenesis, Steroidogenesis, and Steroidogenic activity in Adult Albino Rats. West Bengal University of Animal and Fishery Sciences.
  10. Kutlubay, R., Oguz, E. O., Can, B., Guven, M. C., Sinik, Z. and Tuncay, O. L. (2007). Vitamin E protection from testicular damage caused by intraperitoneal aluminium. *International Journal of Toxicology*. 26: 297-306.
  11. Latchoumycandane, C. and Mathur P. P. (2002); Effects of Vitamin E on Reactive Oxygen Species-mediated 2,3,7,8 Tetrachlorodibenzo-p-dioxin Toxicity in Rat Testis. *Journal of Applied Toxicology*, 22: 345-351.
  12. Luck, M. R., Jeyaseelan, I. and Scholes, R. A. (1995); Ascorbic acid and fertility. *Biology of Reproduction*, 52: 262-266.
  13. Maxwell MJ, Muth P and Priiy PE. Accidental colchicine overdose. A case report and literature colchicine overdose. A case report and literature review. *Emerg., Med., J.* (2002): 19(3). pp: 265-267.
  14. Mittler, J. C., Pogach, G. L. and Ertel, N. K., (1983): Effects of chronic smoking on testosterone metabolism in dogs. *Journal of Steroid Biochemistry*, 18; pp. 759-763.
  15. Ogura, R. A., Ikeda N. L., Yuki, K. D., Morita, R. O., Saiga, K. S., Blackstock, C. B. and Kasamatsu, J. T., (2008): Genotoxicity studies on nicotine *Chemical Toxicology*; 46; pp. 2190-2200.
  16. Oyeyemi, W. A., Shittu, S. T., Kolawole, T. A. and Akinola, A. O., (2015): Protective Effect of Vitamin E on Nicotine Induced Reproductive Toxicity in Male Rats. Igbinedion University. Available from: 23(1); pp. 7-13 [ 5 june 2015].
  17. Oyeyipo, I. P., Raji, A. Y., Emikpe, B. O. adn Bolarinwa, A. F., (2010): Effects of Oral Administration of Nicotine on Organ Weight, Serum Testosterone Level and Testicular Histology in Male Rats. *Nig. J. Physiol. Sci.* 25(10); pp. 81-86.
  18. Patra, S. K., Rizzi, F. L., Silva, A. M., Rugina, D. O. and Bettuzzi, S. H., (2008): Molecular Targets of Epigallocatechin-3-gallate (EGCG): Specificity and interaction with memberane lipid rafts. *J Physiol Pharmacol.*, 59; pp. 217-235.
  19. Raji, Y., Udoh, U.S., Mewoyeka, O. O., Ononye, F. C. and Bolarinwa, A. F. (2003). Implication of reproductive endocrine malfunction in male antifertility efficacy of *Azadirachta indica* extract in rats. *African Journal of Medical Sciences*, 32: 159-165.
  20. Tepperberg J. H., Moses M. J. and Nath J. (1997); Colchicine effects on meiosis in the male mouse I. Meiotic prophase: synaptic arrest, univalents, loss of damaged spermatocytes and a possible checkpoint at pachytene. *Chromosoma*, 106:183-192.
  21. Tepperberg J. H., Moses M. J. and Nath J. (1999): Colchicine effects on meiosis in the male mouse II. Inhibition of synapsis and induction of nondisjunction, *Mutation Research*, 429: 93-105.
  22. Wang, H, L. Li, D, Y. Cho, C, U. (2000): Exposure to cigarette smoke increases apoptosis in the rat gastric mucosa through a reactive oxygen spices-mediated and p53-independent pathway. *Free Radic. Biol, Med.*, 28(7)1125-1131.
  23. Yokozawa, Y. T., Rhyu, D. Y. and Cho, E. J., (2004): Epigallocatechin-3-O-gallate ameliorates the damages related to peroxynitrite production by mechanism distinct from those of other free radical inhibitors. *J. Pharma Pharmacol.*, 56; pp.