

Comparative Study between Microperimetry and Optical Coherence Tomography Angiography Before and After Intravitreal Injection of Aflibercept in Wet Age Related Macular Degeneration

Prof. Dr. Ahmed Salah Abdel Rehim, Dr. Ahmad Elsayed Hudieb, and Ahmed Mohamed Nashaat Ali Rady

Ophthalmolog Department, Faculty of Medicine, Al-Azhar University, Egypt
dr_ahmed_nashaat@hotmail.com

Abstract: Age-related Macular Degeneration (AMD) is a progressive, degenerative disease of the macula and it is the leading cause of irreversible loss of visual acuity in patients over the age of 50 years. OCTA can detect changes in choroidal blood vessel flow and can elucidate the presence of choroidal neovascularization and structural changes in AMD. Microperimetry has allowed highly precise measurements of the functional retinal sensitivity and considering a measure of progression, of the pathological changes in AMD. This study is to assess and compare functional and structural retinal changes in patients with neovascular age-related macular degeneration (AMD) treated with 2mg/0.1ml intravitreal aflibercept three times with an interval of one month each.

[Ahmed Salah Abdel Rehim, Ahmad Elsayed Hudieb, and Ahmed Mohamed Nashaat Ali Rady. **Comparative Study between Microperimetry and Optical Coherence Tomography Angiography Before and After Intravitreal Injection of Aflibercept in Wet Age Related Macular Degeneration.** *Nat Sci* 2018;16(7):34-43]. ISSN 1545-0740 (print); ISSN 2375-7167 (online). <http://www.sciencepub.net/nature>. 7. doi:[10.7537/marsnsj160718.07](https://doi.org/10.7537/marsnsj160718.07).

Keywords: Comparative; Optical Coherence Tomography Angiography (OCTA); Microperimetry; Aflibercept; Wet Age Related Macular Degeneration.

1. Introduction

Age-related Macular Degeneration (AMD) is the leading cause of irreversible vision loss among individuals aged 50 or older in developed countries. It can be classified into two types: dry (atrophic) AMD and wet (exudative) AMD **1**.

Advanced wet AMD is characterized by choroidal neovascularization (CNV), the leakage of new blood vessels can cause edema and disorders in retinal architecture eventually causing blurred and distorted vision. If left untreated, the area of neovascularization can expand rapidly leading to the development of fibrous scarring. Recent studies show that within 3 years of onset of neovascularization, about 75% of untreated patients will present a visual acuity of 20/200 or worse **2**.

Several risk factors for AMD have been identified, such as advanced age, genetic predisposition, and history of cataract surgery, smoking history and diabetes **3**.

Vascular Endothelial growth factor-A (VEGF-A) has been implicated to play a major role in the pathogenesis of the wet AMD **4**.

VEGF-A and placental growth factor (PGF) are members of the VEGF family of angiogenic factors which may act as potent mitotic factors, vascular permeability and chemotactic for endothelial cells **5**.

Since VEGF plays an important role in the pathogenesis of the choroidal neovascular membrane (CNVM), the treatment for exudative AMD has been revolutionized with intravitreal anti-VEGF therapy: Ranibizumab, Bevacizumab and Aflibercept **5**.

Aflibercept is a fusion protein with binding domains from native VEGF receptors, binds VEGF-A, VEGF-B, and placental growth factors 1 and 2 with high affinity. Ophthalmologic studies demonstrated that aflibercept suppresses choroidal neovascularization in patients with exudative age-related macular degeneration with excellent visual outcomes **6**.

The introduction of intravitreal anti-vascular endothelial Growth factor (VEGF) blockade for neovascular age-related macular degeneration (AMD) in the last decade has had a significant beneficial impact on patients with neovascular AMD **7**.

Retinal sensitivity determined on fundus-tracked perimetry commonly referred to as “microperimetry” has been recently used as such a measure, and has been shown to be effective at detecting functional deficits in the early stages of AMD **8**.

The real-time compensation of eye movements achieved through visualization of the fundus with microperimetry has allowed highly precise measurements of retinal sensitivity at individual retinal regions sampled. This feature is crucial when considering a measure of progression, as pathological changes in AMD frequently occur in localized regions **9**.

Published studies hint at the optical coherence tomography angiography (OCTA) potential efficacy in the evaluation of common ophthalmologic diseases such as age related macular degeneration (AMD), diabetic retinopathy, artery and vein occlusions, and glaucoma **10**.

OCTA can detect changes in choroidal blood vessel flow and can elucidate the presence of choroidal neovascularization (CNV) in a variety of conditions but especially in AMD. It provides a highly detailed view of the retinal vasculature, which allows for accurate delineation of the foveal avascular zone (FAZ) *10*.

Further studies are needed to more definitively determine OCTA's utility in the clinical setting and to establish if this technology may offer a non-invasive option of visualizing the retinal vasculature in detail *10*.

2. Patient and Methods

The present study will be conducted on twenty (20) eyes.

1- Pre-operative evaluation:

- 1) Systemic assessment (blood pressure & diabetes mellitus).
- 2) Best corrected visual acuity.
- 3) Full ophthalmic examination.
- 4) Optical coherence tomography angiography (OCTA).
- 5) Microperimetry.

2- Operative:

All patients will receive a dose of 2mg/0.1ml intravitreal aflibercept three times with an interval of one month each.

3-Post-operative & follow up:

- 1- First day post-operative full ophthalmic examination after each intravitreal injection.
- 2- Recording any complications after each intravitreal injection.
- 3- The same as pre-operative evaluation will be repeated again after one month of the third intravitreal injection.
- 4- Follow up for one year.

Inclusion criteria:

Neovascular age-related macular degeneration (AMD) patients.

Exclusion criteria:

- 1- Diabetic patients.
- 2- Hypertensive patients.
- 3- Advanced ocular co-morbidity with poor vision.
- 4- Previous intravitreal injections.

Statistical analysis:

Recorded data were analyzed using the statistical package for social sciences, version 20.0 (SPSS Inc., Chicago, Illinois, USA). Quantitative data were expressed as mean \pm standard deviation (SD). Qualitative data were expressed as frequency and percentage.

The following tests were done:

- Paired sample t-test of significance was used when comparing between related sample.

- Pearson's correlation coefficient (r) test was used for correlating data.
- The confidence interval was set to 95% and the margin of error accepted was set to 5%. So, the p-value was considered significant as the following:
 - Probability (P-value)
 - P-value <0.05 was considered significant.
 - P-value <0.001 was considered as highly significant.
 - P-value >0.05 was considered insignificant.

3. Results

Table (1): Demographic distribution of the study group.

Demographic data	Total (N=20)
Eye	
OD	10 (50%)
OS	10 (50%)
Age (years)	53.0-60.0 [55.25 \pm 2.84]
Gender	
Female	15 (75%)
Male	5 (25%)
Race	
Caucasian	20 (100%)

This table shows that the OD (50%), OS (50%), mean age 55.25 \pm 2.84, and female (75%) & male (25%) of race (100%).

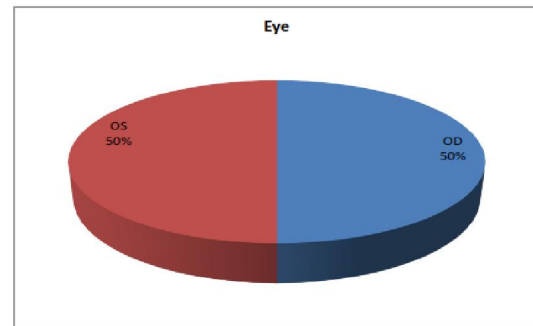


Figure (1): Pie chart eye distribution of the study group.

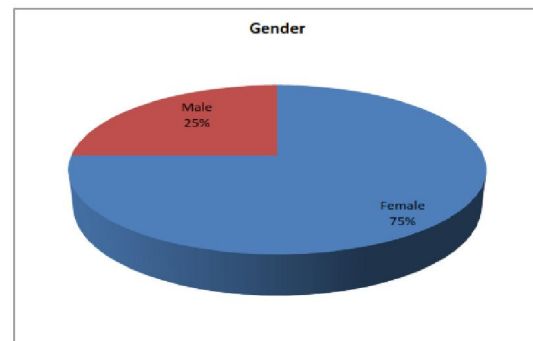


Figure (2): Gender chart eye distribution of the study group.

Table (2): Pre-Treatment greatest linear dimension, area and retinal thickness on top of CNV descriptive of the study group.

	Total (N=20)
Pre-treatment greatest linear dimension (GLD) (mm)	
Choriocapillaries	2.69-7.29 [4.36±1.84]
Outer retina	1.85-4.72 [2.89±1.16]
Pre-treatment Area (mm²)	
Choriocapillaries	0.56-3.27 [1.41±1.13]
Outer retina	0.27-1.41 [0.63±0.47]
Pre-treatment retinal thickness on top of CNV (um)	339.0-782.0 [488.3±176.99]

This table shows that the mean choriocapillaries 4.36±1.84 and outer retinal 2.89±1.16 of pre treatment greatest linear dimension (GLD), also choriocapillaries 1.41±1.13 and outer retina 0.63±0.47 of pre treatment area, while pre treatment retinal thickness on top of CNV 488.3±176.99.

Table (3): Pre-Treatment mean retinal sensitivity within the central 4 degree area in microperimetry (dB) descriptive of the study group.

	Total (N=20)
Pre-treatment mean retinal sensitivity within the central 4 degree area in microperimetry (dB)	4.60-7.80 [6.30±1.22]

This table shows that the pre-treatment mean retinal sensitivity within the central 4 degree area in microperimetry 6.30±1.22.

Table (4): Post-treatment greatest linear dimension descriptive of the study group.

	Total (N=20)
Post-treatment greatest linear dimension (GLD) (mm)	
Choriocapillaries	1.40-4.92 [2.99±1.35]
Outer retina	0.00-3.02 [1.74±1.18]
Post-treatment Area (mm²)	
Choriocapillaries	0.26-2.35 [0.99±0.84]
Outer retina	0.00-1.02 [0.40±0.39]
Post-treatment retinal thickness on top of CNV (um)	224.0-355.0 [279.0±56.90]

This table shows that the mean choriocapillaries 2.99±1.35 and outer retinal 1.74±1.18 of Post treatment greatest linear dimension (GLD), also choriocapillaries 0.99±0.84 and outer retina 0.40±0.39 of Post treatment area, while Post treatment retinal thickness on top of CNV 279.0±56.90.

Table (5): Post-treatment mean retinal sensitivity within the central 4 degree area in microperimetry descriptive of the study group.

	Total (N=20)
Post-treatment mean retinal sensitivity within the central 4 degree area in microperimetry (dB)	6.70-9.30 [8.03±1.02]

This table shows the post treatment mean retinal sensitivity within the central 4 degree area in microperimetry 8.03±1.02.

Table (6): Comparison between pre and post according to treatment greatest linear dimension (GLD) (mm), treatment Area (mm²) and treatment retinal thickness on top of CNV (um).

	Pre (N=20)	Post (N=20)	Mean Diff.	Diff. %	t-test	p-value
Treatment greatest linear dimension (GLD) (mm)						
Choriocapillaries	4.36±1.84	2.99±1.35	-1.37	-31.4%	9.934	<0.001**
Outer retina	2.89±1.16	1.74±1.18	-1.15	-39.8%	6.718	<0.001**
Treatment Area (mm²)						
Choriocapillaries	1.41±1.13	0.99±0.84	-0.42	-29.8%	6.210	<0.001**
Outer retina	0.63±0.47	0.40±0.39	-0.23	-36.5%	8.452	<0.001**
Treatment retinal thickness on top of CNV (um)	488.3±176.99	279.0±56.90	-209.3	-42.9%	4.552	<0.001**

This table shows highly statistically significant difference between pre and post according to treatment greatest linear dimension (GLD) (mm), treatment Area (mm²) and treatment retinal thickness on top of CNV (um).

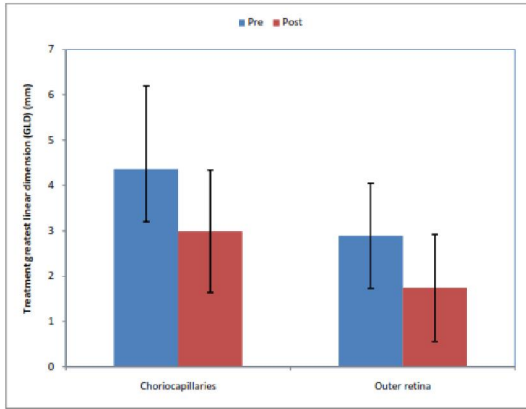


Figure (3): Bar chart between pre and post according to treatment greatest linear dimension (GLD) (mm).

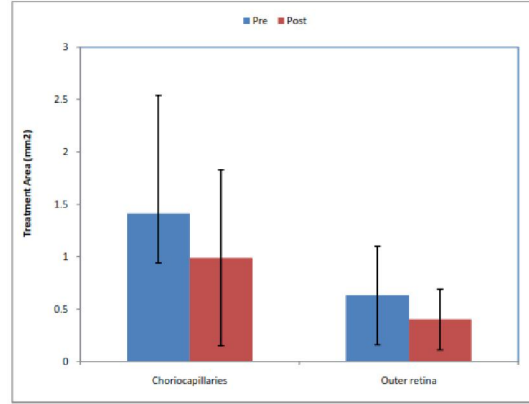


Figure (4): Bar chart between pre and post according to treatment Area (mm²).

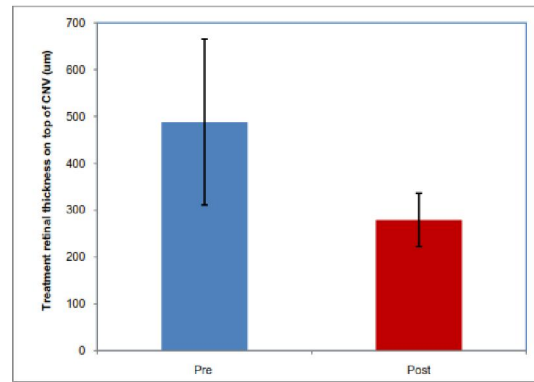


Figure (5): Bar chart between pre and post according to treatment retinal thickness on top of CNV (um).

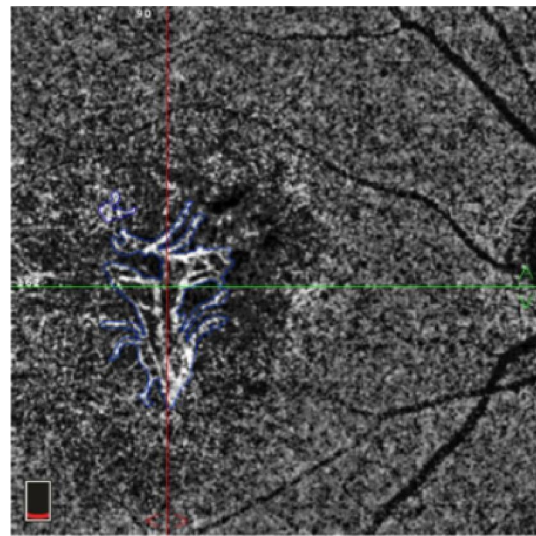



Figure (6): Comparison between pre (yellow line in the upward photo) and post (blue line in the downward photo) treatment of the CNV area in the choriocapillaries (mm²) of the same patient.




Figure (7): Comparison between pre (yellow line in the upward photo) and post (blue line in the downward photo) treatment of the CNV area in the outer retina (mm²) of the same patient.




Figure (8): Comparison between pre (yellow line in the upward photo) and post (blue line in the downward photo) treatment of greatest linear dimension (GLD) in the choriocapillaries (mm) of the same patient.




Figure (9): Comparison between pre (yellow line in the upward photo) and post treatment of greatest linear dimension (GLD) in the outer retina (mm), notice that: the downward photo shows a completely resolved CNV.




Figure (10): Comparison between pre (the upward photo) and post (the downward photo) treatment retinal thickness on top of CNV (um) of the same patient.

Table (7): Comparison between pre and post according to Treatment mean retinal sensitivity within the central 4 degree area in microperimetry (dB).

	Pre (N=20)	Post (N=20)	Mean Diff.	Diff.%	t-test	p-value
Treatment mean retinal sensitivity within the central 4 degree area in microperimetry (dB)	6.30±1.22	8.03±1.02	1.73	27.5%	-6.328	<0.001 **

This table shows highly statistically significant difference between pre and post according to Treatment mean retinal sensitivity within the central 4 degree area in microperimetry (dB).

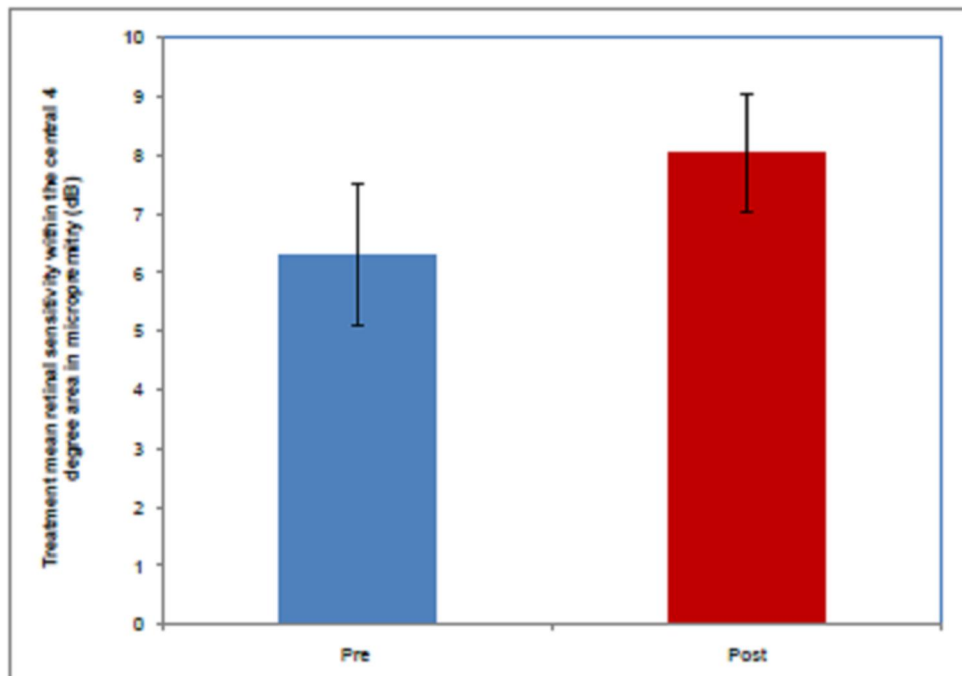


Figure (11): Bar chart between pre and post according to Treatment mean retinal sensitivity within the central 4 degree area in microperimetry (dB).

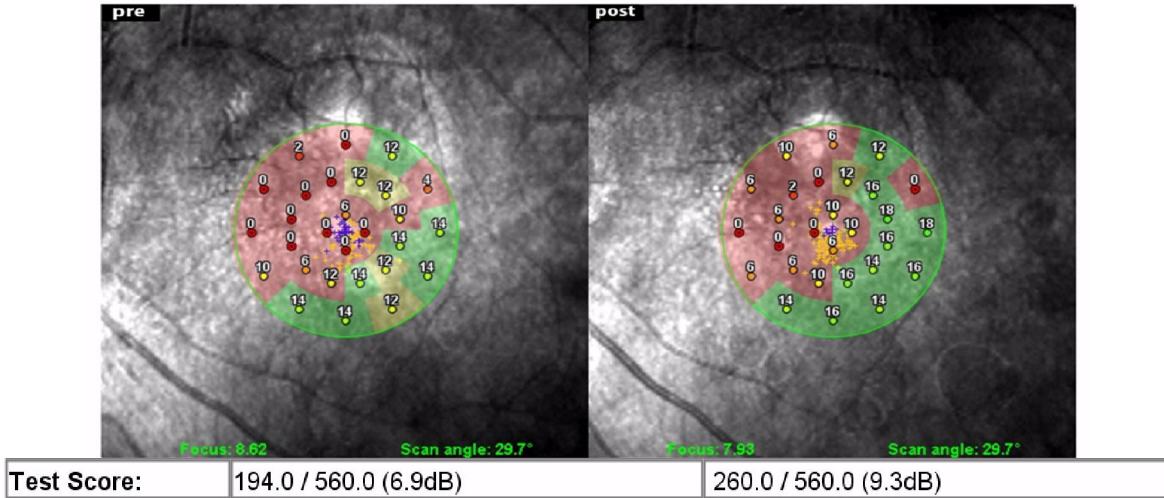


Figure (12): Comparison between pre (the left side photo) and post (the right side photo) treatment according to the mean retinal sensitivity within the central 4 degree area in microperimetry (dB) of the same patient.

Table (8): Correlation between post-treatment mean retinal sensitivity within the central 4 degree area in microperimetry (dB) with GLD, treatment area and retinal thickness on top of CNV.

	Post-treatment mean retinal sensitivity within the central 4 degree area in microperimetry (dB)	
	r	p-value
Post-treatment greatest linear dimension (GLD) (mm) [Choriocapillaries]	-0.467	<0.001**
Post-treatment greatest linear dimension (GLD) (mm) [Outer retina]	-0.453	<0.001**
Post-treatment Area (mm ²) [Choriocapillaries]	-0.561	<0.001**
Post-treatment Area (mm ²) [Outer retina]	-0.454	<0.001**
Post-treatment retinal thickness on top of CNV (um)	-0.65	<0.001**

r- Pearson Correlation Coefficient
 **p-value <0.00 HS

Negative correlation and significant between post-treatment mean retinal sensitivity within the central 4 degree area in microperimetry (dB) with GLD, treatment area and retinal thickness on top of CNV.

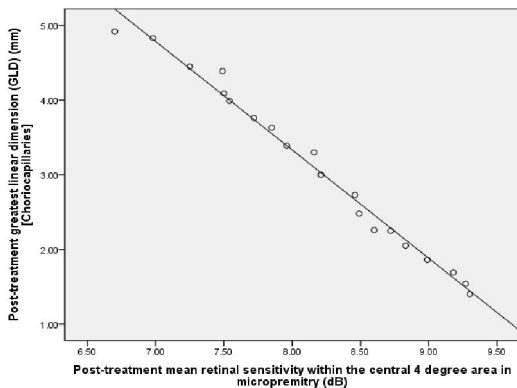


Figure (13): Scatter plot, negative correlation and significant between post-treatment mean retinal sensitivity within the central 4 degree area in microperimetry (dB) and Post-treatment greatest linear dimension (GLD) (mm) [Choriocapillaries].

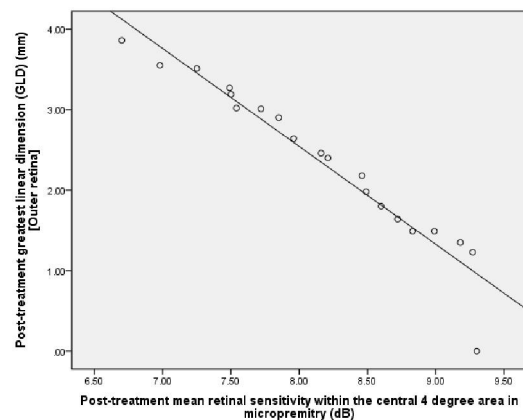


Figure (14): Scatter plot, negative correlation and significant between post-treatment mean retinal sensitivity within the central 4 degree area in microperimetry (dB) and Post-treatment greatest linear dimension (GLD) (mm) [Outer retina].

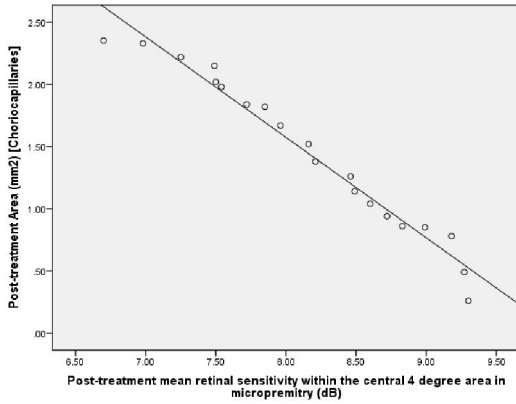


Figure (15): Scatter plot, negative correlation and significant between post-treatment mean retinal sensitivity within the central 4 degree area in microperimetry (dB) and Post-treatment Area (mm²) [Choriocapillaries].

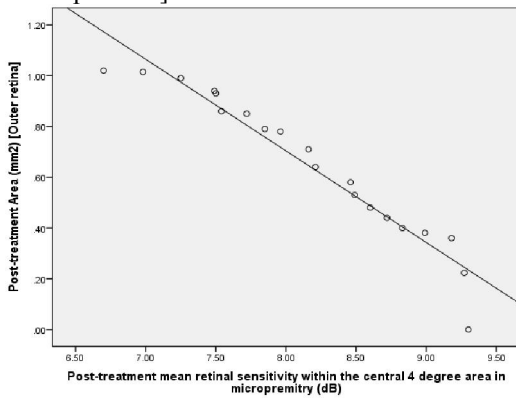


Figure (16): Scatter plot, negative correlation and significant between post-treatment mean retinal sensitivity within the central 4 degree area in microperimetry (dB) and Post-treatment Area (mm²) [Outer retina].

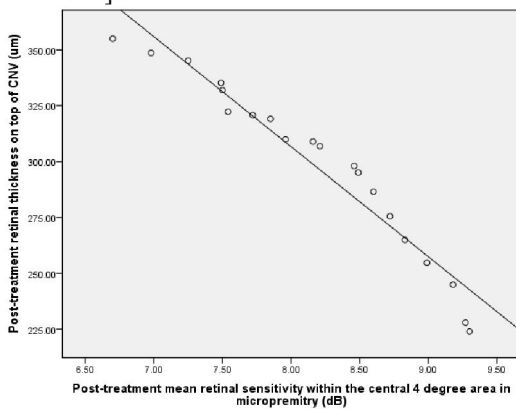


Figure (17): Scatter plot, negative correlation and significant between post-treatment mean retinal sensitivity within the central 4 degree area in microperimetry (dB) and Post-treatment retinal thickness on top of CNV (µm).

4. Discussion

In the present comparative study, OCTA scanning was done for eyes with wet AMD for anatomical assessment of CNV area size in both of (choriocapillaries and outer retina), GLD in both of (choriocapillaries and outer retina), macular thickness on top of the CNV. Microperimetry was done for assessment of retinal function for the same eyes in the form of mean retinal sensitivity within the central 4 degree area.

These investigations and tests were done at baseline before starting intravitreal aflibercept treatment and at follow up one month after the loading dose (3 injections) of intravitreal aflibercept treatment.

The present study included 20 eyes, previously diagnosed as wet AMD, of 20 patients with mean age [55.25 ± 2.84] years and male to female ratio (1:3) of race 100% Caucasian.

In the present study, we found that the area size of the CNV had highly statistically significantly improved from mean value of [1.41±1.13 mm²] at baseline to [0.99±0.84 mm²] at follow up ($p < 0.001$) and the mean value of change occurred was [-29.8%] in choriocapillaries. Moreover, the area size of the CNV had highly statistically significantly improved from mean value of [0.63±0.47 mm²] at baseline to [0.40±0.39 mm²] at follow up ($p < 0.001$) and the mean value of change occurred was [-36.5%] in outer retina.

The present study results typically agreed with those of *II* in which the mean value of change in the CNV area size in choriocapillaries had been improved to [-29.8%] after intravitreal single dose of bevacizumab injection ($p < 0.001$).

In the present study, we found that the GLD of the CNV had highly statistically significantly improved from mean value of [4.36±1.84 mm] at baseline to [2.99±1.35 mm] at follow up ($p < 0.001$) and the mean value of change occurred was [-31.4%] in choriocapillaries. Moreover, the GLD of the CNV had highly statistically significantly improved from mean value of [2.89±1.16 mm] at baseline to [1.74±1.18 mm] at follow up ($p < 0.001$) and the mean value of change occurred was [-39.8%] in outer retina.

The present study results had been agreed with those of *II* in which the mean value of change in the GLD of the CNV in choriocapillaries had been improved to [-23.6%] after intravitreal single dose of bevacizumab injection ($p < 0.001$).

The difference in the results between both studies is suggested to be due to the following;

In *II*. Study the number of intravitreal injection was (a single dose) while in the present study (a 3 doses) had been injected, in addition to the difference of the anti-VEGF type had been used which were bevacizumab and aflibercept respectively.

In the present study, we found that the retinal thickness on top of CNV had highly statistically significantly improved from mean value of $[488.3 \pm 176.99 \mu\text{m}]$ at baseline to $[279.0 \pm 56.90 \mu\text{m}]$ at follow up ($p < 0.001$) and the mean value of change occurred was $[-209.3] = [-42.9\%]$.

This decrease in the retinal thickness on top of CNV agreed with **12**. results in which mean central foveal thickness (CFT) at baseline was $[310.82 \mu\text{m}]$ and improved highly statistically significantly with mean value of change occurred was $[-119.44] = [-38.42\%]$ ($p < 0.0001$) at 12 months follow up of bevacizumab intravitreal injection.

Also, this decrease in retinal thickness map agreed with **13**. results in which mean CFT at baseline was $[324 \pm 94 \mu\text{m}]$ and decreased significantly by $[-109 \pm 98 \mu\text{m}] = [-33.64\%]$ ($p < 0.0001$) at month three of ranibizumab intravitreal injection.

The difference in the results between both studies is suggested to be due to the following;

Both **12**. and **13**. studies had been measured the CFT which may not contain the juxtafoveal CNV, while in the present study we had measured the retinal thickness in the site top to the CNV where the maximum edema size usually present thus, the improvement in the thickness may increase. In addition to the difference of the anti-VEGF type had been used which were bevacizumab and ranibizumab respectively, while in the present study we had used aflibercept.

In the present study we found that; the mean retinal sensitivity within the central 4° area in microperimetry had highly statistically significantly increased from $[6.30 \pm 1.22 \text{ dB}]$ at base line to $[8.03 \pm 1.02 \text{ dB}]$ at follow up at month three with mean value of change occurred was $[1.73 \text{ dB}] = [27.5\%]$, ($p < 0.001$).

This result agreed with **14**. in which the mean retinal sensitivity within the central 4° area in microperimetry had increased from $[3.69 \pm 3.44 \text{ dB}]$ at base line to $[6.95 \pm 3.43 \text{ dB}]$ at month three ($p < 0.001$), both studies had the same p-value result, but **14**. study has been found to be better result in the mean value of change which is $[88.3\%]$.

At the end of the present study we had found a negative correlation and significant between post-treatment mean retinal sensitivity within the central 4° area in microperimetry with GLD in choriocapillaries [$r = -0.467$] ($p < 0.001$), GLD in outer retina [$r = -0.453$] ($p < 0.001$), CNV area size in choriocapillaries [$r = -0.561$] ($p < 0.001$), CNV area size in outer retina [$r = -0.454$] ($p < 0.001$) and retinal thickness on top of CNV [$r = -0.65$] ($p < 0.001$).

This result agreed with a prospective observational study by **15**. they found a strong negative

correlation between central retinal thickness values and central retinal sensitivity ($r = -0.509$, $p = 0.004$) **15**.

5. Conclusion

After 3 times intravitreal injections of aflibercept in cases of AMD, we concluded that, aflibercept is an effective treatment in AMD; it can decrease the activity, area size, GLD and thickness of the CNV, in addition to improving the sensitivity function of the retina and visual acuity.

OCTA is an effective tool that can provide a non-invasive method in the diagnosis and follow up of the activity and anatomical changes in AMD.

Microperimetry is an effective tool which can help in the follow up of the retinal sensitivity functional improving in AMD.

Recommendations

Early diagnosis and treatment are essential for the best outcome not only regarding anatomical retinal structural improvement but also important for restoration of functional vision. Thus, we recommend that; all people of the age group > 50 years old should be advised for fundus examination especially those with one or more risk factors.

We recommend OCTA as a helpful non-invasive tool for diagnosis and follow up of AMD.

Microperimetry is an effective method to follow up the functional improvement of the retinal sensitivity; unfortunately few studies have been included it. We recommend future more studies on the microperimetry it can provide a lot of significant data on different kinds of the retinal diseases.

We recommend aflibercept as an anti-VEGF drug that is effective in the treatment of active CNV.

References

1. Mathenge W, Bastawrous A, Peto T, et al. Prevalence of age related macular degeneration in Nakuru, Kenya: a cross-sectional population-based study. *PLoS Med* 10: e1001393, 2013.
2. Wong TY, Chakravarthy U, Klein R, et al. The natural history and prognosis of neovascular age-related macular degeneration: a systematic review of the literature and meta-analysis. *Ophthalmology* 115: 116-126, 2008.
3. Ferrara N and Kerbel RS Angiogenesis as a therapeutic target. *Nature* 438: 967-974, 2005.
4. Lanzetta P, Mitchell P, Wolf S, et al Different antivascular endothelial growth factor treatments and regimens and their outcomes in neovascular age-related macular degeneration: a literature review. *Br J Ophthalmol* 97: 1497-1507, 2013.
5. Ozkaya A, Alkin Z, Agca A, et al. One-year results of treatment with bevacizumab alone or ranibizumab alone for low visual acuity due to

- neovascular age-related macular degeneration. *J Ocul Pharmacol Ther* 29: 865-869, 2013.
6. David J. Browning, Peter K. Kaiser, Philip J. Rosenfeld et al. Aflibercept for Age-Related Macular Degeneration: A Game-Changer or Quiet Addition? *Am J Ophthalmol*, Volume 154, Issue 2, Pages 222–226 (August 2012).
 7. Chakravarthy U, Harding SP, Rogers CA, et al. Alternative treatments to inhibit VEGF in age-related choroidal neovascularisation: 2-year findings of the IVAN randomised controlled trial. IVAN study investigators. *Lancet* 382: 1258-1267, 2013.
 8. Hartmann KI. Scanning laser ophthalmoscope imaging stabilized microperimetry in dry age-related macular degeneration. *Retina* 31:1323–1331, 2011.
 9. Luu CD, Dimitrov PN, Robman L, et al. Role of flicker perimetry in predicting onset of late-stage age-related macular degeneration. *Arch Ophthalmol*. 130:690–699, 2012.
 10. Talisa E de Carlo, Andre Romano, Nadia K Waheed, et al. A review of optical coherence tomography angiography: *International Journal of Retina and Vitreous* 119:101-110, 2015.
 11. NORA W. MUAKKASSA, MD, ADAM T. CHIN, MD, TALISA DE CARLO, BA, KENDRA A. KLEIN, MD et al.: Characterizing the effect of antivascular endothelial growth factor therapy on treatment-naïve choroidal neovascularization using optical coherence tomography angiography. *RETINA* 35:2252–2259, 2015.
 12. Danny Siu-Chun Ng, Alvin Kwan-Ho Kwok, Justin Man-kit Tong, Clement Wai-Nag Chan and Walton Wai-Tat Li, Bevacizumab for neovascular age-related macular degeneration in chinese patients in clinical setting. *Int J Ophthalmol.*; 9(3): 424-430, doi: 10.18240/ijo.2016.
 13. Bolz M, Simader C, Ritter M, Ahlers C, Benesch T, Prünke C, Schmidt-Erfurth U: Morphological and functional analysis of the loading regimen with intravitreal ranibizumab in neovascular age-related macular degeneration. *Br J Ophthalmol*; 94(2):185-189, 2010.
 14. Ozdemir H, Karacorlu M, Senturk F, Karacorlu SA, Uysal O: Microperimetric changes after intravitreal bevacizumab injection for exudative age-related macular degeneration. *Acta Ophthalmol*; 90:71-75, 2012.
 15. Sulzbacher F., Kiss C., Kaider A., Eisenkoelbl S., Munk M., Roberts P., Sacu S., Schmidt-Erfurth U.: Correlation of SD-OCT Features and Retinal Sensitivity in Neovascular Age-Related Macular Degeneration. *IOVS*; 53(10):6448-6455, 2012.

5/29/2018