

Protective Effect of Folic Acid on Prenatal & Postnatal Toxicity of Cisplatin on Spinal Cord " A light and electron microscopic study "

Saadia A. Shalaby, Essam M. Eid, Omar A. Aziz Allam, Naglaa A. S. Sarg and Abulmaaty M. Elsayed

Anatomy and Embryology Department, Faculty of Medicine, Benha University, Egypt.

dr.abulmaaty@gmail.com

Abstract: Background: cisplatin is used in chemotherapy of different cancers because of its apoptotic effects and its ability to generate Reactive Oxygen Species, but its usage during pregnancy is restricted because of its side effects including many malformations. As folic acid supplementation decreases the incidence of the neural defects caused by certain drugs as progesterone, this work investigates the possible protective effect of folic acid on cisplatin toxicity on spinal cord. **Material & methods:** I- (Prenatal group): Thirty pregnant rats were subdivided into three equal subgroups: **A.** prenatal control subgroup: received saline. **B.** Prenatal cisplatin subgroup: were injected intraperitoneally with the therapeutic dose of Cisplatin (1 mg /kg) on alternate days. **C.** Prenatal cisplatin & folic acid subgroup: They were injected intraperitoneally with Cisplatin Plus folic acid (400 microgram) by the nasogastric tube. The fetuses were obtained by caesarian section 2 days after the last dose to get the spinal cord. II- (Postnatal group): Thirty pregnant rats were subdivided into three equal subgroups **A-**Postnatal control subgroup: pups received saline from 1st day of delivery. **B-**Postnatal cisplatin subgroup: pups were injected intraperitoneally with the therapeutic dose of Cisplatin (1mg/gm.) on alternate days from 1st day of delivery. **C-**Postnatal cisplatin & folic acid subgroup: pups were injected intraperitoneally with the therapeutic dose of Cisplatin Plus folic acid in a dose of (400 microgram) by gastric tube. The specimens were prepared for light and electron microscopic examination. **Results: Light microscopic observations:** The spinal cord show signs of cisplatin toxicity in the form of degeneration & disfigurement of the grey matter with spots of hemorrhage. The neurons of the ventral horn have piknotic nuclei and surrounded by vacuolated white matter. The spinal cord of the folic acid groups show improvement which appear in the arrangement of the grey matter in dorsal and ventral horns. The central canal also become well defined and patent the neurons of the anterior horn have large nuclei and prominent nucleolus, the vacuoles in the white matter are less than that of the cisplatin group. **Electron microscopic observations:** the cisplatin affects the neurons which appear distorted with shrunken eccentric piknotic nuclei that consist mainly of heterochromatin. The nucleus is surrounded by irregular nuclear membrane. the cytoplasm of these neuron is full of vacuoles and dilated rough endoplasmic reticulum. The myelinated axons surrounding the neurons are vacuolated with destructed myelin sheath. The folic acid treated group show the neuron with signs of improvement which appear in the nucleus which consists of abundant euchromatin and less heterochromatin with regular nuclear membrane. The cytoplasm of these neurons contains multiple healthy mitochondria, rough endoplasmic reticulum and Golgi apparatus with no vacuoles; the myelinated axons are surrounded by intact myelin sheath. **Conclusion:** cisplatin has a potent toxic effect on the developing spinal cord which may extend to the degeneration of the spinal cord. Folic acid can alter this toxicity and protect the developing spinal cord.

[Saadia A. Shalaby, Essam M. Eid, Omar A. Aziz Allam, Naglaa A. S. Sarg and Abulmaaty M. Elsayed. **Protective Effect Of Folic Acid On Prenatal & Postnatal Toxicity Of Cisplatin On Spinal Cord " A light and electron microscopic study "**. *Nat Sci* 2018;16(4):96-104]. ISSN 1545-0740 (print); ISSN 2375-7167 (online). <http://www.sciencepub.net/nature>. 16. doi:10.7537/marsnsj160418.16.

Keywords: cisplatin – spinal cord – folic acid.

1. Introduction

For many years, cisplatin (cispt) has been used in chemotherapy of different cancers because of its apoptotic effects. It binds DNA-generating adduct cispt/DNA that provokes the distortion of double helix blocking the transcription and the replication processes (Todd and Lippard, 2009) Also, it is able to generate Reactive Oxygen Species (ROS) and it inhibits the activity of antioxidant enzymes in some tissues (Dilliogluligil et al., 2005) Unfortunately, one of the adverse side effects of cisplatin is neurotoxicity (Rzeski et al., 2004) The incidence of cancer during

pregnancy is increasing this is likely because of the tendency for sex specific cancers, such as breast and cervical cancer, to occur at younger ages than other cancers. Demonstrably, breast and cervical cancers are the 2 most common cancers to occur in young women. Thyroid cancer is the third most common. Platinum derivatives are active against various malignancies that occur more frequently during pregnancy (Pereg et al., 2008). In spite of the effectiveness of cisplatin as antineoplastic drug, but its usage during pregnancy is restricted because of its side effects including many malformations as ventriculomegaly, microphthalmous

and polyhydraminos (**Elite L et al. 1999**). Folic acid (FA) administration during child-bearing years can prevent many congenital malformations caused by teratogens (**John Wallingford, et al. 2013 & Apolline, et al. 2013**). Based on animal studies, epidemiologic studies and intervention trials, maternal folic acid is known to be protective for neural tube defects, primarily spinabifida and anencephalus (**Jaquier et al.,:2006**).

Folic acid supplementation decreased the incidence of the defects caused by certain drugs as progesterone, but did not obviate them (**Iqbal I. et al., 2012**).

Aim of the work: to investigate the possible protective effect of folic acid on cisplatin toxicity on spinal cord.

2. Materials and methods

A) Materials:

1-Animals:

Sixty adult female albinorats (obtained from faculty of veterinary medicine, Benha University) were used in this study. Their weights ranged from 200-250g. Animals were placed in quarantine for one week prior to breeding, housed in separate plastic cages in a controlled environment at 23-25 °C and light – dark cycle (14-10 H). There was free access to water and balanced diet which consisted of milk, vegetables and bread. All rats were kept under the same circumstances throughout the experiment.

After acclimatization to laboratory conditions, two females were kept overnight with one male to allow mating; the presence of sperms in vaginal smear in the next morning indicated the day zero of pregnancy.

2-Drugs:

Two drugs were used in this study:-

1-The cisplatin in the form of 50 mg vial was prepared for injection (produced by BRISTOL-MAYERS-SQUIB). This vial was diluted in 500 ml of distilled water, so every 1 ml of the solution contains 0.1 mg of cisplatin. Every rat was injected by 1 mg /kg (once every other day) intraperitoneally. This is equivalent to the human low therapeutic dose. (**Apfel et al., 1992**).

2- The folic acid in the form of 800 microgram tablets was prepared for oral use (produced by AVENTIS PHARMA). This was powdered and dissolved by 10 ml of distilled water, so every 5 ml of the solution contains 400 microgram of folic acid. By the nasogastric tube, every rat was supplied by 5ml of the solution (once daily). (**Deborah et al, 2012**).

B) Methods:

I- (Prenatal group): Thirty pregnant rats were subdivided into three equal subgroups each subgroup consists of ten pregnant rats:

a. Prenatal control subgroup: They received saline from 1st day of pregnancy till be sacrificed at 18th Day of pregnancy.

b. Prenatal cisplatin subgroup: They were injected intraperitoneally with the therapeutic dose (1 mg/Kg) of Cisplatin on alternate days from 1st day of pregnancy till being scarified at 18th day of pregnancy.

c. Prenatal cisplatin & folic acid subgroup: They were injected intraperitoneally with (1 mg/Kg) of Cisplatin (every other day) Plus folic acid in a dose of (400microgram) daily from 1st day of pregnancy by the nasogastric tube till being scarified at 18th of pregnancy.

The fetuses were obtained by caesarian section to get the spinal cord, the back was dissected under the dissecting microscope, to obtain the vertebral column then the vertebral column was opened to get the spinal cord. The specimens of the spinal cord were prepared for light and electron microscopic examination.

II- (Postnatal group): Thirty pregnant rats were subdivided into three equal subgroups; each subgroup consisted of ten pregnant rats:

a- Postnatal control subgroup: The pregnant rats were allowed to complete pregnancy, pups received saline from 1st day of delivery till being sacrificed on the 21st day postnatal

b- Postnatal cisplatin subgroup: They will be allowed to complete pregnancy; pups were injected intraperitoneally with the therapeutic dose (1 mg/Kg) of Cisplatin on alternate days from 1st day of delivery till being sacrificed on the 21st day postnatal.

c- Postnatal cisplatin & folic acid subgroup: They were allowed to complete pregnancy, pups were injected intraperitoneally with the therapeutic dose (1 mg/Kg) of Cisplatin (every other day) Plus folic acid in a dose of (400microgram) daily (given to the pups through gastric tube) from 1st day of delivery till being sacrificed on the 21st day postnatal.

The pups were anaesthetized by ether inhalation and the specimens were obtained by the same way as the prenatal groups and prepared for light and electron microscopic examination.

For Light microscopic preparation: (Drury and Wallington, 1980)

The specimens were fixed in 10% buffered neutral formalin then, transferred to ethyl alcohol for dehydration. The specimens were cleared in xylol. Then, impregnated with soft paraffin and finally, embedded in hard paraffin. Serial sections 5-7 µm thick were sliced and stained with Hematoxylin & Eosin and for prenatal and postnatal specimens (**Bancroft and Gamble, 2002**).

The stained slices were examined with an Olympus light microscope equipped with an automatic photo micrographic camera system.

For Electron microscopic preparation:

The fresh specimens were fixed in 3% phosphate buffered glutaraldehyde. The specimens were post fixed in a freshly prepared 1% osmium tetroxide in phosphate buffer then dehydrated. The dehydration was completed by propylene. The specimens were then embedded in pre-labeled plastic capsule.

Capsules were polymerized in a temperature controlled oven at 60°C for 48 hours. The polymerized block was trimmed into a pyramid with a small trapezoid surface. Semi thin sections were cut at 1 µm thickness, and then the sections were stained with 1% toluidine blue stain and examined by the Olympus microscope for general orientation (Bancroft and Gamble, 2002).

Ultra-thin sections: 50 nm thick were obtained from the selected blocks stained with uranyl acetate followed by lead citrate

The stained grids were examined by Philips 201-transmission electron microscope at 60-80 kv in transmission Electron microscope Unit at Medical Military Academy. Finally, the electron photographs were taken from the selected areas.

3. Results

A- The spinal cord in the Fetal Albino Rat aged 18 days:

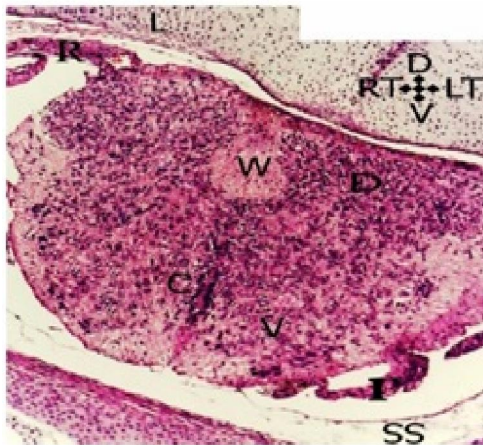


Fig. (1):- A Photomicrograph of thoracic segment of the Spinal cord of rat fetus aged 18 day of the control group showing that: the spinal cord consists of ill-defined H- shape grey matter. The grey matter surrounds the central canal (C). The grey matter is surrounded by white matter (W); Notice the ratio of the grey matter is more than the white matter. the section is surrounded by the subarachnoid space (SS). Notice the lamina of the vertebra (L), the dorsal root (R) and the ventral root (r), the ventral horn (V) & dorsal horn (D). (Hx & E. x 100).

a- Control group:

In Light microscopic observations: The sections of the spinal cord showed that, the spinal cord consisted of ill-defined H- shape grey matter. The grey matter surrounded the central canal. The grey matter was surrounded by cylindrical white matter. The ratio

of the grey matter was more than the white matter. the spinal cord was surrounded by pia mater, arachnoid mater and subarachnoid space and dura mater (fig.1). The neurons of the ventral horn were large in size with large nucleus & prominent nucleolus; the neurons were surrounded by neuroglial cells that had a dark small nucleus (Fig. 2).

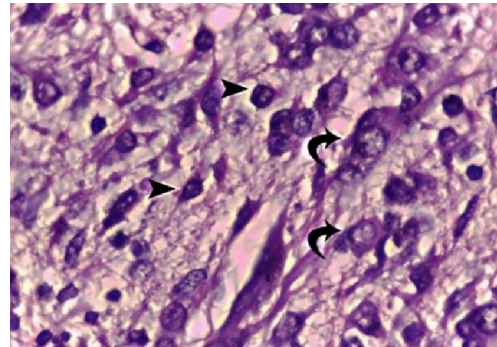


Fig. (2): A Photomicrograph of the ventral horn of Spinal cord of rat fetus aged 18 days of the control group showing large neuron (arrow) with large central nucleus & prominent nucleolus, the neurons are surrounded by neuroglial cells (arrow heads) & in the periphery there is the white matter. (H x & E. x 1000).

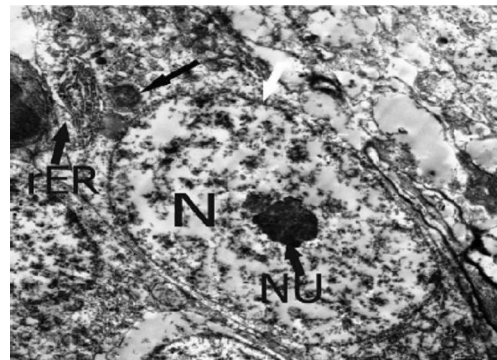


Fig. (3): An electromicrograph of the spinal cord of rat fetus aged 18 day of the control group showing: a neuron with large nucleus (N), the nucleus consists of abundant euchromatin and less heterochromatin. The nucleus has a prominent nucleolus (NU) and surrounded by regular nuclear membrane (white arrow). the cytoplasm of the neuron contains mitochondria (black arrow) and rough endoplasmic reticulum (rER). (EM x 2000).

In Electron microscopic observation: The neuron had a large nucleus that consisted of abundant euchromatin and less heterochromatin and had a prominent nucleolus. The nucleus was surrounded by a regular nuclear membrane. The cytoplasm of these neurons contained mitochondria and rough endoplasmic reticulum. (fig.3).

b- Cisplatin group:

In Light microscopic observations: The sections of the spinal cord showed signs of toxicity in the form of degeneration in the grey matter and disfigurement of the spinal cord. The central canal was

obliterated (**fig. 4**). The neurons of the ventral horn had swollen nucleus that surrounded by a thin rim of cytoplasm and were surrounded by white matter that had large vacuoles (**fig. 5**).

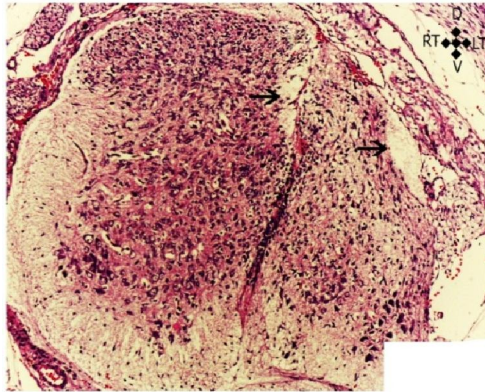


Fig. (4): A Photomicrograph of the Spinal cord of rat fetus aged 18 days of the cisplatin group showing: degeneration (arrow) and disfigurement of the grey matter. The central canal is obliterated (H & E. x 100).

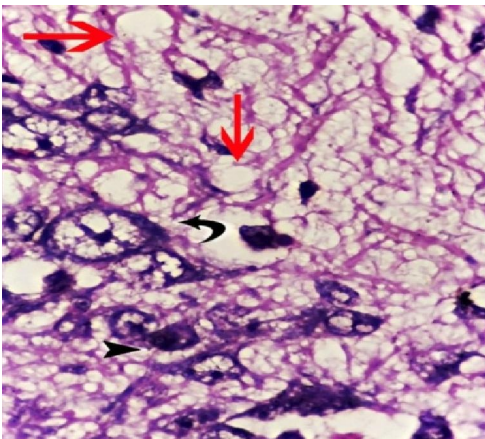


Fig. (5): An Photomicrograph of the ventral horn of the cisplatin group showing neurons with swollen nucleus that surrounded by thin rim of cytoplasm (black arrow), other neurons a (arrow head) are small with dark cytoplasm. The white matter has large vacuoles (red arrow). (H x & E. x 1000).

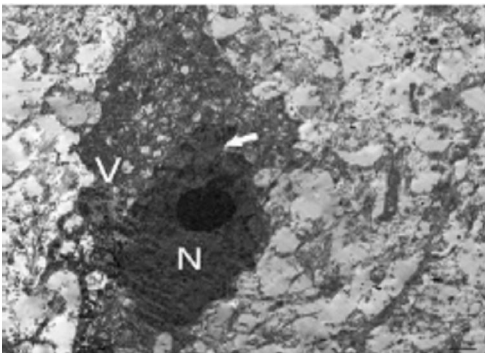


Fig. (6): An electro micrograph of the spinal cord of rat fetus aged 18 day of the cisplatin group showing: distorted neuron with shrunken eccentric piknotic nucleus (N), the nucleus consists mainly of heterochromatin. The nucleus is surrounded by irregular nuclear

membrane (white arrow). the cytoplasm of the neuron is electro dense and is full of vacuoles (V). (EM x 2000)

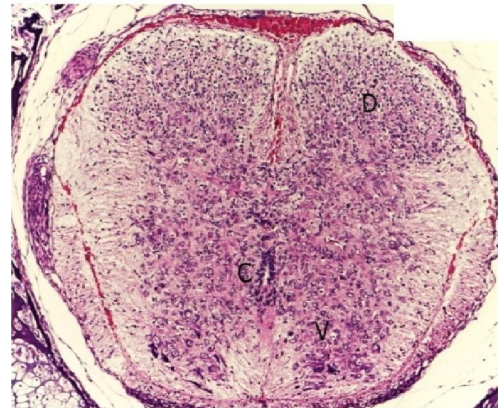


Fig. (7): A Photomicrograph of the Spinal cord of rat fetus aged 18 days treated by the cisplatin and folic acid showing: the grey matter of the spinal cord is well arranged in dorsal horn (D) and ventral horn (V); the central canal (C) is well defined and patent. (H & E. x 100).

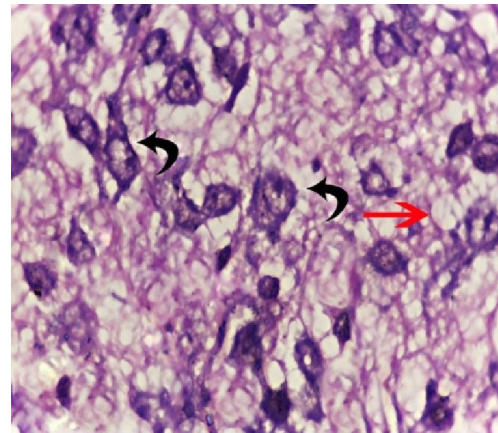


Fig. (8): A Photomicrograph of the anterior horn of Spinal cord of 18 days fetus of cisplatin & folic acid group showing that; the neuron (arrow) has a large nucleus and prominent nucleolus the, the cytoplasm amount is increased in relation to the nucleus size, but some vacuoles (red arrow) are still present in the white matter. (H x & E. x 1000).

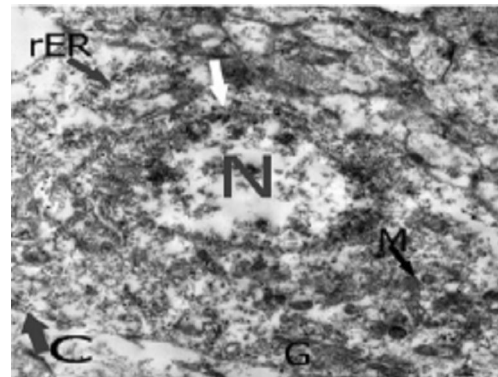


Fig. (9): A Photomicrograph of the spinal cord of rat fetus aged 18 day treated by cisplatin and folic acid showing: a neuron that has a nucleus (N) with slightly irregular nuclear membrane (white arrow). The nucleus consists of abundant euchromatin and less

heterochromatin. the cytoplasm of the neuron contains multiple healthy mitochondria (M), rough endoplasmic reticulum (rER) and Golgi apparatus (G). Notice the cell membrane (C). (EM x 2000).

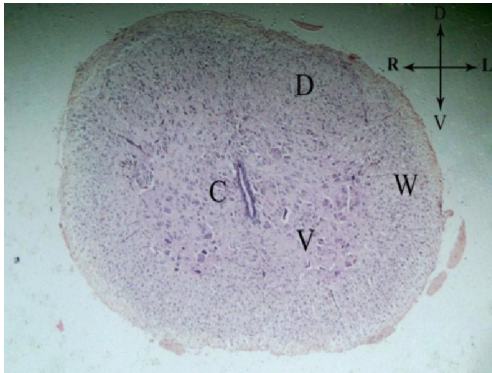


Fig. (10): A Photomicrograph of lumbar segment of the Spinal cord of rat aged 21 day of the control group showing: regular outline of the section, the grey matter consists of dorsal horn (D) and ventral horn (V); the grey matter surrounds the central canal (C) which is elongated and completely patent. The grey matter is surrounded by white matter (W). notice that the ratio of white to grey matter increased than the prenatal group. (H. & E. x 100).

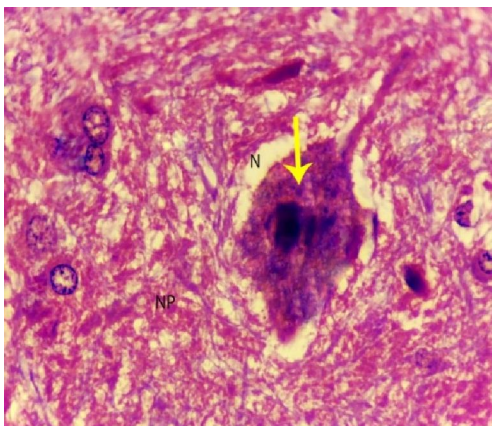


Fig. (11):: A Photomicrograph of the anterior horn of the spinal cord showing large multipolar neuron (N) with large nucleus & prominent nucleolus, the cytoplasm is full with Nissl granules (yellow arrow). the neuron is surrounded by dense neuropil (NP). (H x & E. x 1000).

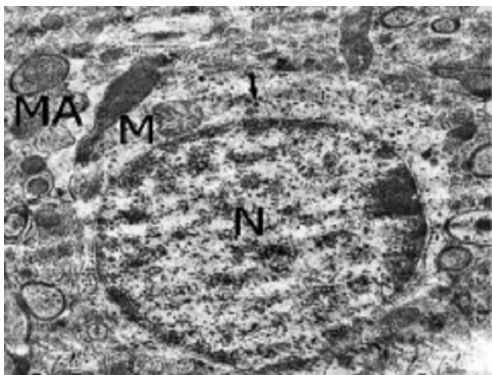


Fig. (12): A Photomicrograph of the spinal cord of rat aged 21 day of the control group showing: a neuron with large nucleus (N), the chromatin inside the nucleus is euchromatin mainly and less amount of heterochromatin. the cytoplasm of the neuron contains large

mitochondria (M) and multiple lysosomes (black arrow). The neuron is surrounded by many myelinated axons (MA). (EM x 2000).

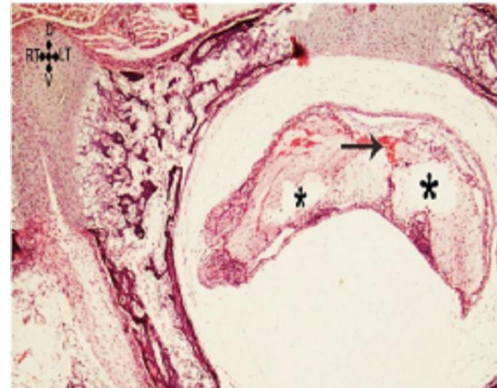


Fig. (13): A Photomicrograph of the Spinal cord of rat aged 21 days of the cisplatin group showing: complete degeneration of the spinal cord which is replaced by large vacuoles (*) and spots of hemorrhage (arrow). (H & E. x 100).

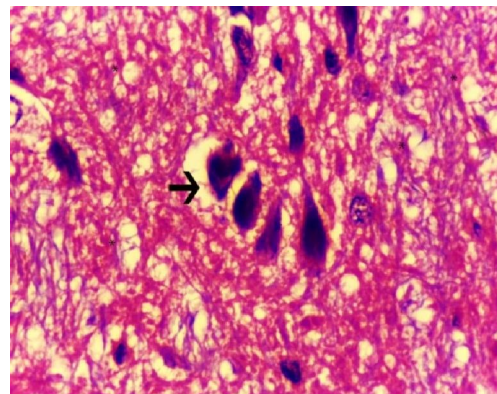


Fig. (14):: An enlarged Photomicrograph of the ventral horn cells showing neurons that are shrunken and piknotic with condensed chromatin (arrow) with vacuoles in the surrounding neuropil (*). (H x & E. x 1000).

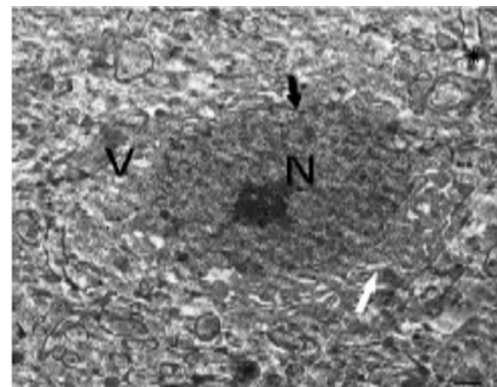


Fig. (15): A Photomicrograph of the spinal cord of rat aged 21 day of the cisplatin group showing: a neuron with small dark piknotic nucleus (N), and the nuclear membrane is irregular (black arrow). the cytoplasm of the neuron contains dilated rough endoplasmic reticulum (white arrow) and multiple vacuoles (V). The myelinated axons (*) are vacuolated with destructed myelin sheath. (EM x 2000).

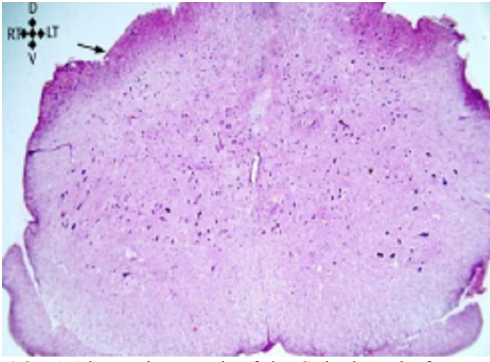


Fig. (16): A Photomicrograph of the Spinal cord of rat aged 21 days treated by the cisplatin and folic acid showing that: the spinal cord regains its usual design but the outlines are still irregular (arrow). n (H & E. x100).

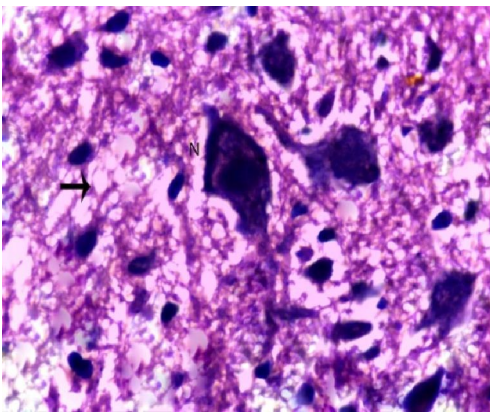


Fig. (17): A Photomicrograph of the anterior horn of Spinal cord of 21 days old rat of folic acid & cisplatin group showing large neuron with large central nucleus (N), small spaces in the neuropil (arrow). Notice the number of Glial cells decreased than in cisplatin group (H x & E. x 1000).

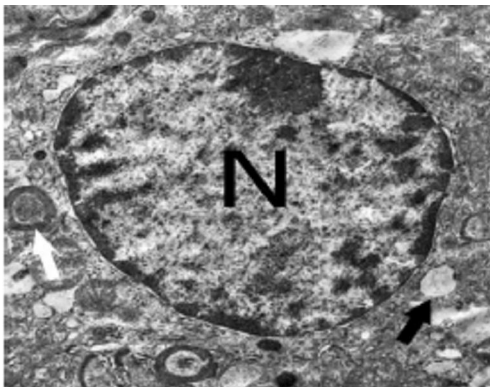


Fig. (18): A Photomicrograph of the spinal cord of rat aged 21 day treated by the cisplatin and folic acid showing: a neuron with large nucleus (N), the chromatin inside the nucleus is condensed at the periphery, the nuclear membrane is regular. the cytoplasm of the neuron contains multiple vacuoles (black arrow). The myelinated axons (white) are surrounded by intact myelin sheath. (EM x 2000).

In Electron microscopic observation: -the cisplatin affected the neurons which appeared

distorted with shrunken eccentric piknotic nuclei that consisted mainly of heterochromatin. The nucleus was surrounded by an irregular nuclear membrane. The cytoplasm of these neuron was electro dense and full of vacuoles (fig.6).

c- Cisplatin & folic acid group:

In Light microscopic observations: the sections of the spinal cord showed improvement of the spinal cord which appeared in the nearly normal arrangement of the grey matter in dorsal horn and ventral horn, and the central canal which became well defined and patent (fig. 7) the neurons of the anterior horn had large nuclei and prominent nucleolus. The cytoplasm amount was more than that of the cisplatin group, but there are still some vacuoles in the white matter (Fig. 8).

In Electron microscopic observation:-: the neuron showed improvement which appeared in the nucleus which consisted of abundant euchromatin and less heterochromatin and the cytoplasm of the neuron contained multiple healthy mitochondria, rough endoplasmic reticulum and Golgi apparatus with no vacuoles in the cytoplasm (fig.9).

B- The spinal cord in Albino rat aged 21 Days:

a- Control group:

In Light microscopic observations: The sections of the spinal cord showed regular outline of the section, the grey matter consisted of dorsal horn and ventral horn; the grey matter surrounded the central canal which was elongated and completely patent. The grey matter was surrounded by white matter and the ratio of white to grey matter was more than that of the prenatal group (fig. 10). The anterior horn neurons were large multipolar neuron with large nucleus & prominent nucleolus, the cytoplasm was full with Nissl granules. the neuron was surrounded by dense neuropil (fig.11).

In Electron microscopic observation:-the sections of the spinal cord of the control group showed neurons with large nucleus, the chromatin inside the nucleus was euchromatin mainly with less amount of heterochromatin. The cytoplasm of the neuron contained large mitochondria and multiple lysosomes. The neuron was surrounded by many myelinated axons (fig.12).

b- Cisplatin group:

In Light microscopic observations: The sections of the spinal cord showed complete degeneration of the spinal cord which was replaced by large vacuoles and spots of hemorrhage (fig. 13). The ventral horn cells showing neurons that were shrunken and piknotic with vacuoles in the surrounding neuropil (Fig. 14).

In Electron microscopic observation: -: the neurons had a small dark piknotic nucleus that was full

of heterochromatin and the nuclear membrane was irregular. The cytoplasm of the neuron contained dilated rough endoplasmic reticulum and multiple vacuoles. The myelinated axons surrounding the neurons were vacuolated with destructed myelin sheath. (Fig. 15).

c- Cisplatin & folic acid group:

In Light microscopic observations: the sections of the spinal cord showed that, the spinal cord regained its usual design but the outlines were still irregular (fig. 16). The anterior horn showing that the neuron were enlarged with large central nucleus, small spaces in the neuropil Fig. (17).

In Electron microscopic observation: - the spinal cord showed some improvement. The neuron that had a large nucleus, the chromatin inside the nucleus was condensed at the periphery of the nucleus and the nuclear membrane was regular but the cytoplasm still contains multiple vacuoles. The myelinated axons were surrounded by intact myelin sheath (fig. 18).

4. Discussion

Cisplatin is one of platinum compounds which are of great value as an anticancer chemotherapy as reported by (Argyriou et al., 2005). Neurotoxicity is considered to be the major dose-limiting side effect for some of these compounds (Muller et al., 1992). Up till now there has been a lack of fundamental knowledge regarding the sub-cellular effects of these drugs and the possible role of neuro-protective agents. Therefore, this study was designed to investigate the neurotoxic effect of cisplatin, as an anticancer agent, on the developing spinal cord and the possible neuroprotective role of folic acid on it.

In the present study it was found that, cisplatin has a toxic effect on the developing spinal cord. This toxicity is represented by multiple vacuoles in the grey and white matter with partial degeneration of the ependymal cells lining the central canal. These findings go with the results of (Lin et al., 2005). The shape of the spinal cord is severely affected and this effect ranges from disfigurement of the grey matter in fetuses aged 18 days to end in complete degeneration of the cord which is replaced by large vacuoles and spots of hemorrhage in rats aged 21 days. These findings are agreed by (Abou-Elghait et al., 2012) who found that Examination of spinal cord of cisplatin treated animals showed marked structural degeneration of the spinal cord architecture. But some researches as (Thompson et al. 1984) found that cisplatin cannot affect the spinal cord as it cannot pass the blood brain barrier. We postulated this toxicity of cisplatin on the spinal cord in perinatal rats as it can pass placental barrier and affect the nervous tissue before formation of the blood brain barrier.

Ultrastructure examination confirm this toxicity as the sections of the spinal cord by electron microscope show that in prenatal group there are distorted neurons with eccentric piknotic nuclei. These findings are agreed by (Uribe et al., 2013) who found that the nuclei of the neurons became piknotic after treatment by cisplatin compounds; he postulated this effect to the cisplatin DNA adduct complex which occur in the nucleus. In the current study the nucleus of the cisplatin treated specimens consists mainly of heterochromatin and surrounded by irregular nuclear membrane, the cytoplasm is full of vacuoles and dilated rough endoplasmic reticulum and swollen mitochondria. These findings were approved by (Gari et al., 2011) who found that cisplatin induces morphological changes due to apoptosis including condensation of the nuclear chromatin and irregularity of nuclear membrane with destruction of rough endoplasmic reticulum. In this study it was found that; in postnatal group there are vacuoles in the myelinated fibers with shrinkage of the axoplasm and destruction of myelin sheath. These finding are similar to the results of (Minami T et al., 1996). These results could be explained by previous reports which mentioned that patients treated with cisplatin are characterized by a significant reduction of circulating NGF (nerve growth factor) level (Authier et al., 2003). Since NGF is a protein played a key role to prevent cisplatin mediated neuronal apoptosis, we postulated that the low availability of neurotropic factors might be a cause of neuropathy development. Moreover, it was proved that cisplatin induced cell death in a culture of neurons and interfered with the morphological and molecular events of postnatal rat neuronal development (Wick et al., 2004).

In the current study, we found that, the folic acid can alter the cisplatin toxicity of the spinal cord as the specimens received folic acid during treatment with cisplatin show signs of improvement which appear in the following, the vacuulations in the grey and white matter decreased and the size of the spinal cord increased and its outlines are regular. These finding are agreed by (M.J. CANO et al., 2000) who postulated that effect to the fact that the process of, "injured nerve tissue began producing surface receptors for folate and then folate is absorbed into the nerve cell" which triggered the accelerated healing of the spinal cord. The major niche in this process is part of what could be a revolution of modern medicine, the discovering and application of epigenetics, which are "changing the functioning of DNA without changing the composition of genes." (Bermans et al., 2004).

The ultrastructure confirms that, the amount of euchromatin increased in the nuclei, with regular nuclear membrane, these findings are agreed by (Quan et al., 2015) who found that Under electron

microscopy observation, folic acid can remit and suppress the damage done to neurons and increase the amount of its euchromatin. Tetrahydrofolate is The active form of folic acid in the body which is used in the synthesis of purines and pyrimidines, and in mutual conversion between amino acids. Thus, folic acid has important regulative effects on neurogenesis and proliferation and differentiation of nuclear DNA **(Hsu and Guo 2002 & Soltaninejad et al., 2003).**

In our study we found that, the cytoplasm of the neurons receiving folic acid is full of mitochondria but some of them are swollen, the myelinated axons has no vacuoles in the myelin sheath or shrinkage of the axoplasm. These finding are agreed by **(Sun Ah Park et al., 2000)** who found that cisplatin neurotoxicity on hybrid neurons could be prevented by using antioxidants including folic acid as the major mechanism of cisplatin toxicity depends on the generated free oxygen radicals.

Conclusion:

Folic acid can protect the developing spinal cord against cisplatin toxicity.

References

1. Amal T. Abou-Elghait, Dalia A. El-Gamal, Amal R. Abdel-Sameea and Amal A. Mohamed. (2012): Effect of Cisplatin on the Cerebellar Cortex and Spinal Cord of Albino Rat and the Possible Role of Vitamin E: Light and Electron Microscopic Study. *Egypt. J. Histol.* Vol. 33, No. 2, June, 2010: 202 – 212.
2. Apfel SC1, Arezzo JC, Lipson L, Kessler JA. (1992): Nerve growth factor prevents experimental cisplatin neuropathy. *Ann Neurol.* Jan; 31(1):76-80.
3. Apolline Imbard, Jean-François Benoist and Henk J. Blom, (2013). Neural Tube Defects, Folic Acid and Methylation. *Int. J. Environ. Res. Public Health*,10, 4352-4389.
4. Argyriou AA, Chroni E, Koutras A, Ellul J, Papapetropoulos S, Katsoulas G, Iconomou G and Kalofonos HP. (2005): Vitamin E for prophylaxis against chemotherapy-induced neuropathy: A randomized controlled trial. *Neurology* Jan 11; 64(1):26-31.
5. Authier N, Gillet JP, Fialip J, Eschalier A and Coudore F. (2003): An animal model of nociceptive peripheral neuropathy following repeated cisplatin injections. *Exp. Neurol.* Jul; 182(1):12-20.
6. Bancroft, J. D. & Gamble, M. (2002): Theory and practice of histological techniques. 5th. Ed. Edinburgh. Churchill Livingstone; pp 172-5, pp 593-620.
7. Bermans J. Iskandar, MD, Aaron Nelson, BS, Daniel Resnick, MD, J. H. Pate Skene, PhD, Peng Gao, PhD, Chenara Johnson, BS, Thomas D. Cook, PhD, and Nithya Hariharan, MD (2004): Folic Acid Supplementation Enhances Repair of the Adult Central Nervous System: *Ann Neurol*;56: 221–227.
8. Deborah Kennedy, MBA ND and Gideon Koren, MD FRCPC FACMT (2012): Identifying women who might benefit from higher doses of folic acid in pregnancy. *Canadian Family Physician* April; vol. 58 no. 4: 394-97.
9. Dillioglugil MO, Maral Kir H, Gulkac MD, Ozon Kanli A, Ozdogan HK, Acar O and Dillioglugil O. (2005): Protective effects of increasing vitamin E and a doses on cisplatininduced oxidative damage to kidney tissue in rats. *Urol. Int.*; 75(4):340-344.
10. Drury RAB, Wallington EA (1980): Preparation and fixation of tissues. In: Drury RAB, Wallington EA, editors. *Carleton's Histological Technique*. 5. Oxford: Oxford University Press; 41–54.
11. Elit L, Bocking A, Kenyon C, Natale R., (1999). An endodermal sinus tumor diagnosed in pregnancy: case report and review of the literature. *Gynecol Oncol.*; 72:123-127.
12. Giari L, Dezfuli BS, Astolfi L, Martini A (2011): Ultrastructural effects of cisplatin on the inner ear and lateral line system of zebrafish (*Danio rerio*) larvae.: *J Appl Toxicol*;32(4):293-9.
13. Hsu PC and Guo YL (2002). Antioxidant nutrients and lead toxicity: *Toxicology*, 180: 33-34.
14. Iqbal I, (2012). The Role of Folic Acid in Prevention of Neural Tube Defects Caused by High Dose Progesterone. *Turkish Neurosurgery*, Vol: 22, No: 1, 7-.
15. Jaquier M, Klein A, Boltshauser E. (2006); Spontaneous pregnancy outcome after prenatal diagnosis of anencephaly. *BJOG* 113:951–953.
16. John B. Wallingford, Lee A. Niswander, Gary M. Shaw, and Richard H. Finnell, (2013). The continuing challenge of understanding and preventing neural tube defects. *Science*. March 1; 339(6123): (6148).
17. Lin WL, Zehr C, Lewis J, Hutton M, Yen SH, Dickson DW. (2005): Progressive white matter pathology in the spinal cord of transgenic mice expressing mutant (P301L) human tau.: *J Neurocytol.*; 34(6):397-410.
18. M. J. CANO a, A. AYALA b, M. L. MURILLO and O. CARRERAS a'(2000): Protective Effect of Folic Acid against Oxidative Stress Produced in 21-Day Postpartum Rats by Maternal-Ethanol Chronic Consumption during Pregnancy and

- Lactation Period: *Free Rad. Res.*, Vol134, pp. 1-8.
19. Minami T, Ichii M and Okazaki Y. (1996): Detection of Platinum in the brain of mice treated with cisplatin and subjected to short-term hypoxia. *J. Pharm. Pharmacol.* May; 48(5): 505-509.
 20. Muller LJ, Moorer van Delft CM, Roubos EW, Vermorken JB and Boer HH. (1992): Quantitative ultra-structural effects of cisplatin (Platinol), carboplatin (JM8) and iproplatin (JM9) on neurons of freshwater snail *Lymnaea stagnalis*. *Cancer Res.* Feb 15; 52(4):963-973.
 21. Pereg D, Koren G, Lishner M (2008). Cancer in pregnancy: gaps, challenges and solutions. *Cancer Treat Rev*; 34:302–12.
 22. Quan FS, Yu XF, Gao Y, and Ren WZ. (2015): Protective effects of folic acid against central nervous system neurotoxicity induced by lead exposure in rat pups: *Genet Mol Res.* 16; 14(4):12466-71.
 23. R. C. Todd and S. J. Lippard, (2009): "Inhibition of transcription by platinum antitumor compounds," *Metallomics*, vol. 1, no. 4, pp. 280–291.
 24. Rzeski W, Pruskil S, Macke A, Felderhoff-Mueser U, Reiher AK, Hoerster F, Jansma C, Jarosz B, Stefovaska V, Bittigau P and Ikonomidou C. (2004): Anticancer agents are potent neurotoxins in vitro and in vivo. *Ann. Neurol.*; 56(3):351-360.
 25. Soltaninejad K, Kebriaeezadeh A, Minaiee B, Ostad SN, et al. (2003). Biochemical and ultrastructural evidences for toxicity of lead through free radicals in rat brain. *Hum. Exp. Toxicol.* 22:417-423.
 26. Sun Ah Park, Kyeong Sook Choi, Jung Hee Bang, Kyoong Huh, and Seung U. Kim (2000): Cisplatin-Induced Apoptotic Cell Death in Mouse Hybrid Neurons Is Blocked by Antioxidants Through Suppression of Cisplatin-Mediated Accumulation of p53 but Not of Fas/Fas Ligand: *J. Neurochem.*, Vol. 75, No. 3, 2000.
 27. Thompson SW, Davis LE, Kornfeld M, Hilgers RD and Standefer JC. (1984): Cisplatin neuropathy. Clinical, electrophysiologic, morphologic and toxicologic studies. *Cancer Oct 1; 54(7):1269-1275.*
 28. Uribe PM, Mueller MA, Gleichman JS, Kramer MD, Wang Q, Sibrian-Vazquez M, et al. (2013) Dimethyl Sulfoxide (DMSO) Exacerbates Cisplatin-induced Sensory Hair Cell Death in Zebrafish (*Danio rerio*). *PLoS ONE* 8(2): e55359.
 29. Wick A, Wick W, Hirrlinger J, Gerhardt E, Dringen R, Dichgans J, Weller M and Schulz JB. (2004): Chemotherapy induced cell death in primary cerebellar granule neurons but not in astrocytes: In vitro paradigm of differential neurotoxicity. *J. Neurochem.*; 91(5):1067-1074.

3/17/2018