

## Nebulization And Inhalation Therapy Versus Conventional Medication Of Feline Asthma

Wael, M. Kelany<sup>1</sup> And Haithem, A. M. , Farghali<sup>2</sup>

<sup>1</sup>Dept. of internal medicine, faculty of Vet. Med., Cairo University, Giza, Egypt

<sup>2</sup>Dept. of surgery, anesthesiology and radiology, faculty of Vet. Med., Cairo University Giza, Egypt  
\*[wael6kelany@yahoo.com](mailto:wael6kelany@yahoo.com)

**Abstract:** Feline asthma syndrome is a life threatening clinical condition characterized by chronic inflammation of the small passageways of the lungs. Although allergens are the prime suspect in the cause of feline asthma, the actual cause is unproven and the condition is believed to be a result of type I immediate hypersensitivity reaction to inhaled allergens. Twenty two diseased and five apparently healthy cats were thoroughly investigated in the present study. The most common clinical presentation was recurrent bouts of coughing (n=13), Cyanosed mucous membranes (n= 7), open-mouth breath (n=7), Squatting with shoulder hunched, neck extended and rapid breathing or gasping for breath (n=11), gagging up foamy mucous (n=3) and exercise intolerance (n=17). Seventeen cats underwent chest radiography. Six cases showed no patterns neither bronchial nor interstitial, nine cases showed bronchial pattern, one case suffer from severe interstitial pattern and one case showed pneumothorax in addition to bronchial pattern. A predominant eosinophilic sample was collected from only 4 cats by transtracheal lavage. There were minimal changes in differential white cell counts, except significant eosinophilia. Therapeutic plan was directed initially to control asthmatic attack either by conventional medication by injection or nebulization by bronchodilators. Then the pet maintained on oral form of conventional medication or spacer, respectively. The building stone in the present study was avoidance of putative aeroallergens. On the basis of the data of the present cases, it would appear that the diagnosis of feline asthma depends largely on the clinical presentation and radiographic findings. The present study concluded that nebulization and inhalation therapy were more effective and rapid therapy than conventional medication. (n=number).

[Wael, M. Kelany And Haithem, A. M., Farghali. **Nebulization And Inhalation Therapy Versus Conventional Medication Of Feline Asthma.** Nature and Science 2011;9(4):20-27]. (ISSN: 1545-0740). <http://www.sciencepub.net>.

**Keywords:** Nebulization, inhalation, conventional, radiography, feline, asthma.

### 1. Introduction:

Feline asthma is a chronic inflammation of small lung passageways (Dye et al, 1996; Johnson, 2000; Drowling, 2001; Gardner, 2005; Cohn et al, 2010). Asthma has been referred to in the literature by a variety of terms including eosinophilic bronchitis, allergic bronchitis, feline bronchitis, feline bronchial asthma, Allergic airway disease, feline chronic obstructive pulmonary disease (Dye and Moise, 1992; Padrid, 2000 and Gardner, 2005). Feline asthma is very similar to humane asthma (Padrid et al, 1995; Gardner, 2005). When an asthma attack occurs, these passageways thicken and constrict, making it very difficult for a cat to breath (Padrid, 2000a). This often leads to respiratory distress, which can become grave in matter of minutes. The lungs may also begin to discharge mucus into the airways, leading to fits of coughing and wheezing (Dye, 1992).

The prevalence of lower airway diseases in the adult cat populations has been estimated to be approximately 1%. Although any breed may be affected, Siamese cats appear to be over-represented (Moise, 1989; Padrid, 1996, Adamama-Moraitou et al 2004; Hibbert, 2010). Feline asthma has been recognized as a clinical entity for over 100 years and is a common cause of coughing and dyspnoea (Hill,

1906????). Asthma has been defined as a disorder of the lower airways that causes airflow limitation, which may resolve spontaneously or in response to medical treatment (Padrid, 2009). Asthma is thought to be due to a type I hypersensitivity reaction to inhaled allergens. It is characterized by eosinophilic airway inflammation, spontaneous bronchospasm and airway remodeling. Young to middle aged cats are most commonly affected (Adamama-Moraitou et al., 2004; Corcoran et al, 1995).

An asthmatic attack can range from mild to severe. In mild cases the cat may suffer bouts of coughing, wheezing and labored breathing that come and go, (can sometimes be mistaken for trying to fetch up a hairball). With a severe attack, the cat will have extreme respiratory problems that can, in some, be life threatening (Corcoran, et al, 1995; Padrid, 2000b). So, any coughing cat needs veterinary evaluation (Gardner, 2005). Clinical signs of asthma in cats included bouts of coughing, wheezing, persistent cough, Squatting with shoulder hunched, neck extended, rapid breathing or gasping for breath, gagging up foamy mucus, open mouth breath, blue lips and gums, labored breath after exertion, overall weakness and lethargy (Dye et al, 1996; Gardner,

2005; Reiner et al; 2009). Heartworm test should be done if the cat lives in an area endemic for heart worm diseases (Leib and Monroee, 1997).

The most common radiographic feature identified is a bronchial pattern, characterized by bronchial wall thickening and mineralization (doughnuts and tramlines). Hyper-inflation of the lung fields and flattening of the diaphragm may be identified, due to air trapping. Interstitial and focal alveolar patterns may also be seen, hypothesized to be due to airway obstruction by mucus plugs, causing local atelectasis; the right middle lung lobe is most frequently affected. Gas within the esophagus and gastro-intestinal tract may be seen, as a consequence of aerophagia. Pneumothorax may occasionally be identified; however is a rare complication of feline asthma (Cooper et al, 2003). It is very important to remember that up to 16% of affected cats may have no or only very subtle radiographic changes (d'Anjou et al, 2007).

Unfortunately, feline asthma is a chronic progressive disease that cannot be fully cured. Medications can reduce the symptoms of asthma a great deal, but may not be able to eliminate coughing fully. In recent years, veterinarians have found that the most effective therapy for feline asthma may be to use inhalers such as human asthmatics use. A mask and spacer system, called AeroKat®, has been invented to enable cats to use inhalers or puffers. This system is similar to the mask and spacer system used to treat babies and small children (Kirschvink et al, 2006; Cohn et al, 2010; Hibbert, 2010).

## 2. Materials and Methods

A total number of 22 clinically affected and 5 apparently healthy cats were admitted to the Vet. Clinic of surgery, anesthesiology and radiology department, faculty of veterinary medicine, Cairo University; and private Vet. clinics in Giza governorate. History, clinical presentation, physical examination, complete blood count and radiographic examination were used to confirm clinically affected cats with feline asthma. All cats were thoroughly investigated including age, gender, breed, respiratory rate/ min, pulse rate/ min, rectal temperature (°C), lymph nodes, mucous membranes and physical examination by percussion and auscultation of chest according to Kelly (1984).

Blood samples were collected from anterior median artery. Complete blood count (CBC) was performed for all blood samples with standard techniques described by Feldman et al (2000). The CBC included red blood cells (RBCs) count, hemoglobin (Hb) concentration, packed cell volume (PCV), red cell indices (mean corpuscular hemoglobin concentration (MCHC), Mean

Corpuscular Volume (MCV)) as well as total (TLC) and differential leukocyte count (DLC).

Chest radiographs:

Seventeen cats underwent chest radiography, they were not sedated and a ventro-dorsal and a right lateral view were performed. A scoring system according to (Foster et al, 2004 and Kirschvink et al, 2006) ranging for the total combined score from 0 to 6 aimed to evaluate separately bronchial pattern (0: absence of signs, 1: mild [first generation of bronchi visible], 2: moderate [second generation visible], 3: severe [third generation visible]) and interstitial pattern (0: absence of signs, 1: mild [mild interstitial framework visible], 2: moderate [interstitial framework distinguishable from a bronchial pattern], 3: severe [clearly apparent interstitial pattern]). The five other cats with normal radiographic findings were used as a control group.

The clinically affected cats were divided into 2 groups according to therapeutic approach. Firstly, Cats presented in severe asthma required emergency treatment. All stressful procedures such as restrain for injections or radiographs should be avoided until the cat is stable. The first group consisted of 10 clinically affected cats treated traditionally (conventional medication) using initially a single dose of injectable corticosteroids and bronchodilators then maintained on tablet form of corticosteroids and bronchodilators. The second group consisted of 12 clinically affected cats managed by nebulization initially and maintained on inhalers using spacer. The 2 groups managed as follow:

I) The first group consisted of 10 clinically affected cats treated traditionally (conventional medication). Initial emergency treatment consisted of 0.5 ml/ kg Bwt of Aminophylline® ampoules (Aminophylline as injectable bronchodilators, 125mg/ 5ml/ ampoule, by Alex pharmaceutical company) and 0.25 ml/ Kg Bwt of dexamethasone® ampoule (dexamethasone sodium phosphate as injectable corticosteroid, 8 mg / ampoule/ 2ml, by Memphis pharmaceutical company). Then cases maintained on a third of tablet/ 5 kg Bwt of Quibron® once at night (anhydrous theophylline, as tablet form of bronchodilators, 300 mg/ Tablet Bristol- Mayer Squibb) and tablet/ 5 kg Bwt / 12 hrs of Prednisolone® tablet (prednisolone, 5mg/ tablet by Adco pharmaceutical company). The dose decreased gradually after clinical improvement. This application was described by Leib and Monroee (1997).

II) The second group consisted of 12 clinically affected cats managed by nebulization (using FLO or aerosol delivery system, Piston Compressor system for aerosol therapy made in Italy by CA- MI) initially and maintained on inhalers using

spacer (Averro-spacer or valved holding chamber with pediatric mask for use with metered dose inhalers; Made in Egypt by AVERROES Pharma) in addition of oral one third of a tablet/ 5 kg Bwt of Qibron® once at night (unhydrous theophylline, as tablet form of bronchodilators, 300 mg/ Tablet Bristol- Mayer Squibb). 0.5 ml of Farcolin® solution (Salbutamol soln. 0.5 mg/ ml by Pharco) mixed with 1.5 ml of Saline® soln. (0.9 % Nacl soln., by Otsuka) then used in nebulizer. Cats maintained on 7 puffs of Clenil compositum® as inhaler (Salbutamol 100 µg and Beclomethasone dipropionate 50 µg / dose; 200 doses by Cheisi). The doses decreased gradually according to clinical improvement. This method was described by Gardner (2005) and Cohn (2010). Clinical improvement detected by monitoring of clinical status, physical examination and radiographic examination.

History of parasitic control and vaccination was collected. All cats were dosed one tablet for each 4 kg Bwt of Drontal (20mg Praziquantel and 230 mg Pyrantel Embonate made in Germany by Bayer Healthcare) as broad spectrum anthelmintic. Also cats were vaccinated against Chlamydia psitacci, Feline Parvo virus, Feline calici virus and Feline Rhinotracheitis virus (vaccine of Schering pharmaceutical company).

Fecal examination is simple, quick, inexpensive and one of the most important diagnostic procedures to exclude parasitic infestation of lungs and intestines. Examination of a fresh fecal saline smear was yield a diagnosis in some cases. Several drops of saline can be applied to fresh thin fecal smear, a coverslip added, the slide examined microscopically according to Leib and Monoroe (1997).

Transtracheal lavage in cats was performed by Transtracheal approach. Transtracheal techniques were performed by clipping and shaving of hair over triangular area of cricothyroid ligament. The skin prepared aseptically using Betadine® antiseptic solution (Povidone iodine by Mundi pharmaceutical company). Stabilization of trachea was done by one hand then needle of jugular catheter (18 guge needle) was inserted by other hand. The needle was advanced slightly into tracheal lumen. Twelve ml syring attached to the catheter containing 2-4ml of sterile saline was injected and aspirated quickly back into the syringe at time of cough. Adequate amounts of fluid (1-2 ml) should be aspirated for cytological evaluation. Direct smears examined on microscope slides for cytological evaluation according to Padrid

et al (1991); Leib and Monoroe (1997).

Statistical analysis was performed by statistical Package for Social Sciences (SPSS). Mean and standard deviation are descriptive values for quantitative data. ANOVA (Analysis Of Variance) was used for testing means of more than two groups by computer program according to the method described by Irwan (1996).

### 3. Results:

#### 1-Apparently healthy cats:

Apparently healthy cats were 5 cats of age ranged from 6 months to 12.7 years old (2 females and 3 males) without any apparent clinical signs of feline asthma and of normal laboratory data and normal X-ray. The breeds of apparently healthy cats were 3 Persian cats and 2 Siamese cats.

#### 2-Clinically affected cats:

This group was consisted of 22 clinically affected cats of age ranged from 5 months to 7.8 years old (14 females and 6 males). The breeds of the affected cats in the present study were 13 Persian cats, 7 Siamese cats and one Himalayan cat. The investigated cats revealed significant changes of respiratory, pulse rates and cyanosed mucous membranes in 7 cats. There was a panorama of clinical presentation including open-mouth breath with lateral recumbency in some cats (n= 7), bouts of coughing or persistent cough (n= 13), Squatting with shoulder hunched, neck extended and rapid breathing or gasping for breath (n= 11), gagging up foamy mucus (n= 3), overall weakness or exercise intolerance (n=17), retching and vomiting occur in 3 cases at the end of a coughing episode (figures 1A, 2A, 3A).

Physical examination of cats with bronchial disease was yield normal results between episodes (n= 5), although most cats have expiratory wheezes (n=14) on thoracic auscultation. In severe cases no breath sounds may be heard (n=7). There were significant (P ???)changes in respiratory and pulse rates (table 1)

On the basis of our findings, age, gender and breed of cats with feline asthma were not significantly different from those of cats without feline asthma or control cases.

#### Chest Radiographs

According to Foster et al, 2004 and Kirschvink et al, 2006 scoring system, the seventeen radiographic examined cats were classified as in table (3).

**Table (1): General clinical examinations of apparently healthy and clinically asthmatic cats (Mean ± SE )**

Parameters	Clinically healthy cats	Clinically asthmatic cats
1-Respiratory rate (No./min)	32.6 ± 1.21	57.90 ± 2.69**
2- Pulse rate (No. / min)	93.00 ± 1.76	162.73± 6.21**
3- Rectal temperature (° C)	38.52 ± 0.10	38.35± 0.09
4- Mucous membranes	Very faint rosy red	Cyanosis in 7 cats and pallor mm in 15 cats
5- Superficial lymph nodes	Free	Free

\*\* There were significant increase of respiratory and pulse rates in clinically asthmatic cats.

**Table (2): Hematological studies Complete blood count was normal except significant esinophilia.**

Parameters	Unit	Control cats	Asthmatic cats
RBCs count	X 10 <sup>6</sup> /μL	6.43 ± .0.10	5.11 ± 0.23**
PCV	%	40.80 ± 0.32	39.38 ± 0.39
Hb concentration	g/dl	12.45 ± 0.12	11.06 ± 0.32*
MCV	fl	63.47 ± 0.83	75.29 ± 3.05
MCHC	g/dl	30.52 ± 0.21	28.04 ± 0.55*
TLC	X 10 <sup>3</sup> /μL	8.72 ± 0.06	9.45 ± 0.43
Neutrophils	X 10 <sup>3</sup> /μL	5.46 ± 0.07	5.60 ± 0.24
Lymphocytes	X 10 <sup>3</sup> /μL	2.30 ± 0.03	2.36 ± 0.13
Monocytes	X 10 <sup>3</sup> /μL	0.52 ± 0.02	0.45 ± 0.05
Esinophils	X 10 <sup>3</sup> /μL	0.44 ± 0.03	1.05 ± 0.06**

\* = P < 0.05 \*\* = P < 0.01

**Table (3): Classification of the seventeen radiographic examined cats according to Foster et al, (2004) and Kirschvink et al, 2006 scoring system:**

The score		Description of the pattern	number
Bronchial pattern	0	absence of signs	6
	1	mild [first generation of bronchi visible]	-
	2	moderate [second generation visible]	2
	3	severe [third generation visible]	7
Interstitial pattern	0	absence of signs	6
	1	mild [mild interstitial framework visible]	-
	2	moderate [interstitial framework distinguishable from a bronchial pattern]	-
	3	severe [clearly apparent interstitial pattern]).	1

From this table we can see that six cases showed no signs neither bronchial nor interstitial. While nine cases showed bronchial pattern (two moderate and seven severe, Fig. 1B). In the other hand there was one case suffer from severe interstitial pattern (Fig. 2B). One case showed pneumothorax in addition to bronchial pattern (Fig. 3B).

#### Therapeutic Approach:

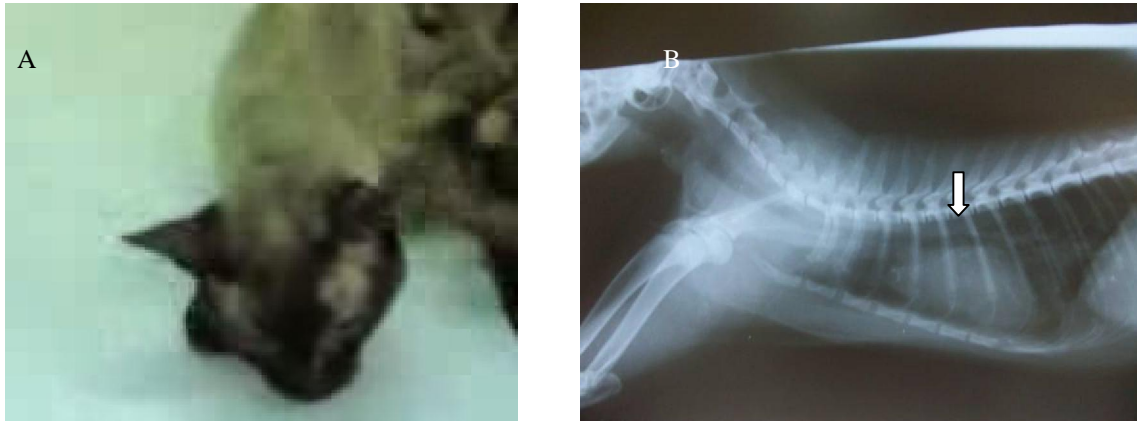Improved cases in nebulization and inhalation therapy represented 83% but dead cases represented about 17%. While improved cases in conventional medication represented 50% and dead cases were

50%.(fig. 4 A & B)

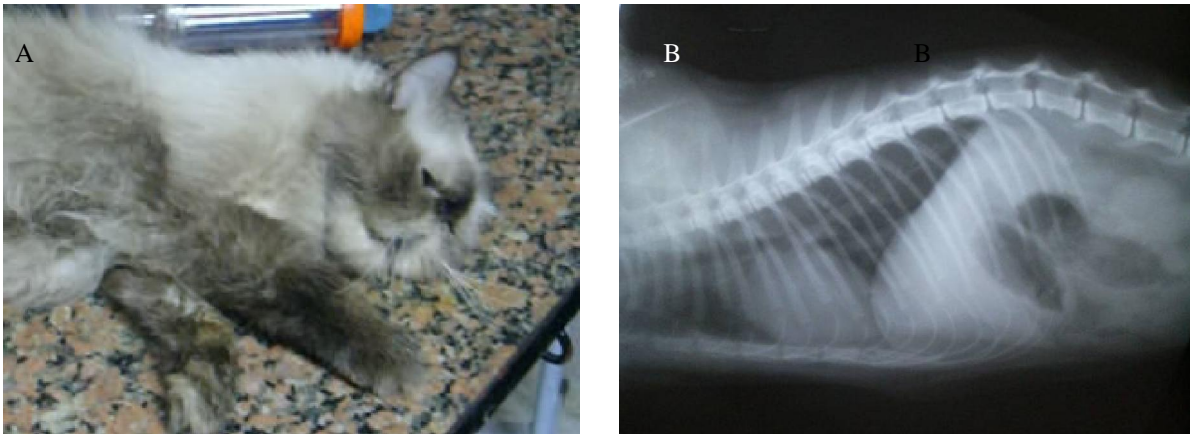
Cases	Nebulization and inhalation therapy		Conventional medication	
	Improved cases	Dead cases	Improved cases	Dead cases
Number and Days	10 cases out 12 improved within 10-17 days	2 cases within first 2 days of therapy	5 cases with 12-24 days	5 cases dead within first week of treatment

Fecal examination revealed negative samples except 2 samples contained *Eimeria* oocysts. Transtracheal lavage revealed large numbers of esinophils.

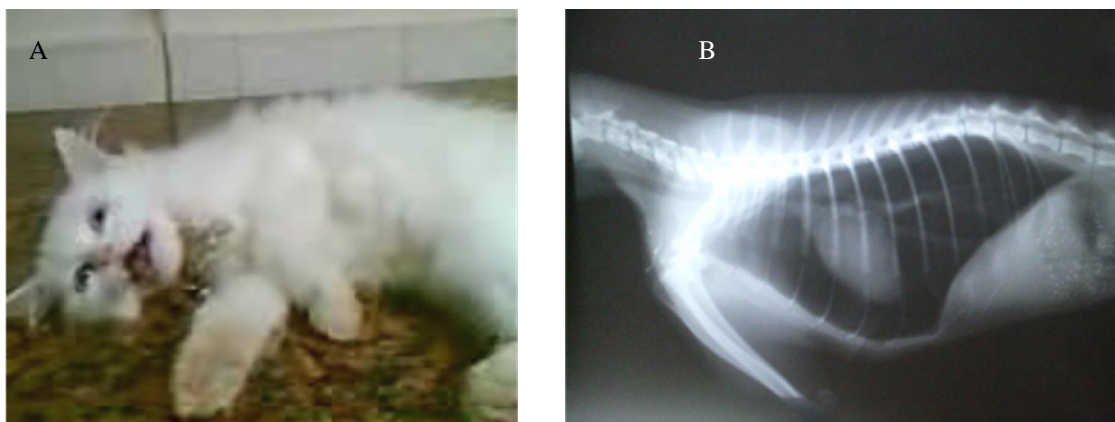





**Fig (1): (A) Three years and six months old Siamese queen showed marked respiratory distress and squatting position with shoulder hunched and extended head and neck to catch its breath. (B) Right lateral view plain x-ray film of the same case showed bronchial pattern mainly in the right middle lung lobe (White arrow).**



**Fig (2): (A) Two years and two months old apathic Himalayan tom cat displayed gasping of air. (B) Right lateral view plain x-ray film of the same case showed bronchial wall thickening and mineralization (doughnuts and tramlines), local atelectasis and clearly apparent interstitial pattern.**



**Fig (3): (A) Six months female Persian kitten showed open mouth breath with overall weakness (lateral recumbency). (B) Right lateral view plain x-ray film of the same case showed bronchial wall thickening and hyper-inflation of the lung fields (pneumothorax).**



**Fig (4): (A) The same Himalayan tom cat in Fig. 2 initially treated (emergently) by nebulization using saline® and bronchodilator (Farcolin®). (B) Then maintained on spacer using bronchodilator and corticosteroid (Clenil compositum® spray).**

#### 4. Discussion

Feline asthma syndrome is a life threatening condition (Corcoran et al, 1995; dye et al, 1996). When the cat has asthma, the small passageways of the lungs were thickened, and collapsed when the cat inhales, making it difficult for the pet to catch its breath. In severe cases, there were coughing, exercise intolerance, open-mouth breath and cyanosis of mucous membranes. In these cases, large numbers of bronchioles plug mucus and smooth muscle that surrounds these tubes go into spasm restricting breathing (Corcoran et al, 1995; Johnson, 2000; Padrid, 2000a). Cats during acute asthma attack have very hard time breathing. They assume a praying position and concentrate on obtaining the air they need in deliberate breaths. These breaths are deep, labored and abdominal.

Intrathoracic airway obstruction may be due to bronchial smooth muscle hypertrophy, increased mucus production, bronchial inflammation and edema, leading to bronchoconstriction. Bronchial obstruction prevents movement of air out of the lower airways during expiration, which can lead to air trapping and subsequent emphysema and pneumothorax (rare) (Leib and Mnoroe, 1997; Padrid, 2000a). Pneumothorax was recorded in one case in the present study which parallel to the results of Cooper et al (2003) who reported pneumothorax as a complication of feline asthma in 5 cats out of 421 cases (1.2 %). These changes are associated with severe clinical manifestations that often do not respond to treatment

Other cats have only a mild cough or high pitched wheeze that comes and goes. From the present study, it is estimated that very low percent of cases of feline asthma were recorded in Persian cats which is the common breed reared in Egypt. Padrid (1996), Gardner (2005) and Hibbert (2010)

concluded that feline asthma represents one percent of feline diseases although this percent could be increasing. The incidence of the disease is highest in Siamese cats.

Episodes of asthma are triggered by inhalation of allergens in the air or by stress. Some common allergens are grass and tree pollens, smoke, fumes, Cigarettes, mold, polish, dust mites, dust, potpourri, paint, carpeting, feather pillows, aerosols of various sorts such as perfumes, deodorants and flea spray. Heat, cold and exertion can all trigger an attack (Dye, 1992; Padrid et al, 1995; Adamama-Moraito et al; 2004 Padrid, 2009). Food can cause allergic reactions in cats even if the food has been fed for years. Sensitivity to the food ingredients may last forever and must be omitted from the diet permanently. Common food ingredients that cause asthma symptoms included wheat, milk, gluten, tuna, and the preservatives added to cat food.

In the present study, feline asthma confirmed by the marked clinical presentation specially in severe cases. The asthmatic cat is bought by little restrain to X-ray tray to avoid stress which may be the end of life of severely asthmatic cat. As it may result in the release of stress hormones which in turn led to bronchoconstriction which aggravate the case.

Frequently, radiographs may demonstrate diffuse prominent bronchial markings consistent with inflammatory airways. Radiographic signs of increased lung lucency and flattening and caudal displacement of the diaphragm represent hyperinflation and suggest air trapping. It is worth recalling that the feline heart sits in the mid thorax because of the presence of inflated lungs on either side. When a lung lobe collapses and the lung volume decreases, the heart may shift its position within the thorax to take over this new space. Thus, a mediastinal shift is evidence of atelectasis rather than

consolidation. In more extreme cases, you may appreciate fluffy ill defined heavy interstitial infiltrates in multiple lung lobes. The cause of these changes in cats with lower airway disease is apparently due to multiple small areas of atelectasis in multiple lung lobes resulting from multiple diffuse small mucus plugs.

Feline asthma must be differentiated from other diseases of the same clinical manifestations. Firstly, the present study rule out cardiac cough by physical examination and absence of cardiac murmurs or gallop rhythm. Pleural diseases also differentiated by absence of muffled respiratory or cardiac sounds. Although bronchial asthma is confirmed by the results of a complete blood counts, fecal floatation, thoracic radiography. Eosinophilia is identified in approximately 20% of cats with bronchial disease. Stool analysis was used to exclude Paragonimiasis and Aleurostrongylosis (Corcoran et al, 1995; Dye, 1996; Foster, 2004; d'Anjou et al, 2007)

Saline can be used to wash cells from deep within the lungs for a microscopic examination (transtracheal wash). The presence of large numbers of eosinophil white blood cells is characteristic of the disease. Stool analysis excluded parasitic agents that cause eosinophilia. So, the present study denoted hypersensitivity reaction (mostly immediate type I). These findings were in parallel with the results of significant eosinophilia in the present hematological studies. We must capture the incriminated aeroallergens as the etiology of asthma.

From the present data, clinical improvement in nebulization and inhalation therapy is more obvious in cases with severe asthmatic attacks. As Salbutamol and Beclomethasone dipropionate directed into the target organ and exerted its action rapidly. It was resulted in the solution of rigid asthma except in 2 cases. Only 2 dead cats attributed to marked bronchial obstruction which prevent air movement (Leib and Monroee, 1997; Foster et al, 2004). While conventional medication could solve 50% of mild to moderate cases. But it failed to treat 50% of severe cases of feline asthma as bronchial asthma cannot be cured by injectable and tablet form due to severe bronchoconstriction.

Feline asthma in our study was confirmed and differentiated with other diseases of the same manifestations by clinical presentation, findings of thorough clinical examination, x-ray, complete blood count and transtracheal lavage. From the present study, nebulization and inhalation therapy is more rapid, effective and cheapest than conventional medication. The percent of cure in nebulization and inhalation therapy was 83% while in conventional medication was 50%. Although nebulization and inhalation therapy is more effective, the conventional

medication is easier in application. This is because a short period is required to restraint asthmatic cats for injection or oral medication while nebulization and inhalation therapy needs more time (Gardner,2005; Kirschvink et al, 2006; Padrid, 2006; Reinero et al, 2009; Cohn et al, 2010; Hibbert, 2010).

## 5. Conclusion:

Allergens are the main culprits in feline bronchial disease. The present panorama of diagnostic approach depends mainly on clinical presentation and radiographic examination. The present study concluded that nebulization and inhalation therapy were more effective and rapid therapy than conventional medication as it is directed to the target organ.

## Corresponding author

Wael, M. Kelany

Dept. of internal medicine, faculty of Vet. Med., Cairo University, Giza, Egypt

[wael6kelany@yahoo.com](mailto:wael6kelany@yahoo.com)

## 5. References:

- 1- ADAMAMA-MORAITOU, K., M. PATSIKAS; A. KOUTINAS .2004. Feline lower airway disease: a retrospective study of 22 naturally occurring cases from Greece. *Journal of Feline Medicine and Surgery*, 6: 227-233.
- 2- COHN, LA, A.E. DECLUE; R.L.; C.R. REINERO .2010. Effects of fluticasone propionate dosage in an experimental model of feline asthma. *J. Feline Med. Surg.*, 12 (2): 91-96.
- 3- COOPER, E.S., R.S. SYRING; L.G KING .2003. Pneumothorax in cats with a clinical diagnosis of feline asthma: 5 cases (1990-2000). *Journal of Veterinary Emergency and Critical Care*, 13 (2): 95-101.
- 4- CORCORAN, B.M., D.J. FOSTER, V.L. FUENTES .1995. Feline asthma syndrome: A retrospective study of clinical presentation in 29 cats. *J. Small Anim. Pract.*, 36: 481- 488.
- 5- D'ANJOU, M.A., J.GADBOIS; M. DUNN; G. BEAUREGARD; J. D'ASTUS .2007. Feline asthma: prevalence of radiographic findings. *Journal of Veterinary Radiology and Ultrasound*, 48 (2): 164.
- 6- DROWLING, P.M..2001. Options for treating feline asthma. *Vet. Med.* 353- 365.
- 7- DYE, J.A. .1992. Feline bronchopulmonary disease. *Vet. Clin. North. Am. Small Pract.*, 22 (5): 1187-1201.
- 8- DYE, J.A., B.C. MCKIERNAN; E.A. ROZANSKI; ET AL .1996. Bronchopulmonary disease in the cat: Historical, physical,

- radiographic, clinicopathologic, and pulmonary functional evaluation of 24 affected and 15 healthy cats. *J. Vet. Intern. Med.*, 10 (6): 385-400.
- 9- DYE, J.A., NS MOISE .1992. Feline bronchial disease In: Kitk, R.W.; Bonagura, J.D., eds. *Kirk's Current Veterinary Therapy XI*. Philadelphia, W.B. Saunders, 802-811.
  - 10- FELDMAN, B.F., J.C. ZINKL, N.C. JAIN .2000. *Schalm's Veterinary Hematology*. 5<sup>th</sup> ed., Lippincott Williams and Wilkins, Philadelphia, U.S.A.
  - 11- FOSTER, S.F., G.S. ALLAN; P. MARTIN; I.D. ROBERTSON; R. MALIK .2004. Twenty-five cases of feline bronchial disease (1995-2000). *Journal of Feline Medicine and Surgery*, 6: 181-188.
  - 12- GARDNER, S.Y..2005. Feline asthma. World Small Animal Veterinary association, World Congress proceedings.
  - 13- HIBBERT, A..2010. Therapy for feline asthma. ESFM pre-BSAVA feline symposium Wednesday 07 April 2010: 18-25.
  - 14- HILL, J. .1906. Diseases of respiratory organs. In: Jenkins, W.R editors: *The diseases of the cat*, New York, 11-21.
  - 15- IRWAN, T.M. .1996. In *Applied Linear Statistical models*, Neter, Kutner, Neachtsheim Wasserman. Fourth edition.
  - 16- JOHNSON, L. .2000. Diseases of the bronchus. *Textbook of Veterinary Internal Medicine*, 5<sup>th</sup> ed. Philadelphia: W.B. Saunders Co., 1055- 1061.
  - 17- KELLY, W.R. (1984): *The thorax*. *Textbook of Veterinary Clinical Diagnosis*, Third edition; 143-185.
  - 18- KIRSCHVINK N., LEEMANS J., DELVAUX F., SNAPS F., JASPART S., EVRARD B., DELATTRE L., CAMBIER C., CLERCX C. AND GUSTIN, P. .2006. Inhaled fluticasone reduces bronchial responsiveness and airway inflammation in cats with mild chronic bronchitis. *Journal of Feline Medicine and Surgery*, 8: 45-54.
  - 19- LEIB, M.E., W.E. MONROE .1997. Feline bronchial disease. *Practical Small Animal Internal Medicine*, W.B. Saunders company, 1167-1169.
  - 20- MOISE, N.S., D. WIEDENKELLER; A.E. YEAGER; ET AL .1989. Clinical, radiographic, and bronchial cytological features of cats with bronchial disease: 65 cases (1980-1986). *J. Am. Vet. Med. Assoc.*, 194: 1467-1473.
  - 21- PADRID, P. .2006. Use of inhaled medications to treat respiratory diseases in dogs and cats. *J. Am. Anim. Hosp. Assoc.*, 42 (2): 165-169.
  - 22- PADRID, P.A. .2000a. Feline asthma. Diagnosis and treatment. *Vet. Clin. North Am. Small Pract.*, 30 (6): 1279-1293.
  - 23- PADRID, P.A., B.F. FELDMAN; K. FUNK; ET AL .1991. Cytological, microbiological and biochemical analysis of bronchoalveolar lavage fluid obtained from 24 healthy cats. *Am. J. Vet. Res.*, 52: 1300.
  - 24- PADRID, P.A., P. COZZI; A.R. LEFF .1996. Cyclosporine A inhibits airway reactivity and remodeling after chronic antigen challenge in cats. *Am. J. Respir. Care Med.*, 154: 1812- 1818.
  - 25- PADRID, P.A., S. SNOOK; T. FINUCANE; ET AL .1995. Persistent airway hyperresponsiveness and histological alterations after chronic antigen challenge in cats. *Am. J. Respir. Crit. Care Med.*, 151: 184- 193.
  - 26- PADRID, P.A..1996. Animal models of asthma. In Ligett S.B., Meyers D.A., editors: *The genetics of asthma: lung biology in health and disease*, New York, Marcel Dekker, 211.
  - 27- PADRID, P.A..2000b. Pulmonary diagnostics. *Vet. Clin. North Am. Small Pract.*, 30 (6): 1187-1206.
  - 28- PADRID, P.A..2009. Chronic bronchitis and asthma in cats. In Bonagura J.D., Twedt D.C. editors: *Kirk's Current Veterinary therapy XIV*, St Louis, Elsevier Saunders, 650-658.
  - 29- REINERO, C.R.; C. DELGADO; C. SPINKA; A.E. DECLUE; R. DHAND .2009. Enantiomer-specific effects of albuterol on airway inflammation in healthy and asthmatic cats. *Int. Arch. Allergy Immunol.*, 150 (1): 43-50.

2/1/2011