

The Impact of Silicone Frontalis Suspension with Ptosis Probe R for the Correction of Congenital ptosis on the Asian Eyelids in Taiwan

Chi-Ting Horng^{1,2}, Han-Yin Sun³, Ming-Liang Tsai⁴, Shang-Tao Chien⁵, Feng-Chi Lin^{1*}

¹Department of Ophthalmology, Kaohsiung Armed Force General Hospital, Kaohsiung, 802, Taiwan ROC ;

²Department of Pharmacy, Tajen University, Pintung, 907, Taiwan ROC; ³School of Optometry, Chung-Shan Medical University, Taichung, 402, Taiwan ROC; ⁴Department of Ophthalmology, Tri-Service General Hospital, Taipei, 114, Taiwan ROC ; ⁵Department of Pathology, Kaohsiung Armed Force General Hospital, Kaohsiung, 802, Taiwan ROC
h56041@gmail.com

Abstract — To evaluate the basic technique of Ptosis probe^R and the impact of ptosis repair by silicone rod frontalis sling on the Asian eyelid. A retrospective interventional study including 30 patients (49 eyelids) who underwent silicone rod frontalis suspension by the same surgeon between 2005 and 2008. Cosmetic outcomes, marginal reflex distance (MRD), chin-up head posture and recurrence rate were evaluated. In all patients, MRD increased an average of 1.2 ± 1.5 mm after the operation ($P < 0.05$). The score of cosmetic outcomes was 0.6 ± 0.4 (the most of the operated eyelids achieved to good-to-excellent final lid height). The rate of chin-up head posture decreased from 33.3% to 6.6% ($P < 0.05$). Transient punctate keratopathy without corneal infection occurred postoperatively in 9 (18%) of 49 eyes. Extrusion of the sling node with or without infection occurred in 2 forehead. With a mean follow-up of 20.73 months (range : 6-41 months), no recurrence of the ptosis was found. Silicone rods is an effective material in frontalis suspension for the treatment of severe ptosis with poor levator function. It may increase the MRD of operated eyelid and decreased the rate of chin-up head posture. The procedure with Ptosis probe^R is easy, fast, and leads to less tissue trauma on the Asian eyelids. . [Life Science Journal. 2010; 7(2): 19 – 24] (ISSN: 1097 – 8135).

Key words: blepharoptosis, frontalis slings, silicone rod.

I. Introduction

Children with unilateral or bilateral congenital ptosis may have problems about crawling, walking and can not achieve other development milestones. It is not only healthy but also social problems.

The ideal surgical treatment and age of intervention were controversial in the management of congenital ptosis [1]. Factors including the severity of ptosis, degree of head posture, presence or absence of levator muscle function, patient age and the presence of amblyopia. Children with severe congenital ptosis are at risk of developing amblyopia. For this reason, repair of ptosis is indicated as soon as the diagnosis is made. Frontalis suspension of the upper lid is an effective and simple method of treatment [2].

Levator function is probably the most important eyelid measurement in term of surgical planning as the effectiveness of certain procedures rests solely on the integrity of levator muscle function. Frontalis suspension surgery is now well-accepted as the procedure of choice for patients (congenital or acquired etiologies) with severe ptosis and poor levator function [3]. This surgery treats the sequence of a variety of diseases, but certain entities present more different treatment challenges. For example, patients with cranial nerve III palsy and myasthenia gravis may be at greater risk for development of exposure keratopathy after surgery because of poor ocular mobility. Patients with MG may also have weak orbicularis muscles which may induce the poor closure of the eyelids and incompletely blink, thus resulting in exposure keratopathy [4]. Some progressive eyelid

disorders may need adjustment of eyelid height after the initial surgical intervention because of a progressive decrease in levator strength.

For these reasons, many suspension materials have been used. These include autogenous and preserved fascia lata [4], sclera [5], non-absorbable sutures [6], suture reinforced sclera, temporalis fascia [7], Gore-Tex strips [8] and silicone bands and rods. Our purpose of this study was to evaluate the efficacy and outcomes of silicon frontalis suspension by double pentagon. In this report, we also describe our experience using silicone sling for the correction of ptosis in Asian eyelid in Taiwan and the basic technique of Ptosis probe^R.

II. Patients and Methods

Charts of all eyes that had undergone a silicone rod frontalis sling procedure with Ptosis probe^R for correcting congenital ptosis between Feb.2005 and Dec.2008 at Department of Ophthalmology, Kaohsiung Armed Forces General hospital, Kaohsiung, Taiwan (ROC) were retrospectively reviewed. The inclusion criteria was ptosis with poor levator function (5mm or less). In total, 49 lids of 30 patients met the above criteria. All patients were victims of congenital ptosis of children. Patients selected for surgery either had ptosis obscuring the visual axis, evidence amblyopia or fixation preference, or extreme chin-up posture. All experiment protocols were conducted in accordance with the Declaration of Helsinki. Ethical approval for this study were obtained from their parents.

The data were collected including age, gender, diagnose, preoperative and postoperative marginal reflex distance.

The visual acuity, cosmetic outcomes, chin-up head posture (abnormal chin-up head posture is frequently present in infant with congenital ptosis), recurrence rate and related complications were observed in the same time.

The surgeries were all performed under general anesthesia in all patients by the same surgeon (Dr. Horng). Six skin incisions were made using a No.15 blade. Three skin incisions were made 2 mm above lash line of the upper eyelid, medially, laterally, and centrally. Two incisions, down to the level of periosteum, were made in the superior brow hair. A forehead incision approximately 1.0cm above the brow, down to periosteum, was placed midway between the two brow incisions. The Ptosis probe package contains 2 polished stainless steel guide needle probe 0.8mm in diameter and 80mm in length extended with silicone tubing 0.8mm in diameter (Fig 1). One probe was passed from the lateral brow incision to the central lid incision, posterior to the orbital septum, then to lateral lid incision at a pre-tarsal level, and back to lateral brow incision to complete a triangle (Fig 2). The other probe was passed between the medial brow and eyelid incisions in similar fashion to form a second triangle. Tie the ends of the silicone rod with a square knot and adjust the tension to reproduce a normal eyelid contour. Place the height at the limbus or just 1mm below the limbus. The two probe ends were passed to central forehead incision. The probes were then cut off. Tie the two residual silicone rods together at the forehead incision. Adjust the tension to maintain the eyelid margin contour (Fig 3). Nylon 6-0 thread was used to close the six skin incisions (Fig 4).

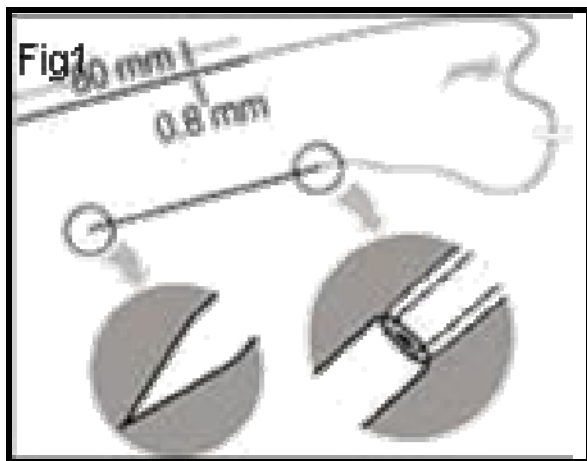


Fig 1. Ptosis probe+ silicone tubing(FCI, France)

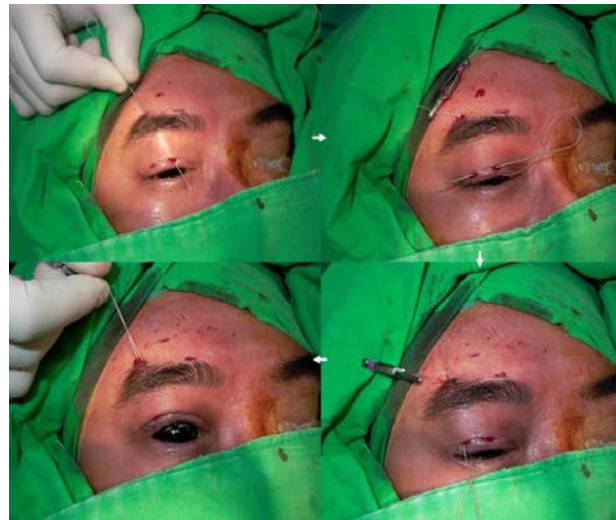

Fig. 2. Silicone frontalis sling repair of ptosis :triangle passing of silicone rod by guide needle probe from lateral brow incision to central lid incision, then lateral lid incision and back to brow incision

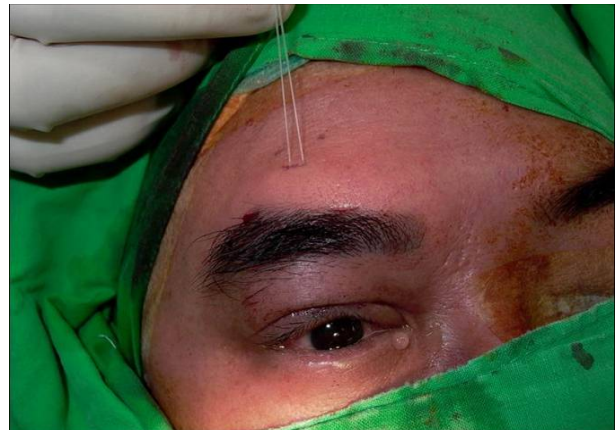

Fig. 3. Silicone frontalis sling repair of ptosis: final adjustment of lid position at frontal incision

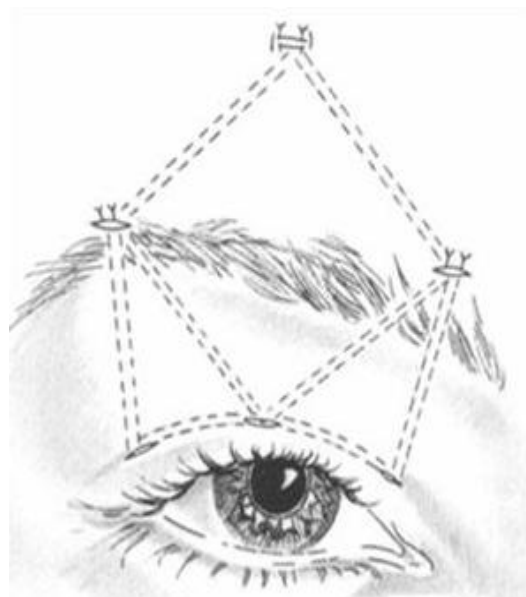


Figure 4. This figure shows the shape of the silicone loop after complete passage of silicone rod

Postsurgical evaluation were performed at 1 week, 2 week, 1 month after operation and then every three months.. The define appropriate surgical goals, a classification system was designed to assess the feature relevant to ptosis surgery, which are upper eyelid height and symmetry. Marginal reflex distance(MRD) elevation of 2 mm or greater was considered satisfactory. MRD was defined as the vertical distance measured from the corneal light reflex in primary gaze to the upper eyelid margin. The postoperative eyelid symmetry was calculated as the difference between MRD of the surgical and fellow eyelid, and was considered satisfactory if it was 1mm or less.

Postoperative cosmetic outcome was graded on a 0 to 2 scale, with 0 score indicative of excellent results, 1 as good, and 2 as poor. Outcome was defined as excellent if the eyelids were within 1 mm height between the eyelids with an acceptable crease and contour, good if there was > 1mm difference in eyelid height and/or asymmetric crease, and poor if there was poorly defined eyelids crease and contour asymmetry [9]. All patients underwent cosmetic grading of outcome. The pre- and postoperative photographs were reviewed by the same observer.

Amblyopia was defined as best-correct visual acuity of less than 20/40, and greater than 2 Snellen lines of difference between the 2 eyes. In younger patients(such as our study) amblyopia was defined by a lack of fixation in the ptotic eye compared with the nonptotic one.

In addition to lid height, the cornea was examined postoperatively for the presence or absence of a punctate keratopathy, confluent epithelial defect, corneal scar, or corneal ulcer. If any complications such as prior sling revisions, visible sling migration, infection, extrusion, suture granulomas, lagophthalmos or poor cosmetic results happened, we should record in detail.

Statistical analyses:

Statically analysis was performed with Microsoft Excel (Microsoft Corporation with Excel 2003) and SPSS (Version 1.3 ; SPSS Inc, Chicago, Illinois , USA). The independent t test is used to evaluate the data. If the $P < 0.05$, it means significantly.

III. Results

Forty-nine eyelids of thirty patients (24 males and 6 females) were operated for upper eyelids ptosis by silicon frontalis suspension (Table1). Patient age range for 20 months to 40 months old (The mean operative age is 28.77 months old.) Amblyopia was found in 16.8%(5/30), associated with strabismus was found in 10%(3/30). With a mean follow-up of 20.73 months, the final lid height was rated as cosmetic outcomes. The mean score was 0.6 ± 0.4 . In all patients, MRD increased an average of 1.2 ± 1.5 mm, from a mean preoperative 0.1 ± 0.7 mm. The rate of chin-up headache posture from preoperative 10 cases (33.3%) to postoperative 2 cases (6.6%) (Table2).

Transient punctate keratopathy occurred immediately postoperatively in 9 (18%) of 49 eyes. The keratopathy

Table 1
Demographics of study population 30 patients (49 eyelids), who Underwent Frontalis Suspension Surgery

Case	Age(Months) /Sex	Ptosis Etiology	Follow-up Time (month)	Lid Height (right/left)	Complications
1	26M.M	Congenital OU	14	good/good	Transient keratopathy. OD
2	25M.M	Congenital OU	16	good	None
3	40M.F	Congenital OU	18	good/good	None
4	24M.M	Congenital OD	18	good	Wound infection with rod exposure
5	22M.F	Congenital OD	30	good	None
6	38M.M	Congenital OU	12	good/good	Transient keratopathy. OD
7	36M.F	Congenital OU	16	good/good	None
8	36M.F	Congenital OD	20	good	Transient keratopathy. OD
9	37M.M	Congenital OU	20	good/good	None
10	30M.F	Congenital OU	34	good/good	Transient keratopathy. OS
11	40M.M	Congenital OU	20	good/good	Transient keratopathy. OS
12	24M.M	Congenital OU	22	good/good	None
13	24M.M	Congenital OS	16	good	Transient keratopathy. OS
14	30M.F	Congenital OD	22	good	None
15	32M.M	Congenital OD	20	good	None
16	27M.M	Congenital OU	40	good/good	Transient keratopathy. OD
17	26M.M	Congenital OU	16	good/good	Transient keratopathy. OD
18	28M.M	Congenital OU	18	good/good	Transient keratopathy. OS
19	30M.M	Congenital OU previous ptosis repair OD	20	good/good	good/good
20	24M.M	Congenital OU	18	good/good	None
21	20M.M	Congenital OU	24	excellent/excellent	None
22	22M.M	Congenital OU	20	excellent/excellent	Extrusion of sling. OS
23	28M.M	Congenital OU	16	good/good	None
24	26M.M	Congenital OU	16	good/good	None
25	26M.M	Congenital OU	24	good/good	None
26	36M.M	Congenital OU	18	poor/poor	None
27	27M.M	Congenital OD	22	good	None
28	28M.M	Congenital OD	24	good	None
29	25M.M	Congenital OD	18	poor	None
30	26M.M	Congenital OU. previous ptosis repair OS	24	good	uneven crease. OD

was managed with artificial tear drops and, if needed, a bandage contact lens. The epithelial disease did not result in corneal ulcers in any patient. Extrusion of the sling with or without infection occurred in two cases. During the whole follow-up time, no recurrence of ptosis was found.

Table 2
Pre- and Post-operative data in 49 eyelids

Data	Preoperative	Postoperative	P value
MRD(mm)	0.1 ± 0.7	1.2 ± 1.5	< 0.05
Chin-up head posture	10 (33.3%)	2 (6.6%)	< 0.05
Recurrence rate		0	
Cosmetic outcome		0.6 ± 0.4	

IV. Discussion:

The incidence of amblyopia associated with congenital ptosis in some retrospective chart studies were about 17-23% [10,11,12]. Children younger than 3 years of age with congenital ptosis and developmental delay or possible amblyopia can undergo frontalis suspension to achieve good visual results.

Refractor errors including astigmatism and anisometropia, and strabismus are also coexisting congenital ptosis [13]. Many previous reports had ever proved that corrective surgery may increase the MRD, lower the rate of chin-up head posture and decrease the incidence of amblyopia in children [14,20]. Our reports matched the same results.

Since 1977, repair of ptosis by frontalis muscle and fascia lata were first developed by Crawford et al [15]. Unfortunately, the fascia lata has a more permanent nature and induces scarring and loss of mobility of the upper eyelid. Some ophthalmologists tried to develop a new method of frontalis suspension to resolve the problem. The technique of correction of ptosis with poor levator function were first adopted by Tillett et al in 1966 (16). They used silicon band in frontalis suspension correction of ptosis. 6 patients who underwent silicon sling with good result after 19-24 months follow-up. They first enumerated the advantages of using silicon in frontalis slings. Silicon rod is readily available, easily adjustable and well tolerated by the surrounding tissues. The elasticity if silicon permits good upper lid height, as well as closure.

Lately Rowan et al (17) found the use of 0.8mm silicon rod fixed with a Watzke silicon sleeve to be less bulky than the no.40 band in 1977. In the same time, they reported no incidence of infection, rejection of silicone, or recurrence of ptosis after one silicone sling placement in 12 patients with up to 2 years of follow-up.

In 1978, Leone et al (18) described the suture fixation of one end of the band to the tarsus medially and one laterally. The two ends then were passed subcutaneously in a pentagonal shape to meet in the central brow region. The new method reduced the bulk of the silicon band in the lid. In 1981, Leone et al (19) further altered his procedure by using silicon rod in a pentagonal fashion with a full-lid crease incision. The same procedure as Leone in our study was adopted. The surgical procedure can performed to address ptosis easily. The mechanism of operation may create a linkage between the frontalis muscle and the tarsus of the upper eyelid, which allows for a better eyelid position in primary gaze.

Till now, silicon frontalis suspension is the first choice of surgery for congenital ptosis in younger children. In addition, the surgery is also used in cases of poor levator palpebrae superioris muscle function, neuromuscular diseases, and where linkage between the muscle and the eyelid is abnormal (such as Marcus Gunn jaw-winking phenomenon) (6).

Although many nature or artifact material had been well developed and used in the repair of ptosis, everyone all had their own weak-point. Jeong et al (21) had stiffered on form histopathological study that autologous fascia lata showed less inflammation and better incorporation with surrounding structures than the silicon. However, the silicone band showed a great deal of inflammatory reaction at 2 weeks, but the reaction gradually disappeared by 8 weeks after implantation. The elasticity of silicon permits a good upper lid aperture, as well as closure. The collagenous tissues surrounding silicon band did not have incorporation or tight bond with the

implant. So the silicon rod is readily available, easily adjustable, and well-tolerated by the surrounding tissues. Silicon rod remain a reasonable material choice for frontalis suspension surgery, especially for young children, because they may easily revised or replaced in comparison to other materials.

Silicone rods also remained a safe choice in patients risk for keratopathy.(20). Meanwhile, Jeong et al (21) found that the silicon is not incorporated with the surroundings tissue, it is best used as temporal material. Fresh autologous fascia appears to be the most suitable suspension.

Every surgery has its own gold periods. If Children < 3 years old was victim of severe ptosis, early surgery (even < 1 year old) were suggested by Saunder et al(6). Because of the autofascia lata was not harvesting, silicon rod frontalis suspension was prefer. Until 3.5 years of age, Crawford(22) et al were favorable fascia lata. Should they consider the gold time for treating amblyopia? To the most of ophthalmologists' concepts, the exact of time in plan to repair ptosis may be about 3 year of age in children.

Katowitz et al and Anderson et al (29,30) had stated that severe unilateral and bilateral congenital ptosis may result in development delay due to abnormal head posturing or amblyopia secondary to occlusion of the visual axis. For this reason, Carter(25) had strongly suggested that surgery to correct the ptosis often needs to be performed at a younger age. Frontalis suspension ptosis repair is indicated for severe ptosis with poor levator function. Fascia lata has been harvested to serve as the suspensory materials for children 3 years or older with great success. However, postoperative recurrence rate, infection and the formation of granuloma have been reported higher than silicon rod (31)

In our experiences, we prefer the use of the silicon sling in Taiwan for its versatility and for its lesser tendency to induce scar tissue around the sling(23). The ease of adjusting silicone rod slings makes it an excellent suspensory material in cases of blepharoptosis that more frequently require adjustment postoperatively. For these reasons, it become the newer material of choice for patients with MG, Cranial nerve III palsy, et al in many studies(24,25). Postoperative results are often unpredictable in patients with ptosis associated with a poor Bell's phenomenon such as chronic progressive external ophthalmoplegia (CPEO), MG, cranial nerve III palsies. The best benefit of the silicone sling is that it can be adjusted easily through the central forehead incision to reverse under-correction or over-correction.

Although the rate of complications were relatively and seldom permanent, adequate initial observation is important. The incidence of exposure keratopathy following silicon frontalis suspension can be not omitted. Van Sorge et al. (24) had reviewed 101 eyelids receiving silicon frontalis suspension and their cohort study demonstrated a 26 % risk of exposure keratopathy following operation. In the same time, the risk of major corneal complications, such as ulceration, was low (3%). They used the intensive lubrication therapy, eye packing

at night, partial conjunctival auto-grafting covering the inferior one-third of the cornea, even removal of sling. The conclusion is that the elasticity of the sling certainly is important in the prevention of corneal complication, even when putative risk factors are present. In our study, 30% (9/30) patients showed temporary punctate epithelial defect, and all the lesions improved only by lubrication therapy.

Van Sorge et al. (24) also suggest that transient superficial punctate staining was the rule for the first postoperative week or two. Even with careful postoperative use of lubricants every one to two hours, corneal abrasion may occur sometimes. However, some previous reports showed that patients with keratitis may progress into true corneal ulceration in the complication of overcorrection. Although lagophthalmos and corneal exposure are really unavoidable with any suspension procedure, in time, the exposed corneal epithelium in young children appears to adjust, provided there is careful support with lubricant drops and/or ointment during day and night (26). The possible complications of exposure keratopathy should be kept in mind in all ophthalmologists.

The other complications of repair of ptosis were under- or over-correction. No cases of under- and over-correction were encountered in our study. Lelli Jr et al (3) had ever reported that their cases needed to adjust or replace of silicon rod sling because of under-corrected (50%) and over-correction (10%). However, their patients were all victims of high risk non-congenital blepharoptosis (such as CN 3 palsy, MG and CPEO). Leone (19) demonstrated that the advantages of the use of silicon for frontalis suspension under local or general anaesthesia. It may enable the surgeon to judge the eyelid position during operation. Silicon sling are well tolerated by the surrounding tissues and allow eyelid closure because of their elasticity. Shortening of the sling allows for adjustment of eyelid position in the case of under-correction. Although the general anaesthesia were all adopted in our study, we can easily set the optimum position (the lower eyelid just cover the 1/4 upper cornea) according to our experience. Thus no extra-procedure about under-correction or over-correction were necessary.

The elasticity and ease of adjustment of the silicon rod are ideal characteristics for suspensory material used to correct severe ptosis. The ability could achieve excellent cosmetic outcome and functional outcome (27). The elasticity of the silicone also allows the patients to close their upper lids with greater ease. Preoperative patients education regarding delicate balance required between elevation the eyelid height enough to allow acuity vision, but not so high as to cause excessive exposure keratitis should help the patient accept an eyelid height that may be cosmetically suboptimal.

A pattern of gradual droop of the eyelid operated on became most obvious several years postoperatively in some literatures reviews, so call "recurrence" (28). These findings suggest that this suture material is a poor alternative to fascia lata for permanent frontalis suspension in patients with congenital ptosis.

Traditionally, the Wright fascia needle is used to thread the silicone rod.

In our study, no recurrence rate was noted after 21 months follow up in Taiwan children. In the same time, Ben Simon et al (27) mentioned the recurrence rate about 26% in Los Angeles, USA, and Lelli Jr et al (3) found the recurrence of ptosis are almost 10% in Michigan, USA. We want to investigate why the results showed the fluctuation and what is the different follow-up time as well as the region factor and race factor. We know the thicknesses of eyelids of Asian Children are thinner in USA. If the subcutaneous tissues layer of ptosis patients were thinner in Taiwan, the inflammatory reaction around the silicon should be severe (may be due to different collagen types). The biochemistry of stable scar is easy to form in children in Taiwan. It can easily explain that the more stable fixed scars may contracture the surrounding tissues and induced the postoperative lower recurrence rate in Asian eyelid.

Only two severe complications in our study were found. In case 1, a 24 months old child, signs of wound infection with rod exposure developed four months after surgery. We arranged to remove the sling right now. In case 2, a 22 months old, extrusion of the sling developed spontaneously. However, there was no evidence of infection was found. Therefore, the end of silicone rod was cut shorter and passed deep to the frontalis muscle. Finally the patient did not have evidence of recurrence and the problem of infection postoperatively.

With good elasticity and ease of postoperative adjustment, silicone rods is an ideal suspensory material. During our follow-up period, 46 lids (94%) had good-to-excellent final lid height. No eyelids became more ptotic, suggesting that the silicone rods had not lost their tensile strength or migrated out of position. Whether or not Ptosis probe^R is preferable to traditional Wright fascia needle can not be assessed by the study. With our procedure, we used a Ptosis probe^R to the silicone rod. The procedure with Ptosis probe^R is easy and fast. Compared with traditional Wright fascia needle 2mm in diameter, the Ptosis probe^R 0.8mm in diameter facilitates less tissue trauma. However, we still prepared the Wright fascia needle standby. If detachment the sling from the probe or bending of probe tip happened during insertion, the Wright fascia needle can be used to thread the sling.

Congenital ptosis may result in developmental delay due to abnormal head posturing or amblyopia secondary to occlusion of the visual axis, necessitating corrective surgery at a very young age. In our experience, the silicon rod frontalis suspension surgery may play an important role in congenital ptosis on Asian eyelids because of its efficacy and good outcome.

V. Conclusion

This is an important advantage if early correction helps alleviate associated functional, developmental and cosmetic problems of congenital ptosis. Recent studies have identified a 3 to 10% incidence of amblyopia with severe congenital ptosis.

Congenital ptosis may result in developmental delay due to abnormal head posturing or amblyopia, necessitating corrective surgery at a very young age 3-5. Silicone rods is an effective material in frontalis suspension for the treatment of severe ptosis with poor levator function. The procedure with Ptosis probe^R is easy, fast, and leads to less tissue trauma on the Asian eyelid.

References

1. Oral Y, Ozgur OR, Akcay L, Ozbas M, Dogan OK.(2010)Congenital ptosis and Amblyopia. *J Pediatric Ophthalmol Strabismus* ; 47(2): 101-4
2. Morris CL, Buckley EG, Enyedi LB, Stinnett S, Freedman SF.(2008)Safety and efficacy of silicone rod frontalis suspension surgery for childhood ptosis repair. *J Pediatr Ophthalmol Strabismus* ;45:280-8.
3. Lelli Jr. GJ, Musch DC, Fruech BR, Nelson CC.(2009)Outcomes in silicon rod frontalis suspension surgery for high-risk non-congenital blepharoptosis. *Ophthal Plast Reconstr Surg*; 25:361-5.
4. Wilson ME, Johnson RW.(1991)Congenital ptosis. Long-term results of treatment using lyophilized fascia lata for frontalis suspensions. *Ophthalmology* ; 98:1234-7
5. Bodian M.(1968)Repair of ptosis using human sclera. *Am J Ophthalmol*; 65:352-8.
6. Saunders RA,(1991)Grice CM. Early correction of severe congenital ptosis. *J Pediatr Ophthalmol Strabismus*;28:271-3.
7. Neuhaus RW, Shorr N.(1982)Use of temporal fascia and muscle as autograft. *Arch Ophthalmol*; 101:262-4.
8. Steinkogler FJ, Kuchar A, Huber E, Arock-Mettinger E,(1993)Gore-Tex soft-tissue patch frontalis suspension technique in congenital ptosis and in blepharophimosis-ptosis syndrome. *Plast Reconstr Surg*; 92:1057-60.
9. Lee V, Konrad H, Bunce C. et al.(2002)Aetiology and surgical treatment of childhood blepharoptosis. *Br J Ophthalmol*; 86: 1282-6
10. Harrad RA, Graham CM, Collin JR.(1988)Amblyopia and strabismus in congenital ptosis. *Eye(Lond)*. 2 (Pt6): 625-7.
11. Hornblass A, Kass LG, Ziffer AJ.(1995)Amblyopia in congenital ptosis. *Ophthalmic Surg* ; 26(4):334-7.
12. Dray JP, Leibovitch I.(2002)Congenital ptosis and amblyopia: a retrospective study of 130 cases. *J Pediatr Ophthalmol Strabismus*; 39(4): 222-5.
13. Stark N, Walther C.(1984)Refractive errors, amblyopia and strabismus in congenital ptosis. *Klin Monbl Augenheilkd*; 184(1):37-9.
14. Lin LK, Uzcategui N, Chang EL.(2008)Effect of surgical correction of congenital ptosis on amblyopia. *Ophthal Plast Reconstru Surg*; 24(6): 434-6
15. Crawford JS.(1977)Repair of ptosis using frontalis muscle and fascia lata: a 20-year review. *Ophthalmic Surg*; 8(4): 31-40.
16. Tillett CW, Tillett GM.(1966)Silicon sling in the correction of ptosis. *Am J Ophthalmol*; 92: 521-3.
17. Rowan PJ, Hayes GS.(1977)Silicon sling for ptosis. *South Med J*; 70: 68-9
18. Leone CR, Jr, Rylander G.(1978)A modified silicon frontalis sling for the correction of blepharoptosis. *Am J Ophthalmol*; 85: 802-5.
19. Leone CR Jr, Shore JW, Van Gemert JV.(1981) Silicon frontalis sling rod for the correction of blepharoptosis. *Ophthalmic Surg* ; 12: 881-7
20. Morris CL, Buckley EG, Enyedi LB, Stinnett S. Freedman SF.(2008)Safety and efficacy of silicon rod frontalis suspension surgery for children ptosis repair. *J Pediatric Ophthalmol Strabismus*; 45:289-8.
21. Jeong S, Ma YR, Park YG.(2000)Histopathological study of frontalis suspension materials. *Jpn J Ophthalmol*; 44:171-86.
22. Saunders RA, Grice CM.(1991)Early correction of severe congenital ptosis. *J Pediatr Ophthalmol Strabismus*; 28:271-3.
23. Bernardini FP, de Conciliis C, Devoto MH.(2002)Frontalis suspension sling using a silicon rod in patients affected by myogenic blepharoptosis. *Orbit*; 21:195-8.
24. Van Sorng AJ, Devoglaere T, Sotodeh M, Wubbels R. Paridaens D.(2010)Exposure keratopathy following silicon frontalis suspension in adult neuro- and myogenic ptosis. *Acta Ophthalmol*; 8: 1 -5.
25. Carter SR, Meecham WJ, Seiff SR.(1996)Silicon frontalis slings for the correction of blepharoptosis: indication and efficacy. *Ophthalmology*; 103:623-30.
26. Katowitz JA.(1979)Frontalis suspension in congenital ptosis using a polyfilament, cable-type suture. *Arch Ophthalmol*; 97:1659-1663.
27. Ben Simon GJ, Macedo AA, Schwarcz RM, Wang DY, Mccann JD, Goldberg RA.(2005) Frontalis suspension for upper eyelid ptosis: evaluation of different surgical designs and suture material. *Am J Ophthalmol*; 140:877-85.
28. Older JJ, Dunne PB.(1984)Silicone slings for the correction of ptosis associated with progressive external ophthalmoplegia. *Ophthalmic Surg*; 15:379-381.
29. Katowitz JA.(1979)Frontalis suspension in congenital ptosis using a polyfilament, cable-type suture. *Arch Ophthalmol* ; 97:1659-63.
30. Anderson RL, Baumgartner SA.(1980)Amblyopia in ptosis. *Arch ophthalmol*;98:1068-9.
31. Hersh D, Martin FJ, Rowe N.(2006)Comparison of silastic and backed fascia lata in pediatric frontalis suspension. *J Pediatric Ophthalmol strabismus* ; 143:212-8.