

## Review On Infectious Bursal Disease, Newcastle Disease, Marek's Disease And Avian Pox

Eyachew Ayana

Bahirdar Animal Health Investigation And Diagnostic Laboratory, P.O. Box 70, Bahirdar, Ethiopia  
[eyuelayana83@gmail.com](mailto:eyuelayana83@gmail.com)

**Abstract:** Viral diseases are posing a growing threat to the young poultry industry flourishing in the country. Infectious bursal disease, Newcastle disease, Marek's disease (MD), and Fowl pox are among the serious threats to poultry production. IBD is considered as AIDS of chicken since it severely affects the immune system of chicken. NDV is a human pathogen and the most common sign of infection in humans is conjunctivitis. Marek's disease (MD) is a lymphomatous and neuropathic disease of domestic fowl. Avian pox is a viral disease of a wide range of both domestic and wild bird species. It is a slow-spreading and characterized by the formation of proliferative lesions and scabs on the skin, and diphtheritic lesions in the upper parts of the digestive and respiratory tracts. Many viral diseases of poultry can be diagnosed on the basis of clinical signs together with post mortem findings and histopathological changes. However, confirmation of the involvement of specific viral pathogens requires specific laboratory procedures. There is no specific treatment for viral diseases of poultry. However, antibiotics are sometimes given in viral disease outbreaks to prevent secondary infection with bacteria. The most practical way to control viral diseases in poultry and prevent losses through effective biosecurity practices, timely vaccination and good hygiene accompanied by improved management is therefore of the greatest importance at all times.

[Eyachew Ayana. Review On Infectious Bursal Disease, Newcastle Disease, Marek's Disease And Avian Pox. 2024;14(4):1-12]. ISSN: 2150-1041 (print); ISSN: 2150-105X (online). <http://www.cancerbio.net> 01. doi:10.7537/marscbj140424.01

**Key words:** Avian pox, Borrel bodies, Infectious bursal disease, Newcastle disease, Marek's disease

### 1. Introduction

Ethiopia has more than 50.38 million chickens, from this about 96.9% of the chicken population consists of indigenous chickens, while the remaining 2.56% and 0.54% consists of exotic and hybrid breeds respectively (CSA, 2013). Despite, Ethiopia owned huge chicken flock; there are different constraints that hinder the productivity of the chickens. These includes: poor nutrition, poor management and prevalence of diseases in most area of the country. Among the above obstacles, the poultry diseases are the main constraints incriminated for reduction of total numbers and compromised productivity (Natnael, 2015).

Research and case reports coming from various regions of the country indicated that viral diseases are posing a growing threat to the young poultry industry flourishing in the country. In addition, the intensification and dissemination of susceptible exotic breeds to villages has been exacerbating the prevalence of poultry viral diseases. Infectious bursal disease, Newcastle disease, Marek's disease (MD), and Fowl pox are among the serious threats to poultry production (Zelege *et al.*, 2005a). However, the epidemiology and the total economic damage caused by these diseases are not fully known. Frequent outbreaks and occurrence of new strains for these viral diseases became a challenge to the poultry industry in Ethiopia (Hailu, 2012).

Infectious Bursal Disease (IBD) is a disease of an immune system. Although turkeys, ducks, guinea fowl and ostriches may be infected, clinical disease occurs solely in chickens. Only young birds are clinically affected. Severe acute diseases of 3-6-week-old birds are associated with high mortality, but a less acute or subclinical disease is common in 0-3-week-old birds. This can cause secondary problems due to the effect of the virus on the bursa of fabricius. IBD virus causes lymphoid depletion of the bursa (Minalu *et al.*, 2015). Bursectomy can prevent illness in chicks infected with virulent virus (Pattison *et al.*, 2009).

Newcastle disease (ND) is one of the major problems in village chickens in most parts of Ethiopia (Hailu, 2012). The disease has become endemic in poultry population and recurs every year inflicting heavy losses (Tadelle and Jobre, 2004). The highest rate of ND outbreaks from March to May is suggested to be associated with high rate of chicken marketing for Easter (Spradbrow, 1999). It is a sudden and severe, rapidly spreading disease of poultry characterized by rapid onset, respiratory symptoms, nervous manifestations and varying mortality (vegad, 2008).

Marek's disease is a devastating disorder affecting chickens worldwide. It is characterized by T cell lymphomas, polyneuritis, immunosuppression and,

rarely atherosclerosis (Mirtneh, 2015). In chickens, MD occurs at 3–4 weeks of age and is most common between 12 and 30 weeks of age. Clinical signs observed are paralysis of the legs and wings, with enlargement of peripheral nerves, but nerve involvement is sometimes not seen, especially in adult birds (Fenner *et al.*, 2011). MDV strains of higher virulence may also cause increased mortality in young birds of 1–2 weeks of age, especially if they lack maternal antibodies. Depending on the strain of MDV, lymphomatosis can occur, especially in the ovary, liver, spleen, kidneys, lungs, heart, proventriculus and skin (OIE, 2010).

Avian pox is a viral disease of a wide range of both domestic and wild bird species caused by the Virus of genus *Avipox virus* under the family *Poxviridae*. The disease has two forms. These are dry or cutaneous form and diphtheritic or wet form. The virus enters into the body of birds through abraded skin or bite of mosquitoes. Contaminated environment, carrier birds and mosquitoes are sources of infection. The virus can survive for long period of time in the environment. Secondary complications are common as a result of break in the continuity of the skin caused by pox lesions (Elias *et al.*, 2014).

Therefore, the objective of this seminar paper is:

- To summarize the most important viral disease of poultry in Ethiopia
- To indicate the direction of research with regard to the major viral diseases of chickens in Ethiopia.
- To forward some recommendations.

## 2. Major Viral Diseases Of Poultry In Ethiopia

### 2.1. Infectious Bursal Disease

Infectious bursal or Gumboro is an acute (sudden and severe), highly contagious viral infection of young chickens. The name Gumboro disease was given as it was first recognized in the Gumboro districts of Delaware, a state in U.S.A. and it was also called avian nephrosis because of the severe kidney damage it caused. Gumboro is a disease of the avian immune system. Gumboro virus settles in the bursa, a place where B-lymphocytes develop which later form antibodies (Vegad, 2008). The *Infectious bursal disease virus* replicates inside immature B-lymphocyte in the bursa of fabricius leading to reduced immunologic responsive of chicken (Dwight *et al.*, 2004). It is considered as AIDS of chicken since it severely affects the immune system of chicken (Minalu *et al.*, 2015).

#### 2.1.1. Etiology

Infectious Bursal Disease (IBD) is an immune system disease which is caused by a virus (*Infectious bursal disease virus*) which is a member of the genus *Avibirnavirus* of the family *Birnaviridae*. It is non-enveloped with a single-shelled icosahedral capsid that confers the virus a high resistance in the outside environment, which represents a key issue in the control of the disease (Pattison *et al.*, 2009). Two serotypes of IBDV have been identified (serotype 1 and 2); within them, antigenic variation between strains is considerable. Serotype 2 infects chickens and does not cause clinical disease or immunosuppression (Khan, 2005). Clinical disease has been associated with only serotype 1 and all commercial vaccines are prepared against this serotype. Very virulent strains of classical serotype 1 are now common and are causing serious disease in many countries (Minalu *et al.*, 2015).

#### 2.1.2. Epidemiology

*Incidence and distribution:* Birds that are 3-6 weeks age are the most susceptible to clinical disease. The IBDV is susceptible to mutation, highly resistant to heat and chemicals and can persist in faces, bedding, contaminated feed and water for up to four months in certain conditions. Mode of transmission is primarily through fecal oral route, with aerosol spread considered to be less important. There is no evidence that IBD can be transmitted in embryos or semen (Woldemariam and Wossen, 2007). *Infectious bursal disease virus* is highly host-specific. Experimental inoculation other bird species with serotype 1 viruses failed to induce any clinical sign or disease. The virus is transmitted by direct contact with excreting subjects, or indirect contact with inanimate or animate contaminated vectors (Pattison *et al.*, 2009).

#### 2.1.3. Pathogenesis

Within hours of ingestion, virus can be detected in macrophages and lymphoid cells in the caeca, duodenum and jejunum. Virus reaches the liver via the portal circulation and infects kupffer cells. Infection spreads to the bursa of fabricius where rapid replication results in a pronounced secondary viraemia and dissemination to other tissues. The main target cells are B lymphocytes and their precursors in the bursa. The major antigenic protein VP2 has been shown to induce apoptosis in infected cells. Depletion of B lymphocytes in early life results in impaired immune responses, lowered resistance to infectious diseases and ineffective responses to vaccines (Quinn *et al.*, 2002). In some birds kidneys are swollen and

may contain urate deposits. These deposits are due to blocking of the ureters by a markedly swollen bursa (Vegad, 2008).

#### 2.1.4. Clinical Signs

The incubation period is very short which range from 2 to 3 days. In acute cases, the chickens tired, prostrated, dehydrated, suffer from watery diarrhea, and feathers are ruffled. Mortality commences on the third day of infection, reaches a peak by day four, then drops rapidly, and the surviving chickens recover a state of apparent health after five to seven days. Disease severity depends on the age and breed sensitivity of the infected birds, the virulence of the strain, and the degree of passive immunity. Initial infection on a given farm is generally very acute, with very high mortality rates if a very virulent strain is involved. If the virus persists on the farm and is transmitted to successive flocks, the clinical forms of the disease appear earlier and are gradually replaced by subclinical forms. Nonetheless, acute episodes may still occur. Moreover, a primary infection may also be in apparent when the viral strain is of low pathogenicity or if maternal antibodies are present (Natnael, 2015).

#### 2.1.5. Pathology

*Gross changes:* dehydrated and darkened discoloration of the pectoral muscles, frequent hemorrhages in the thigh and pectoral muscles, increased mucus in the intestine, hemorrhages at the junction of proventriculus and gizzard, enlarged kidney, distended kidney tubules with urates, enlarged spleen with small grey foci, increase in the size of bursa of fabricius on the third and fourth day of infection bursa has prominent internal striation and creamy colored appearance (Singh *et al.*, 2006).

*Microscopic Lesion:* IBDV infections produce microscopic lesions primarily in the lymphoid tissues i.e. cloacal bursa, spleen, thymus, cecal tonsils and Hardarian gland. Degeneration and necrosis of B lymphocytes in the medullary region of the bursal follicles is apparent within one day of exposure. Depleted lymphocytes are quickly replaced by heterophils, pyknotic debris and hyperplastic reticulo-endothelial (RE) cells. By 3 or 4 post-infection, IBDV-associated lesions are visible within all bursal follicles. Necrosis and infiltration of heterophils and plasma cells occur within the follicle, as well as, the inter-follicular connective tissue. In addition, a fibroplasia the inter-follicular connective tissue may appear and

the surface epithelium of the bursa becomes involuted and abnormal (Tsegaye and Mersha, 2014).

#### 2.1.6. Diagnosis

Diagnosis is based on the age of affected bird, clinical signs and gross lesions. Rapid onset, high morbidity and mortality, rapid disappearance of the clinical signs (5-8 days) and post-mortem examination of the pathognomonic lesions, in particular of the bursa of Fabricius are the characteristics of this disease. Another important feature is the size and color of cloacal bursa, enlargement of bursa in the initial stage and then atrophies (Mandal *et al.*, 2004).

In all acute cases, the presence of bursal lesions allows for a diagnosis of IBD (Lukert and Saif, 1997). During later stages of disease, it is difficult to confirm a diagnosis of IBD by examining only shrunken and atrophied of bursa of fabricius. In birds less than 3 weeks of age or in young chickens with maternal antibodies, IBD virus infections are usually subclinical. Thus, typical clinical signs are not present and diagnosis should be supported by histopathologic study of bursa of fabricius, serologic studies (An AGID, VN or ELISA may be carried out on serum samples), or by virus isolation (Rajaonarison *et al.*, 2006). ELISA is the most commonly used serological test for the evaluation of *Gumboro virus* antibodies in poultry flock (Vegad, 2008).

#### 2.1.7. Treatment

No curative or supportive treatment has been found to change the course of Gumboro disease (Vegad, 2008).

#### 2.1.8. Economic Significance

It has been described throughout the world and its socioeconomic significance is recognized worldwide. The most economic significances of this disease are; higher mortality especially during initial outbreak, immune suppression, susceptibility and vaccination failure (Muller *et al.*, 2003).

#### 2.1.9. Control and Prevention

Due to the stable nature of the virus and the large amount of virus excreted following infection, it is practically impossible to remove all sources of infection once a rearing site has been contaminated (Jordan *et al.*, 2002). An effective bio-security program, cleaning and disinfection, depopulation following an outbreak and the practice of all-in all-out measures are important to insure the reduction in

challenge virus. IBDV is highly infectious and very resistant to inactivation therefore, despite strict hygienic measures; vaccination is inevitable under high infection pressure and mandatory to protect chickens against infection during the first week after hatch (Kaufer and Weiss, 2005).

An effective IBD prevention and control program also must involve an effective breeder and broiler vaccination programs are recommended to prevent IBD (Minalu *et al.*, 2015).

## 2.2. Newcastle Disease

This disease is the most dreaded disease and found in all ages of birds. The disease cause heavy mortality within a short span of time if no care is taken to control the disease by effective vaccination. It was first recorded for the first time in Indonesia (Newcastle) in 1926. In India, the disease was recorded for the first time in 1928 from Ranikhet town of Uttar Pradesh. Thus, it is also called Ranikhet disease (Mandal *et al.*, 2004). ND, locally known as Fengel, is a highly contagious and destructive illness of chickens that occurs almost any time of the year, inflicting heavy losses. The first documented evidence of ND in Ethiopia dates back to 1978, when an outbreak occurred in then-Eritrea in the northern part of the country (Serkalem *et al.*, 2005)

### 2.2.1. Etiology

It is caused by Newcastle disease virus (NDV) which is grouped under *Avulavirus* genus, subfamily *Paramyxovirinae* and family *Paramyxoviridae* (Nandi and Samanta, 2010). The most important *avian paramyxovirus* is *Newcastle disease virus* (NDV), also designated as *avian paramyxovirus 1* (APMV-1), which causes Newcastle disease (Quinn *et al.*, 2002).

*Paramyxoviruses* are enveloped, easily destroyed by heat, x-ray and many chemicals. Virulence and disease producing capacity may vary with the disease type (Thyagarajan, 2011). Based on the nature of disease, the disease manifests in five different forms as: (1) Viscerotropic-velogenic: per acute form affects all the internal organs. Much intensive changes are noticed in the intestine; (2) Neurotropic-velogenic: per acute form affects the nervous system. Symptoms are seen in respiratory and nervous systems; (3) Mesogenic type: moderate variety with less mortality where in symptoms of respiratory and nervous system are seen; (4) Lentogenic type: viruses which cause mild or not clearly noticeable respiratory infection; (5)

Asymptomatic enteric type: cause intestinal infection without showing any symptoms (OIE. 2012).

### 2.2.2. Epidemiology

Newcastle disease affects all birds of all ages. Humans and other mammals are also susceptible to Newcastle. In such species, it causes a mild conjunctivitis. The *Newcastle virus* can be transmitted short distances by the airborne route or introduced on contaminated shoes, caretakers, feed deliverers, visitors, tires, dirty equipment, feed sacks, crates, and wild birds. *Newcastle virus* can be passed in the egg, but Newcastle-infected embryos die before hatching. In live birds, the virus is shed in body fluids, secretions, excreta, and breath (Butcher *et al.* 1999).

The mode of transmission from bird to bird is clearly dependent on the organs in which the virus multiplies. Birds showing respiratory disease presumably shed virus in aerosols of mucus which may be inhaled by susceptible birds. Viruses that are restricted to intestinal replication may be transferred by ingestion of contaminated faces, either directly or in contaminated food or water, or by inhalation of small infective particles produced from dried faeces. A key to successful spread of *Newcastle disease virus* is the ability of the virus to survive in the dead host or excretions (Jordan *et al.*, 2002).

The highest rate of ND outbreaks from March to May is suggested to be associated with high rate of chicken marketing for Easter (Spradbrow 1999). The main movement of chicken marketing is from periphery to the center (rural to towns) which favors the spread of diseases all over the country (Dessei and Ogle, 2001). However, there is acute lack of information on bio-security situation and roles of poultry marketing practices in diseases dissemination in the country (Shewantasew *et al.* 2012).

### 2.2.3. Pathogenesis

Viral replication which occurs initially in the epithelia of the respiratory and intestinal tracts and is followed by haematogenous spread to the spleen and bone marrow. Secondary viraemia results in infection of other organs including lungs, intestine and CNS. The extent of spread within the body is related to strain virulence which is determined by the amino acid sequence of the fusion (F) glycoprotein. The fusion (F) glycoprotein of *Newcastle disease virus* is synthesized in an infected cell as a precursor molecule (F<sub>0</sub>) which is cleaved by host cell proteases to F<sub>1</sub> and F<sub>2</sub> subunits.

If cleavage fails to occur, non-infectious particles are produced (Quinn *et al.*, 2002).

#### 2.2.4. Clinical Signs

The disease produced following infection with *Newcastle disease virus* may vary considerably with the infecting virus and its tissue tropism. In addition, the species of the bird, the immune status, age and conditions under which they are reared may also greatly affect the disease signs seen, while the presence of other organisms may greatly exacerbate even the mildest forms of the disease. As a result, no disease signs may be regarded as pathognomonic (Jordan, 2002). Respiratory, gastrointestinal and nervous signs occur in chickens (Quinn *et al.*, 2002).

Newcastle disease is characterized by a sudden onset of clinical signs which include hoarse chirps (in chicks), watery discharge from nostrils, labored breathing (gaspings), facial swelling, and paralysis, trembling, and twisting of the neck (sign of central nervous system involvement). Mortality ranges from 10 to 80 percent depending on the pathogenicity. In adult laying birds, symptoms can include decreased feed and water consumption and a dramatic drop in egg production (Butcher *et al.*, 1999).

Gasping inhalations through half opened beak, tracheal rales, crackling sounds, thick mucus discharge and a watery yellowish or greenish diarrhea with an abnoxious odor are some of the main signs of the disease (Singh *et al.*, 2006). It is also characterized by the lesions in the respiratory tract, visceral organs and brain, causes moderate to severe mortality and morbidity in susceptible flocks (Hailu, 2012).

#### 2.2.5. Pathology

No gross lesions are pathognomonic for any form of Newcastle disease (Pattison *et al.*, 2009). Pathologic changes associated with ND vary greatly from bird to bird, flock to flock and from one geographic region to another. Gross lesions vary depending on virus and may also be absent. Cadavers of birds that died because of virulent NDV, usually have a dehydrated appearance. These lesions are often particularly prominent in the proventriculus, small intestine and caeca. These organs are markedly hemorrhagic which apparently results from necrosis of the intestinal wall or lymphoid tissues, such as cecal tonsils. Little evidence of gross lesions is found in the central nervous system even in birds showing neurological signs prior to death. Gross pathological lesions are usually present in the respiratory tract in birds with

respiratory illness. They consist predominantly of hemorrhagic lesion and congestion of the trachea and in addition air sacculitis may be evident. Egg peritonitis is often seen in laying hens affected with virulent NDV (Saif *et al.*, 2008).

Histopathologically, hyperemia, edema, hemorrhage, and other changes in blood vessels are found in various organs. In general, in most tissues and organs involved, the lesions include hyperemia, necrosis, cellular infiltration, and edema. Lesions in the central nervous system are characterized by nonpurulent encephalomyelitis (Hailu, 2012). It is also characterized by neural degeneration, peri-vascular cuffing of lymphocytes and proliferation of endothelial cells (Mandal *et al.*, 2004).

#### 2.2.6. Diagnosis

Diagnosis is based on clinical signs, lesions in proventriculus and intestine and other respiratory organs. Then confirmatory diagnosis is done based on isolation, identification and characterization of the virus in a suitable equipped laboratory. Tests which can be conducted to confirm the disease are Haemagglutination inhibition test, virus neutralization test; complement fixation test and ELISA test (Mandal *et al.*, 2004).

#### 2.2.7. Treatment

There is no specific treatment for ND; affected birds should be given antibiotics for the treatment of secondary bacterial infections (e.g. *E.coli*) will reduce the losses. Treatment is not beneficial because of very high mortality up to 100% in the birds affected with *Ranikhet disease virus* (APMV-1). Only control measures are useful (Singh *et al.*, 2006).

#### 2.2.8. Economic Significance

The global impact of virulent Newcastle disease is enormous. In developed countries with established poultry industries, not only are outbreaks of vND extremely costly, but control measures, including vaccination representing continuing loss to the industry. Even countries free of vND usually face the cost of repeated testing to maintain that status and for purpose of trade. In many developing countries vND is endemic and therefore, represents an important limiting factor in the development of commercial poultry production and the establishment of trade links (Saif *et al.*, 2008).



### 2.2.9. Public Health Significance

Newcastle disease is a minor zoonosis (disease of animals that can also infect humans) and can cause conjunctivitis, unilateral or bilateral reddening, excessive lacrimation, edema of the eyelids and subconjunctival hemorrhages in humans, but the condition is generally very mild and self limiting. Human infections with ND usually resulted from direct contact with the virus, infected birds carcasses of diseased birds. The types of person known to have been infected with NDV includes: laboratory workers, veterinarians in diagnostic laboratories, workers in broiler processing plants and vaccination crews especially when live vaccines are given as aerosols and fine dust (Pattison *et al.*, 2009).

### 2.2.10. Control and Prevention

Effective control of Newcastle disease requires good sanitation, management, quarantine, an appropriate vaccination program, and monitoring system, including serotyping and pathogenicity testing of isolated virus (Hailu, 2012).

## 2.3. Marek's Disease

The disease was first described by the Hungarian veterinarian Jozsef Marek in 1907, after whom it was named as Marek's disease. It is a lymphoproliferative and neuropathic disease of chickens (Pattison *et al.*, 2009). Marek's disease, characterized by a mononuclear infiltration in the peripheral nerves and visceral organs is the most common of the lymphoproliferative disease of chickens (Lobago and Woldemeskel, 2004). Paralysis is the most common symptom of the disease and that is why this disease is also known as fowl paralysis, range paralysis and neurolymphomatosis. Virus of this disease is responsible for neural and visceral tumors (Mandal *et al.*, 2004).

### 2.3.1. Etiology

The causative agent for Marek's disease (MD) is a cell associated lymphotropic *herpesvirus*. Due to its lymphotropic nature, Marek's disease virus (MDV) was originally classified in the family *Herpesviridae* as a member of subfamily *Gammaherpesvirinae* (Chuah and Roy, 1998). However, on the basis of genomic organization, MDV is currently classified with the viruses of subfamily *Alphaherpesvirinae*. Three serotypes of MDV and related Herpes viruses have been defined. Serotype 1 includes all the pathogenic or oncogenic strains of these viruses.

Serotype 2 includes naturally non-attenuated strains of MDV. Serotype 3 includes *turkey herpesvirus* (HVT), the non-oncogenic MDV related virus isolated from turkey. New pathotypes have been emerging indicating continuous evolution of MDV towards greater virulence (Jordan *et al.*, 2002).

### 2.3.2. Epidemiology

*Marek's disease virus* infection mainly occurs in domestic chickens and is ubiquitous among poultry populations throughout the world. The infection in other species is rare, but occasionally the disease occurs in turkeys and quails. There is no conclusive evidence of human infection with MDV. There is some evidence to suggest that, with increasing age of the birds, the frequency of isolation of non-pathogenic viruses become higher. The transmission of MDV occurs by direct or indirect contact, apparently by the airborne route (Pattison *et al.*, 2009).

*Marek's disease virus* is not transmitted vertically. The incidence of Marek's disease is quite variable and depends on strain and dose of the virus, age at exposure, host gender and genetics, other concurrent diseases, and several environmental factors including stress (Khan, 2005).

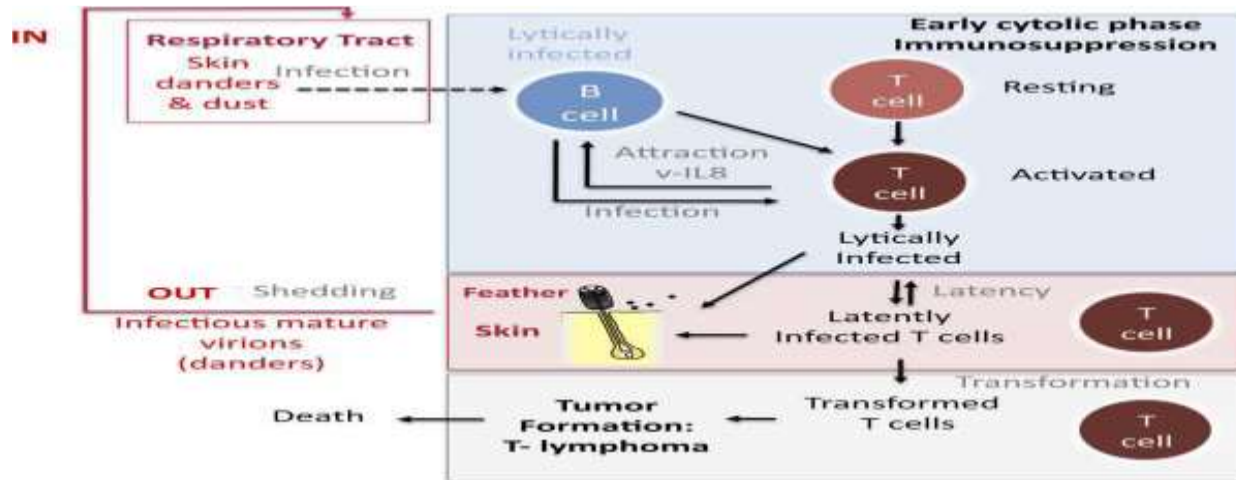
### 2.3.3. Pathogenesis

The pathogenesis of MD is complex, with infection occurring throughout the respiratory route from inhalation of poultry house dust contaminated with the virus. After an early cytolytic infection mainly of the B-lymphocytes in the bursa, spleen and thymus, at 3 to 5 days post infection, the virus infects activated T-lymphocytes, mainly of the CD4+ phenotypes. The infection in the T-lymphocytes becomes latent at 6 to 7 days post infection and the virus is spread throughout the body by the infected lymphocytes that persist as a cell-associated viraemia. A secondary cytolytic infection occur in the feather follicle epithelium form about ten days after infection, from where infectious cell-free virus is produced and shed into the environment in feather debris and dander. The lately infected T- lymphocytes are subsequently transformed leading to the development of lymphomatous lesions in visceral organs. The main target cells for transformation in natural infections are CD4+ T-cells, although the virus also has the potential to transform CD8+ T-cell (Mirtne, 2015).

*Marek's disease virus* (MDV) enters into the chicken through the respiratory tract (figure 1). MDV has a tropism for B- and T- lymphocytes as well as for the

feather follicle epithelium, from which MDV is shedded into the environment. Feathers, skin danders and dust are the major source of MDV infectious

materials and the basis of horizontal bird-to-bird transmission in field Conditions (Calnek, 2001).



**Figure 1:** Pathophysiology of Marek's disease adapted from Calnek model.

#### 2.3.4. Clinical Signs

Birds between 12 and 24 weeks of age are most commonly affected. Clinically, Marek's disease presents as partial or complete paralysis of legs and wings (Quinn *et al.*, 2011). A particularly characteristic posture is that in which the bird has one leg stretched forward and the other backward as a result of partial or complete paralysis of the leg (figure 2). Sometimes, when the cervical nerves are involved, there may be torticollis (twisting of the neck to one side); and if the vagus and intercostals nerves are affected, respiratory symptoms may develop. The interval between onset of symptoms and death varies from a few days to several weeks (Vegad, 2008).



**Figure 2.** Paralyzed chicken with huddling stance (Splay-leg posture of chicken with sciatic neuropathy). Source: (Bland, *et al.*, 2013).

#### 2.3.5. Pathology

The characteristic gross lesions in the classical form of MD are the enlargement of one or more peripheral

nerves. The most commonly affected nerves that are easily seen on post mortem examination are the brachial and sciatic plexus, celiac plexus, and

abdominal vagus and intercostals nerves. The affected nerves are grossly enlarged, and often are three or four times their normal thickness (Chuah and Roy, 1998)

The normal cross-striated and glistening appearance of the nerves is lost; they have grayish or yellowish appearance and are edematous. Lymphomas are present in some chronic form of the disease most frequently as small, soft, grey, tumors in the ovary, kidney, heart, liver and other tissues. In the acute form, the typical lesion is widespread, diffuse lymphomatous involvement of visceral organs such as liver, spleen, ovary, kidney, heart and proventriculus. Sometimes lymphomas are also seen in the skin around the feather follicles and in the skeletal muscle. The liver enlargement in young birds is usually moderate compared to the adult birds. In acute cytolytic form of the disease caused by some virulent isolates, the thymus and bursa of Fabricius may disappear completely due to extensive atrophic changes. The peripheral nerves in both classical and acute form of the disease are affected by proliferative inflammatory or minor infiltrative changes (Venugopal *et al.*, 2001).

Histopathologically, the lesions consist of a mixed population of small, medium and large lymphoid cells plus plasma cells and large anaplastic lymphoblasts. These cell populations undoubtedly include both tumor cells and reactive inflammatory cells (Khan, 2005).

### 2.3.6. Diagnosis

Diagnosis procedures for Marek's disease include both pathological and virological methods. Pathological diagnosis identifies the nature of the tumor, where as virological diagnosis identifies the etiological agents present in a bird or flock (Pattison *et al.*, 2009). The clinical signs, combined with post-mortem findings, will confirm the diagnosis of Marek's disease in most cases, and, most importantly, rule-out other diseases. Enlargement of nerves such as the sciatic nerve are commonly seen at post-mortem. Changes in one or more internal organs may also be observed (Venugopal *et al.*, 2001).

In addition to gross pathology and histology, other advanced procedures used for a definitive diagnosis of Marek's disease include immunohistochemistry to identify cell type and virus-specific antigens, standard and quantitative PCR for identification of the virus, virus isolation and serology to confirm infections (OIE, 2010). Haemagglutination property of the virus is

exclusively used for laboratory investigation of the virus (Thyagarajan, 2011).

### 2.3.7. Treatment

So far there is no treatment for Marek's disease. Affected birds should be given multivitamins like vimeral, B-complex vitamins to reduce stress (Mandal *et al.*, 2004).

### 2.3.8. Economic Significance

However, the epidemiology and the total economic damage caused by these diseases are not fully known. It often causes severe death loss in pullet flocks and has been a major cause of condemnations at the broiler processing plant. Frequent outbreaks and occurrence of new strains for these viral diseases became a challenge to the poultry industry in Ethiopia (Mirtneh, 2015).

The economic loss incurred due to MD is considerable; particularly since poultry production in Ethiopia is at its infancy and such economic losses discourage the farmers ultimately seriously impair the promotion of the poultry industry in the country (Labago and Woldemeskel, 2004).

### 2.3.9. Control and prevention

Because highly contagious nature of MDV and its ability to survive for long periods, with in the host and in the environment, eradication of the disease is difficult. Control of the disease is based on preventive vaccination, with improved management methods and use of genetically resistant birds (Pattison *et al.*, 2009). Vaccination is the central strategy for the prevention and control of Marek's disease (Khan, 2005).

## 2.4. Avian pox

Avian pox is the common name for a mild-to severe, slow developing disease of birds. The disease has two forms. The dry or cutaneous form is mainly characterized by skin lesions on the unfeathered parts of the bird's body. This form of the disease has high prevalence but with less severity. The other form is diphtheritic or wet form which is characterized by lesions in the mouth and upper respiratory tract (Elias *et al.*, 2014). It is a contagious viral disease of chickens and has the following basic features. These includes: hyperplastic and inflammatory changes in the epidermis and feather follicles; appearance of scabs and desquamation of the degenerated epithelium; wart like nodules are seen on unfeathered parts of the body;



formation of intracytoplasmic inclusion bodies (borrel bodies); yellowish adherent deposit is seen in the mouth; watery and purulent discharge can be found running from the eye and the nose (Singh *et al.*, 2006).

#### 2.4.1. Etiology

Fowl pox is caused by an *avipoxvirus* under the family *Poxviridae* and genus *Avipox* (Nandi and Samanta, 2010). *Fowl pox virus* the first virus to be grown on the chorioallantoic membrane (CAM) of embryonated fowls' egg. Growth or pocks on the membrane easily determined the presence of the virus. It is an enveloped, double stranded DNA and is the largest virus known (Jordan *et al.*, 2002).

#### 2.4.2. Epidemiology

*Fowl pox virus* infects birds of both sexes, all ages and breeds. This virus does not penetrate the intact skin. Some break in the skin is required for the virus to enter the cells, grow and cause disease. As a result, infection occurs through mechanical spread of the virus to the injured skin. Spread of the virus from one chicken to another by direct contact between infected and susceptible bird is a major factor in the spread of disease. Most of the spread is the result of birds picking, fighting, or scratching one another. In a contaminated environment, presence of virus in the air from feathers and dried scabs containing *Fowl pox virus*, may lead to skin and respiratory infection. Lining of the upper respiratory tract and mouth appears to be highly susceptible to the virus, because infection may occur in the absence of trauma or injury (Vegad, 2008).

Fowl pox is a mosquito-borne disease. During viraemic phase, this virus can be easily transmitted by blood sucking mosquitoes. Male birds and those having larger combs suffer severely, mainly due to large area available for the mosquitoes to bit. The virus is having long survivability in dried scabs, which may be for months or even years (Mandal *et al.*, 2004). Some affected birds may become carriers, and the disease may be reactivated by stress or by immunosuppression due to other infections. The disease tends to persist for extended periods in multiple-age poultry complexes (Khan, 2005).

There are some factors for increase in the incidence of the disease like breed differences, managerial practices and environmental conditions (Elias *et al.*, 2014).

#### 2.4.3. Pathogenesis

Virus enters a skin cell, and spreads from cell to cell locally. Some virus enters in to the blood to cause a blood infection (viraemia). Although there is spread to internal organs, no changes are seen. However, it is likely that there is viral growth in certain organs, such as the liver and spleen, and a secondary viraemia occurs. Virus can enter again in to the skin cells and a generalized disease can occur, although this is rare (Vegad, 2008).

Virus multiplication occurs at the site of introduction may be confined to that site when the strain of the infecting virus is of low virulence. Infection caused by virulent strains result in viraemia with replication in internal organs. The route of introduction influences the distribution and severity of lesions. Factors such as malnutrition, debilitation and stress may contribute the severity of the disease (Quinn *et al.*, 2002).

#### 2.4.4. Clinical Signs

Weakness, emaciation, difficulty in swallowing and breathing, vision problems, a reduction in egg production, soiled facial feathers, conjunctivitis and edema of the eyelids and the presence of the characteristic wart-like growths are the general clinical signs of the disease (Elias *et al.*, 2014). Unthriftiness and retarded growth are typical symptoms of fowl pox. Chickens may be affected with either or both forms of fowl pox at one time (Vegad, 2008).

**Skin, Dry or Cutaneous Form:** Characterized by the appearance of cutaneous eruptions or wart like nodules on the unfeathered parts of fowl, e.g. comb, wattle, eyelid, feet, cloaca aperture and under the wings. In young chicks; corner of mouth, nostril and eyelids are affected. The cutaneous lesion can vary in size and appearance. First there is development of a papule which rapidly progress in to vesicle then to pustule and finally to crust or scab form. If the desiccated scab is removed in the meantime, a moist sero-purulent exudate is found underneath, covering a bleeding, granulating surface. When the scab drops off, a smooth scar may be left (Samour, 2004).

**Diphtheritic or Wet form:** In the wet form there are canker-like lesions in the mouth, pharynx, larynx, and trachea. The wet form may cause respiratory distress by obstructing the upper air passages. This type is not as common as the cutaneous form. The eruptions on the mucous membranes are white, opaque, slightly elevated nodules. These processes rapidly increase in

size, often coalescing to become a yellowish, cheesy, necrotic material with the appearance of a pseudo membrane. Where these pseudo membranes are removed they leave bleeding erosions. The invasion by contaminated bacterial aggravates the diphtheritic form of the disease. The inflammatory process may extend from the mouth region into the sinuses, particularly the intra orbital sinuses, resulting in a tumor like swelling and may extend into the pharynx, resulting in respiratory disturbance. This form of disease is primarily a problem of young chickens and turkeys (Elias *et al.*, 2014).

#### 2.4.5. Pathology

*Gross changes:* epithelial hyperplasia in the epidermis and underlying feather follicles is noticed. The nodules first appear as white foci which become yellow and also increase in size. Inflammatory and hyperemic changes occur in such lesions and scabs are formed. The scab drops off to leave behind a smooth scar. In the diphtheritic forms, white or opaque nodules develop on the oral mucous membrane. These nodules may coalesce to form a yellow, cheesy and necrotic diphtheritic membrane. The inflammatory changes can spread in to the infraorbital sinus and pharynx resulting in respiratory distress. There can be formation of masses of soft, yellow, diphtheritic ulcers adhering to the mucous membranes. The eyelids are swollen and they stick or glue to each other due to ocular discharges. The birds with such lesions die of starvation or blindness. Microscopic changes: proliferation of epidermal cells and the characteristic eosinophilic cytoplasmic inclusion bodies can be seen in the epithelial cells (Singh *et al.*, 2006).

#### 2.4.6. Diagnosis

A presumptive diagnosis of avian pox can be made due to the gross lesions on the body. Confirmation of avian pox is accomplished by microscopic examination for the characteristic Bollinger bodies. Virus isolation by transmission of the organism via egg inoculation, serological results and polymerase chain reaction can also be a means of confirming the disease (Rocke *et al.*, 2005).

#### 2.4.7. Treatment

There is no specific treatment for fowl pox. Affected birds can be treated symptomatically to reduce stress by giving anti-stress factors and also antibacterials to prevent secondary bacterial infection (Thyagarajan, 2011).

#### 2.4.8. Economic Significance

The major economic importance of the disease is that mortality mainly due to secondary infections and reduction in the productive performance of the birds as the disease can result in a drop in egg production, or retarded growth in younger birds (Elias *et al.*, 2014).

#### 2.4.9. Control and Prevention

In endemic areas, improved management and hygiene along with regular vaccination have reduced the effect of the disease on commercial poultry production (Quinn *et al.*, 2011). The fundamental principle for controlling avian pox is to interrupt virus transmission. It is very essential to control the mosquitoes in poultry sheds. The infected equipments and other materials should be disinfected. Litter from the infected birds and dead birds should be incinerated or buried deep (Mandal *et al.*, 2004).

### 3. Conclusion And Recommendation

In poultry production system, desired performance can be achieved only from healthy flocks. A variety of infectious agents may affect the birds' health causing great loss in meat and egg production. Infectious bursal disease, Newcastle disease, Marek's disease and Fowl pox are among major viral diseases of poultry in Ethiopia. They are highly contagious and cause significant losses to both commercial poultry farms as well as rural poultry production. Although there are some studies that indicated poultry diseases of viral origin became endemic throughout the country, information on the epidemiology and as well as the occurrence of new strains of these diseases are scanty. Therefore, there is need of a comprehensive knowledge in different viral poultry diseases encompassing the characteristics of the causal agent and the disease, prevention and control and sanitation measures. The following points are recommended as they are important to design strategies to control and prevent these diseases:

- 1) An integrated vaccination program along with effective management system and biosecurity measures should be implemented
- 2) In depth studies should be done on investigation of the epidemiology and identification of local viral strains of these viral diseases to design cost-effective vaccine
- 3) All-in all-out principle should be employed for those diseases which cause massive mortality and possibility of long duration of

stay in the poultry house so as to block the infection cycle.

#### Acknowledgements

I would like to thank Bahirdar Animal Health Investigation And Diagnostic Laboratory for letting me to write a Review On Infectious Bursal Disease, Newcastle Disease, Marek's Disease And Avian Pox. I wish also to express my profound gratitude to my friends who assist during study period and valuable comments.

#### Corresponding Author:

Dr. Eyachew Ayana

Bahirdar Animal Health Investigation And Diagnostic Laboratory, P.O.Box 70, Bahirdar, Ethiopia

Telephone: (+251)918575003

e-mail: [eyuelayana83@gmail.com](mailto:eyuelayana83@gmail.com)

#### 4. References

- Belayheh, G., Moses, N.K., Melese, B., Fufa, D., 2015. Isolation and identification of Newcastle disease virus from out break cases and apparently healthy local chickens in south west Shewa, Ethiopia. *International journal of microbiological research* **6** (1): 05-08.
- Butcher, G.D., Jacob, J.P., Mather, F.B., 1999. Common poultry diseases. 1<sup>st</sup> ed. University of Florida/IFAT extension. Pp.1-15.
- Calnek, B., 2001. Pathogenesis of Marek's disease virus infection. *Current Topics in Microbiology and Immunology*, **255**: 25-55.
- Chuahan, HV, Roy, SY. 1998. Poultry Disease Diagnosis, Prevention and Control. 7th Edition. India: W.B. Saunders. Pp. 58-429.
- CSA. 2013. Report on livestock and livestock characteristics, agricultural sample survey (3): 13 -20.
- Dessei T, and Ogle B., 2001. Village poultry production system in the central highlands of Ethiopia. *Trop Anim Health Prod.* 33:521–537.
- Dwight, C.H., N.M. James and L.W. Richard, 2004. Veterinary Microbiology, 2<sup>nd</sup> ed. Asia: Blackwell, pp: 407-419.
- Elias, A., Mersha, C., and Desalegn, M., 2014. A systematic review of serological and clinicopathological feature and associated risk factors of Avian Pox, University of Gondar, Faculty of Veterinary Medicine, Gondar, Ethiopia, *British journal of poultry science*: **3** (3):78-87.
- Fenner, Stephen W., Richard A., Ronald P., Donald P., Michael D., Colin R., Linda J., and David E., 2011. Veterinary Virology. 4<sup>th</sup> ed. Academic Press an imprint of Elsevier, London, UK, Pp: 180-193.
- Hailu, M., 2012. Review on major viral diseases of chickens reported in Ethiopia, *Journal of Infectious Diseases and Immunity* Vol. **4**(1): 1-9.
- Jordan, F., Pattison, M., Alexander, D., Faragher, T., 2002. Poultry diseases, 5<sup>th</sup> ed, WB Saunders. Pp. 221-297.
- Kaufer, L. and Weiss, A., 2005. Significance of bursal fabricius as target organ in infectious bursal disease of chicken. *Infection and immunity*, 21: 364-367.
- Khan, C.M., 2005. The Merck Veterinary Manual, 9<sup>th</sup> ed. USA: MERCK & CO., INC. Pp. 2239-2277.
- Lobago, F. and Woldemeskel, M., 2004. An outbreak of Marek's disease in chickens in central Ethiopia. *Tropical animal health and production*, **36**(4), 397-406.
- Lukert P.D. and Saif Y.M., 1997. Infectious bursal disease. In Diseases of poultry, 10<sup>th</sup> ed. Iowa State University Press, Ames, pp. 721-738.
- Mandal, A.B., Yadav, A.S., Johri, T.S., Pathak, N.N., 2004. Nutrition and disease management of poultry, 1<sup>st</sup> ed. India, international book distributing co. Pp.257-281.
- Minalu, T., Tewodros, F., and Bemrew, A., 2015. Infectious bursal disease (Gumboro disease) in chickens, Faculty of Veterinary Medicine, University of Gondar, Ethiopia, *British journal of poultry sciences* **4**(1):22-28.
- Mirtneh, A., 2015. Isolation and characterization of Marek's disease virus in central Ethiopia and evaluation of its vaccine trial, MSC thesis, College of Veterinary Medicine and Agriculture of Addis Ababa University, Bishoftu, Ethiopia. Pp.1-80.
- Muller, M., R. Islam and R. Raue, 2003. Research on IBD the past, present and future *veterinary micro-biology*, **97**: 153-165.
- Nandi, S., Samanta, S.(2010). Poultry diseases; at a glance. India, ibdc publishers. Pp. 3-42.
- Natnael T., 2015. Pathological and seroprevalence studies on Infectious Bursal Disease on chickens in and around Bahirdar Northwest Ethiopia. DVM thesis, Addis

- Ababa University, College of Veterinary Medicine and Agriculture, Bishoftu, Ethiopia. Pp.1-67.
22. OIE., 2010. Office International des Epizootics, chapter 2.3.13: Marek's disease, Manual of diagnostic test and vaccines for terrestrial animals. Pp: 1-11.
  23. OIE., 2012. Office international des epizootics, chapter 2.3.14: Newcastle disease, manual of diagnostic test and vaccines for terristorial animals. Pp. 555-573
  24. Pattison, McMullin, Bradbury, Alexander, 2009. Poultry diseases, 6<sup>th</sup> ed. India, Elsevier. Pp. 258-366.
  25. Quinn, P.J., Markey, B.K.,Carter, M.E., Donnelly, W.J. , Leonard, F.C., 2002. Veterinary Microbiology and Microbial Disease.1<sup>st</sup> ed. Blackwell publishing press, pp: 324-388.
  26. Quinn, P.J., Markey, B.K., Leonard, F.C., Fitzpatrick, E.S., Fanning, S., Hartigan, P.J., 2011. Veterinaty Microbiology and Microbial disease, 2<sup>nd</sup> ed. Blackwell science. Ltd. Pp.505-664
  27. Rajaonarison, J.J., S.M. Rakotonindrina, E.K. Rakotondramary and S. Razafimanjary, 2006. Gumboro Disease (Infectious bursitis) in Madagascar. Revue d'élevage et de médecine vétérinaire des pays tropicaux, **47**(1): 15-17.
  28. Rocke, T., K. Converse, C. Meteyer and B. Mclean, 2005. The impacts of disease in the American White Pelican in North America. Water birds, 28: 87-94.
  29. Saif, Y.M., Fadly, A.M., Glisson, J.R., McDougald, L.R., Nolan, N.K., Swayne, D.E., 2008. Disease of poultry, 12<sup>th</sup> ed. Asia: Blackwell. Pp.75-617.
  30. Samour, J., 2004. Avian Medicine. 3<sup>rd</sup> ed. China: Elsevier. Pp: 266-269.
  31. Serkalem, T., Hagos, A., Zeleke, A., 2005. Seroprevalence study of Newcastle disease in local chickens in central Ethiopia. *Intern J App Res Vet Med.* **3**(1): 25-29.
  32. Shewantasew M, Melesse B, MesfinS MB., 2012. Assessment of Bio-security situation and practices in live poultry Markets of Addis Ababa, Ethiopia. *Asian J Anim Vet Adv.* **7**(5):421–433.
  33. Singh, C,D.N., Singh, S.D., Verma, S.P., Prasad, L.N., 2006. Advanced pathology and treatment of disease of poultry; with special reference to etiology, signs, pathology and management, 1<sup>st</sup> ed. India: international book distributing co. Pp.1-49.
  34. Spradbrow, PB., 1999. Proceedings of international workshop on Poverty eradication and promotion of gender equality, held at Livestock Research Institute 26–26 March1999. Denmark: Tune landboskole. Epidemiology of Newcastle Disease and the Economic of its control. Pp. 165–173.
  35. Tadelle and Jobre Y., 2004. A review of the importance and control of Newcastle disease in Ethiopia. *Ethiopian Veterinary Journal.* **1**:71–81.
  36. Thyagarajan, D., 2011. Diseases of poultry. India, Satish serial publishing house. Pp.39-68.
  37. Tsegaye, K. and Mersha, C., 2014. Review on the incidence and pathology of infectious bursal disease, University of Gondar, Faculty of Veterinary Medicine, Gondar, Ethiopia. *British journal of poultry sciences* **3**(3):68-77.
  38. Vegad, J.L., 2008. Poultry disease; a guide for farmers and poultry professionals, 2<sup>nd</sup> ed. India, international book distributing co.pp. Pp. 13-76.
  39. Woldemariam, M. and Wossen, A., 2007. Infectious bursal disease; case report at region. *Ethiopian Veterinary Journal,* **11**: 151.
  40. Zeleke, A., Gelaye, E., Sori, T., Ayelet, G., Sirak, A., and Zekarias, B., 2005a. Investigation on infectious bursal disease outbreak in Debre Zeit. *International Journal of Poultry Science,* **7**: 504-506.