



Mitigation of Cisplatin-Induced Acute Kidney Injury by Punicalagin Therapy in Mice

Nouf Khalifa ALaqeel ⁽¹⁾ and Meneerah Abdulrahman Al-Jafary ⁽²⁾

Department Biology, College Sciences, Imam Abdrahman Bin Faisal University, P.O. Box 1982, Dammam 31441, Saudi Arabia.

nalqaeel@iau.edu.sa, maljafary@iau.edu.sa

Abstract: The ameliorated impact of punicalagin was studied in mice exposed to nephrotoxicity caused by cisplatin (5 mg/kg, i.p.). Punicalagin treatment (9 mg/kg/day, p.o.) was given for 5 days, administered on the same day as cisplatin. Punicalagin greatly ameliorated the cisplatin-induced elevations of serum creatinine, renal nitric oxide, malondialdehyde, tumor necrosis factor- α , and caspase-3, and significantly increased kidney glutathione peroxidase in mice that received cisplatin. In addition, punicalagin markedly attenuated the histopathological changes, and significantly decreased nuclear factor- κ B expression in the kidneys of mice that received cisplatin. We concluded that punicalagin protected against acute kidney injury caused by cisplatin in mice through its antioxidant, and anti-inflammatory effects.

[Nouf Khalifa ALaqeel and Meneerah Abdulrahman Al-Jafary. **Mitigation of Cisplatin-Induced Acute Kidney Injury by Punicalagin Therapy in Mice.** *Cancer Biology* 2021;11(1):10-14]. ISSN: 2150-1041 (print); ISSN: 2150-105X (online). <http://www.cancerbio.net>. 2. doi:[10.7537/marscbj110121.02](https://doi.org/10.7537/marscbj110121.02).

Keywords: Punicalagin; cisplatin; kidneys; mice

1. Introduction:

Some cancers such as head and neck, gonadal, thyroid, breast and lung cancers are commonly treated by the antitumor agent cisplatin [1, 2]. However, the optimum clinical efficacy of cisplatin is usually limited by its dose-dependent nephrotoxicity [3]. Acute kidney injury with various degrees of renal dysfunction occurs in about 20% of patients following the initial dose of cisplatin [4]. The exact mechanism underlying this toxicity is not well understood. However, oxidative stress, exhaustion of endogenous antioxidants, as glutathione peroxidase (GPx), and membrane lipid peroxidation with enhanced generation of malondialdehyde (MDA) are implicated in the pathogenesis of this condition. In addition, activation of nuclear factor- κ B (NF- κ B), and increased production of inflammatory cytokines, as tumor necrosis factor- α (TNF- α), seem to play an important role [4, 6]. This leads finally to renal cell necrosis and apoptosis. Several antioxidants and anti-inflammatory agents significantly protected the kidneys against the harmful effects of cisplatin [7, 8].

Punicalagin is the main active polyphenolic constituent of pomegranate extract. It has, anti-inflammatory [9,10], antioxidant and anti-apoptotic activities [11]. Previous studies showed that pomegranate extract significantly ameliorated kidney damage in rats exposed to gentamicin, and hypoxia-reoxygenation [12, 13]. Therefore, the possible ameliorated effect of punicalagin against cisplatin-

induced nephrotoxicity in mice was investigated in the present study.

2. Materials and Methods:

Chemicals

Both punicalagin and cisplatin were provided by Sigma-Aldrich, USA, and were dissolved in physiological saline. In this study selected doses were based on previous studies [5, 14].

Laboratory animals

The animals used were male albino mice, weighing 25-30 g, they were given free access to standard food and water, and housed at 24°C, 12 h light-dark cycle, and humidity of 45%. They were left to acclimatize for 7 days before the beginning of the experiments. All experimental procedures were approved by University Ethics Committee and carried out in accordance with Animal Welfare Committee (IRB NO 2019-034-Sci).

Study design

The mice were divided into 3 clusters ($n = 12$, each). Group one served as control, receiving physiological saline through i.p. injection. The mice of group two and three were given a single injection of cisplatin (5 mg/kg, i.p.). The mice of group two and three received a daily physiological saline or punicalagin (9 mg/kg/day), p.o., respectively, for 5 days beginning on the same day of cisplatin administration.

Sample collection and biochemical examination

The mice were euthanized 5 days after cisplatin administration. The left ventricle of the heart was punctured to collect blood samples, the blood was left to clot for 60 min, then centrifuged for 10 min at 500 rpm. The serum creatinine level was measured using a colorimetric kit (Stanbio Laboratory, USA).

Cold potassium phosphate buffer (0.05 M, pH 7.4) was used to homogenize the collected right kidneys, after which centrifugation at 5000 rpm for a duration of 10 min at 4 °C was conducted to the resulting homogenate samples, the supernatant was used to detect levels of: malondialdehyde (MDA) and glutathione peroxidase (GPx) using (BioVision, USA) colorimetric assay kit, and nitric oxide (NO) was assayed using (Sigma-Aldrich, USA) colorimetric assay kit. In addition, kidney tissue levels of tumor necrosis factor- α (TNF- α), and caspase-3 were measured by ELISA kits (R & D Systems, USA). All kits were used as directed by manufacturers.

Histopathology examination

Fixation of left kidneys occurred in 10% formalin solution, after which ascending grades of alcohol dehydrated the tissues, and finally paraffin was used to embed the samples. 5 μ m-thick sections were stained in hematoxylin and eosin (H & E) and examined using a light microscope.

Immunohistochemistry examination

Sections were deparaffinised, rehydrated, and H₂O₂ in methanol blocked endogenous peroxidase activity. Citrate buffer was used to pre-treat the sections at (pH 6.0) using a microwave. After which sections were incubated with rabbit polyclonal antibody against mice nuclear factor- κ B (NF- κ B) at room temperature (Thermo Scientific, USA, dilution 1:100). Sections were incubated with biotinylated goat anti-polyvalent, streptavidin peroxidase and DAB plus chromogen respectively. Hematoxylin was used to counterstain the slides, after which they were examined by light microscope.

Statistics

The data is presented as mean \pm S.E.M. The results were analyzed by one-way ANOVA, thereafter were analyzed by Tukey test for post hoc comparisons using GraphPad Prism software program (version 6). Statistical significance was considered at $P < 0.05$.

3. Results:

Biochemistry

Cisplatin administration caused a significant increase in serum creatinine, and renal MDA, NO, TNF- α , and caspase-3, and a noticeable decrease in renal GPx, when compared to control. On the other hand, punicalagin treatment significantly decreased serum creatinine, and renal MDA, NO, TNF- α , and caspase-3, and significantly increased GPx in the

kidneys of mice received cisplatin (Figures 1, 2, and 3).

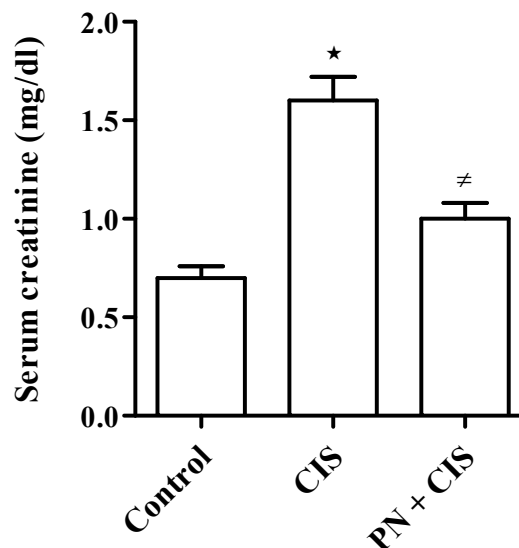


Figure 1. Effect of punicalagin (PN) on serum creatinine level in mice that received cisplatin (CIS). * $P < 0.05$ vs. control group, # $P < 0.05$ vs. cisplatin group.

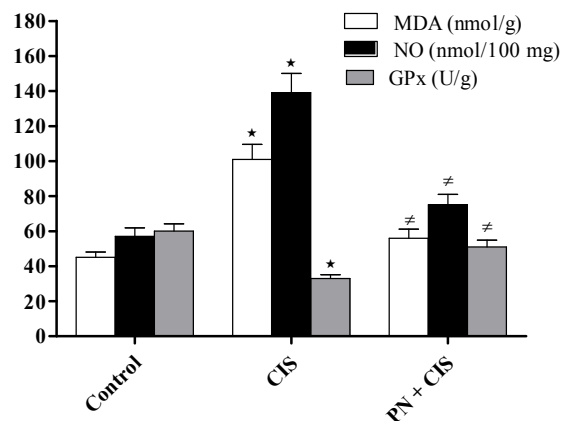


Figure 2. Effects of punicalagin (PN) on renal MDA, NO, and GPx in mice that received cisplatin (CIS). * $P < 0.05$ vs. control group, # $P < 0.05$ vs. cisplatin group.

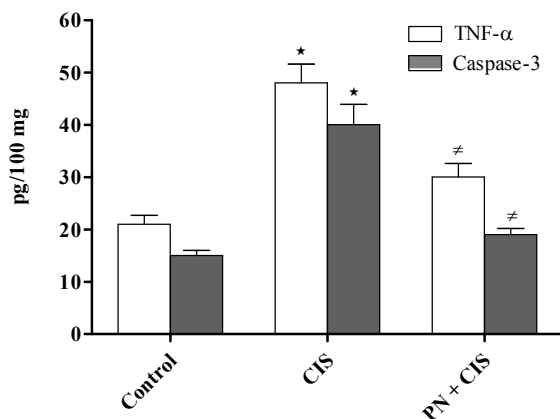


Figure 3. Effects of punicalagin (PN) on renal TNF- α , and caspase-3 in mice that received cisplatin (CIS). * $P < 0.05$ vs. control group, # $P < 0.05$ vs. cisplatin group.

Histopathology

Histopathological damage of kidney tissue was caused by cisplatin, it was apparent in the form of desquamation of epithelial cells, tubular dilatation, vacuolization, coagulative necrosis and interstitial edema. Punicalagin markedly attenuated kidney tissue injury, and improved the histopathological picture of the kidneys in mice received cisplatin (Figure 4).

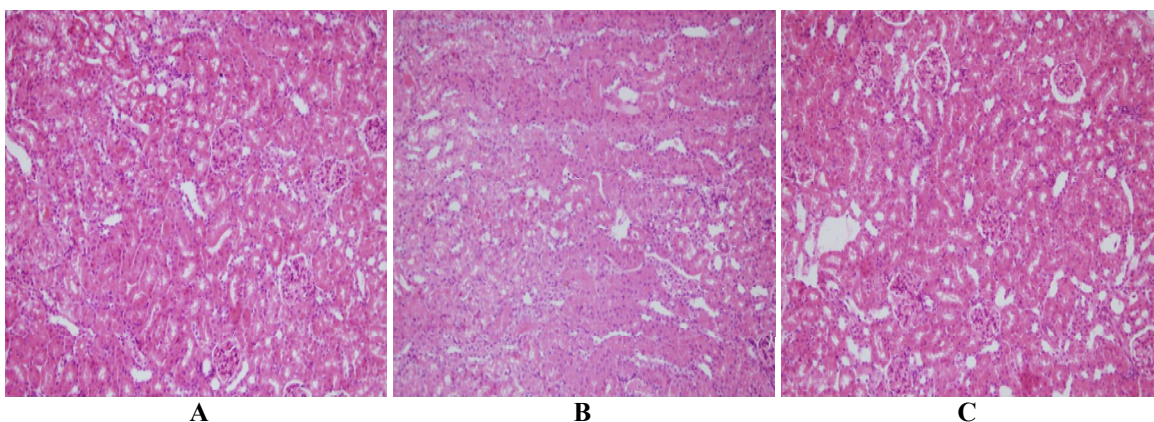


Figure 4. Histological sections: (A) control group revealing normal histology of kidney tissues; (B) cisplatin group revealing tubular necrosis, dilatation, epithelial desquamation, vacuolization, and interstitial edema; (C) punicalagin plus cisplatin group revealing histological similarities to the control group. (H & E, 200 \times)

Immunohistochemistry

Immunohistochemical examination revealed that cisplatin caused a marked increase of NF- κ B expression in the kidney tissue when compared with

control group. Contrarily, punicalagin caused clear decrease in NF- κ B expression in mice that received cisplatin (Figure 5).

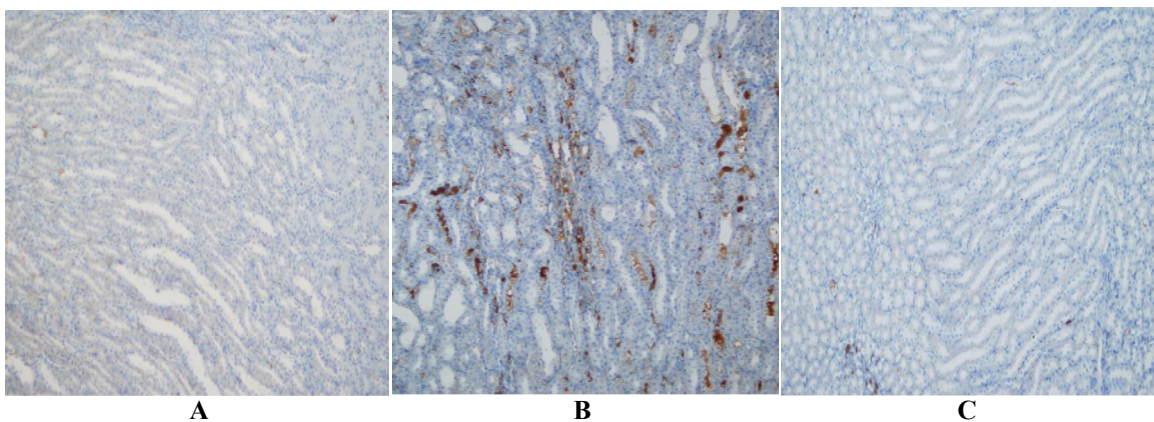


Figure 5. Immunohistochemical staining of NF- κ B (200 \times) in mice kidneys from: (A) control group revealing low NF- κ B levels; (B) cisplatin group revealing a marked addition in NF- κ B immunoreactivity; (C) punicalagin plus cisplatin group showing a marked decrease in NF- κ B immunostaining.

4. Discussion:

In agreement with the present study, recent evidence suggests that cisplatin-induced kidney injury results from oxidative stress and increased production of reactive oxygen species [15, 16]. The depletion of the endogenous antioxidant enzymes, are caused by the increased production of reactive oxygen species, as GPx, and enhances membrane lipid peroxidation in renal tissue with increased production of MDA [17]. Punicalagin has marked antioxidant effect, scavenges reactive oxygen species, and protects against lipid peroxidation. This is in agreement with our results, which indicated that punicalagin decreased MDA, and enhanced GPx activity in the kidneys of mice that received cisplatin. In addition, cisplatin nephrotoxicity increases NO production because TNF- α can activate inducible nitric oxide synthase enzyme [18]. Excess NO reacts with superoxide anion to generate peroxynitrite, which oxidizes and nitrates cellular macromolecules causing further cell damage. Cisplatin also enhances NF- κ B pathway with elevated production of inflammatory cytokines, mainly TNF- α , responsible for further renal tissue damage [19]. In consistence with the present results, previous investigations showed similar antioxidant, anti-inflammatory, and antinitrosative activities of punicalagin [20, 21].

Besides, it was reported that cisplatin causes apoptosis of renal cells by inducing caspase family of protease enzymes. Caspase-3 is the major apoptotic executioner responsible for DNA fragmentation, chromatin condensation, and protein denaturation [22]. In the present work, punicalagin significantly prevented apoptosis by inhibiting caspase-3 activity in the kidneys of mice exposed to cisplatin. Similarly, previous investigations showed that punicalagin exerted a significant anti-apoptotic effect [23, 24]. The antioxidant, anti-inflammatory, and antinitrosative effects are the main factors responsible for anti-apoptotic activity of punicalagin.

Histopathological examination revealed that cisplatin caused widespread injury in the kidney tissues in the form of tubular cell necrosis, tubular dilatation, epithelial desquamation, vacuolization, and interstitial edema. Similar injuries were observed in previous studies [25, 26]. This study showed that punicalagin protected the integrity of kidney tissue in cisplatin-challenged mice.

It was concluded by biochemical, histopathological, and immunohistochemical examinations that punicalagin exerted a significant ameliorated effect against kidney injury caused by cisplatin in mice through its antioxidant, anti-inflammatory, antinitrosative and anti-apoptotic properties, giving punicalagin an important role as a naturally occurring therapeutic agent that may be

administered during the course of treatment with cisplatin.

References

1. Delord JP, Puzozzo C, Lefresne F, Bugat R. Combination chemotherapy of vinorelbine and cisplatin: a phase I pharmacokinetic study in patients with metastatic solid tumors. *Anticancer Res* 2009;29:553-60.
2. Manohar S, Leung N. Cisplatin nephrotoxicity: a review of the literature. *Journal Of Nephrology* 2018;31(1):15–25.
3. Pabla N, Dong Z. Cisplatin nephrotoxicity: mechanisms and renoprotective strategies. *Kidney Int* 2008;73:994-1007.
4. Yao X, Panichpisal K, Kurtzman N, Nugent K. Cisplatin nephrotoxicity: a review. *Am J Med Sci* 2007;334:115-24.
5. Behling EB, Sendao MC, Francescato HDC, Antunes LMG, Costa RS, Bianchi MP. Comparative study of multiple dosage of quercetin against cisplatin induced nephrotoxicity and oxidative stress in rat kidneys. *Pharmacol Rep* 2006;58:526-32.
6. Yano T, Itoh Y, Matsuo M, Kawashiri T, Egashira N, Oishi, R. Involvement of both tumor necrosis factor-alpha-induced necrosis and p53-mediated caspase-dependent apoptosis in nephrotoxicity of cisplatin. *Apoptosis* 2007;12:1901-9.
7. Do Amaral CL, Francescato HD, Coimbra TM, Costa RS, Darin JD, Antunes LM, Bianchi M, De L. Resveratrol attenuates cisplatin-induced nephrotoxicity in rats. *Arch Toxicol* 2008;82:363-70.
8. Khan SA, Priyamvada S, Khan W, Khan S, Farooq N, Yusufi AN. Studies on the protective effect of green tea against cisplatin induced nephrotoxicity. *Pharmacol Res* 2009;60:382-91.
9. Du Lin, Li Jianke, Zhang Xitong, Wang Lifang, Zhang Weimin, Yang Mi, Hou Chen. Pomegranate peel polyphenols inhibits inflammation in LPS-induced RAW264.7 macrophages via the suppression of TLR4/NF-kappa B pathway activation. *FOOD & NUTRITION RESEARCH* 2019;63:3392.
10. Du Lin, Li Jianke, Zhang Xitong, Wang Lifang, Zhang Weimin. Pomegranate peel polyphenols inhibits inflammation in LPS-induced RAW264.7 macrophages via the suppression of MAPKs activation. *Journal of Functional Foods* 2018; 43:62–69.
11. Tyagi S, Singh A, Bharadwaj P, Sahu S, Yadav AP, Kori M.L. Punicalagins - a large polyphenol compounds found in pomegranates: a therapeutic review. *Acad J Plant Sci* 2012;5:45-9.

12. Cekmen M, Otunctemur A, Ozbek E, Cakir SS, Dursun M, Polat EC, Somay A, Ozbay N. Pomegranate extract attenuates gentamicin-induced nephrotoxicity in rats by reducing oxidative stress. *Ren Fail* 2013;35:268-74.
13. Sancaktutar AA, Bodakci MN, Hatipoglu NK, Soylemez H, Basarılı K, Turku G. The protective effects of pomegranate extracts against renal ischemia-reperfusion injury in male rats. *Urol Ann* 2014;6:46-50.
14. Rao F, Tian H, Li W, Hung H, Sun F. Potential role of punicalagin against oxidative stress induced testicular damage. *Asian J Androl* 2016;18:627-32.
15. Gulec M, Iraz M, Yilmaz HR, Ozyurt H, Temel I. The effects of ginkgo biloba extract on tissue adenosine deaminase, xanthine oxidase, myeloperoxidase, malondialdehyde, and nitric oxide in cisplatin-induced nephrotoxicity. *Toxicol Ind Health* 2006;22:125-30.
16. Chirino YI, Sánchez-González DJ, Martínez-Martínez CM, Cruz C, Pedraza-Chaverri J. Protective effects of apocynin against cisplatin-induced oxidative stress and nephrotoxicity. *Toxicology* 2008;245:18-23.
17. Ali BH, Al Moundhri MS, Tag Eldin MT, Nemmar A, Tanira MO. The ameliorative effect of cysteine prodrug L-2-oxothiazolidine-4-carboxylic acid on cisplatin-induced nephrotoxicity in rats. *Fundam Clin Pharmacol* 2007;21:547-53.
18. Mukhopadhyay P, Rajesh M, Pan H, Patel V, Mukhopadhyay B, Bátkai S, Gao B, Haskó G, Pacher P. Cannabinoid-2 receptor limits inflammation, oxidative/nitrosative stress, and cell death in nephropathy. *Free Radic Biol Med* 2010;48:457-67.
19. Kang KP, Kim DH, Jung YJ, Lee AS, Lee S, Lee SY, Jang KY, Sung MJ, Park SK, Kim W. Alpha-lipoic acid attenuates cisplatin-induced acute kidney injury in mice by suppressing renal inflammation. *Nephrol Dial Transplant* 2009;24:3012-20.
20. Yaidikar L, Thakur S. Punicalagin attenuated cerebral ischemia-reperfusion insult via inhibition of proinflammatory cytokines, up-regulation of Bcl-2, down-regulation of Bax, and caspase-3. *Mol Cell Biochem* 2015;402:141-8.
21. Zhong J, Reece EA, Yang P. Punicalagin exerts protective effect against high glucose-induced cellular stress and neural tube defects. *Biochem Biophys Res Commun* 2015;467:179-84.
22. D'Amelio M, Cavallucci V, Cecconi F. Neuronal caspase-3 signaling: not only cell death. *Cell Death Differ* 2010;17:1104-14.
23. Fouad AA, Qutub HO, Al-Melhim WN. Nephroprotection of punicalagin in rat model of endotoxemic acute kidney injury. *Toxicol Mech Methods* 2016;26:538-43.
24. Ding M, Wang Y, Sun D, Liu Z, Wang J, Li X, Huo C, Jia X, Chen W, Fu F, Wang X. Punicalagin Pretreatment Attenuates Myocardial Ischemia-Reperfusion Injury via Activation of AMPK. *Am J Chin Med* 2017;45:53-66.
25. Topcu-Tarladacalisir Y, Sapmaz-Metin M, Karaca T. Curcumin counteracts cisplatin-induced nephrotoxicity by preventing renal tubular cell apoptosis. *Ren Fail* 2016;38:1741-8.
26. Darwish MA, Abo-Youssef AM, Khalaf MM, Abo-Saif AA, Saleh IG, Abdelghany TM. Vitamin E mitigates cisplatin-induced nephrotoxicity due to reversal of oxidative/nitrosative stress, suppression of inflammation and reduction of total renal platinum accumulation. *J Biochem Mol Toxicol* 2017;31:1-9.