

Esophagogastric Anastomosis with Invagination of Esophageal Stump into Stomach versus Direct End To End Anastomosis after Subtotal Esophagectomy for Esophageal Cancer: Tertiary Centre Experience.

Mahmoud Hussein Elshoieby, and Khalid Rezk and Hussein Fakhry

Surgical Oncology Department, South Egypt Cancer Institute, Assiut University. elshoieby@live.co.uk

Abstract: Background: we aim to compare the outcome of two techniques of recontinuity after subtotal esophagectomy for esophageal cancer: cervical esophagogastricanastomosis with invagination of the cervical esophageal stump and direct end to end anastomosis with gastric tube, mainly for incidence of post-operative fistula and stenosis. **Patients & Methods:** A prospective included all operable patients admitted to South Egypt Cancer Institute in period of beginning of 2013 to end of 2015 with cancer middle and lower third cancer esophagus underwent subtotal esophagectomy with cervical esophagogastric anastomosis. Patients were grouped according to the method of recontinuity into 2 groups: - Group 1: cervical esophagogastricanastomosis with invagination of the cervical esophageal stump (21 patients). - Group 2: direct end to end cervical esophagogastricanastomosis with gastric tube (21 patients). **Results:** Postoperative fistula at esophagogastric anastomosis was diagnosed in 9 (21.4%) patients, 7 patients had minimal leakage of air or saliva through cervical incision while 2 patients had mild to moderate leakage which required fistula repair. Postoperative stenosis was noticed 13 (31%) patients whom were managed well by regular endoscopic dilatation. Incidence of postoperative fistula was significantly lower in group I compared to group II (3 (33.3%) versus 6 (66.7%), $p= 0.040$). Similarly, incidence of postoperative stenosis was significantly lower in group I compared to group II (4 (30.8%) versus 9 (69.2%), $P = 0.036$). **Conclusions:** cervical esophagogastric anastomosis with invagination of the proximal esophageal stump into the stomach after subtotal esophagogastric anastomosis regarding postoperative fistula and stenosis.

[Mahmoud Hussein Elshoieby, and Khalid Rezk and Hussein Fakhry. **Esophagogastric Anastomosis with Invagination of Esophageal Stump into Stomach versus Direct End To End Anastomosis after Subtotal Esophagectomy for Esophageal Cancer: Tertiary Centre Experience.** *Cancer Biology* 2018;8(3):1-8]. ISSN: 2150-1041 (print); ISSN: 2150-105X (online). <http://www.cancerbio.net>. 1. doi:[10.7537/marscbj080318.01](https://doi.org/10.7537/marscbj080318.01).

Key Words: Esophageal cancer, Esophagogastric anastomosis, Invagination of esophageal stump, Telescopic surgery, Esophageal fistula

1. Introduction

Esophageal cancer is the ninth most common cancer worldwide, with 442,000 new cases annually, and the sixth most common cause of cancer death, with 440,000 deaths annually [1]. Esophageal cancer represents 6–8% of all malignancies in Egypt with mean age of 58.7 years [2]. The advances in technology combined with understanding of genomics and biology of esophageal cancer has allowed introduction of era of multimodality treatment. Despite advances in cancer care, malignancy of the esophagus continues to portend a poor prognosis, with 5-year survival rates of 15% to 40% [3-5].

One of the main factors in surgical success is enblock resection of the tumor with negative margins. Roder et al. showed that survival duration was significantly reduced if there was residual tumor and concluded that only patients in whom R0 resection can be anticipated based on preoperative assessment should undergo primary resection for esophageal cancer [6].

Esophagectomy is a chief surgery that has both a high morbidity rate (60%) and mortality rate, which may reach 26.7%, as shown in a large series of cases

included two thousand trans-hiatal esophagectomies, mostly due to pulmonary complications, mediastinitis, anastomotic fistulas, stenosis of anastomotic line and necrosis of the gastric conduit [7].

In the presence of major levels of mortality and morbidity associated with the high incidence of esophagogastric fistulas, many surgical techniques have been tried to decrease the incidence of fistula formation. These methods included: two-staged anastomosis [8], laparoscopic preparation of the gastric conduit before the esophageal resection surgery [9], revascularization of the gastric tube [10], omentoplasty of cervical esophagogastric anastomosis [11], stapled anastomosis [12], mucosal tube technique [13] and telescopic anastomosis (with invagination) [14].

In this study, we aim to compare the outcome of two techniques of recontinuity after subtotal esophagectomy for esophageal cancer: cervical esophagogastricanastomosis with invagination of the cervical esophageal stump and direct end to end anastomosis with gastric tube, mainly for incidence of post-operative fistula and stenosis.

2. Material and Methods

Study design and patients:

This study included all operable patients admitted to South Egypt Cancer Institute in period of beginning of 2013 to end of 2015 with cancer middle and lower third cancer esophagus either received neoadjuvantchemoradiation or not and underwent subtotal esophagectomy with cervical esophagogastric anastomosis.

Exclusion criteria include all locally advanced or metastatic esophageal cancer patients and also patients who had anesthetic contraindications due to compromised clinical state and/or serious comorbidities.

Patient Grouping:

We compared some surgical morbidity and mortality outcome especially rate of fistula and stenosis which evaluated clinically, radiologically and by upper endoscopy, and its impact on recovery of patients between two groups of patients.

Group 1: underwent subtotal esophagectomy for esophageal cancer with cervical esophagogastricanastomosis with invagination of the cervical esophageal stump.

Group 2: underwent subtotal esophagectomy for esophageal cancer with direct end to end cervical esophagogastricanastomosis with gastric tube.

Preoperative workup:

All patients underwent surgery properly evaluated by:

Routine laboratory investigations.

Multislice CT chest and pelvi-abdomen.

Upper endoscopy, pulmonary function tests.

PET-CT scan in selected cases especially those received neoadjuvant therapy.

Surgical technique:

All operative procedures were carried out by one team, operating in the abdominal, thoracic and cervical regions. Lymph node dissection was done in both the abdominal and lower mediastinal fields. In all cases the gastric tube was pulled up to the cervical region through the posterior mediastinum.

The proximal esophagus was carefully dissected and separated from its adjacent structures in the cervical, thoracic, and abdominal areas. The esophagus was resected in the cervical region, with preservation of proximal 3-4cm of esophagus to be invaginated into the stomach, with a safety margin of grossly 5.0 cm at minimum away from the tumor. The stomach was divided with a linear stapler which released the resection specimen followed by preparation of gastric tube.

In the part selected for anastomosis in cervical stump, either a direct end to end anastomosis (in group II) or small a transverse myotomy was carried out around the entire circumference of the esophagus (Figure 1-A) then the upper border of the myotomy anastomosed with the tip of the pulled up gastric

conduit in the cervical region (in group I). Anastomosis of the posterior wall was performed first by using suture of 3-0 polyglactin (Vicryl) (Figure 1-B). Afterwards, the proximal esophageal 4.0 cm segment was invaginated into the stomach. Lastly, anastomosis of the anterior wall was done similar to the one performed on the posterior wall (Figure 1-C).

Pyloroplasty was done to avoid gastroparesis, and a naso-enteral tube was inserted, in some cases feeding jejunostomy tube for feeding, an intercostal tube and abdominal & cervical drains were inserted.

All patients underwent contrast study at an average of 5th day postoperatively. Oral feeding was usually started between the 7th-10th postoperative day, in the absence of signs of esophagogastric fistula. If a fistula was present, it managed according to its output, and feeding was maintained by the feeding tube till closure of fistula.

Statistical analysis

The data were tested for normality using the Anderson-Darling test and for homogeneity variances prior to further statistical analysis. Categorical variables were described by number and percent (N, %), where continuous variables described by mean and standard deviation (Mean, SD). Chi-square and fisher exact tests used to compare between categorical variables where compare between continuous variables by Unpaired t-test. Pearson correlation coefficient used to assess the association between continuous variables. A two-tailed $p < 0.05$ was considered statistically significant. All analyses were performed with the IBM SPSS 20.0 software.

3. Results

In our study, forty-two patients with middle and lower third esophageal cancer and underwent subtotal esophagectomy with cervical esophagogastric anastomosis were included with mean age about 54 years. Neoadjuvant chemotherapy and chemoradiation was given in 8(19.1%) patients. 26 (61.9%) patient had McEwen's approach while 16 (38.1%) patients had Trans-hiatal approach. Mean time for oral feeding was day 9 and mean hospital stay was about 19 days.

Postoperative fistula at esophagogastric anastomosis was diagnosed in 9 (21.4%) patients, 7 patients had minimal leakage of air or saliva through cervical incision at day 5-7 and spontaneous closure occurred with conservative treatment, while 2 patients had mild to moderate leakage did not improve on conservative measures and required fistula repair.

Postoperative stenosis was noticed 13 (31%) patients who presented with dysphagia, which occurred 15-62 day postoperatively, and was managed well by regular endoscopic dilatation. No intraoperative mortality (Table 1).

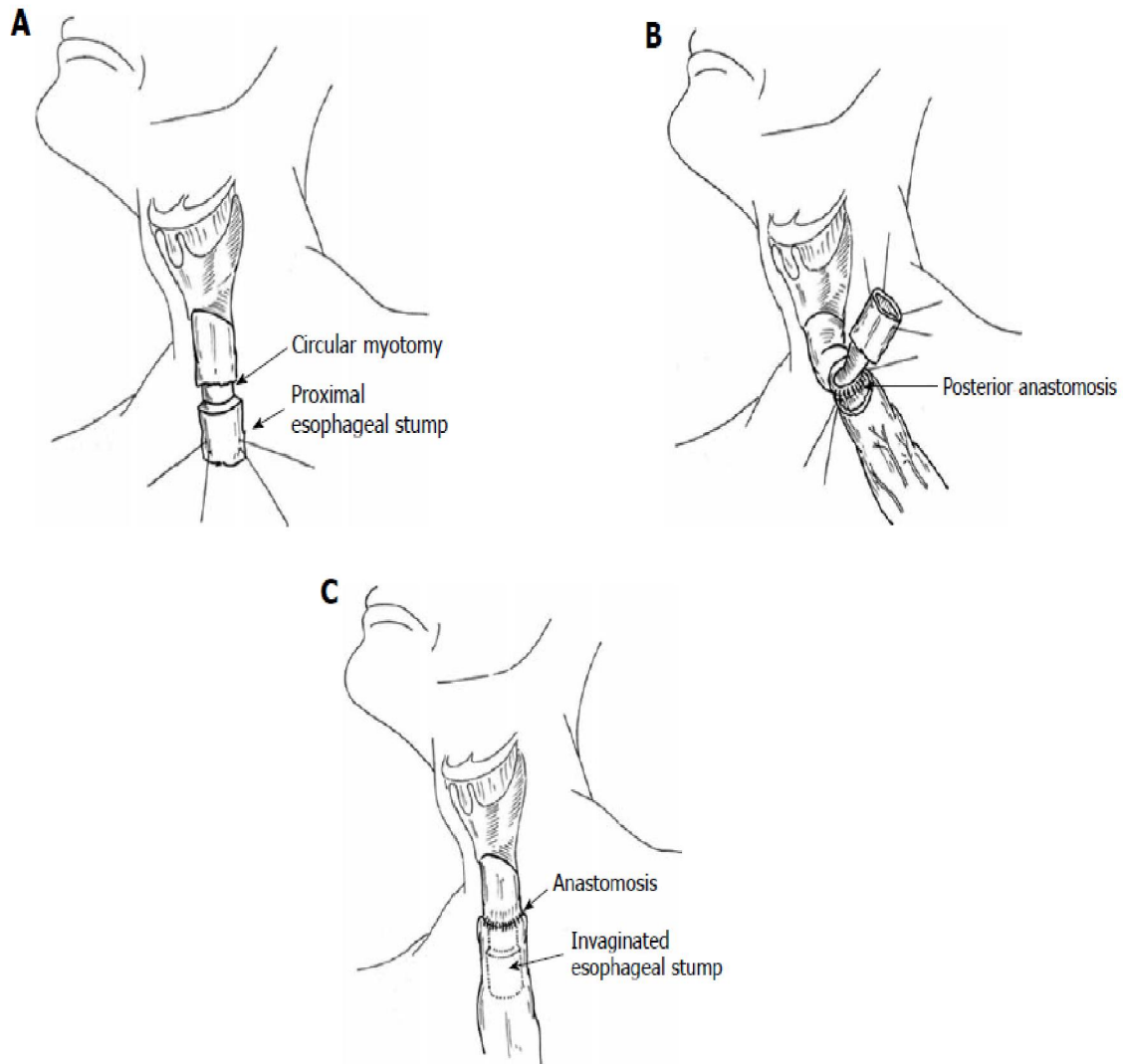


Figure 1. Esophago-gastric anastomosis with stomach invagination:

A: Diagram showing the circular myotomy (long arrow) in the section of the proximal esophageal stump (short arrow), which created a 4.0 cm segment of extension to be invaginated into the stomach;

B: Diagram showing the anastomosis of the posterior wall of the esophagus performed first using interrupted sutures;

C: Diagram showing the sectioned esophagus protruding into the stomach (The illustration of the trachea was omitted).

Adopted from Henriques et al. [14]

Table 1: Socio-demographic and clinical characteristics of the studied cases

Variable	Category	n = 42
Age in years (Mean ± SD)		53.98 ± 9.4
Sex	• Male	25 (59.5%)
	• Female	17 (40.5%)
Tumor Site	• NOS	19 (45.2%)
	• Lower Third	19 (45.2%)
	• Middle Third	19 (9.6%)
Co-morbidity	• Yes	13 (31%)
Type of Subtotal Esophagectomy	• McEwen	26 (61.9%)

Variable	Category	n = 42
	• Trans-hiatal	16 (38.1%)
Time to oral feeding/days (Mean ± SD)		8.71 ± 2.5
Hospital stay/days (Mean ± SD)		19.31 ± 8.9
Post-operative Fistula	• Yes	9 (21.4%)
Post-operative Stenosis	• Yes	13 (31%)
Neo-adjuvant Chemotherapy	• Yes	6 (14.3%)
Neo-adjuvant Chemoradiation	• Yes	2 (4.8%)
Adjuvant Therapy	• Yes	25 (59.5%)

Patients were categorized according esophagogastric anastomosis technique after subtotal esophagectomy for esophageal cancer into two groups; Group I included 21 (50%) patients underwent esophagogastricanastomosis with invagination of the cervical esophageal stump and Group II included 21 (50%) patients underwent direct end to end esophagogastricanastomosis.

Incidence of postoperative fistula was significantly lower in group I compared to group II (3 (33.3%) versus 6 (66.7%), $p= 0.040$). Similarly, incidence of postoperative stenosis was significantly lower in group I compared to group II (4 (30.8%) versus 9 (69.2%), $P = 0.036$). No other significant difference in other factors between the two groups (Table 2).

Table 2: Socio-demographic and Clinical Data Differences between the two studied groups

	Group I (No.=21)	Group II (No.=21)	P-value
Age in years	51.81 ± 10.3	56.14 ± 8.1	= 0.138*
Sex			
• Male	7 (33.3%)	10 (47.6%)	= 0.346**
• Female	14 (66.7%)	11 (52.4%)	
Tumor Site			
• NOS	13 (61.9%)	6 (28.6%)	=0.100**
• Lower Third	6 (28.6%)	13 (61.9%)	
• Middle Third	2 (9.5%)	2 (9.5%)	
Co-morbidity			
• No	14 (66.7%)	15 (71.4%)	= 0.500**
• Yes	7 (33.3%)	6 (28.6%)	
Type of Subtotal Esophagectomy			
• McEwen	12 (57.1%)	14 (66.7%)	= 0.376**
• Trans-hiatal	9 (42.9%)	7 (33.3%)	
Time to oral feeding/days	8.59 ± 2.3	19.09 ± 5.1	= 0.250*
Hospital stay/days	8.48 ± 2.6	19.52 ± 4.6	= 0.480*
Post-operative Complications			
• Fistula	3 (33.3%)	6 (66.7%)	= 0.040**
• Stenosis	4 (30.8%)	9 (69.2%)	

*Mann-Whitney U test was used to compare the median difference between groups

**Chi-square test was used to compare the percentages between groups

4. Discussion

Radical esophagectomy for most patients remains the cornerstone of any potential cure for localized resectable esophageal cancers or as secondary to achieve R0 resection after down staging disease with neo adjuvant chemo therapy or after chemoradiation [15-17]. However, esophagectomy is a complex oncological procedure, and except in specialized centers, mortality and morbidity rates approximate 10% and 35%, respectively [18]. Most serious complications are mainly due to pulmonary complications, cervical fistulas, stenosis of anastomosis, necrosis of the gastric conduit, and mediastinitis. The largest prospective outcome cohort in the literature reported a morbidity rate of 50% and mortality rate of 10% [19].

In cases in which the fistula does not lead directly to death, it may compromise quality of life by interfering with resumption of feeding and prolong hospital stay. Additionally, 30% to 50% of those patients who present with fistula go on to develop stenosis [20].

Left cervical esophagogastrostomy is currently the most common method for esophageal reconstruction after subtotal esophagectomy. The advantages and disadvantages of hand-sewn, linear-stapled, or circular-stapled anastomoses have been subject to debate in recent years [21].

The history of invagination (telescopic) anastomosis can be traced back to the end of the 19th century, published first as the ideas of the surgeons Sonnenburg and Maylard [22]. It was originally proposed for ileocolicrecontinuity following right hemicolectomy but with high leakage rate. This concept was then first applied to esophagogastric anastomosis by Sauerbruch and Bircher who performed telescopic esophagogastrostomas in the early 1930s [23].

In their work, from June 1991 to May 2001 – over 10 years –, Szücs et al. enrolled 131 patients who underwent resection for esophageal cancer and 77 for gastric cancer, when the continuity of the alimentary tracts were reconstructed using telescopic anastomosis. Ninety-six transthoracic and 12 transhiatalesophagectomies were performed. One hundred and ten cervical anastomoses and 21 intrathoracic anastomoses were made. Of these cases, 108 cases underwent esophagectomy with esophagogastric anastomosis and telescoping of a 10-15 mm length of the esophageal end into the stomach. Twelve patients (9.2%) of 131 developed fistula at the anastomotic site in all cases of telescopic esophagogastrostomy with the leakage rate was 12 of 108 (11.1%) after cervical telescopic

esophagogastrostomy [24].

Another remarkable cohort study was conducted by Henriques et al. to evaluate rate of post-operative fistula, its clinical consequences and rate of anastomotic stenosis following cervical esophagogastrostomy with invagination of esophageal stump in gastric tube. They published their work in two series of cases [14, 25]. The first study, included 54 patients who underwent subtotal esophagectomy, 45 (83.3%) patients with carcinoma and nine (16.6%) with advanced megaesophagus. Three (5.5%) patients had a fistula at the esophagogastric anastomosis, two of whom with minimal leakage of air or saliva and with mild clinical repercussion; the third had a low output fistula that drained into the pleural space, and this patient developed empyema that showed good progress with drainage. Fibrotic stenosis of anastomosis occurred in thirteen (24%) subjects and was treated successfully with endoscopic dilatation [25]. The other series included a group of 31 patients with thoracic and abdominal esophageal cancer underwent cervical esophagogastric anastomosis with invagination of the proximal esophageal stump into the stomach tube. Postoperative minor complications occurred in 22 (70.9%) patients. Four (12.9%) patients had serious complications that led to death. Three (9.7%) patients had fistula at the esophagogastric anastomosis, with minimal leakage of air or saliva and with mild clinical repercussions. No patients had esophagogastric fistula with intense saliva leakage from either the cervical incision or the thoracic drain. Fibrotic stenosis of anastomoses occurred in seven (22.6%) patients. All these patients obtained relief from their dysphagia with endoscopic dilatation of the anastomosis [14].

We adopted surgical technique similar to that described by Henriques et al. [14] which is quite different from the one adopted by Szücs et al. [24] who only invaginated a 10-15-mm length of the esophageal end into the stomach. In the region elected for anastomosis, a transverse myotomy of the esophagus was carried out around the entire circumference of the esophagus. Afterwards, a 4-cm long segment of esophagus was invaginated into the stomach and anastomosed to the anterior and the posterior walls. This method is proposed not only to cover the entire site of the anastomosis, but also to encourage the discharge of saliva at a lower region, while attempting to leave the anastomosis site out of alimentary transit [14].

The proximal level of esophageal resection is chosen to balance between the oncologic need of at least 5-cm tumor free margin proximal to the tumor and the technical demand of a mobilized 4 cm length

of esophageal stump to be invaginated into the gastric tube. These 4 cm is not considered a compromise to oncologic radical esophageal resection as it is less than the length left in cases of thoracic anastomosis which – as documented in many publications- is not oncologic inferior to esophagectomy with cervical end-to-end anastomosis [26].

In our work, postoperative fistula at esophagogastric anastomosis was diagnosed in 9 (21.4%) patients, 7 patients had minimal leakage of air or saliva through cervical incision at day 5-7 and spontaneous closure occurred with conservative treatment, while 2 patients had mild to moderate leakage did not improve on conservative measures and required fistula repair.

We –in contrast to previous studies- used a control group to evaluate the outcome on both groups among homogenous cohort of patients. Our data suggest that the incidence of postoperative fistula was significantly lower in group I (invagination group) compared to group II (no-invagination group) (Three (33.3%) vs. Six (66.7%), $p=0.040$).

To establish diagnosis of fistula, we evaluate patients clinically –discharge in neck incision or pleural catheter drain-, radiologically–by gastrographin swallow radiographs- and upper endoscopy.

Stenosis is reported to develop in 5% to 50% of all operated cases, and can manifest itself up to one year after surgery. In addition to fistula, other factors, such as cardiac insufficiency, ischemia of the gastric fundus, and mechanical anastomosis can contribute to the development of stenosis [27, 28]. Anastomotic leakage, chemoradiotherapy and early development of stricture were independently associated with the development of refractory strictures, requiring a higher number of dilations [28].

Diagnosis of postoperative stenosis was assigned when diameter of esophagogastric anastomosis is less than 10mm in gastrographin radiographs or endoscopy. Overall postoperative stenosis was noticed 13 (31%) patients who presented with dysphagia, which occurred 15-62 day postoperatively, and was managed well by regular endoscopic dilatation. Similarly, the incidence of postoperative stenosis was significantly lower in group I compared to group II (4 (30.8%) versus 9 (69.2%), $P=0.036$).

It is important to note that the true incidence of postoperative fistula may not be much lower in invagination technique but its clinical significance and consequences on patient's outcome has favorably much less impact. As the saliva flows to an area below the anastomosis, these leakages probably can undergo rapid regeneration. On the other hand, in cases without invagination, the saliva discharges directly into the area of the suture with dehiscence, which induces local inflammation and infection, thereby delaying the

healing process of the suture line.

Similarly, anastomosis with invagination may not influence the factors that might predispose to stenosis; but with reduced clinical consequences of these events could possibly trigger a fibrotic reaction and scarring, with subsequent stenosis formation in the anastomosis.

Another surgical technique is adopted by Sen Wu et al. [29]. They perform end-to-side esophagogastronomy with a circular stapler by embedding the anastomosis and the remaining esophagus into the residual stomach, placing it into the gastric cavity to prevent erosion by saliva, and further surrounding it by the proximal stomach to prevent gastroesophageal reflux. A total of 123 patients (96.9 %) had successful surgery, and 4 patients (3.3 %) developed anastomotic leakage, with the total morbidity of 20 of 123 (16.3 %) and in-hospital mortality of 1 of 123 (0.8 %). The incidence of stricture affected 14 of 123 patients (11.4 %). Eight patients underwent dilatation treatment as a result of severe dysphagia (6.5%). They concluded that embedded cervical esophagogastronomy with circular stapler is a simple and convenient method which not only facilitates the healing of the anastomosis but can also reduce the incidence of gastroesophageal reflux [29].

Differences in survival after major cancer resections have been demonstrated in high- compared with low- volume medical centers [30]. Both increased surgeon and hospital volume have been shown to decrease operative mortality after esophagectomy [31, 32]. These findings have led some to recommend that complex oncological surgery be performed only in centers with experience and sufficient volume.

Conclusions

In conclusion, cervical esophagogastric anastomosis with invagination of the proximal esophageal stump into the stomach after subtotal esophagogastrectomy in patients with esophageal cancer is better and advantageous over conventional direct end to end esophagogastricanastomosis regarding postoperative fistula and stenosis.

However, randomized controlled larger studies which involve esophagogastric anastomosis with invagination of the proximal esophageal stump into the pulled-up gastric conduit are needed to confirm the initials results obtained in this study.

References

1. Fitzmaurice C., Dicker D., Pain A., Hamavid H., Moradi-Lakeh M., et al. The Global Burden of Cancer 2013. *JAMA Oncol* 2015. 1(4): p. 505-27.
2. Ezzat S, Hossieny HE, and Alla MA. A clinicoepidemiological study of esophageal cancer patients at the National Cancer Institute,

- Cairo University, Egypt. *Oncol Transl Med* 2016. 2: p. 1-7.
3. Ando N., Ozawa S., Kitagawa Y., Shinozawa Y., and Kitajima M. Improvement in the results of surgical treatment of advanced squamous esophageal carcinoma during 15 consecutive years. *Ann Surg* 2000. 232(2): p. 225-32.
 4. Ellis F. H., Jr., Heatley G. J., Krasna M. J., Williamson W. A., and Balogh K. Esophagogastrectomy for carcinoma of the esophagus and cardia: a comparison of findings and results after standard resection in three consecutive eight-year intervals with improved staging criteria. *J Thorac Cardiovasc Surg* 1997. 113(5): p. 836-46; discussion 846-8.
 5. Millikan K. W., Silverstein J., Hart V., Blair K., Bines S., et al. A 15-year review of esophagectomy for carcinoma of the esophagus and cardia. *Arch Surg* 1995. 130(6): p. 617-24.
 6. Roder J. D., Busch R., Stein H. J., Fink U., and Siewert J. R. Ratio of invaded to removed lymph nodes as a predictor of survival in squamous cell carcinoma of the oesophagus. *Br J Surg* 1994. 81(3): p. 410-3.
 7. Orringer M. B., Marshall B., Chang A. C., Lee J., Pickens A., et al. Two thousand transhiatal esophagectomies: changing trends, lessons learned. *Ann Surg* 2007. 246(3): p. 363-72; discussion 372-4.
 8. Oezcelik A., Banki F., DeMeester S. R., Leers J. M., Ayazi S., et al. Delayed esophagogastrotomy: a safe strategy for management of patients with ischemic gastric conduit at time of esophagectomy. *J Am Coll Surg* 2009. 208(6): p. 1030-4.
 9. Holscher A. H., Schneider P. M., Gutschow C., and Schroder W. Laparoscopic ischemic conditioning of the stomach for esophageal replacement. *Ann Surg* 2007. 245(2): p. 241-6.
 10. Yoshimi F., Asato Y., Ikeda S., Okamoto K., Komuro Y., et al. Using the supercharge technique to additionally revascularize the gastric tube after a subtotal esophagectomy for esophageal cancer. *Am J Surg* 2006. 191(2): p. 284-7.
 11. Dai J. G., Zhang Z. Y., Min J. X., Huang X. B., and Wang J. S. Wrapping of the omental pedicle flap around esophagogastric anastomosis after esophagectomy for esophageal cancer. *Surgery* 2011. 149(3): p. 404-10.
 12. Kunisaki C., Makino H., Akiyama H., Nomura M., Otsuka Y., et al. Predictive factors for anastomotic leakage in the neck after retrosternal reconstruction for esophageal cancer. *Hepatogastroenterology* 2008. 55(81): p. 98-102.
 13. Maciver R. H., Sundaresan S., De Hoyos A. L., Sisco M., and Blum M. G. Mucosal tube technique for creation of esophageal anastomosis after esophagectomy. *Ann Thorac Surg* 2009. 87(6): p. 1703-7.
 14. Henriques A. C., Godinho C. A., Saad R., Jr., Waisberg D. R., Zanon A. B., et al. Esophagogastric anastomosis with invagination into stomach: New technique to reduce fistula formation. *World J Gastroenterol* 2010. 16(45): p. 5722-6.
 15. Kakegawa T. Forty years' experience in surgical treatment for esophageal cancer. *Int J Clin Oncol* 2003. 8(5): p. 277-88.
 16. Markar S. R. and Low D. E. Physiology, not chronology, dictates outcomes after esophagectomy for esophageal cancer: outcomes in patients 80 years and older. *Ann Surg Oncol* 2013. 20(3): p. 1020-6.
 17. Pultrum B. B., Bosch D. J., Nijsten M. W., Rodgers M. G., Groen H., et al. Extended esophagectomy in elderly patients with esophageal cancer: minor effect of age alone in determining the postoperative course and survival. *Ann Surg Oncol* 2010. 17(6): p. 1572-80.
 18. Martin R. C., 2nd, Brennan M. F., and Jaques D. P. Quality of complication reporting in the surgical literature. *Ann Surg* 2002. 235(6): p. 803-13.
 19. Bailey S. H., Bull D. A., Harpole D. H., Rentz J. J., Neumayer L. A., et al. Outcomes after esophagectomy: a ten-year prospective cohort. *Ann Thorac Surg* 2003. 75(1): p. 217-22; discussion 222.
 20. Orringer M. B., Marshall B., and Iannettoni M. D. Eliminating the cervical esophagogastric anastomotic leak with a side-to-side stapled anastomosis. *J Thorac Cardiovasc Surg* 2000. 119(2): p. 277-88.
 21. Boone J., Livestro D. P., Elias S. G., Borel Rinkes I. H., and van Hillegersberg R. International survey on esophageal cancer: part I surgical techniques. *Dis Esophagus* 2009. 22(3): p. 195-202.
 22. Moore W. J. and Forrest-Hamilton J. The Maylard-Sonnenburg method of intestinal anastomosis. *Br Med J* 1953. 2(4851): p. 1407-9.
 23. W Fisher A, Die Operationen am Oesophagus, in *Chirurgische Operationslehre*, Bier A, Braun H, and Kümmel H, Editors. 1955, Verlag. p. 353-420.
 24. Szucs G., Toth I., Gyani K., and Kiss J. I. Telescopic esophageal anastomosis: operative technique, clinical experiences. *Dis Esophagus* 2003. 16(4): p. 315-22.
 25. Henriques A. C., Fuhro F. E., Godinho C. A., Campos A. L., and Waisberg J. Cervical

- esophagogastric anastomosis with invagination after esophagectomy. *Acta Cir Bras* 2012. 27(5): p. 343-9.
26. Walther B., Johansson J., Johnsson F., Von Holstein C. S., and Zilling T. Cervical or thoracic anastomosis after esophageal resection and gastric tube reconstruction: a prospective randomized trial comparing sutured neck anastomosis with stapled intrathoracic anastomosis. *Ann Surg* 2003. 238(6): p. 803-12; discussion 812-4.
 27. Cassivi S. D. Leaks, strictures, and necrosis: a review of anastomotic complications following esophagectomy. *Semin Thorac Cardiovasc Surg* 2004. 16(2): p. 124-32.
 28. van Heijl M., Gooszen J. A., Fockens P., Busch O. R., van Lanschot J. J., et al. Risk factors for development of benign cervical strictures after esophagectomy. *Ann Surg* 2010. 251(6): p. 1064-9.
 29. Wu S., Chen M., Wei L., and Chen Z. Embedded cervical esophagostomy: a simple and convenient method using a circular stapler after esophagectomy for esophageal carcinomas. *Ann Surg Oncol* 2013. 20(9): p. 2984-90.
 30. Bach P. B., Cramer L. D., Schrag D., Downey R. J., Gelfand S. E., et al. The influence of hospital volume on survival after resection for lung cancer. *N Engl J Med* 2001. 345(3): p. 181-8.
 31. Birkmeyer J. D., Stukel T. A., Siewers A. E., Goodney P. P., Wennberg D. E., et al. Surgeon volume and operative mortality in the United States. *N Engl J Med* 2003. 349(22): p. 2117-27.
 32. Van Lanschot J. J., Hulscher J. B., Buskens C. J., Tilanus H. W., ten Kate F. J., et al. Hospital volume and hospital mortality for esophagectomy. *Cancer* 2001. 91(8): p. 1574-8.

7/3/2018