

External Beam Radiotherapy versus High Dose Rate Brachytherapy plus External Beam Radiotherapy in locally advanced uterine cervical cancer

*Elumelu TN., *Oladeji A., *Adenipekun A., Elumelu T.N MBBS, DPC, FMCR, FWACS, MBA

*Department of Radiotherapy College of Medicine, University of Ibadan

Corresponding Author: Department of Radiotherapy, College of Medicine, University of Ibadan, Ibadan, Oyo State, Nigeria. Email- telumelu@com.ui.edu.ng, tessynek@yahoo.com 1

Abstract: Introduction: Prior to 2008 when High Dose Rate (HDR) Brachytherapy was installed in Radiotherapy Department of University College Hospital (UCH), Ibadan, patient with locally advanced cancer of cervix were treated with chemotherapy and External Beam Radiotherapy (EBRT), but with the advent of HDR brachytherapy facility, patients are treated now with chemotherapy, EBRT and brachytherapy. Aim: This a retrospective evaluation of the treatment outcome of patients with locally advanced squamous cell carcinoma of the cervix treated with external beam radiotherapy and high-dose-rate brachytherapy, compared with the patients that had external beam radiotherapy alone. Material and Methods: The treatment records of patients with locally advanced uterine cervical cancer (FIGO stage IIB-IVA), treated with EBRT alone (Group I) and those treated with High Dose Rate Brachytherapy and EBRT (Group II) were extracted from case notes and radiotherapy treatment cards for analysis. Results: 179 cases in all divided into Group I (109) and Group II (70). In Group I, 19(17%) had local relapse, 8(7.3%) suffered persistence disease, 4(3.7%) had distance metastases, hepatic metastasis (2), lungs (1) and pelvic bone (1), 3(2.8%) died from disease progression, while 75(68.8%) were disease free. For Group II 7(10%) recorded local failure, persistence disease in 3(4.3%), malignant pleural effusion in 1(1.48%) and 59(84.3%) of the patients were disease free. Conclusion: The results of this study demonstrated some degree of therapeutic advantage of combining EBRT and HDR over EBRT alone in the management of locally advanced cancer of cervix. However, the therapeutic ratio of EBRT/HDR is low, making the adverse effect to be more compared with EBRT only.

[Elumelu TN., Oladeji A., Adenipekun A., Elumelu T.N MBBS, DPC, FMCR, FWACS, MBA. **External Beam Radiotherapy versus High Dose Rate Brachytherapy plus External Beam Radiotherapy in locally advanced uterine cervical cancer.** *Cancer Biology* 2018;8(2):90-96]. ISSN: 2150-1041 (print); ISSN: 2150-105X (online). <http://www.cancerbio.net>. 12. doi:[10.7537/marscbj080218.12](https://doi.org/10.7537/marscbj080218.12).

Key Words: Cancer of cervix, External Beam Radiotherapy, High Dose Rate Brachytherapy.

1 Introduction

Cervical cancer continues to be a significant health burden in developing countries such as Nigeria, where most cases are locally advanced at diagnosis; hence, radiation remains the most frequently used modality of treatment.

High Dose Rate (HDR) Brachytherapy is relatively new in the country. Before 2008, patients were treated with external Beam radiotherapy as the only form of radiotherapy; but now most patients are treated with both external beam radiotherapy and HDR Brachytherapy.

Although many decades of experience and literature reports on the use of HDR brachytherapy for treatment of cervix cancer are available in world literature, not many contributions from Nigeria are available. This retrospective study aims to report our experience with HDR brachytherapy in the treatment of patients with cervical cancer, analyzing the treatment outcome and complications and comparing these with those treated before the advent of HDR brachytherapy.

Cervical cancer is the most common cancer among women in most of sub-Saharan Africa 1.

However in Nigeria, cervical cancer is second only to breast cancer 2. GLOBOCAN in 2008 estimated the incidence of cervical cancer in Nigeria to be 32.9 per 100000.3

Over 90% of cervical cancers are [squamous cell carcinomas](#), arising in the [squamous epithelial cells](#) that line the cervix. Followed by invasive adenocarcinoma (7-10%) 4 which may be pure or mixed with squamous cell carcinoma (adenosquamous carcinoma) arising in the glandular [cells](#) of the endocervix. Very rarely, cancer can arise in other types of cells in the cervix 5

Squamous-cell carcinoma of the uterine cervix usually originates at the squamous columnar junction of the cervix. The lesion is frequently associated with severe cervical dysplasia and carcinoma in situ, which over a period of 10 to 20 years may progress to invasive carcinoma6.

Cancer of cervix, if untreated, may spread to the adjacent vaginal fornices or to the paracervical and parametrial tissues, with eventual direct invasion of the bladder, the rectum, or both. Hematogenous dissemination may occur through the venous plexus and the paracervical veins, the metastatic sites are

usually the lungs, para-aortic lymph nodes, liver, bone (commonly lumbar, thoracic spine and pelvic bone), and brain. 4

The early stages of cervical cancer may be completely [asymptomatic](#), 7 [abnormal vaginal bleeding](#), contact bleeding and sometimes a vaginal mass may indicate the presence of malignancy. Other symptoms include moderate pain during sexual intercourse, post coital bleeding and foul smelling vaginal discharge. Metastatic disease may be present with the signs related to organ involved, e.g. cough or dyspnea in pulmonary metastases. Other symptoms of advanced cervical cancer may include: loss of appetite, weight loss, fatigue, pelvic pain, back pain, leg pain, and pedal oedema, a vesicovaginal or rectovaginal fistulae and bone fractures.8

2 Etiological factors for developing cancer of cervix are:

Human papilloma virus (HPV) infection with high-risk types 16 & 18. Omigbodun et al, have showed that a high prevalence of HPV infection in middle and old age women in Ibadan, Nigeria was contributory for high incidence of cervical cancer in Nigeria. 9

Factors that determine the type of treatment a patient will receive would depend on the stage of the disease, histological type, age of the Patient, medical co -morbidity, the patient's desire, and expertise available.

Surgery which incorporates several procedures e.g. Hysterectomy plays a curative role only in very early stage of cervical cancer. Radiotherapy is an effective treatment modality for all stages of cancer of the Cervix also used in developing countries. 10.

Combining External beam radiotherapy (EBRT) with intracavitary brachytherapy (BT) is the standard radiotherapy treatment for patients with cervical cancer 11-12 In the early 2000s concurrent chemo radiotherapy (CCRT) became standard after the National Cancer Institute (NCI) announcement recommending concurrent chemotherapy in 1999. 7 According to the International Federation of Gynecology and Obstetrics, survival improves when radiotherapy is combined with Cisplatin-based chemotherapy.8

Therefore external beam pelvic radiotherapy with concurrent chemotherapy followed by brachytherapy (BT) is now internationally accepted as the standard treatment of locally advanced cervical cancer. While metastatic disease (Stage 1Vb) is treated with Palliative radiotherapy to metastatic sites plus chemotherapy.

Prognosis depends on the stage of the cancer. With treatment, the 5-year [relative survival rate](#) for the earliest stage of invasive cervical cancer is 92% while

only 25 to 35% of women with stage III cancer and 15% or fewer of those with stage IV cancer are alive after 5 years.13

Since the demise of support for Low-dose rate (LDR) brachytherapy, HDR brachytherapy has been widely used in the management of cervical cancer for many decades in Asia and Europe, but it is relatively new in Nigeria where its use was commenced in July 2008 at University College Hospital (UCH), Ibadan, the only center that currently has this facility in the country. This implies that prior to July 2008; most patients with cervical cancer were treated with external beam radiotherapy as the only form of radiotherapy treatment.

In this study, we retrospectively review the treatment outcome of patients with advanced squamous uterine cervical cancer, treated in the era of EBRT alone and those treated with HDR Brachytherapy and EBRT. All the patients had concurrent chemo- radiation therapy.

3 Material and Method

All cases of locally advanced squamous cell carcinoma of the uterine cervix (FIGO stage IIB-IVA) seen between January 2007 and December 2009 at Radiotherapy department of the University College Hospital Ibadan Nigeria were reviewed for this study. The cases were then divided into two groups, those treated with EBRT alone (Group I) before the advent of HDR brachytherapy (in 2008) and those treated with EBRT and HDR brachytherapy (Group II).

Treatment

All patients received external beam radiotherapy using megavoltage machine (Co 60 equipment with average photon-beam energy of 1.25Mv) to the whole pelvis for a dose range of 45-60Gy in 4 to 6 weeks (Av. Dose is 46.5 Gy + 6.18Gy). The superior border of the pelvic field was L4/5 border and the inferior border was at the lower border of the obturator foramen or 2 cm below the vaginal extent of the disease. The lateral border was 2 cm lateral to the widest true pelvic diameter. Patients were treated to mid plane dose.

Group II patients received EBRT (Av. Dose is 45.0 + 1.3Gy) and additional 2 or 3 sandwich intracavitary HDR brachytherapy insertions during the course of EBRT; with a planned biologic effective dose to point A of 80Gy.

All patients (Groups I & II) received concurrent chemotherapy. The chemotherapy received was either weekly Cisplatin (155 patients), or weekly 5-Fluorouracil (24 patients). Intravenous (iv) hydration of patients followed by Cisplatin 50 mg/m² was administered in infusion via a peripheral vein in outpatient clinic. Premedication with iv dexamethasone 8mg and ondansetron 8mg were

employed routinely. 5-Fluorouracil 1 gm/m² administered as bolus iv. injection for those that received weekly 5FU.

Adverse Effects Evaluation

The adverse effects documented in patients' records were noted.

Survival

Patients were seen six weeks post radiation therapy as first follow-up visit then every three months or earlier as patient's condition dictates for the first one year and six monthly thereafter. Full patient examination with complete blood count and other appropriate investigations (ultrasonography scan, CT scan, electrolyte and urea, etc.) were performed at follow-up visits to monitor progression free survival with intention to treat. Patients' survival was measured from the date of completion of therapy to the date of death or last follow up.

Results

267 patients with cancer of cervix were seen between January 2007 to June 2008, but only 109 patients were suitable to be enrolled into the "group 1" based on study criteria, and total of 141 patients with cancer of cervix had HDR and xRT between July 2008 and December 2009, of which only 70 patients were included for analysis based on same study criteria and these are grouped in to the "group 2"

In total, 179 cases of locally advanced squamous uterine cervical cancer cases (FIGO stage IIB-IVA) representing 43.9% of all cases recorded in the study period were analyzed. 109 had EBRT alone (Group I) while 70 had EBRT and HDR (Group II) as seen in table 1.

The age distribution of the patients ranges from 25 – 79, the age group with highest frequency was 51-60 year, and the mean age of patients was 54.65 ± 10.189 years.

The ECOG performance status were as follow: 84% of patients had performance status 0, 13% of the patients had performance status 1, while 03% of the patients had performance status of 2.

The percentage of the different stages in the two groups shown in table 1 revealed that stage IIB has the highest frequency in the two groups 42.2% and 47.1% in groups 1 & 2 respectively and stage IVA has the lowest frequency.

Table 2 show that 75(41.9%) of the patients presented with histological type poorly differentiated squamous carcinoma, 36%; well differentiated squamous carcinoma and 21.8% is moderately differentiated squamous carcinoma.

Majority of the patients (more than 64%) presented at our center more than 6months after noticing the symptoms.

The mean dose of EBRT received in group 1 is 46.5 Gy + 6.18Gy, while, Group II received dose of

45.0 + 1.3Gy from EBRT and 15.42 + 1.8Gy from HDR.

4 Treatment Outcome

The performance of the patients at evaluation, two years after treatment, is presented in [Table 3]. Those alive and without disease had a negative PAP smear done at least six months after treatment. The pelvic relapse or local recurrence, persistent disease, disease progression and distant metastasis were analyzed using the Kaplan-Meier¹⁴ method. Comparison of categorical variables was performed using the chi-square test, and the logistic regression method was used for analysis of complications experienced by the patients. Statistical significance was considered for p values of less than 0.05.

The table 3 shows the treatment outcome in term of local relapse, persistent disease, and distance metastasis. Among the 109 patients who had EBRT only, 19(17%) patients had local relapse, 8(7.3%) suffered persistence disease, 4(3.7%) had distance metastasis, 2 patients had hepatic metastasis, a patient each had metastasis to lungs and pelvic bone, 3(2.8%) died from disease progression, while 75(68.8%) were disease free. whereas among 70 patients who had both EBRT and HDR brachytherapy, 7(10%) patients recorded local failure, persistence disease was seen in 3(4.3%) of the patients, malignant pleural effusion was seen in 1(1.48%) of the patient and the disease free survival was seen in 59(84.3%) of the patients.

There is an indication of better treatment outcome in term of local disease control, persistent disease, and distance metastasis when compared patients treated with both EBRT/ HDR and those treated with EBRT alone.

5 Adverse effects

Adverse effects (acute and late) as shown in Table 4 are on the musculoskeletal (skin desquamation, perineal ulcer), gastrointestinal system (proctitis, enteritis) urogenital system (cystitis), vaginal stenosis, and subcutaneous fibrosis.

Sixty patients (34.5%) had side effects (Acute and Late), 26 (23.9%) patients of EBRT group and 34(48.6%) of EBRT/HDR group. Ten patients had skin desquamation, 9 patients (8.3%) from EBRT group and one patient (1.4%) from EBRT/HDR group. 22.9%, 18.6% and 4.3% had proctitis, stenosis & cystitis respectively following EBRT and HDR while only 6.4%, 2.9% and 2.8% had proctitis, stenosis & cystitis respectively following EBRT alone.

6 Discussion

The combination of external beam radiotherapy (EBRT) with brachytherapy boost has become a common treatment approach for cervical cancer. And

combining it with chemotherapy has become standard treatment modality for locally advanced cervical cancer in many institutes.¹⁸

However in developing countries, where majority of patients present with locally advanced diseases treatment of cancer is still a major challenge. Access to anti-cancer treatment is very limited in almost all African countries. Barton et al found that radiation machine supply in Africa is inadequate to meet demand, as machine supply is sufficient to meet an estimated 18% of the need for radiation (155 megavoltage machines available, 842 needed in total).¹⁹

Whereas High-dose rate intracavitary brachytherapy (HDR) use has been widely used in the management of cervical cancer for many decades in Asia and Europe, the facility is new in Nigeria and currently only one HDR brachytherapy machine is available in Nigeria (none in other West African countries) where cervical cancer incidence is 32.9 per 100000.³

In Nigeria about 75% patients present with locally advanced cancer of cervix at the time of diagnosis¹⁶ often requiring chemo radiation therapy.

This retrospective study was therefore conducted to determine the outcome of cervical patients treated in our center with EBRT alone (prior to installation of HDR Brachytherapy machine) as compared with the patients treated with both EBRT and HDR Brachytherapy (after installation of HDR Brachytherapy).

The American Brachytherapy Society (ABS) issued some guidance regarding HDR regimens based on a theoretical LDR tumor equivalent dose prescribed to point A of 80 to 85 Gy for early stage disease and 85 to 90 Gy for advanced stage, 20 however most centers still use a variety of different fractionation schedules to combine HDR with EBRT for radical treatment of locally advanced cervical cancer²¹, and this is also seen in this study.

In this study, the age group with the highest frequency was 51-60years which is similar to a study done by Abdusalam et al where the age group with highest frequency was 50-69, 22. And the mean age of the patients with cervical cancer from this study is 54.65 + 10.2 years which is also in line with the study done by Uzoigwe et al where the mean age of the patient was 55 year 23.

Majority of the patients (more than 64%) presented at our center more than 6months after noticing the symptoms.

The outcome of treatment is an important aspect to be considered in the choice of treatment modality. And this study demonstrates that combined radiotherapy (HDR and EBRT) provides an improved treatment outcome, as better clinical remission was

observed. Local recurrence was observed in only 10% of EBRT/HDR group as compared with 17 % with EBRT group. Disease free survival was seen in 84.3%as of patients that had EBRT/HDR treatment compared to 68.4% seen in patients that had EBRT only), which is close to actuarial disease-free survival rate of 70% at 2 years reported by Forrest, Jennifer Louise.²⁴

However 48.6.5% experienced toxicity (early and late) with EBRT/HDR group compare with 23.9% of those that had only EBRT.

Though there is no statistical significance between the two groups, the treatment results and toxicity profiles can be compared with other data where a combination chemotherapy and EBRT/HDR was used. In a study done by Jennifer Louise Forrest et al²⁴ on patient outcome study of concurrent chemoradiation, external beam radiotherapy, and high dose rate brachytherapy in locally advanced carcinoma of the cervix, he observed recurrence at follow-up time (about 18 months) to be in the range of 20-24% and Akiva P. Novetsky et al²⁵ in their study on efficacy and toxicity of concomitant Cisplatin with external beam pelvic radiotherapy and two high-dose-rate brachytherapy insertions for the treatment of locally advanced cervical cancer observed that Grade 3/4 GI symptoms were the most common acute side effects (47%). Grade 3/4 late toxicities occurred in five (6%) patients.

The limitations of this study include:

- lack of standard fractionation regimen used for both groups,
- No proper scoring for the adverse effects.
- Also it was not certain if all patients completed treatment within the 56days as recommendation by ABS.

The follow-up period for this study was limited to 2years because after 2years over 60% of patients in our setting default from regular follow up appointments, visiting only when they deemed fit. This makes survival estimations difficult.

7 Conclusion

This retrospective study of patients with locally advanced cervical cancer treated in our center with EBRT alone (prior to installation of HDR Brachytherapy) and those patients treated with both EBRT and HDR (after the installation of HDR Brachytherapy) has demonstrated that there is a better treatment outcomes in term of local disease control, persistent disease, and distance metastasis among the patients treated with EBRT/HDR over those patients treated with EBRT only. Although the number of patients who reported adverse side effect is more among the group treated with EBRT/HDR compared with the group treated with EBRT only, those adverse

effects recorded where successfully treated conservatively. However further study need to be done with larger study group and longer follow up period.

It is recommended that more “high dose rate brachytherapy” facilities be established in the country as this will lead to an improved outcome in the treatment of cancer of cervix.

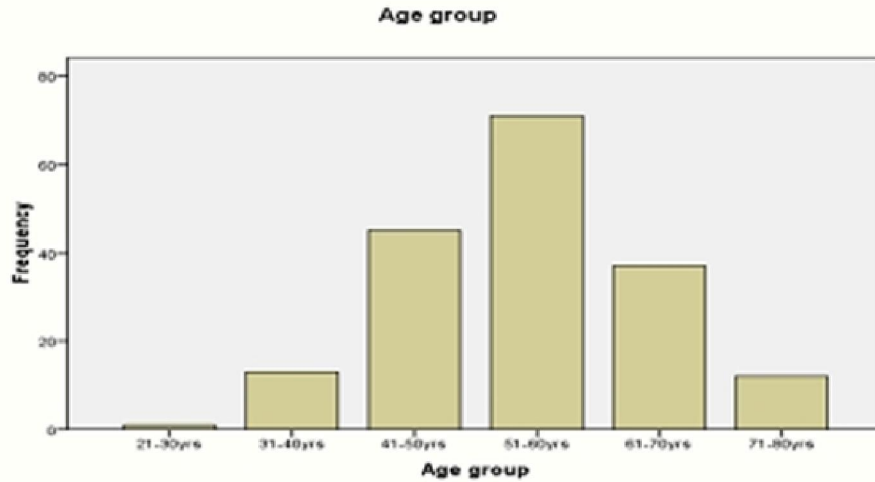


Figure 1: Age distribution

Table 1: The Stages of disease for each study group

Stage of Disease	"Group 1" xRT	"Group 2" xRT+ HDR	Total	p-value
IIIB	46(42.2%)	33(47.1%)	79(44.1%)	0.637*
IIIA	26(23.9%)	14(20.0%)	40(22.3%)	
IIIB	35(32.1%)	23(32.9%)	58(32.4%)	
IIVA	2(1.8%)	0(0.0%)	2(1.1%)	
Total	109(100.0%)	70(100.0%)	179(100.0%)	

*Fisher’s exact test

Table 2: The histological differentiation of patients in each group

Histology Differentiation	"Group 1" xRT	"Group 2" xRT+ HDR	Total
Well	32(29.4%)	33(47.1%)	64(36.3%)
Poor	42(38.5%)	33(47.1%)	75(41.9%)
Moderate	35(32.1%)	4(5.7%)	39(21.8%)
Total	109(100.0%)	70(100.0%)	179(100.0%)

Table 3: The treatment outcome of the patients in the two groups

	Local Relapse	Persistent disease	Distance Metastasis	Died of Disease progression	Disease free survival
EBRT "Group1"	19(17.4%)	8(7.3%)	4(3.7%)	3(2.8%)	75(68.8%)
EBRT/HDR "Group2"	7(10.0%)	3(4.3%)	1(1.4%)	0(0.0%)	59(84.3%)
Total	26(14.5%)	11(6.1%)	5(2.5%)	3(1.7%)	134(74.9%)
p-value		0.781	0.650	0.282	

Table 4: The adverse effects experienced by the patients in the two groups

	Desquamation	Cystitis	Proctitis	Stenosis	Sub cut. fibrosi s	Enteritis	perine al ulcer	Nil	others	Total
"Group 1" EBRT	9(8.3%)	3(2.8%)	7(6.4%)	3(2.8%)	1(0.9%)	1(0.9%)	1(0.9%)	83 (76.1%)	1(0.9%)	109 (100.0%)
"Group 2" EBRT+ HDR	1(1.4%)	3(4.3%)	16(22.9%)	13(18.6%)	1(1.4%)	0(0%)	0(0%)	36 (51.4%)	0(0%)	70 (100%)
Total	10(5.6%)	6(3.4%)	23(12.8%)	16(8.9%)	2(1.1%)	1(0.6%)	1(0.6%)	119 (66.5%)	1(0.6%)	179 (100%)
P- value	0.091	0.680	0.001	0.000				0.001		

Ethical Considerations

Ethical clearance to conduct the study was obtained from the Joint Ethical Review Committee of the University of Ibadan/University College Hospital, Ibadan, Nigeria.

The study was conducted accordingly to good clinical practice.

References

- Jamison DT, Feachem RG, Makgoba MW, et al. Disease and Mortality in Sub-Saharan Africa. 2nd edition; 2006.
- Elima Jedy-Agba et al; Cancer incidence in Nigeria: A report from population-based cancer registries. *Cancer Epidemiology*; 36 (2012) e271-e278.
- Globacom 2008
- Perez and Brandys, Principles and Practice of Radiation Oncology; 5 th Edition; 2008; pg 1541
- Kumar, Vinay; Abbas, Abul K.; Fausto, Nelson; & Mitchell, Richard N.. Robbins Basic Pathology (8th ed.) Ed.). Saunders Elsevier. (2007) pp. 718-721. ISBN 978-1-4160- 2973-1.
- Barron BA, Richart RM. Statistical Model of the Natural History of Cervical Carcinoma: II Estimates of the Transition Time from Dysplasia to Carcinoma in Situ. *J Natl Cancer Inst* 1970;45:1025:1030.
- NCI Issues Clinical Announcement on Cervical Cancer: Chemotherapy Plus Radiation Improves Survival. <http://www.nih.gov/news/pr/feb99/nci-22.htm> (11 April 2012, date last accessed).
- Gillian M. Thomas, M.D. Improved Treatment for Cervical Cancer — Concurrent Chemotherapy and Radiotherapy; *Engl J Med* 1999; 340:1198-1200
- J.O Thomas, R. Herrero, A.A. Omigbodun et al. prevalence of papilloma virus infection in women in Ibadan, Nigeria: a population based study. *Br. J. Cancer.* 2004 Feb. 9;90(3): 638-645.
- Saibishkumar E.P et al, Evaluation of the late toxicities of patients with carcinoma of the cervix treated with radical radiotherapy; An audit from india. *Clin. Oncol (R Coll Radiol)* 2006;18:30-7.
- Thoms WW Jr, Eifel PJ, Smith TL, et al. Bulky endocervical carcinoma: a 23-year experience. *Int J Radiat Oncol Biol Phys* 1992; 23:491-9.
- Perez CA, Grigsby PW, Nene SM, et al. Effect of tumor size on the prognosis of carcinoma of the uterine cervix treated with irradiation alone. *Cancer* 1992;69:2796-806.

13. Cancer" Cancers of the Female Reproductive System: Merck Manual Home Edition.
14. Kaplan El, Meier P: Nonparametric estimation from incomplete observations. *J Am Stat. Assoc* 1958, 53:457-481
15. Umezulike A C, Tabansi S N, Ewunonu H A, et al; Cancer of the Cervix in the Federal Capital Territory of Nigeria. *Niger J Clin Pract.* 2007 Jun;10(2):143-6.
16. Campbell O B, Akinlade IB, Arowojolu A, et al; Comparative Evaluation of Hypofractionation Radiotherapy and Conventional Fractionation Radiotherapy in the Management of the Uterine Cervix in Ibadan Nigeria. *Africa J Med Sciences.* 2000; 253-5
17. Atara Ntekim, Adeniyi Adenipekun, Bidemi Akinlade et al; High Dose Rate Brachytherapy in the Treatment of Cervical Cancer: Preliminary Experience with Cobalt 60 Radionuclide Source—A Prospective Study; *Clin Med Insights Oncol.* 2010; 4: 89-94.
18. Reducing Uncertainties About the Effects of Chemoradiotherapy for Cervical Cancer: A Systematic Review and Meta-Analysis of Individual Patient Data From 18 Randomized Trials. *J Clin Oncol.* 2008;26:5802-5812.
19. Barton MB, Frommer M, Shafiq J: Role of radiotherapy in cancer control in low-income and middle-income countries. *Lancet Oncol* 2006, 7(7):584-595
20. Nag S, Erickson B, Thomadsen B, et al. The American Brachytherapy Society recommendations for high dose-rate brachytherapy for carcinoma of the cervix. *Int J Radiat Oncol Biol Phys.* 2000;48:201Y211,
21. Peterit DG, Sarkaria JN, Potter DM, et al. High dose-rate versus low dose-rate brachytherapy in the treatment of cervical cancer: analysis of tumour recurrence the University of Wisconsin experience. *Int J Radiat Oncol Biol Phys.* 1999;45:1267Y1274.
22. Abdus-Salam, A. Ogunnorin, O. Abdus-Salam, R. HIV seroprevalence in patients with carcinoma of the cervix in Ibadan, Nigeria, *Ghana Med J.* 2008 December;42(4)141-143
23. Uzoigwe S.A, Seleye-Fubara D; cancer of the uterine Cervix in Port Harcourt, Rivers State—a 13 year Clinicopathologic Review. *Niger J Med* 2004 Apri-Jun; 13(2): 110-3
24. Forrest, Jennifer Louise; Ackerman, Ida et al Patient Outcome Study of Concurrent Chemoradiation, External Beam Radiotherapy, and High-Dose Rate Brachytherapy in Locally Advanced Carcinoma of the Cervix; *International Journal of Gynecological Cancer Issue: Volume 20(6), August 2010, pp 1074-1078*
25. Novetsky AP, Einstein MH, Goldberg GL, Hailpern SM, Landau E, Fields AL, Mutyala S, Kalnicki S, Garg M: Efficacy and toxicity of concomitant cisplatin with external beam pelvic radiotherapy and two high-dose-rate brachytherapy insertions for the treatment of locally advanced cervical cancer. *Gynecol Oncol.* 2007 Jun; 105 (3):635-40

6/25/2018