

## Oncological safety of conservative axillary lymph node dissection in pathologically positive axilla: randomized controlled study

Mohamed Abdelhamid, Wael Al-shelfa, Salah Abd Elaal, Mansour M Morsy, Osama abd Elaziz, Hassan Ashour, Osama abd Elaziz, Ahmed R Elsayed

General & Lap Surgery Department, Zagazig University, Zagazig, Sharkia, Egypt

Emails: [dr\\_moh2003@yahoo.com](mailto:dr_moh2003@yahoo.com), [dr\\_keko\\_2007@yahoo.com](mailto:dr_keko_2007@yahoo.com), [osamaeltih1975@gmail.com](mailto:osamaeltih1975@gmail.com),

[Waelshel74@yahoo.com](mailto:Waelshel74@yahoo.com), [Drhassanashour@hotmail.com](mailto:Drhassanashour@hotmail.com), [Nooredo@yahoo.com](mailto:Nooredo@yahoo.com), [mansourmorsy@gmail.com](mailto:mansourmorsy@gmail.com),

[Dr\\_ahmedraafat@yahoo.com](mailto:Dr_ahmedraafat@yahoo.com)

**Abstract: Background:** Axillary lymph node dissection (ALND) is associated with many complications as lymphedema. The oncological safety of preserving the upper limb lymphatic is still unclear. The aim of the current study is to determine the oncological safety of sparing upper limb lymphatic in clinically negative and Sentinel lymph node biopsy (SLNB) positive axilla. **Patients and Methods:** Ninety-eight early breast cancer patients with clinically negative axilla were conducted in this study during the period between March 2013 and October 2014. Positive SLNB patients were randomized into two groups, group I for standard ALND and group II for conservative ALND. Conservative ALND group patients underwent Axillary reverse mapping (ARM) for identification of upper limb lymphatic and sparing these lymph nodes during ALND. All patients were followed up till April 2017 with follow up period ranged from 30 – 49 month (mean follow up period was 39 month). **Results:** lymphedema occurred in 10(25%) patients in group I, while no lymphedema in group II. No local recurrence occurred in both groups during the period of follow up. paresthesia, pain and loss of shoulder mobility were more in group I. **Conclusion:** Conservative ALND is oncologically safe as standard ALND in pathologically positive axilla and less in complications regarding lymphedema, parasthesia, pain and loss of shoulder mobility. [Mohamed Abdelhamid, Wael Al-shelfa, Salah Abd Elaal, Mansour M Morsy, Osama abd Elaziz, Hassan Ashour, Osama abd Elaziz, Ahmed R Elsayed. **Oncological safety of conservative axillary lymph node dissection in pathologically positive axilla: randomized controlled study** . *Cancer Biology* 2017;7(3):90-94]. ISSN: 2150-1041 (print); ISSN: 2150-105X (online). <http://www.cancerbio.net>. 13. doi:[10.7537/marscbj070317.13](https://doi.org/10.7537/marscbj070317.13).

**Key words:** Breast cancer, Axillary dissection, Axillary reverse mapping

### Introduction:

Axillary lymph node dissection (ALND) is associated with many complications as lymphedema, seroma, infection, parasthesia and pain but, lymphedema is considered the most dangerous complication following ALND [1, 2]. Lymphedema occur in about 10-30 % of patient with ALND [3-5]. The main target of our study was how to decrease the standard ALND associated morbidity.

Clinically involved axilla needs extensive dissection for oncological safety; we focused on clinically negative axilla with micro metastasis and determine the clinical relevance and oncological safety of sparing upper limb lymphatic.

Axillary reverse mapping (ARM) is a newly developed technique firstly developed in 2007 and helps in decrease the upper limb lymphedema by preserving the upper limb lymphatic during ALND [6,7].

The oncological safety of preserving the upper limb lymphatic is still unclear.

Sentinel lymph node biopsy (SLNB) is the standard technique in clinically negative axilla to determine axillary involvement [8-11].

The aim of the current study is to determine the oncological safety of sparing upper limb lymphatic in clinically negative and SLNB positive axilla.

### Patients and methods:

Ninety-eight early breast cancer patients with clinically negative axilla were conducted in this study during the period between March 2013 and October 2014 at surgical oncology unit, Zagazig university hospital, Zagazig, Egypt. This research was approved by local ethical committee of our university (Zagazig University, Faculty of Medicine, IRB unit) and consents were taken from our patients before the procedure.

All patients were diagnosed as clinically negative axilla by clinical examination and ultrasonography. Clinically positive axilla and patients with history of axillary surgery were excluded from the study.

SLNB were done for all patients at the beginning of the procedure, negative SLNB patients were excluded from the study, while positive SLNB patients were randomized into two groups, group I for standard ALND and group II for conservative ALND.

Conservative ALND group patients underwent ARM for identification of upper limb lymphatic and

sparing these lymph nodes during ALND. Consort flow diagram shown in [figure 1](#).

### **SLNB**

In our study SLNB were done by using patent methylene blue dye as it available and sheep

The dye were injected peri-tumoral 15 minutes before the procedure and identification of the SLN by its bluish discoloration

### **ARM**

After identification of SLN positive patients; 3 ml of patent blue dye was injected into subdermal and subcutaneous tissues in the area of medial intramuscular groove of the upper limb. Gentle massage was applied to allow migration of the dye to axilla. ARM lymph nodes were localized and spared in conservative group.

### **ALND**

Level II axillary dissection was done for all patients with preservation of ARM lymph nodes in conservative ALND group.

### **Lymphedema**

Upper limb lymphedema measured every 3 months during the period of follow up. Lymphedema measured by measuring the upper limb circumference at wrist, mid forearm and mid arm and compared with the normal side [12].

### **Parasthesia and numbness.**

Parasthesia and numbness measured by standardized questioner developed for patients with breast cancer [13].

### **Pain**

Measured by visual analogue scale.

### **Affection of shoulder mobility**

Shoulder mobility assessed by comparing both upper limbs mobility, it considered affected when the patient cannot abduct the arm more than 90 degree.

All patients were followed up till April 2017 with follow up period ranged from 30 – 49 month (mean follow up period was 39 month).

### **Results**

Ninety-eight early breast cancer patients were initially included in this study, 16 patients were negative SLNB, while 82 were positive SLNB.

Positive nodal patients were randomized classified into two groups, 41 in each one. One patient was lost during follow up period in group I, while 3 were lost in group II.

The mean age in group I was 49.8 and 49.2 in groups II. As regarding tumor stage 12 patients in group I were stage I and 28 patients were stage II while in group II, 11 patients were stage I and 27 patients were stage II.

IDC were the commonest histological type in both groups (25 patients in each group). most of tumors were located in upper outer quadrant 22 patients in group I and 16 in group II. the mean number of excised lymph nodes in group I were 17.7 while in group II were 16.45.

Most of our patients underwent BCS, 2 in group I and 25 in group II. while MRM performed in 18 patients in group I and 13 patients in group II.

Demographic, clinical and pathological features of patients in the study were summarized in [table 1](#).

Table 1: Demographic, clinical and pathological features of patients in the study.

	Group I standard ALND (n=40)	Group II conservative ALND (n=38)	X <sup>2</sup>	P- value
Age/year (mean)	49.8 ± 8.81	49.2±9.97	0.277	0.391
Tumor stage				
• T1	12	11	0.135	0.934
• T2	24	24		
• T3	4	3		
Stage				
• I	12	11	0.01	0.918
• II	28	27		
Histology				
• DCI	25	25	0.091	0.762
• Other	15	13		
Tumor site				
UOQ	22	16	2.763	0.598
UIQ	5	4		
LOQ	5	9		
LIQ	5	4		
RETRO-AREOLAR	3	5		
No of excised LN	17.7±1.9	16.45±1.3	T=3.393	0.0005
ER +Ve	26	23	0.167	0.682
PR +VE	21	20	0.0001	0.99
HER2 +VE	17	16	0.0012	0.971
Type of surgery				
• BCS	22	25		
• MRM	18	13		

Lymphedema occurred in 10 patients in group I, while no lymphedema were recorded in group II.

No local recurrence in both groups during the period of follow up.

Parasthesia and numbness, Pain and affection of shoulder mobility were less common on group II. Post-operative complications were included in [table 2](#).

Table 2: post-operative complications

	Group I standard ALND (n=40)	Group II conservative ALND (n=38)	X <sup>2</sup>	P- value
Lymphedema	10	0	8.049	0.004
Local Recurrence	0	0		

### CONSORT Flow Diagram

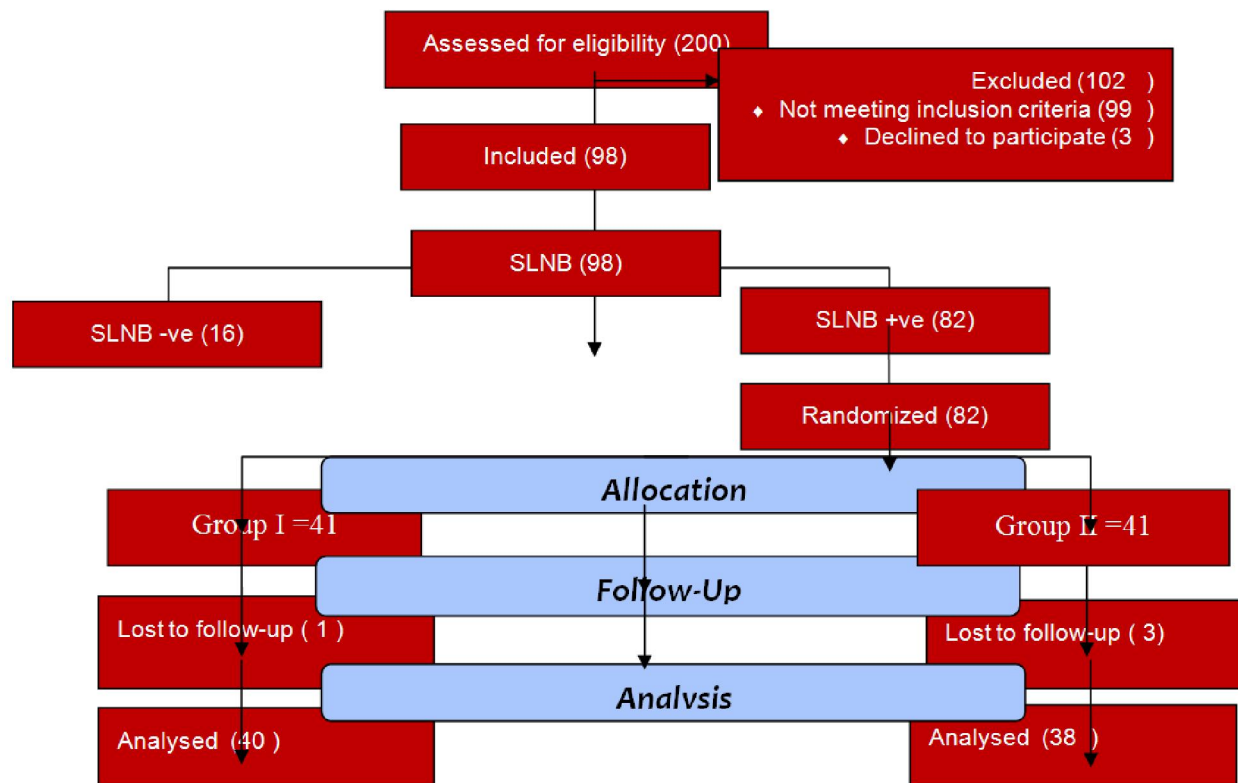


Figure1: consort flow diagram.

### Discussion:

Management of the axilla in breast cancer patients has been a subject of many debates [14].

Lymphedema is a major post axillary dissection complication; the main target of our study was how to decrease the standard ALND associated morbidity.

About 50% of SLN positive axilla have no further positive lymph nodes [15]. The ARM procedure was introduced to decrease the incidence of post axillary dissection lymphedema. This procedure based on separate identification of both breast and arm lymphatic.

In the current study we assessed the oncological safety of CALND in clinically negative axilla and its ability to decrease axillary surgery associated lymphedema.

In our study axillary surgery associated lymphedema was significantly decreased in the conservative group this is in agreement with Boneti et al. [16]. While, Tauscho et al [17].. and Gennaro et al. [18]. Showed no significant reduction in lymphedema but this result mostly due to small number of patients and short follow up period, as mostly lymphedema appears within 3 years after axillary dissection.

As regarding oncological safety no local recurrence were occurred in our patients and this is in agreement with Ikeda et al. [19]. Who conclude that clinically negative axilla and positive SLN had a significantly lower incidence of positive ARM.

As regarding parasthesia and numbness, there is no significant difference as this related to intercosto-brachial nerve sparing.

As regarding pain and shoulder affection, there is no significant difference between the two procedures.

### Conclusions:

Conservative ALND is oncologically safe as standard ALND in pathologically positive axilla and less in complications regarding lymphedema, parasthesia, pain and loss of shoulder mobility.

### Conflict of Interest

The authors declare that they have no conflict of interest.

### Author Details:

1. Mohamed Abdelhamid, MD, lecturer of general surgery, General & Lap Surgery Department, Zagazig University, Zagazig, Egypt, E mail: [dr\\_moh2003@yahoo.com](mailto:dr_moh2003@yahoo.com).
2. Mohammed Alkilany, MD, lecturer of general surgery, General & Lap Surgery Department, Zagazig University, Zagazig, Egypt, E mail: [dr\\_keko\\_2007@yahoo.com](mailto:dr_keko_2007@yahoo.com).
3. Osama abd Elaziz, MD, lecturer of general surgery, General & Lap Surgery Department, Zagazig University, Zagazig, Egypt, E mail: [osamaeltih1975@gmail.com](mailto:osamaeltih1975@gmail.com)
4. Wael Al-shelfa, MD, lecturer of general surgery, General & Lap Surgery Department, Zagazig University, Zagazig, Egypt, E mail: [Waelshel74@yahoo.com](mailto:Waelshel74@yahoo.com)
5. Hassan Ashour, MD, lecturer of general surgery, General & Lap Surgery Department, Zagazig University, Zagazig, Egypt, E mail: [Drhassanashour@hotmail.com](mailto:Drhassanashour@hotmail.com)
6. Salah Abd Elaal, MD, lecturer of general surgery, General & Lap Surgery Department, Zagazig University, Zagazig, Egypt, E mail: [Nooredo@yahoo.com](mailto:Nooredo@yahoo.com)
7. Mansour M Morsy, MD, lecturer of general surgery, General & Lap Surgery Department, Zagazig University, Zagazig, Egypt, E mail: [mansourmorsy@gmail.com](mailto:mansourmorsy@gmail.com)
8. Ahmed R Elsayed, MD, lecturer of general surgery, General & Lap Surgery Department, Zagazig University, Zagazig, Egypt, E mail: [Dr\\_ahmedraafat@yahoo.com](mailto:Dr_ahmedraafat@yahoo.com)

### Corresponding Author Details

Mohamed Ibrahim Abdelhamid

Postal address: General and Laparoscopic Surgery Department, Zagazig University.

Zagazig

sharkia

Egypt

Tel: +20552336364 - 002 01226205757 - 0021117861414

Contact E mail: [dr\\_moh2003@yahoo.com](mailto:dr_moh2003@yahoo.com)

Fax: +20552370600

### References:

1. Lucci A, McCall L, Beitsch P (2007). Surgical complications associated with sentinel lymph node dissection (SLND) plus axillary lymph node dissection compared with SLND alone in the American College of Surgeons Oncology Group Trial Z0011. *J Clin Oncol*;25: 3657–63.
2. Langer I, Guller U, Berclaz G (2007). Morbidity of sentinel lymph node biopsy (SLN) alone versus SLN and completion axillary lymph node dissection after breast cancer surgery: a prospective Swiss multicenter study of 659 patients. *Ann Surg*; 245(3):452–61.
3. McLaughlin S, Wright M, Morris K (2008). Prevalence of lymphedema in women with breast cancer 5 years after sentinel lymph node biopsy or axillary dissection: objective measurements. *J Clin Oncol*;26(32):5213–9.
4. Bani H, Fasching A, Lux M (2007). Lymphedema in breast cancer survivors: assessment and information provision in a specialized breast unit. *Patient Educ Couns*;66:311–8.
5. Michael S, Charikleia S, Konstantinos K (2011). Lymphedema and breast cancer: a review of the literature. *Breast Cancer*;18:174–80.
6. Thompson M, Korourian S, Henry-Tillman R, et al. (2007). Axillary reverse mapping (ARM): a new concept to identify and enhance lymphatic preservation. *Ann Surg Oncol*;14(6):1890–5.
7. Nos C, Lesieur B, Clough K (2007). Blue dye injection in the arm in order to conserve the lymphatic drainage of the arm in breast cancer patients requiring an axillary dissection. *Ann Surg Oncol*;14(9):2490–6.
8. Giuliano A, Kirgan D, Gutenther J (1994). Lymphatic mapping and sentinel lymphadenectomy for breast cancer. *Ann Surg*;220:391–401.
9. Veronesi U, Paganelli G, Galimberti V, et al. (1997). Sentinel-node biopsy to avoid Axillary dissection in breast cancer with clinically negative lymph-nodes. *Lancet*;349:1864–7.

10. Krag D, Weaver D, Ashikaga T, et al. (1998). The sentinel node in breast cancer: a multicenter validation study. *N Engl J Med.* 1998;339:941–6.
11. Cox C, Pendas S, Cox J, et al. (1998). Guidelines for sentinel node biopsy and lymphatic mapping of patients with breast cancer. *Ann Surg*;227:645–53.
12. Klompenhouwer E, Gobardhan P, Beek M (2013). The clinical relevance of axillary reverse mapping (ARM): study protocol for a randomized controlled trial. *Trials* 2013, 14:111.
13. Ververs J, Roumen R, Vingerhoets A, et al (2001). Risk, severity and predictors of physical and psychological morbidity after axillary lymph node dissection for breast cancer. *Eur J Cancer*, 37(8):991–999.
14. Kim T, Giuliano A, Lyman G (2006). Lymphatic mapping and sentinel lymph node biopsy in early-stage breast carcinoma: a meta analysis. *Cancer*, 106(1):4–16.
15. Straver M, Meijnen P, van Tienhoven G, et al. (2010). Role of axillary clearance after a tumor-positive sentinel node in the administration of adjuvant therapy in early breast cancer. *J Clin Oncol*, 28(5):731–737.
16. Boneti C, Korourian S, Diaz Z, et al (2009). Scientific impact award: axillary reverse mapping (ARM) to identify and protect lymphatics draining the arm during axillary lymphadenectomy. *Am J Surg* 198(4):482–487.
17. Tausch C, Baeye A, Dietrich D, et al. (2013) Can axillary reverse mapping avoid lymphedema in node positive breast cancer patients? *Eur J Surg Oncol.* 39(8):880–6.
18. Gennaro M, Maccauro M, Sigari C, et al. (2013). Selective axillary dissection after axillary reverse mapping to prevent breast-cancer-related lymphoedema. *Eur J Surg Oncol*;39(12):1341–5.
19. Ikeda K, Ogawa Y, Komats H (2012). Evaluation of the metastatic status of lymph nodes identified using axillary reverse mapping in breast cancer patients. *World Journal of Surgical Oncology*, 10:233.

9/25/2017