

**IL-33/ST2 Axis and Prohibitin in Breast Cancer: Clinicopathological and Prognostic Significance**Amina El-Sayed<sup>1</sup>, Amany A. Ghazy<sup>2</sup>, Rabie R. Abdelwahed<sup>3</sup>, Eman M. Saied<sup>4</sup><sup>1</sup> Department of Immunology and Allergy, Medical Research Institute, Alexandria University.<sup>2</sup> Department of Microbiology and Immunology, Faculty of Medicine, Kafrelsheikh University.<sup>3</sup> Department of Surgery, Medical Research Institute, Alexandria University.<sup>4</sup> Department of Pathology, Faculty of Medicine, Kafrelsheikh University.[dremansaied@gmail.com](mailto:dremansaied@gmail.com)

**Abstract: Background:** Breast cancer (BC) is an important health challenge that women face and affects their safety and productivity. IL-33 participates in many diseases with dual, pro-inflammatory or protective roles depending on the cellular and cytokine context. However, the role of IL-33/ST2 axis in carcinogenesis, tumour progression and prognosis is still unclear. Prohibitin (PHB) is a multifunctional protein located in different intracellular sites. It shows overexpression in many cancers suggesting its role in tumourigenesis. **Aim:** The present work was designed to study the clinicopathological and prognostic significance of IL-33/ST2 axis and prohibitin in breast cancer. **Subjects & Methods:** The current study was conducted on 45 patients with breast lesions (benign lesions, early and advanced breast cancer) and 15 healthy volunteers. IL-33 and ST2 serum levels were measured by ELISA. Expressions of IL-33 and prohibitin in breast tissue were assessed by immunohistochemistry. **Results:** Serum levels of IL-33 and immunohistochemical expression of prohibitin were significantly increased in groups with breast lesions compared to the control group ( $p < 0.05$ ). Immunohistochemical expression of IL-33 showed significant differences between malignant tumours and control group ( $p < 0.05$ ), while benign lesions showed higher expression than the control group but the difference was statistically insignificant ( $p > 0.05$ ). In addition, Serum levels of IL-33 as well as immunohistochemical expressions of IL-33 and prohibitin were significantly higher in breast cancer cases compared to those with benign breast lesions ( $p < 0.05$ ), moreover, they showed significant increase with progression of cancer from early "stage I and II" to advanced breast cancer "stage III" ( $p < 0.05$ ). Serum levels of sST2 were significantly higher in breast lesions compared to the control group ( $p < 0.001$ ); however, they were lower in malignant cases than these with benign lesions, but the differences were statistically insignificant ( $p = 0.158$ ). There was a significant positive correlation between the serum level of IL-33 and its immunohistochemical expression in all studied groups ( $p < 0.05$ ), and a significant positive correlation between IL-33 and prohibitin immunohistochemical expression in malignant breast tumours ( $p < 0.05$ ). **Conclusion:** IL-33/ST2 and prohibitin have vital roles in breast cancer development. The increased expression of IL-33 and prohibitin with increasing tumour grade and stage indicates that they may be useful prognostic markers for breast cancer.

[Amina El-Sayed, Amany A. Ghazy, Rabie R. Abdelwahed, Eman M. Saied. **IL-33/ST2 Axis and Prohibitin in Breast Cancer: Clinicopathological and Prognostic Significance.** *Cancer Biology* 2016;6(4):48-56]. ISSN: 2150-1041 (print); ISSN: 2150-105X (online). <http://www.cancerbio.net>. 7. doi: [10.7537/marscbj060416.07](https://doi.org/10.7537/marscbj060416.07).

**Key words:** Breast cancer, IL-33/ST2, Prohibitin, Prognosis, IHC

**1. Background And Aim**

Breast cancer (BC) is the most frequently diagnosed cancer in females, and the second leading cause of cancer death (Abdulkareem, 2013). According to global cancer statistics, BC accounts for 23% of all new cancer cases, worldwide (Kruk, 2014). In Egypt, data from the National Cancer Institute (Cairo) showed that breast cancer is the commonest cancer among Egyptian women, representing 37% of all female cancers. It was responsible for 15% of all cancer deaths, as more than 60-80% of patients are presented at advanced stage (Ismail et al., 2013). Women are not only diagnosed with breast cancer in the later stages of the disease but also a higher proportion of younger females in their thirties and forties are clinically presenting with breast cancer (Miller, 2010).

Although the roles of BRCA1, BRCA2 and HER-2/neu antigens is well-established in breast cancer, recent evidence has shed more light on triple negative breast cancer which has a worse prognosis (Kruk, 2014). Thus, early diagnosis and effective therapies for breast cancer are imperative. However, a limited number of biomarkers for BC have been validated for clinical application (Lu et al., 2014).

Interleukin-33 (IL-33) is a novel member of the IL-1 family of cytokines (Schmitz et al., 2005). It is expressed by various non-hematopoietic cells as fibroblasts, bronchial and epithelial cells, macrophages and dendritic cells (Bergis et al., 2013; Liu et al., 2014). It is a multifunctional cytokine in immune regulation (Chen et al., 2014).

The signaling of IL-33 is mediated by its receptor ST2, which exists in 2 forms, a soluble form

(sST2) and as a transmembrane receptor (ST2L). Binding of IL-33 to ST2L leads to activation of nuclear factor  $\kappa$ B and mitogen-activated protein kinase (MAPK) signaling pathways (Bergis et al., 2013). sST2 is suggested to act as decoy receptor for IL-33 leading to attenuation of its biologic activity (Jovanovic et al., 2012; Milovanovic et al., 2012).

ST2L is expressed by T cells (T-helper 2 "Th2", but not Th1 cells), natural killer "NK", NKT cells, mast cells, monocytes, dendritic cells and granulocytes. IL-33 polarizes naïve T-cells to produce IL-4, IL-5 and IL-13 (Th2-associated cytokines), potently induces pro-inflammatory cytokines and chemokines by mast cells and eosinophils, and amplifies polarization of alternatively activated macrophages. Although ST2 and IL-33 act primarily through a Th2-pathway, IL-33/ST2 axis can also promote Th1-type responses depending on the local conditions, for example, the presence or absence of IL-12 (Jovanovic et al., 2012).

IL-33/ST2 axis has been proved to play important roles in Th2-driven chronic inflammatory conditions such as rheumatoid arthritis, bronchial asthma, allergic rhinitis, and inflammatory bowel disease (Jovanovic et al., 2012). It is involved in many diseases with dual, pro-inflammatory or protective roles depending on the cellular and cytokine background (Liew et al., 2010). However, the role of IL-33/ST2 axis in carcinogenesis, tumour progression and prognosis is still not fully elucidated. It is noticed that IL-33 levels were elevated in the serum of patients with different types of cancer, including gastric, lung and hepatocellular cancers (Chen et al., 2014).

Prohibitin (PHB) is a multifunctional protein located in different intracellular sites (Franzoni et al., 2009). In addition to its role in maintenance of mitochondrial function and protection against senescence (Najm et al., 2013), overexpression of prohibitin has been described in many cancers suggesting its role in tumourigenesis. It has been described to be involved in regulation of proliferation, apoptosis and gene transcription (Webster et al., 2013), with either a permissive action on tumour growth or an oncosuppressor role, depending on the cellular context (Franzoni et al., 2009). It was also suggested to be implicated in cancer cell invasion, metastasis and reduced survival (Wood et al., 2009).

The present study focuses on the measurement of serum levels of IL-33 and its soluble receptor sST2 as well as studying the immunohistochemical expression of IL-33 and prohibitin in normal, benign, and malignant breast tissue to investigate their clinicopathological and prognostic significance in breast cancer.

## 2. Subjects And Methods

### 2.1. Subjects

This study was conducted on 45 patients with breast lesions, admitted to Department of Clinical and Experimental Surgery, Medical Research Institute, Alexandria University and 15 healthy normal females as a control group. Subjects were divided into 4 groups; **group 1** included 15 patients with benign breast lesions, **group 2** included 15 patients with early breast cancer "stage I and II", **group 3** included 15 patients with advanced breast cancer "stage III" and **group 4** included 15 healthy normal subjects as a control group.

Informed written consents were gathered from all subjects prior to their inclusion in the study protocol, according to ethical guidelines of Medical Research Institute, Alexandria University (Informed Written Consent for Patient Participation in a Clinical Research, 2011). The study was approved by the Ethical Committee of Medical Research Institute, Alexandria University.

### 2.2. Methods

#### 2.2.1. Measurement of IL-33 and its soluble receptor (sST2) levels

Serum levels of IL-33 and its soluble receptor (sST2) were measured using commercial human IL-33 Platinum ELISA kit (BMS2048 / BMS2048TEN, eBioscience, Germany) and human IL1RL1/ST2 ELISA kits (catalogue No. EK1116, Boster Biological Technology Co., Ltd), respectively, following the manufacturers' protocol. Levels were expressed by pg/ml.

#### 2.2.2. Histopathological examination

Tissue samples from the studied groups were immediately fixed by immersion in 10% formalin, followed by routine histological processing, paraffin embedding, and microtomy for histopathologic examination of the studied groups and grading of malignant cases.

Haematoxylin and Eosin (H&E)-stained slides from all groups were reviewed, characterized and studied. All malignant cases were diagnosed and graded using criteria of the Nottingham grading system (Elston & Ellis, 1991). The stage of the studied carcinomas was obtained from the clinical sheets of the patients.

#### 2.2.3. Immunohistochemical assessment of IL-33 and prohibitin expression in breast tissue

IL-33 and prohibitin expressions in breast tissue were evaluated using immunohistochemistry (IHC) stains. Staining was performed using the UltraVision Detection Kit (TP-015-HD, Lab Vision, USA) according to the manufacturer's protocol. After deparaffinization and heat pretreatment, sections were incubated for 10 minutes with Ultra V block to prevent nonspecific background staining, followed by

rinsing the sections with PBS. Afterwards, an overnight incubation was done in a humidity chamber with rabbit polyclonal anti-interleukin 33 (IL-33) antibody (Bioss Antibodies) at a dilution 1:300, and mouse monoclonal anti-prohibitin (E-5) antibody (clone sc-377037, Santa Cruz Biotechnology, Inc.) at a dilution 1:100, followed by washing in PBS. Sections were then covered with 4-5 drops of UltraVision biotinylated goat anti-polyvalent secondary antibody, incubated at room temperature for 10 minutes, then washed in PBS, followed by incubation with streptavidin peroxidase solution for 10 minutes at room temperature, then rinsing with phosphate buffer saline (PBS). Sections were then covered for 15 minutes by adding one drop of 3,3'-diamino-benzidine-tetra-hydrochloride (DAB) chromogen mixed with 2 ml of DAB substrate. Finally, sections were counterstained with Mayer's haematoxylin, dehydrated in alcohol and mounted in di-n-butyl-phthalate-polystyrene-xylene (DPX). As positive controls, sections from human ovarian tissue (for prohibitin), and sections from human tonsil (for IL-33) were used. Negative controls were prepared by omission of the primary antibodies.

#### 2.2.3.1 Evaluation of immunohistochemical staining

Distinct granular cytoplasmic staining for IL-33, as well as cytoplasmic and/or nuclear staining for prohibitin, were considered to indicate positive immunoreactivity.

The immunohistochemical score (IHS) was used for evaluation of prohibitin and IL-33 immunoreactivity by means of light microscopy examination using 10 high power fields (X400) in each slide, and the average IHS score was calculated by combining the quantity score (percentage of positive stained cells) with the staining intensity score. The quantity score ranges from 0 to 4, i.e. 0, no immunostaining; 1, 1-10% of cells are stained; 2, 11-50% are positive; 3, 51-80% are positive; and 4,  $\geq$ 81% of cells are positive. The staining intensity was scored as: 0 (negative), 1 (weak), 2 (moderate) and 3 (strong). Raw data were converted to IHS by multiplying the quantity score (0-4) with the staining intensity score (0-3), with a range from 0 to 12. An IHS of 9-12 was considered a strong (+3); 5-8, moderate (+2); 1-4, weak (+1); and 0, negative immunoreactivity (Gou et al., 2011).

#### 2.2.4. Statistical analysis of the data

Data were analyzed using IBM SPSS software package version 20.0. Qualitative data were described using number and percent. Comparison between different groups regarding categorical variables was tested using Chi square for Kruskal Wallis test, significance between groups was done using by Mann Whitney test. When more than 20% of the cells have

expected count  $< 5$ , correction for chi-square was conducted using Monte Carlo correction. Correlations between the studied parameters were done by Spearman coefficient. Significance was judged at the 0.05 level (Kirkpatrick & Feeney, 2013).

### 3. Results

#### 3.1. Subjects' demographic data

Age distribution among benign, early breast cancer "stage I and II", advanced breast cancer "stage III" and healthy control groups ranged between 44 and 63 years old. There weren't any statistically significant differences among the studied groups regarding age or menstrual state.

#### 3.2. Serum levels of IL-33 and sST2

The mean levels of IL-33 in serum were  $122.47 \pm 41.96$ ,  $359.23 \pm 277.1$ ,  $372.06 \pm 196.5$  and  $583.9 \pm 203.7$  pg/ml in control, benign, early breast cancer "stage I and II", and advanced breast cancer "stage III" groups, respectively. There was a statistically significant increase in IL-33 serum levels in groups with breast lesions compared to the control group ( $p < 0.001$ ). In addition, levels of IL-33 were significantly higher in malignant cases than benign lesions ( $p = 0.004$ ). Moreover, they were significantly increasing with progression from early "stage I and II" to advanced breast cancer "stage III" ( $p = 0.004$ ).

The mean levels of ST2 were  $59.08 \pm 10.11$ ,  $104.08 \pm 48.24$ ,  $86.53 \pm 29.84$  and  $92.53 \pm 23.93$  pg/ml in control, benign, early breast cancer "stage I and II", and advanced breast cancer "stage III" groups, respectively. There was a statistically significant increase in ST2 serum levels in groups with breast lesions compared to the control group ( $p < 0.001$ ). Levels of ST2 were lower in malignant cases than these with benign lesions, but the differences were statistically insignificant ( $p = 0.158$ ).

#### 3.3. Histopathologic features of studied cases

Histopathologic evaluation of H&E-stained sections revealed that the studied benign breast lesions included 9/15 (60%) cases of fibrocystic change and 6/15 (40%) fibroadenomas. Concerning the studied malignant cases, stage I&II breast carcinomas included 13/15 (86.7%) cases of infiltrating ductal carcinoma—not otherwise specified (IDC-NOS), and 2/15 (13.3%) infiltrating mucinous carcinomas. All stage III breast carcinomas (100%) were IDC-NOS. Grading of the studied breast carcinomas revealed 19/30 (63.3%) grade II tumours and 11/30 (36.7%) grade III tumours.

#### 3.4. Immunohistochemical expression of IL-33 in the studied groups

IL-33 expression was variable among the studied groups. The highest expression was detected in breast carcinomas [27/30 (90%)], compared to benign breast lesions [5/15 (33.3%)], and normal breast tissue [3/15



(20%)] with statistically significant differences ( $p < 0.001$ ). There was a statistically significant increase in IL-33 expression with increased tumour stage, as group 3 “stage III” breast carcinomas showed significantly higher IL-33 expression compared to group 2 “stage I and II” ( $p = 0.001$ ) indicating up-regulation of its expression with cancer progression. All the studied grade III carcinomas (100%) showed IL-33 expression, while 15/19 (78.9%) of grade II

tumours were IL-33 positive. IL-33 expression was slightly higher in group 1 “benign group” compared to group 4 “control group”; however, the differences were statistically insignificant ( $p < 0.05$ ). Within group 1, no differences were found regarding IL-33 expression between fibrocystic change and fibroadenomas. The immunohistochemical expression of IL-33 among the studied groups is shown in figure (1) and table (1).

**Table (1): Immunohistochemical expression of IL-33 in the in the studied groups.**

IL-33 IHS	Group 1 (n= 15)		Group 2 (n= 15)		Group 3 (n= 15)		Group 4 (Control) (n= 15)		MC	p
	No	%	No	%	No	%	No	%		
Negative	10	66.7	3	20.0	0	0.0	12	80.0	50.462*	<0.001*
+ 1	5	33.3	6	40.0	0	0.0	3	20.0		
+ 2	0	0.0	4	26.7	5	33.3	0	0.0		
+ 3	0	0.0	2	13.3	10	66.7	0	0.0		
<b>p<sub>Control</sub></b>	<sup>FE</sup> p=0.682		<sup>MC</sup> p=0.004*		<sup>MC</sup> p<0.001*					
<b>Sig. bet. grps.</b>	<sup>MC</sup> p <sub>1</sub> =0.009*		<sup>MC</sup> p <sub>2</sub> <0.001*		<sup>MC</sup> p <sub>3</sub> =0.001*					

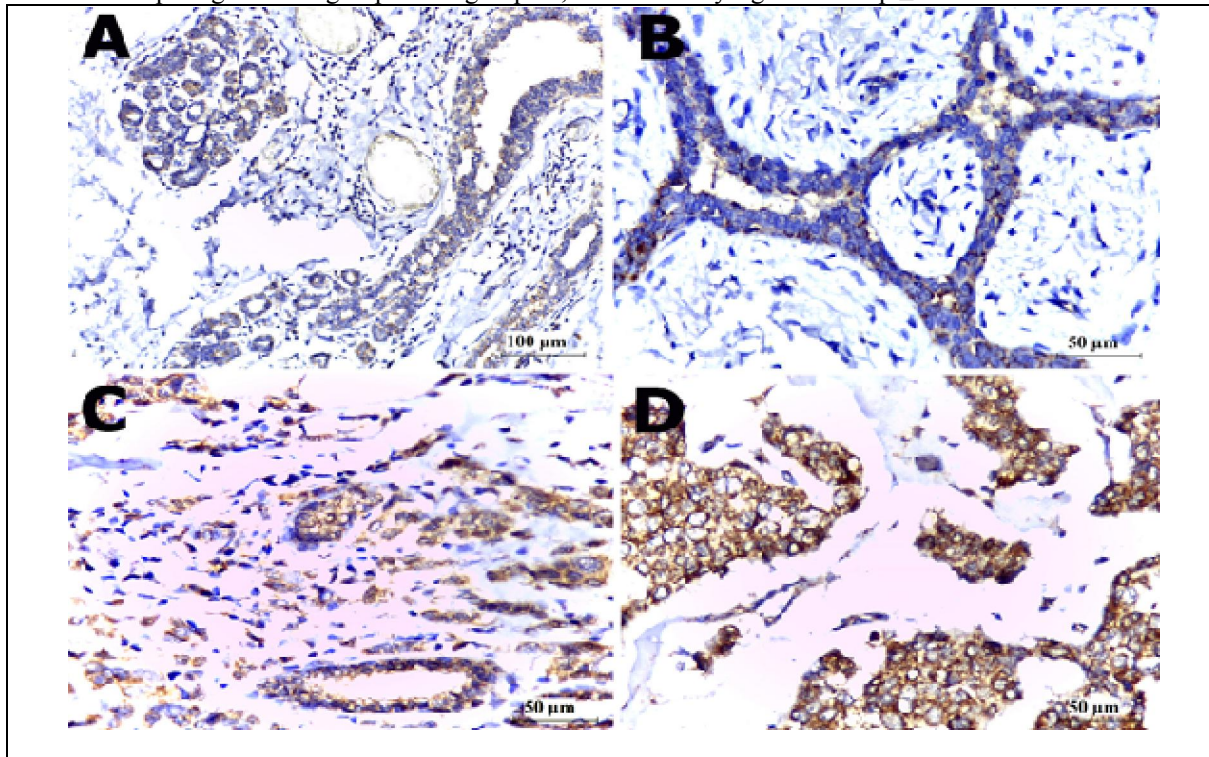
<sup>2</sup>: Chi square test for comparing between the four groups and each two groups.

MC: Monte Carlo for Chi square test for comparing between the four groups and each two groups.

p<sub>Control</sub>: p value for comparing between group IV (Control) and each other group.

p<sub>1</sub>: p value for comparing between group I and group II, p<sub>2</sub>: p value for comparing between group I and group III, p<sub>3</sub>:

p value for comparing between group II and group III, \*: Statistically significant at  $p \leq 0.05$ .



**Figure (1):** Immunohistochemical expression of IL-33 in: (A) Fibrocystic change (group 1) showing weak (+1) IL-33 expression (Immunoperoxidase X200), (B) fibroadenoma (group 1) showing weak (+1) IL-33 expression (Immunoperoxidase X400), (C) IDC-NOS grade II stage II (group 2) showing moderate (+2) IL-33 expression (Immunoperoxidase X400), and (D) IDC-NOS grade III stage III (group 3) showing strong (+3) IL-33 expression (Immunoperoxidase X400).

**3.5. Immunohistochemical expression of prohibitin in the studied groups**

Prohibitin showed similar pattern of expression to IL-33, where the highest expression was detected in breast carcinomas [28/30 (93.3%)], compared to benign breast lesions [8/15 (53.3%)] and normal breast tissue [0/15 (0%)] with statistically significant differences (p <0.001).

The expression of PHB was significantly higher in group 3 “stage III” compared to group 2 “stage I and II” breast cancer (p <0.001) and group 1 (p

=0.001) indicating upregulation of its expression with cancer progression. Also, all the studied grade III carcinomas (100%) showed PHB expression compared to 17/19 (89.5%) grade II carcinomas. PHB expression was significantly higher in group 1 “benign group” compared to group 4 “control group” (p=002); however, no difference between its expression in fibroadenomas and fibrocystic change were found. The immunohistochemical expression of prohibitin among the studied groups is shown in figure (2) and table (2).

**Table (2): Immunohistochemical expression of prohibitin among the studied groups.**

Prohibitin IHS	Group 1 (n= 15)		Group 2 (n= 15)		Group 3 (n= 15)		Group 4 (Control) (n= 15)		MC	p
	No	%	No	%	No	%	No	%		
Negative	7	46.7	2	13.3	0	0.0	15	100.0	67.318*	<0.001*
+1	8	53.3	3	20.0	0	0.0	0	0.0		
+ 2	0	0.0	7	46.7	3	20.0	0	0.0		
+ 3	0	0.0	3	20.0	12	80.0	0	0.0		
<b>p<sub>Control</sub></b>	<sup>FE</sup> p=0.002*		<sup>FE</sup> p=0.009*		<sup>MC</sup> p<0.001*					
<b>Sig. bet. grps.</b>	<sup>MC</sup> p <sub>1</sub> =0.002*		<sup>MC</sup> p <sub>2</sub> =0.001*		<sup>MC</sup> p <sub>3</sub> <0.001*					

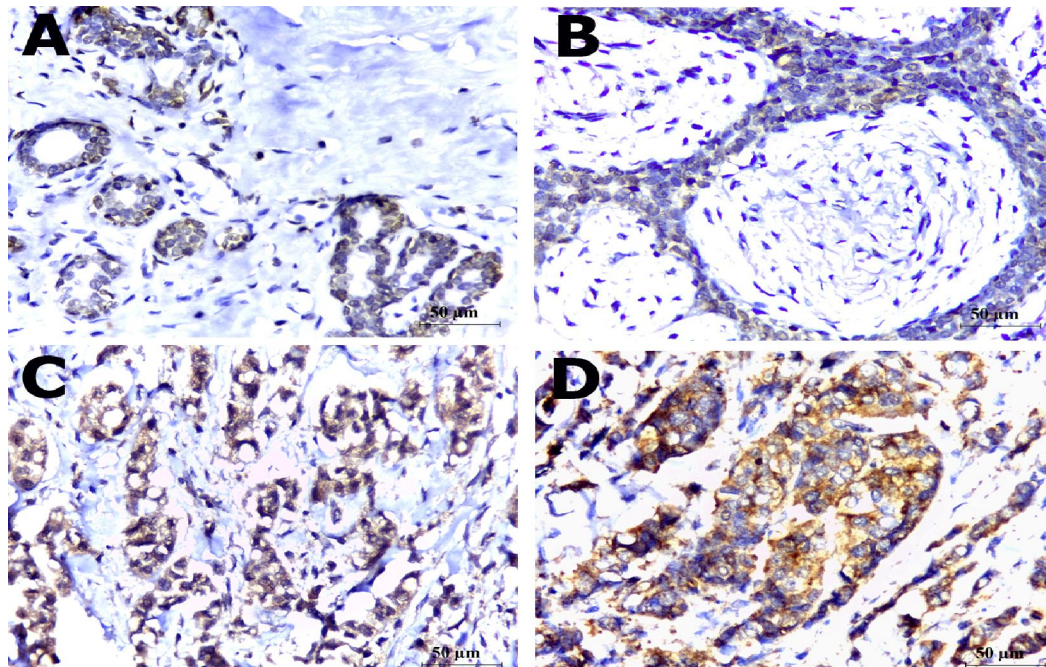
<sup>2</sup>: Chi square test for comparing between the four groups and each two groups.

MC: Monte Carlo for Chi square test for comparing between the four groups and each two groups.

p<sub>Control</sub>: p value for comparing between group IV (Control) and each other group.

p<sub>1</sub>: p value for comparing between group I and group II, p<sub>2</sub>: p value for comparing between group I and group III.

p<sub>3</sub>: p value for comparing between group II and group III, \*: Statistically significant at p ≤ 0.05.



**Figure (2):** Immunohistochemical expression of prohibitin in: (A) Fibrocystic change (group 1) showing weak (+1) prohibitin expression (Immunoperoxidase X400), (B) fibroadenoma (group 1) showing weak (+1) prohibitin expression (Immunoperoxidase X400), (C) IDC-NOS grade II stage I (group 2) showing moderate (+2) prohibitin expression (Immunoperoxidase X400), and (D) IDC-NOS grade III stage III (group 3) showing strong (+3) prohibitin expression (Immunoperoxidase X400).



A significant positive correlation was found between IL-33 immunohistochemical expression and serum levels of IL-33 in all the studied groups ( $p < 0.05$ ). There was also a significant positive

correlation between IL-33 and PHB immunohistochemical expression in malignant breast tumours ( $p < 0.05$ ). Other correlations are represented in table (3).

**Table (3): Correlations between serum IL-33, ST2 and immunohistochemical expression of both IL-33 and prohibitin in the studied groups.**

	Group 1		Group 2		Group 3		Group 4	
	$r_s$	$p$	$r_s$	$p$	$r_s$	$p$	$r_s$	$p$
sIL-33 vs. sST2	0.291	0.293	0.467	0.079	-0.231	0.408	0.533*	0.041
sIL-33 vs. IL-33 (IHC)	0.823*	<0.001	0.954*	<0.001	0.754*	0.001	0.695*	0.004
sST2 vs. IL-33 (IHC)	0.197	0.481	0.388	0.153	-0.360	0.187	0.116	0.681
sST2 vs. prohibitin (IHC)	0.420	0.119	0.390	0.151	-0.193	0.491		
IL-33 (IHC) vs. prohibitin (IHC)	0.378	0.165	0.776*	0.001	0.707*	0.003		

$r_s$ : Spearman coefficient, \*: Statistically significant at  $p \leq 0.05$

#### 4. Discussion

Breast cancer is an important health challenge that women face and affects their safety and productivity (Ismail et al., 2013). Several aetiological factors have been involved in its pathogenesis including age, family history, genetics, diet, alcohol, obesity, lifestyle, physical inactivity, and endocrine factors, so it is considered a multi-factorial disease (Kruk, 2014).

In this work, we studied the IL-33/ST2 axis and the immunohistochemical expression of prohibitin and IL-33 in benign and malignant breast lesions in comparison to normal breast tissue in a trial to investigate their role in breast carcinogenesis.

Interleukin 33 (IL-33) is a member of the IL-1 family of cytokines with a large number of target cells and many biological functions (Martin & Martin, 2016). It participates in many diseases with dual, pro-inflammatory or protective roles depending on the cellular and cytokine context (Liew et al., 2010). It is noticed that IL-33 levels were elevated in the serum of patients with different types of cancer, including gastric, lung and hepatocellular cancers (Chen et al., 2014).

In our study, serum levels of IL-33 were significantly increased in groups with breast lesions compared to the control group. In addition, they were significantly higher in malignant cases than benign lesions ( $p < 0.001$ ). Moreover, they showed significant increase with progression from early "stage I and II" to advanced "stage III" breast cancer ( $p < 0.001$ ). On the contrary, serum levels of sST2 were significantly lower in malignant cases than benign lesions, and were significantly decreasing with progression of cancer from to early "stage I and II" to advanced "stage III" breast cancer ( $p < 0.001$ ). These results are

in accordance with Chen et al. (2014) and Liu et al. (2014), suggesting that serum levels of IL-33/ST2 may be used as useful indicators for breast cancer prognosis.

In addition to serum IL-33 levels, we studied the tissue immunohistochemical expression of IL-33, and the results were correlated. IL-33 showed significantly higher expression in breast cancer cases compared to normal breast tissue ( $p < 0.05$ ). Similar results were documented by Kim et al., (2015). We observed slightly higher IL-33 expression in benign breast lesions compared to control group; however, the difference was statistically insignificant ( $p > 0.05$ ). On the other hand, IL-33 expression was significantly higher in breast cancer in comparison to benign breast lesions ( $p < 0.05$ ). This was in accordance with Liu et al., (2014), who suggested that the local expression of IL-33 may be an important marker for differentiating malignant from normal/benign tissues, and found that IL-33 expression in tissues adjacent to cancer also tends to be higher compared to normal tissues, suggesting that adjacent non-cancerous tissues may be similarly relevant to cancers in terms of anti-tumour immunity.

In the studied breast cancers, we found that IL-33 expression increased significantly with increasing tumour stage ( $p = 0.001$ ), and also showed increased expression in higher grade tumours, which was in agreement with Gillibert-Duplantier et al., (2012), who reported that IL-33 expression was significantly higher in HER2-overexpressing carcinomas, consistent with the report that its receptor sST2 was over-expressed to promote breast cancer metastases upon ErbB2 activation in breast cancer cell lines, This may be explained by the studies suggesting that the IL-33/ST2 pathway inhibits antitumour immunity,

subsequently promoting breast cancer metastasis (Jovanovic et al., 2014). So, IL-33 may be considered an indicator of bad prognosis in breast cancer.

In contrast to our results, Liu et al., (2014) found higher IL-33 expression in low grade tumours compared to high grade ones, they also found that IL-33 expression was not significantly associated with the tumour stage. Additionally, they found that the serum concentration of sST2 has been elevated in patients with metastatic breast cancer. These differences may be attributed to the variations in the number of cases, the different isoforms of the markers used, the scoring methods, the sample size and the population differences.

Previous studies investigated the IL-33/ST2 axis in breast cancer patients; however, its exact role in tumour growth and metastasis has not been fully explored. Jovanovic et al. (2011) have reported that mice lacking ST2 showed slower breast cancer growth and progression than normal mice. Their further experimental studies on breast cancer revealed, that deletion of ST2 signaling may enhance anti-tumour immune response in a murine model of metastatic 4T1 breast carcinoma. In addition, IL-33/ST2 pathway promotes breast cancer progression and metastasis through increased intratumoural accumulation of immunosuppressive cells and by diminishing innate anti-tumour immunity, with subsequent tumour progression and metastasis (Jovanovic et al., 2012; Jovanovic et al., 2014).

Kim et al. (2015) explained that IL-33/ST2 cascade induces the activation of signal transducer and activator of transcription 3 (STAT3) signaling pathways and transcriptional activity. When small interfering RNAs of ST2 were introduced into cells, IL-33-induced STAT3 activity was significantly decreased, unlike that in the control cells. Additionally, knockdown of IL-33 and ST2 in breast cancer cells attenuated tumourigenicity. These findings provide an insight on the role of IL-33/ST2 signaling pathway in supporting cancer-associated inflammation in the tumour microenvironment. Therapeutic approaches that target this pathway may, therefore, effectively inhibit carcinogenesis in the breast. So, in addition to its role as a potential prognostic biomarker, IL-33 is a good target for new therapeutic strategies.

Prohibitin is a multifunctional protein, which has multiple intracellular locations including the mitochondria, the nucleus, and in lipid rafts of the cytoplasmic membrane (Rajalingam et al., 2005). Prohibitin gene is located on chromosome 17q21 close to the ovarian and breast carcinoma susceptibility gene (BRCA1) locus and may function as growth regulatory molecule within several tissues. This protein was suggested to exert different roles in

tumourigenesis (Franzoni et al., 2009; Savulescu et al., 2013).

In this study, immunohistochemical analysis revealed that both benign breast lesions (including fibrocystic change and fibroadenomas) and breast carcinoma cases showed significantly higher prohibitin expression compared to normal breast tissue ( $p < 0.05$ ), moreover, the expression was significantly higher in breast carcinomas compared to benign breast lesions ( $p < 0.05$ ). Similar observations concerning the higher prohibitin expression in carcinomas were reported by other studies indicating that prohibitin expression was up-regulated in tumour cells compared to normal cells in different organs (Peng et al., 2006; Najm et al., 2013).

Within the studied carcinomas, we investigated the relation between prohibitin expression and some clinicopathological variables including the histologic grade and tumour stage. We found that prohibitin expression was increased with increasing tumour grade, which is in accordance with other studies (Najm et al., 2013; Webster et al., 2013).

We found that prohibitin expression was also significantly increased with increasing tumour stage ( $p < 0.001$ ). These results are contrasting to those reported by Najm et al. (2013), who found that prohibitin expression was higher in lower stage breast cancer. The inconsistencies in the results may be attributed to the same factors mentioned in relation to IL-33 expression.

There is a compelling evidence that prohibitin plays an important role in carcinogenesis; however, its exact function is still poorly understood in spite of the different studies. One of the mechanisms suggested to explain the role of prohibitin as a potential tumour suppressor gene is its interaction with the cell cycle checkpoint molecules, including E2F, p53, and pRB, which was also reinforced by the finding that the overexpression of prohibitin modulated the transcription of multiple genes in the transfection experiments, and that microinjection of prohibitin transcripts resulted in growth arrest in HeLa cells (Peng et al., 2006). It has been previously proved to play an important role in cell migration through affection of cell adhesion (Rajalingam et al., 2005).

In breast cancer, the consistently higher levels of prohibitin in cancer cells may be due to the transactivation of c-Myc gene (Nijtmans et al., 2002). Other explanations for the upregulation of prohibitin expression in breast cancer are its overexpression in metabolic stress after heat shock or oxidative stress, or as one of the attempts of the cell to suppress the high proliferation rate (Najm et al. 2013). These findings reveal the importance of prohibitin as crucial gene in breast cancer pathogenesis, progression and treatment. Moreover, the upregulation of prohibitin expression

with increasing tumour grade and stage observed in this study suggests its value as a poor prognostic marker in breast cancer.

In this study, a significant positive correlation was found between the serum level of IL-33 and its immunohistochemical expression in all studied groups ( $p < 0.05$ ). Additionally, a significant positive correlation between IL-33 and prohibitin immunohistochemical expression was found in malignant breast tumours ( $p < 0.05$ ). These results indicate that serum IL-33 may be used as a simple non-invasive technique for predicting the prognosis of breast cancer.

### 5. Conclusion

IL-33/ST2 and prohibitin have vital roles in breast cancer development. The increased expression of IL-33 and prohibitin with increasing tumour grade and stage indicates that they may be useful prognostic markers for breast cancer.

### Conflict of interest

There is no conflict of interest or financial ties to include.

### References

1. Abdulkareem IH. Aetio-pathogenesis of breast cancer. *Niger Med J*. 2013; 54 (6):371-5.
2. Bergis D, Kassis V, Ranglack A, Koeberle V, Piiper A, Kronenberger B, et al. High Serum Levels of the Interleukin-33 Receptor Soluble ST2 as a Negative Prognostic Factor in Hepatocellular Carcinoma. *Transl Oncol*. 2013; 6 (3):311-8.
3. Chen XJ, Huang YD, Li N, Chen M, Liu F, Pu D, et al. Correlations between serum IL33 and tumour development: a meta-analysis. *Asian Pac J Cancer Prev* 2014, 15 (8):3503-5.
4. Elston CW, Ellis IO. Pathological prognostic factors in breast cancer. I. The value of histological grade in breast cancer: experience from a large study with long-term follow-up. *Histopathology* 1991; 19 (5):403–10.
5. Franzoni A, Dima M, D'Agostino M, Puppini C, Fabbro D, Loreto C D, et al. Prohibitin is overexpressed in papillary thyroid carcinomas bearing the BRAF(V600E) mutation. *Thyroid* 2009; 19 (3):247-55.
6. Gillibert-Duplantier J, Duthey B, Sisirak V, Salaun D, Gargi T, Tredan O, et al. Gene expression profiling identifies sST2 as an effector of ErbB2-driven breast carcinoma cell motility, associated with metastasis. *Oncogene* 2012; 31 (30):3516–24.
7. Gou HF, Chen XC, Zhu J, Jiang M, Yang Y, Cao D, and Hou M. Expressions of COX-2 and VEGF-C in gastric cancer: correlations with lymphangiogenesis and prognostic implications. *Journal of Experimental & Clinical Cancer Research* 2011; 30:14.
8. Ismail GM, Abd El Hamid AA, Abd ElNaby AG. Assessment of Factors that Hinder Early Detection of Breast Cancer among Females at Cairo University Hospital. *World Applied Sciences Journal* 2013; 23 (1): 99-108.
9. Jovanovic IP, Pejnovic NN, Radosavljevic GD, Arsenijevic NN, Lukic ML. IL-33/ST2 axis in innate and acquired immunity to tumours. *Oncoimmunology* 2012; 1 (2):229-31.
10. Jovanovic IP, Pejnovic NN, Radosavljevic GD, Pantic JM, Milovanovic MZ, Arsenijevic NN, et al. Interleukin-33/ST2 axis promotes breast cancer growth and metastases by facilitating intratumoural accumulation of immunosuppressive and innate lymphoid cells. *Int J Cancer*. 2014; 134 (7):1669-82.
11. Jovanovic IP, Radosavljevic G, Mitrovic M, Juranic VL, McKenzie AN, Arsenijevic N, et al. ST2 deletion enhances innate and acquired immunity to murine mammary carcinoma. *Eur J Immunol* 2011, 41 (7):1902-12.
12. Kim JY, Lim SC, Kim G, Yun HJ, Ahn SG, and Choi HS. Interleukin-33/ST2 axis promotes epithelial cell transformation and breast tumorigenesis via upregulation of COT activity. *Oncogene* 2015; 34 (38):4928-38.
13. Kirkpatrick LA, Feeney BC. A Simple Guide to IBM SPSS Statistics for Version 20.0. Student ed. Belmont, CA: Wadsworth, Cengage Learning (2013).
14. Kruk J. Overweight, obesity, oxidative stress and the risk of breast cancer. *Asian Pac J Cancer Prev*. 2014; 15 (22):9579-86.
15. Liew FY, Pitman NI, McInnes IB. Disease-associated functions of IL-33: the new kid in the IL-1 family. *Nat Rev Immunol* 2010; 10 (2):103–10.
16. Liu J, Shen J X, Hu J L, Huang W H, and Zhang G J. Significance of interleukin-33 and its related cytokines in patients with breast cancers. *Front. Immunol*. 2014; 5 (141):1-7.
17. Lu DP, Zhou XY, Yao LT, Liu CG, Ma W, Jin F, et al. Serum soluble ST2 is associated with ER-positive breast cancer. *BMC Cancer*. 2014; 14:198.
18. Martin NT; Martin MU. Interleukin 33 is a guardian of barriers and a local alarmin. *Nature Immunology* 2016; 17:122-131.
19. Miller AB. Screening for breast cancer in the Eastern Mediterranean Region. *East. Mediterr. Health J.*, 2010; 16 (10): 1022-4.



20. Milovanovic M, Volarevic V, Radosavljevic G, Jovanovic I, Pejnovic N, Arsenijevic N, et al. IL-33/ST2 axis in inflammation and immunopathology. *Immunol Res.* 2012; 52(1-2):89-99.
21. Najm MZ, Zaidi S, Siddiqui WA, and Husain SA. Immunohistochemical expression and mutation study of Prohibitin gene in Indian female breast cancer cases). *Med Oncol* 2013; 30:614.
22. Nijtmans LG, Artal SM, Grivell LA, and Coates PJ. The mitochondrial PHB complex: roles in mitochondrial respiratory complex assembly, ageing and degenerative disease. *Cell Mol Life Sci* 2002; 59: 143-55.
23. Peng X, Mehta R, Wang S, Chellappan S, and Mehta R G. Prohibitin is a novel target gene of vitamin D involved in its antiproliferative action in breast cancer cells. *Cancer Res* 2006; 66 (14):7361-9.
24. Rajalingam K, Wunder C, Brinkmann V, Churin Y, Hekman M, Sievers C, et al. Prohibitin is required for Ras-induced Raf-MEK-ERK activation and epithelial cell migration. *Nat Cell Biol* 2005; 7: 837-43.
25. Savulescu D, Feng J, Ping YS, Mai O, Boehm U, He B et al. Gonadotropin-releasing hormone-regulated prohibitin mediates apoptosis of the gonadotrope cells. *Mol Endocrinol* 2013; 27:1856–70.
26. Schmitz J, Owyang A, Oldham E, Song Y, Murphy E, McClanahan TK, et al. IL-33, an interleukin-1-like cytokine that signals via the IL-1 receptor-related protein ST2 and induces T helper type 2-associated cytokines. *Immunity* 2005; 23 (5):479-90.
27. Webster L R, Provan P J, Graham D J, Byth K, Walker R L, Davis S, et al. Prohibitin expression is associated with high grade breast cancer but is not a driver of amplification at 17q21.33). *Pathology* 2013; 45 (7): 629-36.
28. Wood IS, Wang B, Trayhurn P. IL-33, a recently identified interleukin-1 gene family member, is expressed in human adipocytes. *Biochem Biophys Res Commun* 2009; 384 (1):105–9.

12/25/2016