

## Immunohistochemical Expression of P63 In Urothelial Carcinoma

Afaf T. Elnashar<sup>1</sup>, Noha ED Hassab El-Naby<sup>1</sup>, Ola M. Nageeb<sup>1</sup> and Atef G. Abd El Wahab<sup>2</sup>

<sup>1</sup>Pathology and <sup>2</sup>Urology Departments, Sohag University Hospital  
[elnasharafaf@yahoo.com](mailto:elnasharafaf@yahoo.com)

**Abstract:** Introduction: Urothelial carcinoma is the most common histologic type of urinary bladder cancer in Egypt. Detection of high-grade urothelial carcinoma is important for modification of therapy and improving the prognosis. P63 is expressed at high levels in the basal layers of different epithelial tissues, including the urothelium. Aim of the work: to study the diagnostic and prognostic value of p63 expression in urothelial carcinoma (UC). Material and Methods: Fifty cases of bladder urothelial carcinoma were involved in the study; 12 cases of non-invasive UC, (3 HG & 9 LG), and 38 cases of invasive UC (30 HG & 8 LG). Sixteen cases of UC showed Bilharziasis. All the specimens were stained with p63 using immunohistochemical technique. Results: P63 was expressed in 28/38 cases (73.7%) of invasive UC and in all cases of non-invasive UC, and also in 16/17 (94%) low-Grade and in 24/33 (72.7%) of high-grade UC, with a statistically significant relation between p63 expression and both invasion ( $p > 0.001$ ) and the tumor grade ( $p > 0.034$ ). Conclusion: P63 can be used as a diagnostic and a prognostic factor for high grade invasive UC.

[Afaf T. Elnashar, Noha ED Hassab El-Naby, Ola M. Nageeb and Atef G. Abd El Wahab. **Immunohistochemical Expression of P63 In Urothelial Carcinoma.** *Cancer Biology* 2016;6(3):19-26]. ISSN: 2150-1041 (print); ISSN: 2150-105X (online). <http://www.cancerbio.net>. 3. doi:[10.7537/marscbj060316.03](https://doi.org/10.7537/marscbj060316.03).

**Key words:** P63, urothelial carcinoma (UC), High Grade (HG), Low Grade (LG).

### 1. Introduction:

Bladder cancer is the most common cancer among Egyptian men, and it has mortality rates twice as high as the rate in Europe and 4 times greater than in the United States (1). Urothelial carcinoma (UC) is the most common histologic type of urinary bladder cancer, constituting more than 90% of bladder cancer cases in United States (2). In Egypt, there was significant rise of UC from 16% to 65.8%, becoming at present the most common tumor type, with a significant decrease in squamous cell carcinoma (SCC) from 75.9% to 28.4% (3). This may be due to increased exposure to etiological factors as smoking and pesticides (4). Urothelial carcinoma of the bladder is a complex heterogeneous disease with a broad spectrum of histological findings and potentially lethal behavior. Despite advances in surgical techniques as well as in intra-vesical and systemic therapy; up to 30% of patients with non-invasive and 50% of patients with invasive urothelial carcinoma experience disease progression, recurrence, and eventual death (5). With regard to clinical management, urothelial neoplasms are divided into two major phenotypic variants; low-grade and high-grade invasive carcinoma. The former has and eventually provided better prognosis (6).

P63 is a transcription factor belonging to the p53 family and shares structural and sequence homology with p53. It is a nuclear protein encoded by a gene on chromosome 3q27-29 (7 & 8). P63 is a marker of basal epithelial cells and is required for normal development of several epithelial tissues including

bladder and prostatic glands (9). The human TP63 gene-localized on chromosome 3-consists of 15 exons and contains two promoters. Transcription from the first promoter, located upstream of exon 1, gives rise to the full-length protein TAp63. Transcription from the second promoter results in the production of N-terminally truncated protein isoforms,  $\Delta$ Np63. Due to alternative splicing of the 3' end of TP63 mRNA, there are also several C-terminal protein isoforms, like  $\alpha$ ,  $\beta$ ,  $\gamma$  and the recently described  $\delta$  and  $\epsilon$ . This further contributes to the diversity of the p63 protein products (10). Different studies support the hypothesis that p63 can function as a tumour suppressor, especially TAp63 isoform. For example TAp63 overexpression is responsible for the activation of p53 responsive genes leading to cell cycle arrest and apoptosis. Additionally, it was also found that TAp63 can mediate apoptosis by triggering death receptor complexes (CD95, TRAIL) and mitochondrial death pathway (BAX, APAF1) (11). On the other hand,  $\Delta$ Np63 inhibits death receptors-mediated apoptosis and chemotherapy-induced mitochondrial apoptosis pathways and thus functions as an oncogene (12). Many studies have investigated the role of p63 in urothelial neoplasms. The first group of investigators proposed that over expression of p63 mRNA relates to carcinogenesis and tumour progression (13). In contrast, other studies revealed that high-grade invasive urothelial carcinomas frequently diminish p63 expression, whereas low-grade tumours highly preserve the normal p63 expression (14). Impaired p63 expression is thought to be a prognostic marker along

with the well-established prognostic factors, such as TNM stage, indicating that impaired p63 characterizes biological aggressiveness of urothelial neoplasms (15). Recently p63 has been shown to be a marker of tumours of urothelial origin (16).

**The aim of the work:**

To study the expression of p63 in UC and to detect the value of using p63 expression as a prognostic marker.

**2. Material and methods:**

The specimens of the study were obtained randomly from urothelial carcinoma (UC) cases admitted to The Urology Department and referred to the Pathology Laboratory at Sohag University Hospital, in the period between May 2014 and June 2015. The total number of studied specimens was 50 cases divided into 17 cases low-grade UC, 33 cases high-grade UC, 12 noninvasive UC and 38 invasive UC. Clinical data were obtained from the referral clinical reports. These data included: age, sex, clinical presentations, laboratory tests and the method of obtaining the specimen. The biopsies were obtained by either transurethral resection (TUR) or radical cystectomy. Each case in the study was stained by routine H&E stained slides to evaluate the diagnosis, grading according to World Health Organization classification of tumors 2004 (17) and staging according to American Joint Committee on Cancer 2010 (18). For immunohistochemical staining, Five micron-thick sections from the formalin-fixed paraffin-embedded blocks of all specimens were cut on chrome alum-gelatin adhesive coated slides and immunostained using peroxidase-labeled streptavidin-biotin immuno-enzymatic antigen-detection kit to detect p63 expression. Mouse monoclonal p63 antibody (clone 4A4), catalog # (CM163A, B, C, H. BIOCARE MEDICAL corporation) was used. All the specimens were stained with the antibody. Tissue sections were deparaffinized in 2 changes of xylene, rehydrated through descending grades of alcohols and washed in distilled water. Endogenous peroxidase activity was blocked with hydrogen peroxide, and then washed in 20% diluted phosphate buffered saline (PBS). Slides were immersed in antigen retrieval solution (10 mmol sodium citrate buffer solution, pH 6.0) and put in the oven at 100°C for 2 hours, washed in distilled water and in PBS. Tissue sections were incubated with P63 at a dilution of 1/100 in normal goat serum (NGS) at a dilution of (1/100) overnight at room temperature to block nonspecific interactions. After rinsing in PBS, tissue sections were treated with biotinylated goat serum for 10 min at room temperature. The slides were rinsed in PBS and peroxidase-labeled streptavidin was applied for 10 min at room

temperature, rinsed again in PBS and blotted. The slides were incubated with 1 micron chromogen to 25 micron diaminobenzidine (DAB) for 20 minutes, washed in distilled water and counter-stained using Myer's Hematoxylin. Tissue sections were washed in tap water dehydrated in ascending grades of alcohol, cleared in xylol, left to dry, then mounted with DPX, and cover slipped. Positive control was section from normal prostate. Negative control was sections of the examined tissues but with omission of the primary antibody.

**Evaluation of immunostaining of p63:**

The entire sections were histologically examined by bright field microscope to evaluate the immunostaining positivity as the mean percentage of positive cells and staining intensity in at least three different fields. Cells stained positive for p63 were identified by the presence of nuclear staining. Semi-quantitation of nuclear p63 immunoreactivity was calculated with a 12-point weighted score system. First, the percentage of positive cells in each area was scored with a 5-point scale: 0 for <5%, 1 for 5-25%, 2 for 25-50%, 3 for 50-75%, and 4 for over 75%. Second, the intensity of positive signal was scored with a 3-point scale: 0 for negative, 1 for weak, 2 for medium, and 3 for strong staining, then, the weighted score for each area was calculated by multiplying the percentage of positive cells by the intensity of staining score. The results were scored as negative (0-1), weak (2-3), moderate (4-6) and strong (8-12) (19). Results were statistically analyzed using Statistical Package for Social Sciences (SPSS) for windows. The association of p63 protein expression with the other bladder carcinoma variables was assessed by the Pearson's Chi-square test. *P* value less than 0.05 was considered significant.

**3. Results**

This study included 50 specimens of urothelial carcinoma of the urinary bladder included 38 cases were diagnosed as invasive UC and 12 cases were diagnosed as non-invasive UC, 33/50 of cases were high grade and 17 cases were low grade. The age range of the 50 studied patients was 20-80 years, mean age was 57.2 years, and median age was 56 years. 42/50 (84%) were males and 8/50 (16%) were females with male: female ratio 5.25:1. Tissue specimens were obtained by TUR in 41 cases (82%) and by radical cystectomy in 9 cases (18%).

**Histopathological findings:**

The collected 50 cases of bladder urothelial carcinoma were graded according to World Health Organization classification (17). Stage grouping and TNM pathological classification were carried out according to The American Joint Committee on Cancer (AJCC) (18). Twelve cases (24%) of

non-invasive urothelial carcinoma were divided into three cases (25%) high grade, and nine cases (75%) low grade. Thirty eight cases (76%) (38/50) were invasive urothelial carcinoma; with thirty cases were high grade, and eight cases (21%) were low grade. Three cases (3/12) (25%) of non-invasive urothelial carcinoma and thirteen cases (13/38) (34.2%) of invasive urothelial carcinoma showed Bilharziasis. Four cases (4/17) of low grade UC and (12/33) of UC showed Bilharziasis.

#### Immunohistochemical finding:

P63 expression appeared as brownish nuclear staining in basal cells of the normal prostatic glands which were used as a positive control. P63 was expressed in 28/38 cases of invasive UC (73.7%) with variation in its expression as it was strongly expressed in 12/38 (31.6%), moderately expressed in 8/38 (21%), weakly expressed in 8/38 (21%) and was negative in 10/38 (26.3%) of cases. P63 was expressed in all cases of non-invasive UC as it was strongly

expressed in 7/12 (58.33%), moderately expressed in 2/12 (16.6%), weakly expressed in 3/12 (25%) of cases (Table 2, Figure 3).

P63 showed variation in its expression in 24/33 cases (72.7%) of high-grade UC as it was strongly expressed in 8/33, moderately expressed in 7/33, weakly expressed in 9/33 and was not expressed in 9/33 (27.3%) of cases. Expression of p63 in (16/17 cases) of low-grade UC and was strong in 11/17, moderate in 3/17 cases, weak expression in 2/17 cases and no expression in 1/33 of cases (Table 3). There was a statistically significant correlation between p63 expression and tumor grade,  $P$  value > (0.034) (decreased expression with increasing grade). There was no statistically significant correlation between p63 expression and clinical parameters (age, sex, bilharziasis, and myoinvasion) although we found that p63 immunostaining was decreased with deeper muscle invasion of the tumor.

**Table 1: Clinical data of studied patients (No= 50)**

Parameter	Histopathological type			
	Noninvasive UC No = 12	Invasive UC No = 38	High grade UC No = 33 (N	Low grade UC No = 17
<b>Age (years)</b>				
≤50	4	8	8	4
>50	8	30	25	13
<b>Sex</b>				
Males	11	31	26	16
Females	1	7	7	1
<b>Clinical features</b>				
Hematuria	5	13	10	7
Cystitis	6	23	20	9
Obstruction	1	2	3	1

**Table 2: P63 expression in non-invasive and invasive UC**

Tumor type	No of cases	P63 expression				P value
		+++	++	+	-ve	
<b>Non-invasive UC</b>	12	7	2	3	-	<b>0.0001*</b>
		12/12				
<b>Invasive UC</b>	38	12	8	8	10	
		28/38 (73.7%)				
					10/38	

Chi-square test was used. \*= Significant

**Table 3: P63 expression in UC according to tumor grading.**

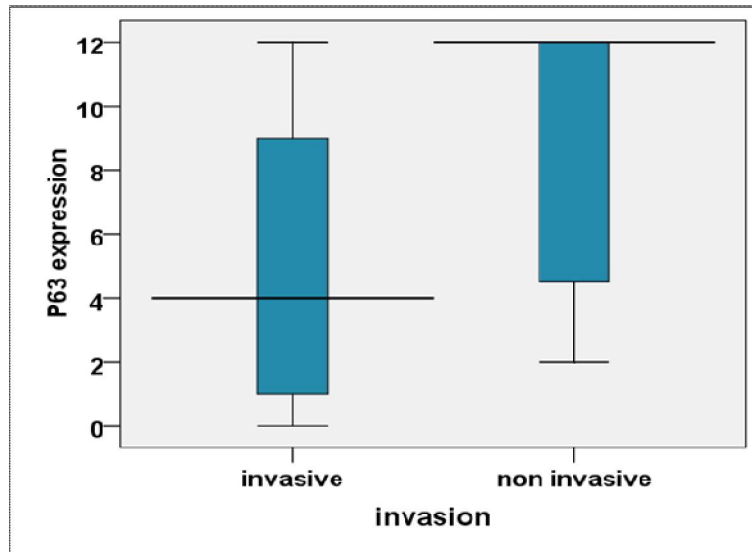
Tumor grade	No of cases	P63 expression				P value
		+++	++	+	-ve	
<b>Low grade UC</b>	17	11	3	2	1	<b>0.034*</b>
		16/17(94.1%)				
<b>High grade UC</b>	33	8	7	9	9	
		24/33(72.7%)				
					9/33(27.3%)	

Chi-square test was used, \*= Significant.

**Table 4: P63 expression in UC with the clinic pathological parameters:**

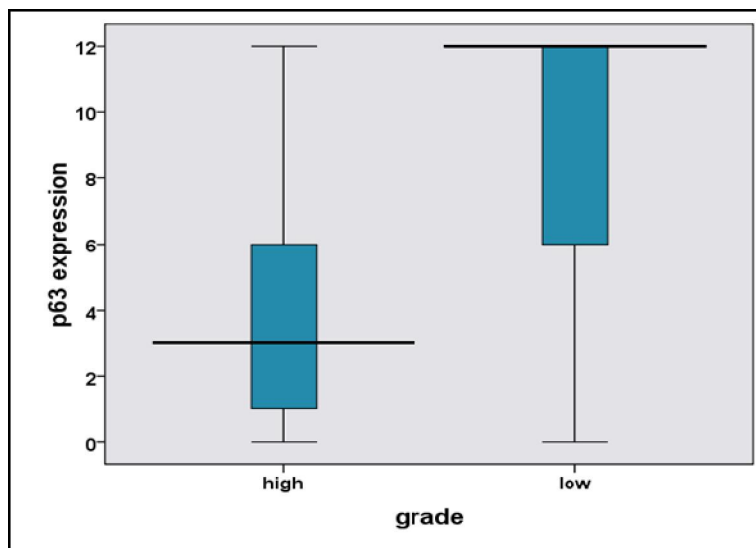
Clinico-pathological parameters	No of cases	P63 expression				P value
		-ve	+++	++	+	
<b>Age (years)</b>						
≤50	12	2	6	3	1	0.527(NS)
>50	38	8	13	7	10	
<b>Sex</b>						
Males	42	7	8	10	17	0.185(NS)
Females	8	3	3	-	2	
<b>Bilharziasis</b>						
Present	16	2	5	2	7	14/16(87.5%)(NS)
Absent	34	8	6	8	12	

Chi-square test was used, (NS) = Not Significant



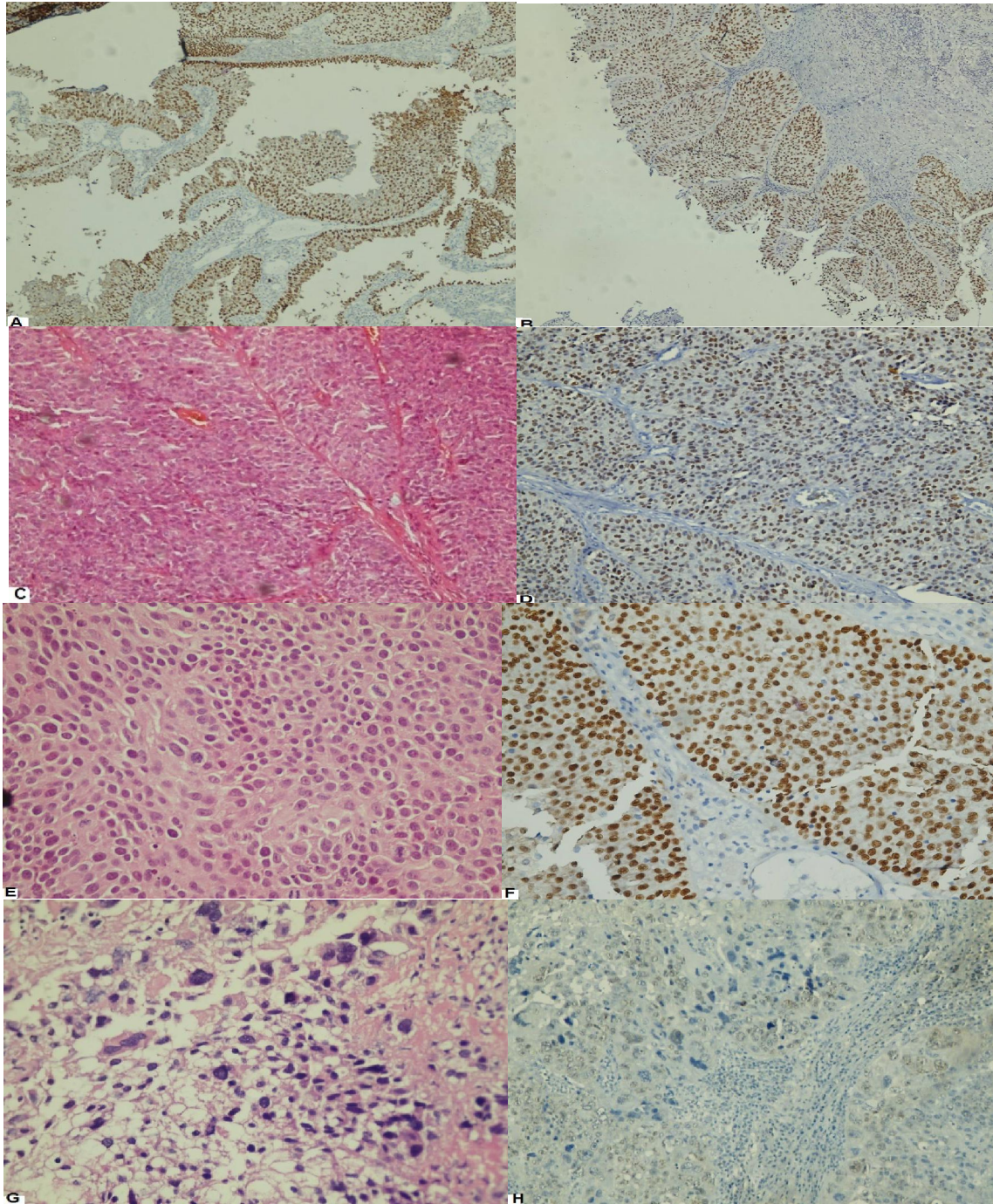
**Figure 1:** The expression of p63.

The horizontal bars represent median values, the boxes represent 50th percentiles, whiskers represent range of data and the numbers refer to total number of cases in each group.



**Figure 2:** The expressions of p63

The horizontal bars represent median values, the boxes represent 50th percentiles, whiskers represent range of data and the numbers refer to total number of cases in each group.



**Figure (3):** A & B: P63 strong expression in non-invasive, Low Grade UC, C: Invasive LG UC stained by H & E. D: p63 expression in invasive, LG UC. E: Invasive High Grade UC stained by H&E. F: strong p63 immunoeexpression. G: invasive High Grade UC stained by H & E. H: Weak p63 immunostaining.

#### 4. Discussion

Despite advances in surgical techniques as well as in systemic chemotherapy; up to 50% of patients in Egypt with invasive urothelial carcinoma suffered

from disease progression, recurrence, and eventual death. P63 has emerged as a critical player in embryonic development, epithelial stem cell maintenance and differentiation. In cancer biology,

p63 has been shown to be involved in all aspects of tumorigenesis and cancer progression (20). The gene encoding the tumor protein p63 is a member of the p53 family and like other family members contains two different promoters that generate two classes of p63 proteins. The trans activating TAp63 and the NH2-terminal truncated  $\Delta$ Np63. TAp63 contains an NH2-terminal transactivation domain that is absent in  $\Delta$ Np63. TAp63 and  $\Delta$ Np63 can be alternatively spliced at the 3' terminus to produce  $\alpha$ ,  $\beta$ ,  $\gamma$ , and  $\delta$  and isoforms (9). P63 regulates many genes involved in DNA repair,  $\Delta$ Np63 binds to the promoters of the RAD51, BRCA2, and MRE11 genes which are involved in homologous recombination, one of the most important pathways for repair of double-strand breaks. In addition, p63 interacts with ATM, a key kinase involved in the recognition of DNA double-strand breaks (21).

Analysis of biopsy samples have shown that reduced P63 expression is associated with progression and advanced stages of breast cancer (22 & 23) cancer bladder (14) and melanoma (24). P63 was expressed in all normal and hyperplastic urothelium in the areas adjacent to the tumor in our study cases. An earlier study at 2001 revealed that p63 is proposed to be critical for the proliferation and maintenance of epithelial progenitor cells population that give rise to the differentiated stratified squamous epithelial cells rather than for the differentiation process itself (25). On the other hand, a study group reported that P63 expression was correlated with the degree of differentiation in the superficial lesion and with the number of cell layers which covered the tumor papillae in muscle-invasive urothelial carcinoma (26). Several reports which tried to evaluate the role of p63 in the process of tumorigenesis suggest that p63 is involved in cell migration and adhesion and thus also in processes connected with these cell abilities such as metastasis and wound healing. Those studies that performed on SCC lines have demonstrated that disruption of p63 causes upregulation of genes associated with a higher potential to metastasize and invade (27), while a more recent study showed that TAp63 suppresses metastasis by regulating micro RNA processing complex (28).

In our study, P63 was expressed in (73.7%) of invasive UC and in all cases of non-invasive UC with a statistically significant relation ( $p$  value > 0.001). In agreement with many authors (29) who found that P63 was expressed in all cases of non-invasive papillary urothelial carcinoma and the immune-reaction was strong in low grade papillary superficial carcinoma (93%) than in high grade urothelial carcinoma (68%) that showed a significant reduction in P63 positivity. Koyuncuer in his study on the other hand found no statistically significant relation was observed between

invasive and non-invasive (pT1-PT2) urothelial carcinoma for P63 expression (30).

P63 showed positive expression in (72.7%) of high-grade UC and in (16/17 cases) of low-grade UC with a statistically significant correlation between p63 expression and tumor grade ( $P$  value > 0.034) (decreased expression with increasing grade).

There was no statistically significant correlation between p63 expression and deep myoinvasion and poor prognosis in the present study although we found that p63 immunostaining was decreased with muscle invasion of the tumor. In agreement with two studies concluded that P63 expression diminished in high grade invasive urothelial carcinoma (31 & 32). A recent study group at 2012 concluded that it is impossible to prospectively identify the lethal muscle-invasive tumors; however, accumulating evidence suggests that molecular reprogramming characteristic of a developmental process known as epithelial-to-mesenchymal transition (EMT) is involved. Muscle-invasive cancers are characterized by down-regulation of E-cadherin and p63, two epithelial markers uniformly expressed in normal urothelium and in non-muscle-invasive cancers. These changes are accompanied by up-regulation of mesenchymal markers Zeb-1, Zeb-2, vimentin, and MMP9, leading to increased invasion and migration. The most superficial bladder cancers have excellent long-term survival (near 100%), and uniformly express high levels of E-cadherin and p63. On the other hand, loss of p63 is restricted to a subset of the muscle-invasive tumors, and muscle-invasive disease is typically associated with worse clinical outcomes as compared to superficial, non-invasive cancer. In addition, the commercial antibody (4A4) that is most commonly used to measure p63 in tissue sections cannot distinguish the two major p63 isoforms (TA and  $\Delta$ N), so the relationship between  $\Delta$ N p63 expression and poor outcome in muscle-invasive bladder cancers could not be recognized in previous IHC-based studies that employed this reagent (33).

Another study group generated an anti-p63 antibody that is specific for the  $\Delta$ N isoforms and used it on an independent cohort of muscle-invasive tumors to show that  $\Delta$ N p63 protein levels also identify a lethal subset of cancers, whereas their results with the 4A4 antibody were inconclusive (34).

P63 was expressed in 87.5% of UC with bilharziasis and in 76.5% of UC cases with no bilharziasis with no statistically significant relation between bilharziasis and p63 expression. A single study on p63 and bilharziasis in -agreement with our study-found a tendency for a statistically significant decrease in the immunoreactivity in bilharzial cystitis ( $p > 0.05$ ) but in malignant tumors, bilharziasis had no apparent effects on the pattern of p63 expression (35).

## Conclusion

P63 can be used as a diagnostic factor specific for urothelial carcinoma and as a prognostic factor for high grade UC in our community.

## References

1. Ferlay J, Shin HR, Bray F, Forman D, Mathers C, Parkin DM. Estimates of worldwide burden of cancer in 2008: GLOBOCAN 2008. *Int J Cancer*. 2010; 127(12):2893-917.
2. Huang W, Williamson SR, Rao Q, Lopez-Beltran A, Montironi R, Eble JN, Grignon DJ, Idrees MT, Emerson RE, Zhou XJ, Zhang S, Baldrige LA, Hahn NM, Wang M, Koch MO, Cheng L. Novel markers of squamous differentiation in the urinary bladder. *Hum Pathol*. 2013; 44:1989-1997.
3. Gouda I, Mokhtar N, Bilal D, El-Bolkainy T, El-Bolkainy NM. Bilharziasis and bladder cancer: a time trend analysis of 9843 patients. *J Egypt Natl Canc Inst*. 2007; 19:158-162.
4. Khaled H. Schistosomiasis and cancer in Egypt: review. *Medical Oncology*, National Cancer Institute, Cairo University, Cairo 11796, Egypt. *J Advanced Res*. 2013; 4:461-466.
5. Shariat SF, Karakiewicz PI, Palapattu GS, Lotan Y, Rogers CG, Amiel GE, Vazina A, Gupta A, Bastian PJ, Sagalowsky AI, Schoenberg MP, Lerner SP. Outcomes of radical cystectomy for transitional cell carcinoma of the bladder: a contemporary series from the bladder cancer Research consortium. *J Urol* 2006; 176: 2414-2422.
6. Lee R and Droller MJ. The natural history of bladder cancer. Implications for therapy. *Urol Clin North Am*. 2000; 27: 1-13.
7. Higgins JP, Kaygusuz G, Wang L, Montgomery K, Mason V, Zhu SX, Marinelli RJ, Presti JC Jr, Van de Rijn M, Brooks JD. Placental S100 (S100P) and GATA3: Markers for transitional epithelium and urothelial carcinoma discovered by complementary DNA microarray. *Am J Surg Pathol*. 2007; 31:673-680.
8. Hodges KB, Lopez-Beltran A, Emerson RE, Montironi R, Cheng L. Clinical utility of immunohistochemistry in the diagnoses of urinary bladder neoplasia. *Appl Immunohistochem Mol Morphol*. 2010; 18:401-410.
9. Pignon J C, Grisanzio C, Geng Y, Song J, Shivdasani RA, Signoretti S. P63-expressing cells are the stem cells of developing prostate, bladder, and colorectal epithelia. *Proc Natl Acad Sci U S A*. 2013; 110 (20): 8105-8110.
10. Joerger, AC, Rajagopalan, S, Natan, E, Veprintsev, DB, Robinson, CV and Fersht, AR Structural evolution of p53, p63, and p73: Implication for heterotetramer formation. *Proc Natl. Acad. Sci. USA* 106 (2009): 17705-17710.
11. Gressner O, Schilling T, Lorenz K, Schulze-Schleithoff E, Koch A, Schulze-Bergkamen H, Lena AM, Candi E, Terrinoni A, Catani MV, Oren M, Melino G, Krammer PH, Stremmel W, and Muller M. TAp63 $\alpha$  induces apoptosis by activating signaling via death receptors and mitochondria. *EMBO J* 2005; 24: 2458-2471.
12. Mundt HM, Stremmel W, Melino G, Krammer PH, Schilling T, and Muller M. Dominant negative  $\Delta$ Np63 $\alpha$  induces drug resistance in hepatocellular carcinoma by interference with apoptosis signaling pathways. *Biochem Biophys Res Commun* 2010; 369: 335-341.
13. Park, B. J., Lee SJ, Kim JI, Lee SJ, Lee CH, Chang SG, Park JH, Chi SG. Frequent alterations of p63 expression in human primary bladder carcinomas. *Cancer Res*. 2000; 60: 3370-3374.
14. Koga, F., Kawakami S, Kumagai J, Takizawa T, Ando N, Arai G, Kageyama Y, Kihara K. Impaired TNp63 expression characterizes aggressive phenotypes of urothelial neoplasms. *Br J Cancer* 2003; 88: 740-747.
15. Hibi, K., Trink, B., Patturajan, M, Westra WH, Caballero OL, Hill DE, Ratovitski EA, Jen J, Sidransky D. AIS are an oncogene amplified in squamous cell carcinoma. *Proc Natl Acad Sci*. 2000; 97: 5462-5467.
16. Nekulova M, Holcakova J, Coates P, Vojtesek B. The role of p63 in cancer, stem cells and cancer stem cells. *Cell Mol Biol Lett*. 2011; 16:296-327.
17. Lopez-Beltran A, Sauter G, Gasser T, Hartmann A, Schmitz-Drager BJ, Helpap B, Ayala AG, Tamboli P, Knowles MA, Sidransky D, Cordon-Cardo C, Jones PA, Cairns P, Simon R, Amin MB, Tyczynski JE. Infiltrating urothelial carcinoma: In World Health Organization classification of tumors. *Pathology and Genetics of tumors of the urinary system and male genital organs*. Lyon, IARCC Press. 2004; PP: 91-94.
18. Edge SB, Byrd DR, Compton CC, Fritz AG, Greene FL, and Trotti A. *AJCC cancer staging manual (7<sup>th</sup>ed)*. New York, NY: Springer 2010.
19. Chan WY, Cheung KK, Schorge JO, Huang LW, Welch WR, Bell DA, Berkowitz RS, Mok SC. Bcl-2 and p53 protein expression, apoptosis, and p53 mutation in human epithelial ovarian cancers. *Am J Pathol*. 2000; 156:409-417.
20. Melino G. P63 is a suppressor of tumorigenesis and metastasis interacting with mutant P53. *Cell Death Differ*. 2011; 18 (9): 1487-1499.

21. Craig AL, Holcakova J, Finlan LE, Nekulova M, Hrstka R, Gueven N, Di Renzo J, Smith G, Hupp TR, and Vojtesek B. Delta Np63 transcriptionally regulates ATM to control p53 serin-15-phosphorylation. *Mol Cancer* 2010; 9: 195.
22. Stefanou D, Batistatu A, Nonni A, Arkoumani E, Agnantis NJ. P63 expression in benign and malignant breast lesions. *Histol Histopathol* 2004; 19(2): 465-471.
23. Wang X, Mori I, Tang W, Nakamura M, Nakamura Y, Sato M, Sakurai T, and Kakudo K. P63 expression in normal, hyperplastic and malignant breast tissues. *Breast Cancer* 2002; 9(3): 216-219.
24. Haqq C, Nosrati M, Sudilovsky D, Crothers J, Khodabakhsh D, Pulliam BL, Federman S, Miller JR 3<sup>rd</sup>, Allen RE, Singer MI, Leong SP, Ljung BM, Saqebiel RW, Kashani-Sabet M. The gene expression signatures of melanoma progression. *Proc Natl AcadSci USA* 2005; 102(7): 6092-6097.
25. Pellegrini G, Dellambra E, Golisano O, Martinelli E, Fantozzi I, Bondanza S, Ponzin D, McKeon F and DeLuca M. P63 identifies keratinocytes stem cells. *Proc Natl AcadSci USA* 2001; 98: 3156-3161.
26. Stepan A, Margaritescu CL, Simionescu C, Ciurea R. E-cadherin and P63 immunoexpression in dysplastic lesions and urothelial carcinoma of the bladder. *Romanian J of Morphology and Embryology* 2009; 50 (3): 461-465.
27. Barbieri CE, Tang LJ, Brown KA, and Pietenpol JA. Loss of p63 leads to increased cell migration and upregulation of genes involved in invasion and metastasis. *Cancer Res* 2006; (66): 7589-7597.
28. Su X, Chakravarti D, Cho MS, Liu L, Gi YJ, Lin YL, Leung ML, El-Naggar A, Creighton CJ, Suraokar MB, Wistuba I and Flores ER. TAp63 suppresses metastasis through coordinate regulation of Dicer and mi RNAs. *Nature* 2010; 467: 986-990.
29. Raheem SA, Saied AN, Al Shaer R, Mustafa O, Ali AH. The role of CK20, P53 and P63 in differentiation of some urothelial lesions of urinary bladder, immunohistochemical study. *Open Journal Of Pathology* 2014; 4: 181-193.
30. Koyuncuer A. Immunohistochemical expression of P63 and P53 in urinary bladder carcinoma. *Indian J Pathology & Microbiology* 2013; 56 (1): 10-15.
31. Urist MJ, Di Como CJ, Lu ML, Charytonowicz E, Verbel D, Crum CP, Ince TA, McKeon FD, Cordon-Cardo C. Loss of P63 expression is associated with tumor progression in bladder cancer. *Am J Pathol* 2002; 16 (4): 1199-1206.
32. Koga F, Kawakami S, Fuji Y, Sato K, Ohtsuka Y, Iwai A, Ando N, Takizawa T, Kaqeyama Y, Kihara K. Impaired p63 expression associated with poor prognosis and Uroplakin III expression in invasive urothelial carcinoma of the bladder. *Clin Cancer Res* 2003; 9(15): 5501-5507.
33. Choi W, Shah JB, Tran M, Svatek R, Marquis L, Lee L, Yu D, Adam L, Wen S, Shen Y, Dinney C, McConkey DJ, Siefker-Radtke A. P63 expression defines lethal subsets of muscle-invasive bladder cancer. *Plosone* 2012; 7 (1): e30206.
34. Karni-Schmidt O, Castillo-Martin M, Hvai Shon T, Gladoun N, Domingo-Domenech J, Sanchez-Carbayo M, Li Y, Lowe S, Prives C, Cordon-Cardo C. Distinct expression profile of P63 variants during urothelial development and bladder cancer progression. *Am J Pathol* 2011; 178: 159-165.
35. Mursi K, Agag A, Hammam O, Riad A and Daw M. The expression of p63 in bladder cancer vs chronic bilharzial bladder. *Arab J Urol* 2013; 11(1): 106-112.

6/29/2016