

The biochemical and histopathological effects of four plants (*Acanthus montanus*, *Euphorbia hirta*, *Vernonia amygdalina* and *Ocimum gratissimum*) leaf extracts on the liver and kidney of Wistar rats

Ogbuleka, N.A.C., Mbakwem-Aniebo, C. and Frank-Peterside N.

Department of Microbiology, University of Port-Harcourt, Port Harcourt, Nigeria

E-Mail: chiakaniebo@yahoo.com, Tel: +2348033066296, +2348036753329

Abstract: Toxicity, biochemical and histopathological evaluation of the leaf extracts on wistar rats was carried out using four plant leaf extracts. The leaf extracts were from *Acanthus montanus*, *Euphorbia hirta*, *Vernonia amygdalina* and *Ocimum gratissimum* plants. Twenty-seven (27) wistar rats weighing between 180-250kg were used. The animals were divided into two groups of three rats per extract, group 1 received 250mg/kg and group 2 received 500mg/kg, the control group received sterile water (0.5ml/kg) only for 14 days. The alanineaminotransferase (ALT), aspartateaminotransferase (AST) and Gamma-glutamyltransferase (GGT) in all the extracts and groups were not statistically significant when compared with the control after the administration of the extracts except for Urea that were significant at $P < 0.05$ in Extract A [group 2 (3.9 ± 0), Extract B group 2 (5.2 ± 0)] and Creatinine were also significant at $P < 0.05$ in Extract B [group 1 and 2 (22 ± 8.4 and 178 ± 0)]. The histological and biochemical results revealed that there are no histological differences in the experimental groups when compared with the control group. From the results, it can be deduced that the leaf extracts caused no noticeable effect on the kidney and liver of the rats evaluated compared to the control. Consequently, these plant leaf extracts possessed high index of safety and the continual use are advocated among the rural and urban population. In summary, extracts of the four plants leaf used in this study has a high margin of safety.

[Ogbuleka, N.A.C., Mbakwem-Aniebo, C. and Frank-Peterside N. **The biochemical and histopathological effects of four plants (*Acanthus montanus*, *Euphorbia hirta*, *Vernonia amygdalina* and *Ocimum gratissimum*) leaf extracts on the kidney and liver of Wistar rats.** *Cancer Biology* 2016;6(1):60-67]. ISSN: 2150-1041 (print); ISSN: 2150-105X (online). <http://www.cancerbio.net>. 11. doi:[10.7537/marscbj06011611](https://doi.org/10.7537/marscbj06011611).

Keywords: *Acanthus montanus*, *Euphorbia hirta*, *Vernonia amygdalina*, *Ocimum gratissimum*, Kidney, Liver, Wistar rats

1. Introduction

Herbal nutraceuticals and pharmaceuticals are becoming increasingly in acceptance worldwide (Ezekwesili et al., 2011). Plants, as gift of nature are the ancient form of health-care and has been known and used by mankind throughout history. Plants are generally important to man as they serve great functions as foods, clothes and medicines to sustain life. Plants that are generally effective in the inhibition or control of micro-organisms are mainly used in the traditional medicines and are likely to yield pharmaceutical active compounds (Hotettman et al., 1996, Ali-Shayeh and Abu-Ghideib, 1999). Plants as gift of nature have many therapeutic properties combined with much nutritive value which have made their use in chemotherapy as valuable as the conventional drugs. These has also encouraged many researchers looking out to an alternative to conventional drugs that is generally acceptable, safe, affordable, accessible and degradable to the environment (Obute, 2005, Ikeyi and Omeh, 2014).

The presence of several chemicals of pharmacological relevance in various parts of plants makes them important in the production of drugs as several drugs have been developed from them. The leaf extracts of four different plants were considered

in this investigation namely *Acanthus montanus* (False thistle or mountain thistle plant), *Euphorbia hirta* (Asthma weed, garden spurge), *Vernonia amygdalina* (Bitter leaf plant) and *Ocimum gratissimum* (Scent leaf plant). The decoctions of the *Acanthus montanus* leaf are used as tea; for the treatment of hypertension, cardiovascular disease or cardiac dysfunctions (Obute, 2005). The leaf of *Euphorbia hirta* are used for the treatment of asthma, cartah; its external application on eczema infestation is a cure for eczema, also speculated to be a cure for Aids since it stimulates the immune system (Obute, 2005, Ikeyi and Omeh, 2014). The leaf of *Vernonia amygdalina* are also taken in Nigeria as an appetizer and digestive tonic and in Ethiopia as "tela" beer (Lobo et al., 2009). The leaf are also used widely for fevers and are known as quinine-substitute (Obute, 2005). *Ocimum gratissimum* popularly called scent leaf, has been extensively used for medicinal condiments and cultural purposes (Lobo et al., 2009).

Though, plant leaf are exploited for treatment of infections and diseases. Nevertheless, the harmful effects of most leaf extracts on the useful body organs cannot be completely ruled out bearing in mind that such mixtures are given by the herbal practitioners without concerns to regulation and safety

specifications (Ezekwesili et al., 2011). These traditional medications, though natural, can be a reason for some grave harmful effects on the essential body organs owing to insufficiency in safety guides and standardization (Ezekwesili et al., 2011). Therapeutical use of traditional mixtures are predominant in many countries across the globe (Venukumar and Latha, 2002; Malaya et al., 2004; Ezekwesili et al., 2011). Thus, the aim of this present is to evaluate the toxicity, biochemical and histopathological effects of four plants (*Acanthus montanus*, *Euphorbia hirta*, *Vernonia amygdalina* and *Ocimum gratissimum*) leaf extracts on the liver and kidney of wistar rats.

2. Materials And Methods

2.1. Plant Material: The four plants namely *Acanthus montanus* (False thistle or mountain thistle plant), *Euphorbia hirta* (Asthma weed, garden spurge), *Vernonia amygdalina* (Bitter leaf plant) and *Ocimum gratissimum* (Scent leaf plant) were collected in 2014 from Port Harcourt in Rivers State. The leaf were dried and pulverized. The powdery material was extracted in 95% methanol. It was decanted, filtered and concentrated. The extract obtained was reconstituted with water to give the required dosage of 250 and 500mg/kg body weight.

2.2. Animal Care: Twenty-seven adult Wistar rats weighing between 180 and 250kg were obtained from the animal house of Nnamdi Azikiwe University, Nnewi Campus, Anambra State. The animals were housed in the Department of Medical Laboratory Science, Niger Delta University, Wilberforce Island, Bayelsa State. All animals were acclimatized for 5 days, allowed free access to commercially purchased grower's feed and water *ad libitum*. All animals were gently and calmly handled according to ethical specifications (NIH Publication, 1985).

2.3. Experimental Design for an in vivo study: The animals were divided into two groups of three rats each per extract and were administered with the aid of orogastric tube once per day for 14days as follows: for *Extract A (Acanthus montanus)*, *Group 1*: Received 250mg/kg of *Acanthus montanus* extract and *Group 2*: Received 500mg/kg of *Acanthus montanus* extract. For *Extract B (Euphorbia hirta)*, *Group 1*: Received 250mg/kg of *Euphorbia hirta* extract and *Group 2*: Received 500mg/kg of *Euphorbia hirta* extract. For *Extract C (Vernonia amygdalina)*, *Group 1*: Received 250mg/kg of *Vernonia amygdalina* extract and *Group 2*: Received 500mg/kg of *Vernonia amygdalina* extract. For *Extract D (Ocimum gratissimum)*, *Group 1*: Received 250mg/kg of *Ocimum gratissimum* extract and *Group 2*: Received 500mg/kg of *Ocimum gratissimum* extract. While *Controls*: Received water.

2.4. Histopathology analysis: The rats were dissected 24 hours after the last dose, blood samples were obtained from the rats. The livers and kidneys were removed, fixed in 10% formal saline, dehydrated in ascending grades of alcohol, impregnated and embedded in paraffin wax. Paraffin sections (5 μ m thick) were stained with haematoxylin and eosin (H&E) method for general histological examination. Slides were viewed under a light microscope and digital photomicrographs were taken.

2.5. Biochemistry analysis: Blood samples obtained from the rats were kept at room temperature to obtain serum. Serum urea and creatinine, alanineaminotransferase (ALT), aspartateaminotransferase (AST) and Gamma-glutamyltransferase (GGT) were determined following standard methods.

2.6. Statistical analysis: Data were analysed using one-way analysis of variance (ANOVA) and group means were compared using the Tukey-kramer Multiple Comparison Test using graph pad Prism® software version 5.01. P values of <0.05 were considered statistically significant.

3. Results

3.1. Biochemical analysis

Table 1 shows the biochemical effects of four plant (*Acanthus montanus*, *Euphorbia hirta*, *Vernonia amygdalina* and *Ocimum gratissimum*) leaf extracts on the kidney and liver of wistar rats. Results showed no significant increase or difference observed in the body weight of wistar rat fed with aqueous plant leaf extract of the four plants used at the various concentrations of 250mg/kg and 500mg/kg (Table 1). The alanineaminotransferase (ALT), aspartateaminotransferase (AST) and Gamma-glutamyltransferase (GGT) in all the extracts and groups were not statistically significant when compared with their control, but Urea were significant at $p \leq 0.05$ in Extract A [group 2 (3.9 \pm 0*)], Extract B group 2 (5.2 \pm 0*) and creatinine were significant at $p \leq 0.05$ in Extract B [group 1 and 2 (22 \pm 8.4* and 178 \pm 0***)] as shown in Table 1.

3.2. Histopathological analysis

The Liver control showed a normal central vein with well radiating hepatocyte and sinusoid. The Kidney control also showed normal tubules, renal corpuscle formed by the Glomerulus with well circumscribed Bowman's capsule. Figure 1a-c shows the histopathological analysis of four plant (*Acanthus montanus*, *Euphorbia hirta*, *Vernonia amygdalina* and *Ocimum gratissimum*) leaf extracts on the kidney and liver of wistar rats. Results showed no histological differences in the experimental groups (Slides 3-18) when compared with the control group (Slide 1and 2).

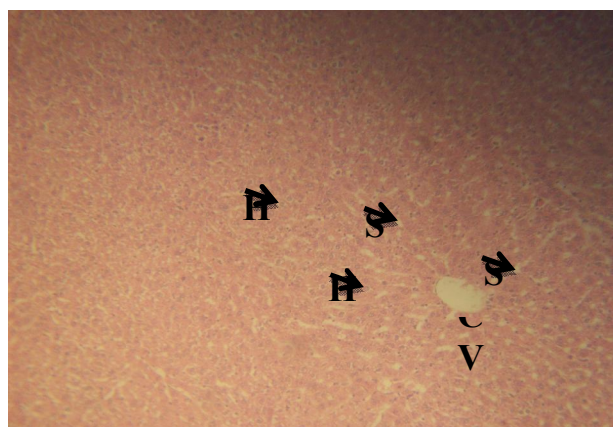
Except that the tissue architecture of slide 6 is slightly distorted as the glomerulus and other features are

clouded (Figure 1a-d).

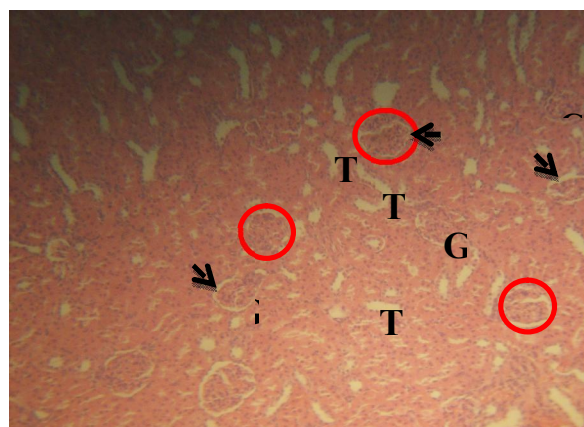
Table 1: Biochemical effects of four plant (*Acanthus montanus*, *Euphorbia hirta*, *Vernonia amygdalina* and *Ocimum gratissimum*) leaf extracts on the kidney and liver of wistar rats.

Parameter	Control	Extract A		Extract B		Extract C		Extract D	
		Group 1	Group 2	Group 1	Group 2	Group 1	Group 2	Group 1	Group 2
ALT	145.7±31.50	132±5.66	151±0	117±4.24	121±0	90±5.65	149±38.89	120.3±39.31	100.5±16.2
AST	223.3±63.81	161.5±2.12	205±0	173.5±17.68	167±0	300±28.28	234.5±2.12	247±157.5	155±7.07
GGT	13.67±5.5	22.5±10.61	5±0	18.50±10.61	15±0	8.5±2.1	27±8.48	20.5±4.95	10±1.41
Urea	2.5±0.45	2.85±0.07	3.9±0*	2.6±0.56	5.2±0*	3.9±0.98	3.9±1.69	3.167±0.40	2.7±0.28
Creatinine	49±7.0	61±69.30	23±0	22±8.4*	178±0***	115±23.35	36.50±6.36	44.33±11.59	37±31.11

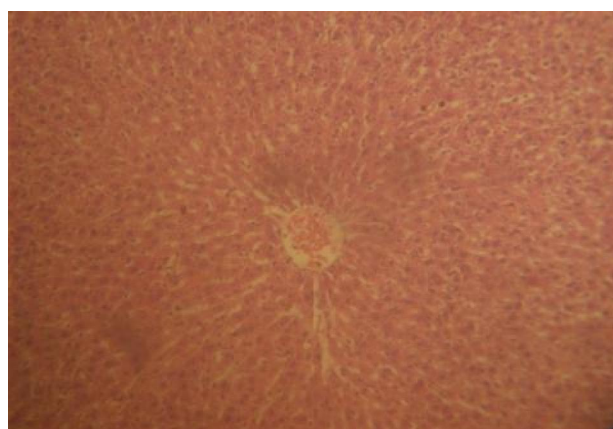
Keys: Values were presented as the mean ± standard deviation. * = Statistically different at $p \leq 0.05$, ** = Statistically different at $p \leq 0.01$, *** = Statistically different at $p \leq 0.0001$.



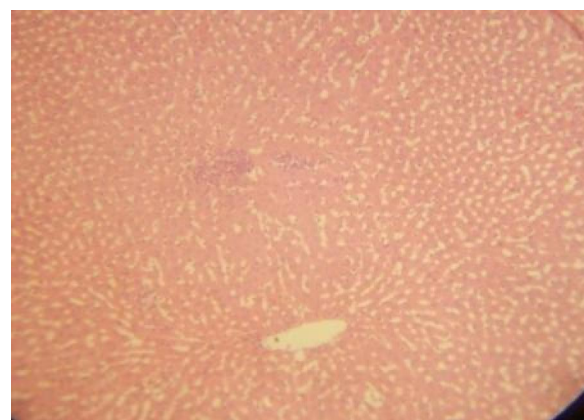
Slide 1(Control): Histology of normal Liver



Slide 2(Control): Histology of normal Kidney



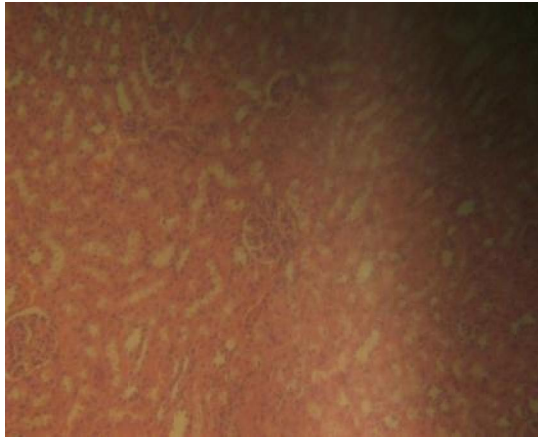
Slide 3: Histology of Liver for Ext. A group 1



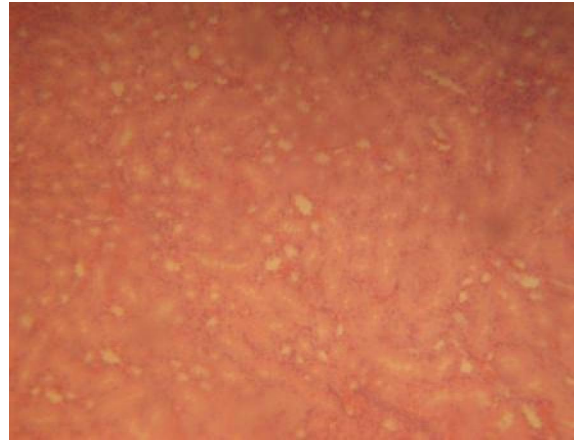
Slide 4: Histology of Kidney for Ext. A group 1

Figure 1a: Histological Appearances

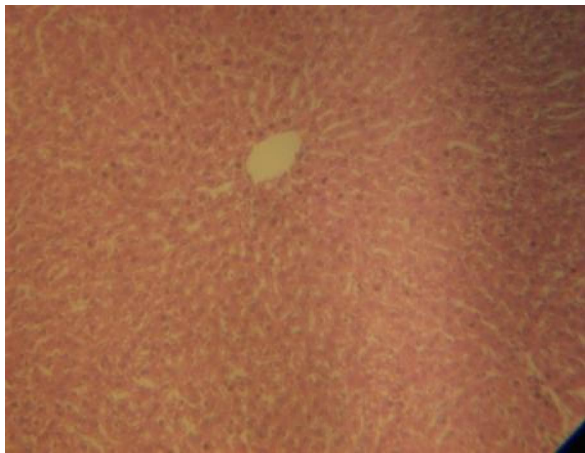Micrographs of Liver and Kidney: Slide 1 (Liver control) with normal Central Vein (CV) with well radiating Hepatocyte (H) and Sinusoid (S). Slide 2 (Kidney control) with normal Tubules (T), Renal corpuscle (Red circle) formed by the Glomerulus (G) with well circumscribed Bowman's capsule (Dash arrow)



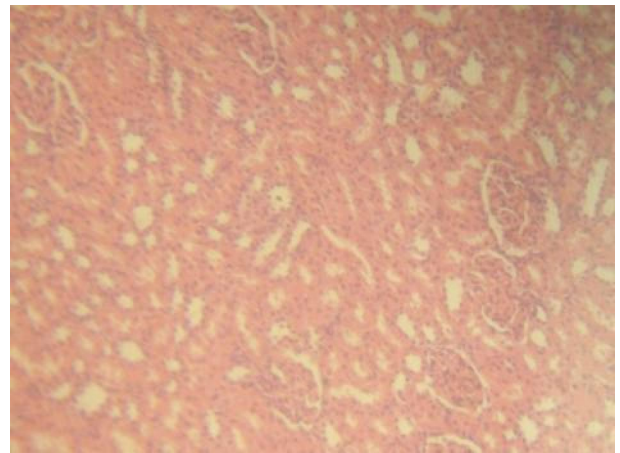
Slide 5: Histology of Liver for Ext. A group 2



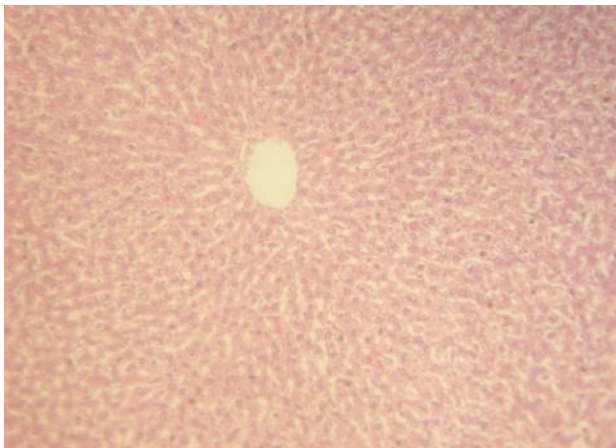
Slide 6: Histology of Kidney for Ext. A group 2



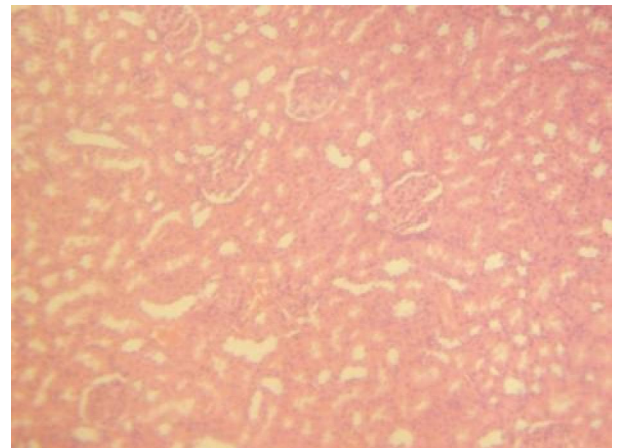
Slide 7: Histology of Liver for Ext. B group 1



Slide 8: Histology of Kidney for Ext. B group 1



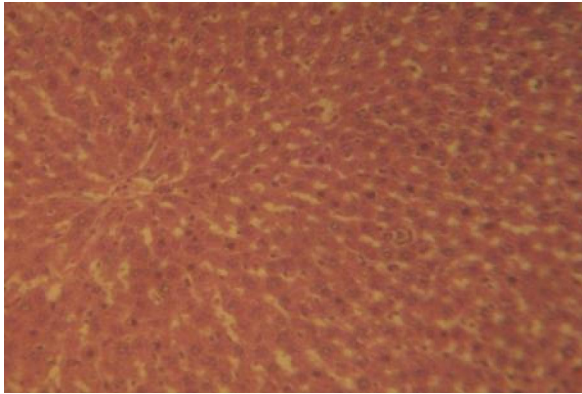
Slide 9: Histology of Liver for Ext. B group 2



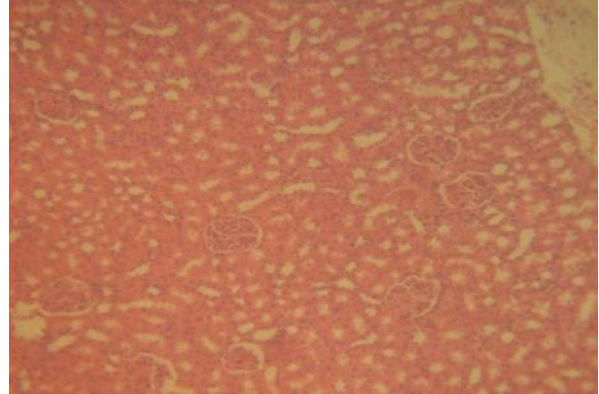
Slide 10: Histology of Kidney for Ext. B group 2

Figure 1b: Histological Appearances Cont'd.

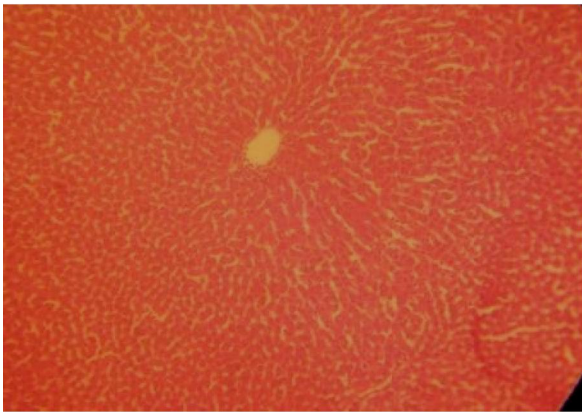
Micrographs of Liver and Kidney: Slide 1 (Liver control) with normal Central Vein (CV) with well radiating Hepatocyte (H) and Sinusoid (S). Slide 2 (Kidney control) with normal Tubules (T), Renal corpuscle (Red circle) formed by the Glomerulus (G) with well circumscribed Bowman's capsule (Dash arrow).



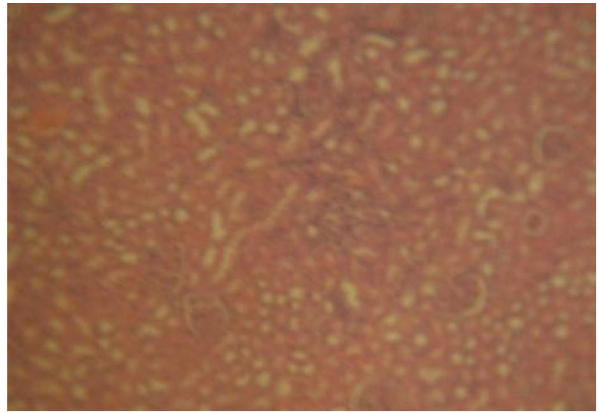
Slide 11: Histology of Liver for Ext. C group 1



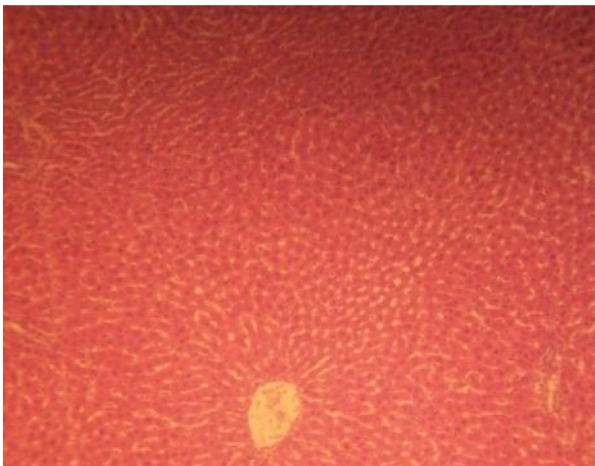
Slide 12: Histology of Kidney for Ext. C group 1



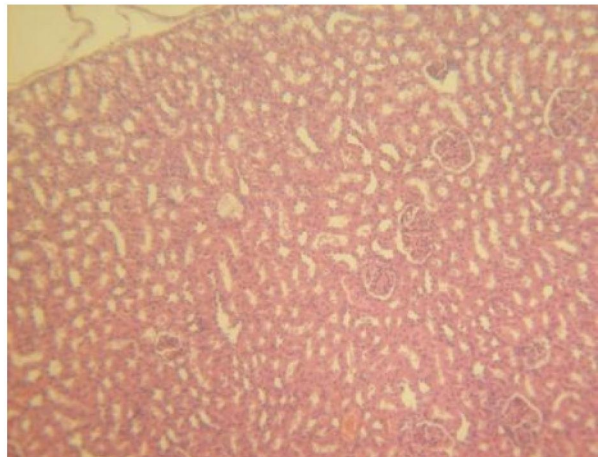
Slide 13: Histology of Liver for Ext. C group 2



Slide 14: Histology of Kidney for Ext. C group 2



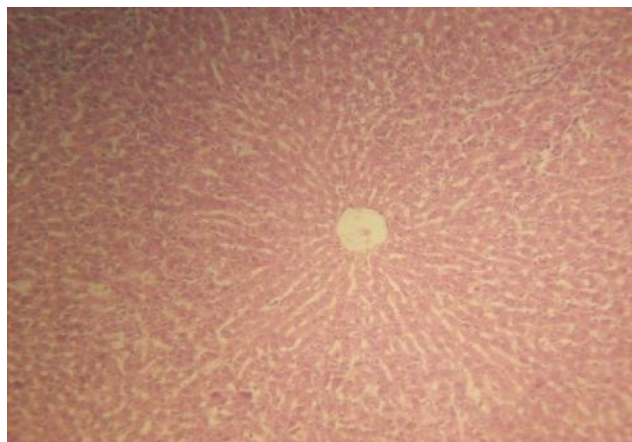Slide 15: Histology of Liver for Ext. D group 1



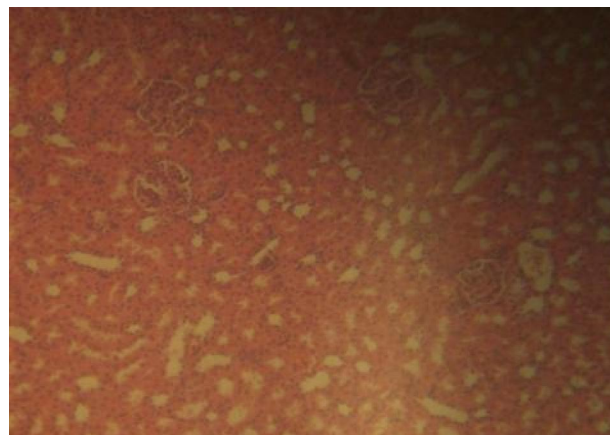
Slide 16: Histology of Kidney for Ext. D group 1

Figure 1c: Histological Appearances Cont'd.

Micrographs of Liver and Kidney: Slide 1 (Liver control) with normal Central Vein (CV) with well radiating Hepatocyte (H) and Sinusoid (S). Slide 2 (Kidney control) with normal Tubules (T), Renal corpuscle (Red circle) formed by the Glomerulus (G) with well circumscribed Bowman's capsule (Dash arrow)



Slide 17: Histology of Liver for Ext. D group 2



Slide 18: Histology of Kidney for Ext. D group 2

Figure 1d: Histological Appearances Cont'd.

Micrographs of Liver and Kidney: Slide 1 (Liver control) with normal Central Vein (CV) with well radiating Hepatocyte (H) and Sinusoid (S). Slide 2 (Kidney control) with normal Tubules (T), Renal corpuscle (Red circle) formed by the Glomerulus (G) with well circumscribed Bowman's capsule (Dash arrow)

4. Discussions

The present study assessed the toxicity, biochemical and histopathological effects of four plant (*Acanthus montanus*, *Euphorbia hirta*, *Vernonia amygdalina* and *Ocimum gratissimum*) leaf extracts on the liver and kidney of wistar rats. Hepatotoxicity of these extracts might be a direct result of the extracts or due to the change of some phytochemicals present in the extracts to poisonous metabolites by the drug breaking down mixed function oxidase system of the liver (Ezekwesili et al., 2011). Acute toxicity studies were intended to decide the dosage that lead to either severe toxicological effects or mortality or higher level of safety when administered once or more (Ezeonwumelu et al., 2011). Acute toxicity studies also help to offer data concerning dosages that would be employed in chronic or sub-chronic studies (Ezeonwumelu et al., 2011).

In this study, there was no death seen throughout the studies duration therefore presenting high protection and safety index of these plant leaf extracts in both the experimental rats and the controls (Ezeonwumelu et al., 2011). Subsequent to the fact that no rat died in this study and no general signs of toxicity seen after 72 h such as mucous production on the eye, respiratory, gastrointestinal, central nervous, peripheral and circulatory system and changes of the skin, these extracts could be seen as being practically safe (Ezeonwumelu et al., 2011).

In this study, results showed no histological differences in the experimental groups (Slides 3-18) when compared with the control group (Slide 1 and 2), except for the tissue architecture of slide 6 which is

slightly distorted as the glomerulus and other features are clouded (Figure 1a-c). No histological changes such as marked tubular necrosis and glomerular degeneration was observed in the kidney section of rats treated with these extracts (Ezekwesili et al., 2011). These histological changes usually follow treatments with herbal preparations. *Securidaca longepedunculata* has been found to elicit tubular necrosis with diffused interstitial and glomerular haemorrhage (Dapar et al., 2007; Ezekwesili et al., 2011), while oral administration of *Ocimum gratissimum* leaf extract caused renal tubular degeneration in rabbits (Effraim et al., 2001; Ezekwesili et al., 2011). However, none was observed in this present study.

According to Ezeonwumelu et al. (2011), alanine amino transferase (ALT) and aspartate amino transferase (AST) are the two most vital transaminases which predominates the muscles, liver and myocardium in high concentrations. ALT is more predominant in the liver compared to AST which is most predominant in the myocardium (Ezeonwumelu et al., 2011). Also, ALT is a fundamental pointer of liver and liver-related diseases and an early indicator in alcoholic hepatitis compared to the gamma glutamyl transpeptidase (GGT) enzyme which catalyzes the transfer of the gamma-glutamyl remains of glutathione to other substrates (Calbreath, 1992; Ezeonwumelu et al., 2011). Assay for liver enzymes namely AST, ALT, GGT and ALP is significant in evaluating best liver function in the course of diabetes (Iweala et al., 2013). Rise in the plasma level of liver enzymes is a sign of liver disease or dysfunction

(Dame, 1981; Iweala et al., 2013). This will affect the pattern of use of medicinal plant concoction by diabetic patients (Egede et al., 2002; Iweala et al., 2013).

In this study, there was no significant biochemical increase or difference in the observed body weight of wistar rat fed with aqueous plant leaf extract of the four plants used at the various concentrations. According to Duke (1997) and Ezeonwumelu et al. (2011), any increase in body weight of the rats used in this study could be as a result of the nutritive components in the plants used.

Also in this study, the alanineaminotransferase (ALT), aspartateaminotransferase (AST) and Gamma-glutamyltransferase (GGT) in all the extracts and groups were not statistically significant when compared with their control, but urea were significant at $P < 0.05$ in Extract A [group 2 ($3.9 \pm 0^*$), Extract B group 2 ($5.2 \pm 0^*$)] and creatinine were significant at $P < 0.05$ in Extract B [group 1 and 2 ($22 \pm 8.4^*$ and $178 \pm 0^{***}$)]. This finding is in agreement with the reports of Orlu and Obulor (2014) in the investigation on the effect of aqueous leaf extract of *Acanthus montanus* on spermatogenesis in Swiss, Avwioro et al. (2014) on the effects of the mixture of Garcima kola and honey on wistar rats and Akomas et al. (2015) on the effect of *Euphorbia hirta* on haematological and biochemical indices in Albino rats where no histological differences in the administration of these plants were reported.

However, the findings of this study deviates from what was reported by other authors. Ildigwe et al. (2010) had reported a rise in the serum level of liver enzymes particularly the ALT and AST in the course of a 90 days of the studies using ethanolic leaf extract of *Spathodea campanulata*. Ezeonwumelu et al. (2011) in a similar study reported an elevated levels of ALT, AST and GGT using aqueous extract of *Bidens pilosa* leaf. According to Ezeonwumelu et al. (2011), the elevated serum level of AST is an evidence of short-term use of *Bidens pilosa* leaf extract which can result to heart and liver diseases. Nevertheless, it has remained a fact that *Bidens pilosa* leaf extract is hepatoprotective (Chin et al., 1996; Li-Ping et al., 2008; Suzigan et al., 2009; Ezeonwumelu et al., 2011) signifying that its short-term use might pose a threat to the body which might resolve post-treatment (Ezeonwumelu et al., 2011).

The findings of this study confirmed the reports of Huxley (1998), Ibe et al. (2005), Obute (2005), Oluwayemi et al. (2012) and Ikeyi and Omeh (2014) on the importance and usefulness of these plants to humans and animals. However, there should be restriction on the dosage to be given as this experiment revealed their effect based on dose related per body weight. It was revealed that extracts A and B

are not good for the kidney base on the dosage given as the urea and creatinine were affected which indicates damage to the kidney but extracts C and D are good for the kidney and liver base on the result of the experiment there were no significant difference from the control.

From the results, it can be deduced that the leaf extracts caused no noticeable effect on the kidney and liver of the rats evaluated compared to the control. Consequently, these plant leaf extracts possessed high index of safety and the continual use are advocated among the rural and urban population. In summary, extracts of the four plants leaf used in this study has a high margin of safety.

References

1. Akomas, S.C., Ijioma S.N. and Emelike, C.U. (2015), Effect of *Euphorbia hirta* on Haematological and Biochemical indices in Albino rats. *Applied Journal of hygiene* 4(1): 01-05, 2015 ISSN 2309-8710.
2. Ali-Shayeh, M.S. and Abu-Ghideib, S.I. (1999). Antifungal activity of plant extracts against Dermatophytes. *Mycoses* 42: 665-672.
3. Avwioro, O.G., Ogunbayo, T.J., Ekhueorhan, A., Onyije, F.M., Adedeji T.M. (2014). The effects of the mixture of Garcima kola and honey on wistar rats. *African journal of cellular pathology*. 3:39-43.
4. Calbreath, D.F.M, 1992. Clinical Chemistry. Philadelphia W.B Saunders Company, pp: 468.
5. Chin, H., C. Lin and K. Tang, 1996. The hepatoprotective effects of Taiwan folk medicine ham-hong-chho in rats, *American J. Chinese Med.*, 24(3-4): 231-240.
6. Dame SS (1981). Drug and the liver: Diseases of the liver and the biliary system. *Drugs* 6: 295-317.
7. Dapar, L. P., Aguiyi, C. J., Wannang, N. N., Gyang, S. S., Tanko, M. N. (2007). The histopathologic effects of *Securidaca longepedunculata* on heart, liver kidney and lungs of rats. *African Journal of Biotechnology*, 6(5): 591–595.
8. Duke, J.A., 1997. The Green Pharmacy: New Discoveries in Herbal Remedies for Common Diseases and Conditions from the World's Foremost Authorities on Healing Herbs. Rodale, Retrieved from: www.greenpharmacy.com.
9. Effraim, K. D., Jacks, T. W., Sodipo, O. A. (2001). Histopathological studies on the toxicity of *Ocimum gratissimum* leave extract on some organs of rabbits. *African Journal of Biomedical Research*, 6: 21 – 25.
10. Egede LE, Ye X, Zheng D, Silverstein MD (2002). The prevalence and pattern of

- complementary and alternative medicine use in individuals with diabetes. *Diabetes Care*. 25: 324-329.
11. Ezekwesili, Chinwe Nonyelum, Obidoa, Onyechi, Nwodo, Okwesili Fred Chiletugo, Ezekwesili-Ofli, Josephine Ozioma. 2011. Toxicity of *Acalypha Torta* (Muell) Leaf Ethanolic Extract in Mice and Rat. *Animal Research International*, 8(1): 1315 – 1322.
 12. Ezeonwumelu J.O.C., A.K. Julius, C.N. Muhoho, A.M. Ajayi, A.A. Oyewale, J.K. Tanayen, S.O. Balogun, A. Ibrahim, B. Adzu, C.P. Adiukwu, J. Oloro, D.M. Kiplagat, A.D.T. Goji, A.G. Okoruwa, A.N. Onchweri and P.M.K. Reddy. 2011. Biochemical and Histological Studies of Aqueous Extract of *Bidens pilosa* Leaf from Ugandan Rift Valley in Rats. *British Journal of Pharmacology and Toxicology* 2(6): 302-309.
 13. Hosttemenn, J.L., Wolfender, S., Rodriguez, S. and Marston .A. (1996). Strategy in the search for bioactive plant constituents in Chemistry, biological and phyarmalological properties of African medicinal plants Univ. of Zimbabwe pubt. Zimbabwe Pp 21 – 42:
 14. Huxley, A.J., *Acanthus montanus* plant description and geographical distribution [<http://w.w.w.doacs.state.fl.us/pi/enpp/98.mar-apr.htm>]webcite.
 15. Ibe, A.E., and Nwufu M. I.(2005), Identification , collection and domestication of Medicinal plants of SouthEastern Nigeria. *Journal of phytotherapy Res*.17(7):807-810.
 16. Ikeyi, P. A. and Omeh, N. Y. (2014) A review of the Ethnotherapeutics of Medicinal plants used in traditional/ alternative Medicinal practices Eastern Nigeria. *A Journal of circular microbial App Sci*, 3(1): 675-683.
 17. Ilodigwe, E., P. Akah and C. Nworu, 2010. Evaluation of the acute and subchronic toxicities of ethanol leaf extract of *Spathodea campanulata* P. Beauv. *Inter. J. Appl. Res. Natur. Prod.*, 3(2): 17-21.
 18. Iweala E. E. J., Uhegbu F. O. and Adesanoye O. A. 2013. Biochemical effects of leaf extracts of *Gongronema latifolium* and selenium supplementation in alloxan induced diabetic rats. *Journal of Pharmacognosy and Phytotherapy*, 5(5), pp. 91-97.
 19. Li-Ping, G., S. Xian-Yu, T. Guan-Rong, C. Kyu-Yun and Q. Zhe-Shan, 2008. The synthesis and anticonvulsant activity of 1-substituted-7-Methoxy-1, 2, 4-Triazolo [4,3-a] Quinoline. *Turkish J. Chem.*, 32(2): 181-189.
 20. Lobo, A. A., Prabhu, K.S., Shirwaikar, A. A. and Shirwaikar, A. (2009)Ocimum gratissimum: A Review of its Chemical, Pharmacological and Ethnomedicinal properties. *The open complementary Medicinal Journal*, vol 1, 1- 15.
 21. Malaya, G., Mazumder, U. K., Kumar, T. S., Gromathi, P., Humar, R. S. (2004). Antioxidant and hepatoprotective effect of *Buhinia racemosa* against paracetamol and carbon tetrachloride induced liver damage in rats. *Iranian Journal of Pharmacology and Therapeutics* 3: 12 –20.
 22. Obute, G.C., (2005) Ethnomedicinal plant Resources of SouthEastern Nigeria African. *Journal of Ethnol Leafstest* . 22(5)78-79.
 23. Oluwayemi, O.O.E, Funmilayo, A. E., Adebayo, I. O., Edewor, T., Ayoola, P.B., and Olufoolakemi., O. A., (2012) Preliminary studies on phytochemical and antimicrobial investigation of plants (irawo-ile) *Mitracarpus villosus*, *Euphorbia hirta* and *Spermacoce ocymoides*. *Journal of phytochemical and antimicrobial investigation of plants* www.arpapress.com/volumes/vol10Issue1/IJRR-AS-10-1-10pdf.
 24. Orlu, E.E., Obulor, A. (2014). Investigation on the effect of aqueous Leaf extract of *Acanthus montanus* on spermatogenesis in Swiss. *Journal of Pharmacy and Biological Sciences (IOSR-JPBS)*, 9(3):44-49.
 25. Suzigan, M., A. Battochio, K. Coelho and C. Coelho, 2009. An aqueous extract of *Bidens pilosa* L. protects liver from cholestatic disease experimental study in young rats. *Acta Cirúrgica Brasileira*, 24(5): 347-352.
 26. Venukumar, M. R., Latha, M. S. (2002). Hepatoprotective effect of metabolic extract of *Cuculigo ordchioides* in CCl4 –treated male rats. *Indian Journal of Pharmacology*, 34: 269 – 275.