

## Results and outcomes of concurrent chemo-irradiation followed by surgery for locally advanced cervical carcinoma

Ahmad M. Alhosainy<sup>1</sup>, Nabila Hefzi<sup>1</sup>, Hussein M. Abdeldayem<sup>2</sup>, Esam M. Hemat<sup>3</sup>

<sup>1</sup>Clinical Oncology & Nuclear Medicine, <sup>2</sup>Gynecology & Obstetrics, and <sup>3</sup>Radiology Departments, Faculty of Medicine, Zagazig University, Egypt.  
[ahosainy40@yahoo.com](mailto:ahosainy40@yahoo.com)

**Abstract: Background:** In 1999, five randomized clinical trials of concurrent platinum-based chemoradiation showed an overall survival benefits in patients with stage IB2 to IVA disease. Consequently in the same year; a subsequent trial performed by the National Cancer Institute of Canada demonstrated no survival advantage for concurrent platinum-based chemoradiation in stage IB to IVA cervical cancer patients. So, **The aim of this study** was to evaluate the results and morbidities of concurrent chemoradiation followed by surgery in those locally advanced disease patients. **Patients and methods:** patients fulfilling the inclusion criteria were planned to receive concurrent chemoradiation in the form of whole pelvic external beam irradiation with delivery of 45 Gy to pelvic cavity concurrently with platinum, 40 mg /m<sup>2</sup> per week, followed by completion surgery 6-8 weeks post the end of chemoradiation. **Results:** fifty patients with a median age of 48 years (range, 41-67 years), were assessed at the time of surgery; 35 patients (70%) had histologic residual disease (RD) in the cervix. The sizes of the cervical RD were < 1 cm in 18 patients (51.4%) while 48.6% (17 patients) had a residual disease ≥ 1 cm. Postoperative complications were noted in 23 patients (46%). The factors increasing the risk of post-operative complications were radical hysterectomy compared with an extrafascial hysterectomy, odds ratio (OR)1, (OR)2-1 (1.7-4); P=0.04 and the presence of cervical RD>1 cm (OR2) (1.2-6.9), compared with no RD (P=0.011). **Conclusion:** In this study, the size of the residual disease (RD) and histologic nodal involvement were the strongest, statistically significant risk factors. These results confirm that the survival of patients treated with concurrent chemoradiation followed by surgery in locally advanced cervical carcinoma could potentially be enhanced by improving the rate of complete response in the irradiated area (cervix and pelvis) and by initially detecting patients with para-aortic spread. So that treatment could be adapted in such patients, as the completion of surgery increases the morbidities. [Ahmad M. Alhosainy, Nabila Hefzi, Hussein M. Abdeldayem, Esam M. Hemat. **Results and outcomes of concurrent chemo-irradiation followed by surgery for locally advanced cervical carcinoma.** *Cancer Biology* 2015;5(4):113-123]. (ISSN: 2150-1041). <http://www.cancerbio.net>. 14. doi:[10.7537/marscbj050415.14](https://doi.org/10.7537/marscbj050415.14).

**Keywords:** locally advanced cervical carcinoma, concurrent chemoradiation, surgery

### 1. Introduction

Cervical carcinoma is the most frequent cause of death from cancer in women from developing countries, and most of these cases are locally advanced at diagnosis.<sup>(1)</sup>

Radiation treatment has been the standard definitive therapy for patients with large cervical cancers confined to cervix and for patients with locally advanced cancers until the beginning of ninth decade. Loco-regional failure when treated with radiotherapy alone is significant: 25-30% for stage IIB and 30-40% for stage III-IVA. To improve the therapeutic ratio, chemotherapy was introduced in the treatment of cervical carcinoma, either as a single agent or in combination as neo-adjuvant, adjuvant, or concurrent protocols. In the setting of concurrent chemoradiotherapy the famous five trials were published with enthusiastic results, and subsequently in February 1999, U.S. National Cancer Institute (NCI) stated that, concurrent chemotherapy should be incorporated in women who require radiation therapy for treatment of cervical cancer.<sup>(2)</sup>

Radiation treatment did not undergo any major modifications until the recent addition of chemotherapy in a concomitant setting. Five randomized studies accruing almost 2000 patients have demonstrated the superiority of the arms with cisplatin-based chemotherapy during pelvic radiation<sup>(2-8)</sup>. Since then, concurrent chemoradiation became the accepted standard of care for cervical carcinoma. In 2005, the Cochrane database systemic review of concurrent chemoradiation in carcinoma of cervix also reiterated an absolute benefit of 10% in overall survival and 13% in progression free survival regardless of whether or not platinum was used<sup>(9)</sup>.

Studies have confirmed that the benefit of chemoradiation are not limited to surgically staged patients and that the patients with more advanced FIGO stage IIIB benefit the most<sup>(10)</sup>.

In the literature, very few data are available on the results of completion surgery in patients treated with chemoradiotherapy (CRT)<sup>(11-18)</sup>. Nevertheless, even if the therapeutic impact of completion hysterectomy continues to fuel debate, the analysis of

prognostic factors (mainly histologic factors) in hysterectomy and lymphadenectomy specimen could add interesting data in order to improve local and distant control for future patients undergoing CRT. Morbidities of completion surgery in this context were also studied.

## 2. Patients and Methods

Patients treated in Clinical Oncology & Nuclear Medicine, Gynecology & Obstetrics, and Radiology Departments, Faculty of Medicine, Zagazig University Hospitals, from January 2008 to July 2014 fulfilling the following inclusion criteria were included in the study: patients had to have a pathologic proof of cervical carcinoma of stage IB2-IVA (according to FIGO staging system), tumors had to be confined to the pelvic cavity, on initial abdominopelvic magnetic resonance imaging (MRI), after initial pelvic TV-US. Patients were treated with pelvic external radiation therapy delivering 45Gy to the pelvic cavity and concurrent chemotherapy (cisplatin 40 mg/m<sup>2</sup> weekly). Surgery was conventionally performed 6-8 weeks after completion of chemoradiation. Simple extrafascial hysterectomy was performed in patients who achieved a clinical and radiological complete response after chemoradiation. During this pelvic surgery, a selective lymphadenectomy was performed in patients with residual lymphadenopathy (pelvic or para aortic nodes) detected after chemoradiation, and for previously non irradiated para aortic nodes.

### Statistical Analysis:

Association between factors was assessed by Chi-square or Fisher's exact tests. Postoperative complications were extracted from medical charts up to 90 days following surgery. The rate of lymphedema was studied without a time limit. Morbidities were classified according to Dindo *et al.*<sup>(19)</sup>. To determine the independent prognostic significance of factors for survival, a multivariate analysis was conducted using the Cox proportional hazard regression method.

Variables attaining significance at a *P* value <0.05 in univariate analysis were retained for the multivariate analysis. Variables with a *P* value <0.05 in the multivariate analysis were considered significant prognostic factors for survival. The overall survival time was defined as the time between surgery and death from any cause or the last follow up for patients still alive. Event-free survival time was defined as the time between surgery and the first event (local or distant failure), or the last follow up for patients free from recurrence.

## 3. Results

All fifty patients completed the study. The median age was 48 years (range, 41-67 years). The distribution of disease stages was as follow:

Stage IB2, n = 8 (16%); stage II, n = 25 (50%); stage III, n = 12 (24%) and stage IV, n = 5 (10%). (Fig. 1 & 2) The distribution of histologic subtypes was as follow:

Squamous cell carcinoma, n = 40 (80%); adenocarcinoma, n = 6 (12%) and mixed subtype, n = 4 (8%).

At the pretherapeutic abdominopelvic MRI, 16 patients were found to have enlarged pelvic lymph nodes, (Fig. 3) and five patients had enlarged para-aortic nodes.

### Treatment Modalities

All patients received CRT in the form of pelvic external radiation therapy delivering 45Gy (1.8 Gy per fraction per day, 5 days per week) to the pelvic cavity and concurrent chemotherapy (cisplatin, 40mg/m<sup>2</sup> per week). The initial irradiation dose was delivered to the whole pelvis through four-field box technique using computerized 3-D planning system (Linac, Elekta 151204, Presice Plan Release 2.12) machine with high-energy photon beam (6 & 15 MV). The anterior fields extend from L4-5 interspace superiorly, to the midpubis or to a line 4 cm below the lowest vaginal disease inferiorly, and lateral borders are placed at least 1 cm lateral to the pelvic margins. While the lateral fields extend from the anterior tip of the pubis anteriorly and include S3 posteriorly.

Then, a boost dose 10Gy was given to the pre-treatment enlarged pelvic nodes and delivered through AP-PA ports with midline block, 4 cm in width. The enlarged para aortic nodes were included within the radiation field (extended field irradiation), the upper border is placed at L1-2 interspace or at a line 4-6 cm above the known disease.

Details of surgical treatment are shown in Table (1). All patients who treated laparoscopically, underwent an extrafascial hysterectomy. Histologic results at the time of completion surgery; thirty five (70%) patients had histologic residual disease (RD) in the cervix. Ten patients (20%) had RD <0.2cm, while 8 patients (16%) had a RD ranging from 0.2cm to <1cm, and 17 patients (34%) had RD ≥1cm (Fig. 4). Involvement of surgical margin was observed in 7 pathological specimens (14%).

### Complications

No major intra-operative morbidity (urinary, bowel, or vascular injuries) was observed. Twenty-three patients (46%) had postoperative complications as shown in Table (2). The factors increasing the risk for postoperative complications were radical

hysterectomy, compared with an extrafascial hysterectomy odds ratio 1, (OR), 2.1 (1.7-4);  $P=0.04$  and the presence of cervical RD < 1cm (OR, 3 (1.3-7.2)) or  $\geq 1$ cm (OR2 (1.2-6.9)), compared with no RD ( $P=0.01$ ) Table (3).

### Recurrence

The median follow up duration was 3.6 years (range, 0.4-6 years). Four patients were lost to follow

up post-operatively. During follow up, fourteen patients (28%) developed recurrence. The overall survival rates at 1 year and 5 years were 90% (95% confidence interval [CI], 85%-90%) and 70% (95% CI, 61%) respectively. The event-free survival rates at 1 year and 5 years were 80% (95% CI, 77%-89%) and 56% (95% CI, 57%-75%) respectively. Table (4)

**Table (1): Patient surgical and pathological characteristics**

Characteristic	N	%
<b>Pelvic surgery</b>		
Extrafascial hysterectomy	35	70
Radical hysterectomy	15	30
<b>Approach</b>		
Laparotomy	15	30
Laparoscopy	35	70
<b>Lymphadenectomy</b>		
None	2	4
Para aortic	39	78
Pelvic and para aortic	9	18
<b>Histological residual &amp; size in the cervix</b>		
No	15	30
$\leq 0.2$ cm	10	20
Millimetric(<2mm)		
10		
20		
Millimetric(<2mm)		
>0.2--<1cm	8	16
$\geq 1$ cm	17	34
<b>Location of extracervical residual disease</b>		
Vagina	10	20
Parametria	2	4
<b>Surgical margins in hysterectomy specimen</b>		
Free of disease	43	86
Positive margins	7	14
<b>Presence of histologically positive nodes</b>		
Pelvic nodes	9	18
Para-aortic nodes	6	12

**Table (2): Postoperative complications of grade  $\geq 2$**

Complication	N	%
Lymphedema	13	26
Ureteral fistula	7	14
Peritonitis	3	6

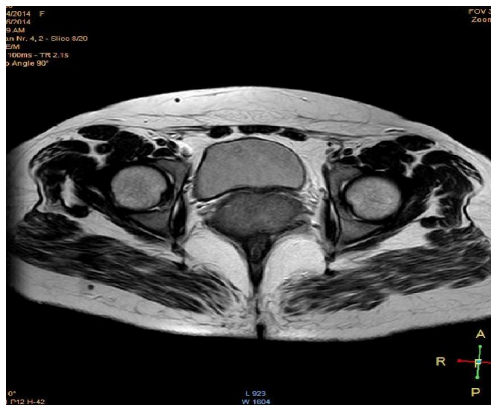
**Table (3): Risk factors for postoperative morbidity**

Variable	Univariate analysis OR (95% CI)	P-value	Multivariate analysis OR (95% CI)	P-value
Pelvic surgery				
Extrafascial hysterectomy	1	0.04	1	0.042
Radical hysterectomy	2.1 (1.7 - 4)		2.2 (1.3 - 4.2)	
Approach				
Laparotomy	1	0.52	-	-
Laparoscopy	0.6 (0.2 - 1.5)		-	-
Residual cervical disease				
None	1	0.01	1	0.02
< 1cm	3 (1.3 - 7.2)		3.2 (1.6 - 8.9)	
Millimetric(<2mm)				
10				
20				
Millimetric(<2mm)				
≥1cm	2 (1.2 - 6.9)		2.4 (1.1 - 5.8)	
Histological involved margins				
No	1	0.93	-	-
Yes	0.6 (0.1 - 2.3)		-	-
Pelvic lymphadenectomy				
No	1	0.06	1	0.45
Yes	1.9 (1 - 3.2)		1.4 (0.8 - 2.5)	
Para aortic lymphadenectomy				
No	1	0.34	1	0.44
Yes	2.1 (0.8 - 8.1)		2.4 (0.8 - 7.5)	
Pelvic lymph node				
-ve	1	0.04	1	0.22
+ve	3 (2.2 - 6.9)		2.3 (0.9 - 5.5)	
Para aortic lymph node				
-ve	1	0.05	1	0.32
+ve	2.2 (1.1 - 5.4)		1.7 (0.8 - 5.6)	

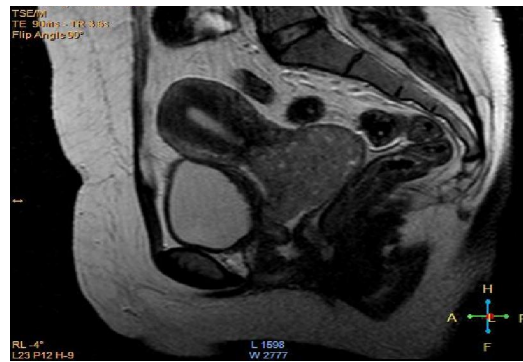
**Table (4): Prognostic factors for overall survival**

Characteristic	No.	5-ys %	Univariate analysis OR (95% CI)	P-value	Multivariate analysis OR (95% CI)	P-value
<b>FIGO stage</b>						
IB2	8	87	1	0.04	1	0.67
II	25	77	0.88 (0.4 - 2)		0.78 (0.33 - 1.2)	
III-IVA	17	47	2.9 (1.5 - 6.4)		1.1 (0.3 - 2.3)	
<b>Histology</b>						
Squamous	40	73	1	0.98	-	-
Non-squamous	10	74	0.83 (0.5 - 1.8)			
<b>Pelvic surgery</b>						
Extrafascial hysterectomy	35	81	1	0.06	1	0.45
Radical hysterectomy	15	54	2.1 (1.2 - 3.4)		1.2 (0.77 - 2)	
<b>Approach</b>						
Laparotomy	15	85.7	1	0.04	1	0.45
Laparoscopy	35	12.5	7.2 (1.6 - 30.2)		4 (0.7 - 22)	
<b>Pelvic and /or paraaortic lymphadenectomy</b>						
No	2	77	1	0.67		
Yes	48	67	1.1 (0.8 - 2.1)			
<b>involved margins</b>						

No	43	75	1	0.03		
Yes	7	31	4.3 (2 – 8.2)			
<b>Residual cervical</b>						
None	15	52	1	0.03	1	0.02
< 1cm	18	30	2.9 (1.9 – 6.5)		1.9	
1 cm						
Millimetric(<2mm)						
10						
20 Millimetric(<2mm)						
≥ 1 cm	17	28	3.9 (2.2 – 8.3)		3.2	
<b>Nodal status</b>						
Negative nodes	29	83	1	0.001	1	0.001
Positive pelvic nodes	16	50	2.1 (1.8 – 6.5)		2.2	
Positive paraaortic nodes	5	17	4.2 (2 – 11.2)		4	

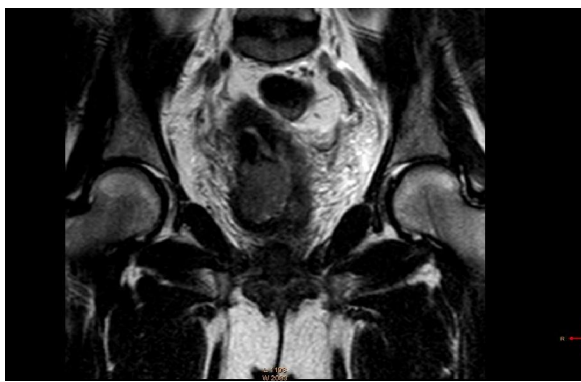


(a)

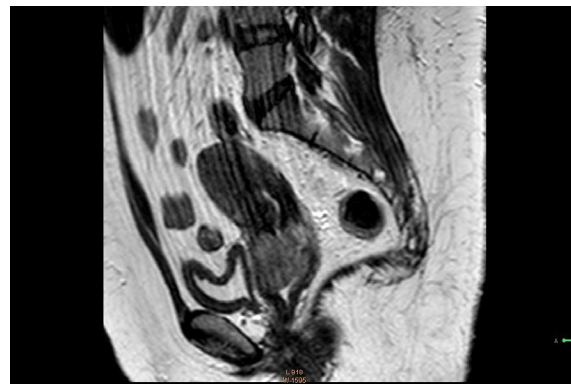


(b)

Figure (1): Pelvic MRI of 45 years old female: (a) Axial T2W (b) Sagittal T2W, show large cervical carcinoma without localized infiltration or lymph nodes enlargement.



(a)



(b)

Figure (2): Pelvic MRI of 47 years old female: (a) Axial T2W (b) Sagittal T2W, images show diffuse cervical carcinoma with small areas of degeneration and localized pelvic infiltration.



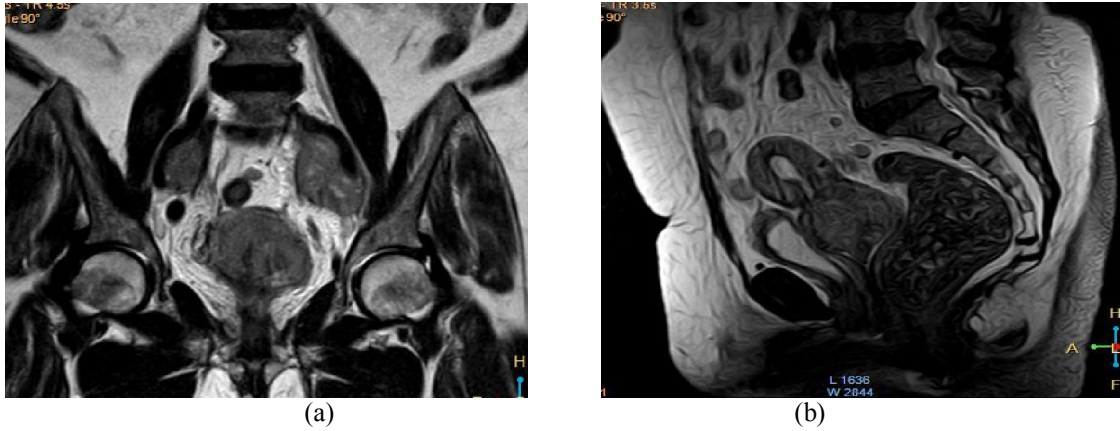


Figure (3): Pelvic MRI of 52 years old female: (a) Coronal T1W (b) Sagittal T2W images show diffuse cervical carcinoma with bilateral pelvic lymph nodes enlargement.

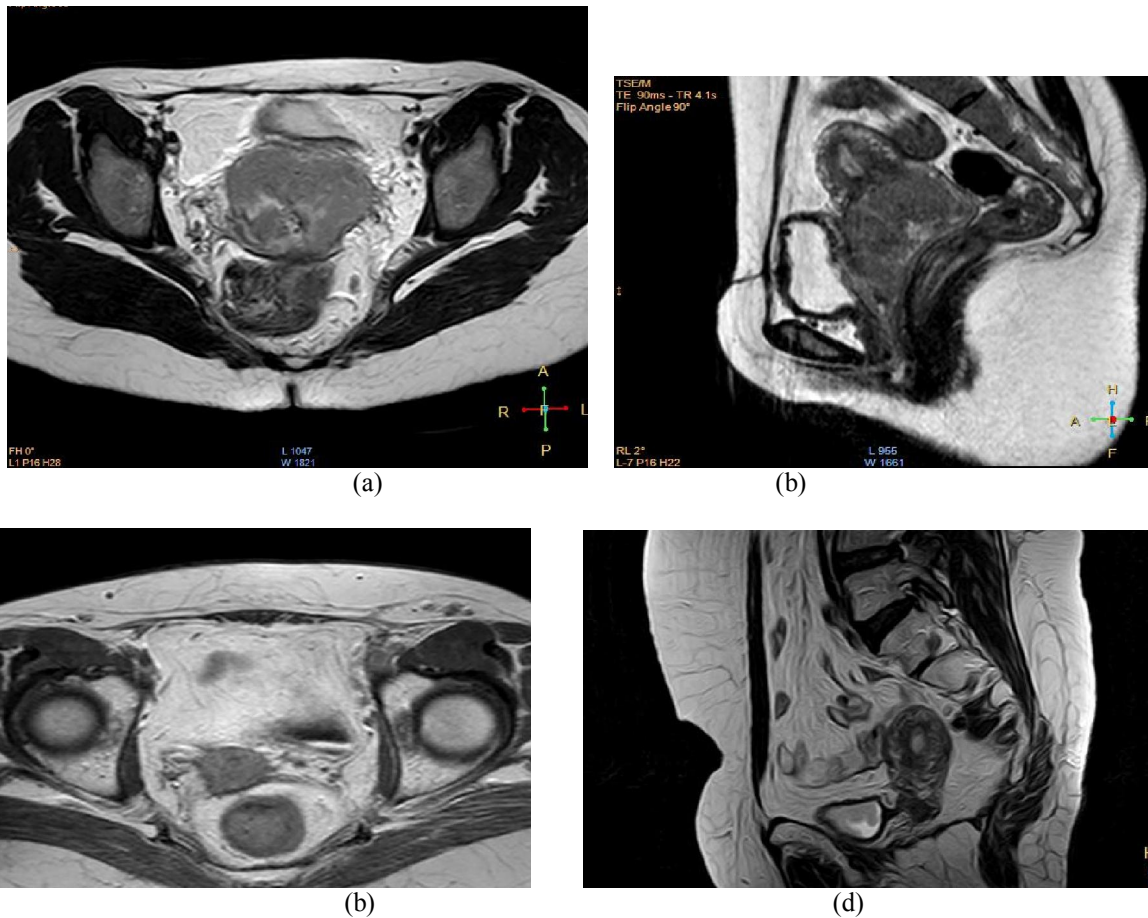


Figure (4): MRI of 42 years old female patient with cancer cervix. (a) T2W MRI coronal and (b) T2W sagittal images of the pelvis pre-chemoradiation, show cervical carcinoma with localized pelvic infiltration, but no lymph nodes enlargement. While, (c) Axial T2W, and (d) Sagittal T2W images post-chemoradiation, show significant decrease in the size of the cervical mass with RD >1cm.

#### 4. Discussion

Several teams consider CRT as a neo-adjuvant therapy, followed by hysterectomy at the end

of treatment <sup>(9)</sup>. A number of retrospective studies have been published concerning the results of this surgical procedure in this context. Those studies

demonstrated that such surgery is feasible and beneficial in terms of removing RD <sup>(9,11,18)</sup>. Nevertheless, those papers were unable to demonstrate any survival advantage in patients subjected to completion surgery because they all reported on their experience of patients treated surgically without comparing them with a control group of patients exclusively managed with CRT. Furthermore, in most of those papers, the CRT modalities were heterogeneous. This is why our study focused on a population of patients with very strict inclusion criteria concerning CRT in order to improve the reliability of the results observed.

Survival rates reported in the study seem to be very close or similar to those reported by teams who manage patients exclusively with definitive CRT <sup>(10,20,21)</sup>. Nevertheless, the aim of this study was not to try to demonstrate the therapeutic value of completion surgery after CRT in locally advanced cervical cancer, because only a randomized trial could adequately explore this crucial question. A trial was opened in France 6 years ago (randomizing patients with a macroscopic and radiologic complete response after CRT between extrafascial hysterectomy and no hysterectomy), but it was closed because of insufficient accrual. Since the closure of that trial, completion surgery is considered in patients with persistent disease 8-10 weeks after end of CRT; therefore clinical and MRI evaluation to diagnose any RD was performed. In cases of a clinical and radiological complete response, no surgery is performed. In cases of RD, a simple extrafascial hysterectomy (type A from Querleu and Morrow's classification) <sup>(11)</sup> is performed or radical hysterectomy fitting the disease when possible.

Data concerning prognostic factors are important because histological results concerning the lymph nodes and the cervix after CRT could help us to understand the natural history of treatment failure. We could then attempt to improve the modalities of CRT and local and distant control of disease for future patients.

The first important prognostic factor in the multivariate analysis was the presence of RD in the cervix. The rate of RD we observed is close to that in other different series, which was in the range of 20-50% <sup>(9,11,18)</sup>. In theory, this could be a strong plea for completion surgery.

Nevertheless, finding histologic RD and removing it does not necessarily imply a survival improvement. One third of the patients with RD had millimetric RD, and many of them would have had total surgical sterilization of the cervix if surgery had been performed later. In patients with larger RD  $\geq 1$ cm in other series <sup>(14,18,20)</sup>, surgery has a theoretical major therapeutic impact, but given the greater risk for

extracervical disease (nodal or distant disease) in patients with RD, the real impact on survival in this subgroup remains unproven and still debated <sup>(12,14)</sup>.

Given the frequency of histologic RD, the burning question is how to improve local control of disease without significantly increasing morbidity (as we observed after completion surgery). The ideal solution is to improve the delivery of radiation therapy, particularly brachytherapy with 3-D MRI-guided procedure <sup>(22)</sup>.

The second major prognostic factor in the current trial is histological nodal status. The rate of patients with positive para-aortic nodes in the current trial was 10%. Among the patients without enlarged para-aortic lymph nodes on conventional imaging who had undergone para-aortic lymphadenectomy, 13.3% had positive para-aortic nodes. Some of them could have experienced disease "progression" during CRT because this para-aortic spread may not have been present initially. However, most of them probably would have had such spread that was not visible during conventional imaging at the time of initial management. This rate is high but is similar to that reported in a previous study <sup>(22)</sup>.

Furthermore, the survival of patients with para-aortic nodal involvement at the time of completion surgery is very poor <sup>(22)</sup>.

Lymphadenectomy at the time of completion surgery is probably pointless or of very limited value in terms of improving the survival of patients with para-aortic spread <sup>(22)</sup>. Thus, the next step is to improve the detection of para-aortic involvement. PET-CT imaging is a major asset in this context <sup>(23,24)</sup>. Several excellent papers have clearly suggested longer survival in patients undergoing treatment based on PET-CT imaging <sup>(25)</sup>. Over the last 3 years, this imaging modality has been systematically performed. This is the rationale behind the inclusion of laparoscopic para-aortic staging surgery in such patients to extend radiation fields in cases of positive para-aortic nodes <sup>(26,27,28)</sup>. Even if the value of such management is still under debate <sup>(29)</sup>, several papers suggest longer survival in patients undergoing surgical staging <sup>(30)</sup>. This surgery is now systematically performed in "operable" patients without uptake in the para-aortic area. Such para-aortic lymphadenectomy is performed up to the level of the left vein <sup>(25)</sup>. The objective of this strategy is to extend the external radiation therapy field to the para-aortic region in cases of para-aortic node disease.

The most "problematic" result of the current analysis concerns the number of patients with positive residual nodes in an irradiated area (12 patients). Houvenaeghel *et al.* <sup>(31)</sup> and Ferrandina *et al.* <sup>(32)</sup> previously reported on residual pelvic lymph nodes after CRT, having observed 11.5% positive pelvic

nodes. Such important data do not plead for us in favor of adding a pelvic lymphadenectomy at the time of completion surgery in this context because the lymphatic morbidity incurred by such a procedure is high in irradiated patients (lymphedema) and its usefulness in terms of optimizing survival is not proven.

However, this important observation raises the question of the optimization of pelvic nodal control in this context<sup>[33, 34]</sup>. The most appropriate procedure for optimizing complete nodal sterilization is the use of a lateropelvic boost of 10 Gy in patients exhibiting enlarged nodes on conventional imaging<sup>[34]</sup>. Ariga T, et al, in 2013 reported that the boost EBRT (external beam radiotherapy) achieves favorable pelvic nodal control without increasing late complications for cervical cancer patients with clinically positive nodes treated by definitive RT or CCRT<sup>[35]</sup>. Yet in our study: 16 patients who underwent lateropelvic boost, nine still had positive pelvic lymph nodes at the time of surgery, which means that the boost was probably not sufficient to completely sterilize bulky pelvic lymph nodes. A new regimen of concurrent chemotherapy and/or image-guided intensity-modulated radiation therapy would probably increase the rate of complete sterilization<sup>[36]</sup>.

The second results from the current study concern the morbidity of completion surgery in this context. We did not investigate the morbidity of combination CRT followed by completion surgery. If this had been the case, the interval of 3 months after the end of treatment would have clearly been too short to accurately evaluate this issue. In an excellent paper by Eifel *et al.*<sup>[37]</sup> published before the era of CRT, the rates of major morbidity at 3 and 5 years in a cohort of 1,784 patients treated for stage IB disease using radiation therapy (with completion hysterectomy in 234) were 7.7% and 9.3%, respectively. After 5 years, there was a continuous risk of 0.34% per year for major morbidity, with a 14.4% rate of major complications at 20 years<sup>[37]</sup>. Thus, a longer follow-up would be required to evaluate the morbidity of the entire treatment. Furthermore, the morbidity of CRT itself is now relatively well evaluated<sup>[37, 38]</sup>. The aim of the study at a time when the usefulness of completion surgery is being questioned is to evaluate the morbidity directly related to the surgical procedure itself. This is why a period of 3 months after surgery seemed appropriate to answer to this question.

Lymphedema, was included which is rarely reported in different analyses of morbidity because it can really deeply impair the quality of life of patients and is mainly observed >3 months after surgery. It was included also because the risk for lymphedema exists in patients treated exclusively with radiation therapy, but it is low<sup>(37, 38)</sup>. However, this risk is

clearly higher in patients subjected to combination surgery (particularly lymph node dissection) and radiation therapy<sup>[38]</sup>. In the randomized trial published by Landoni *et al.*<sup>[38]</sup>, the rate of lymphedema was 0.6% in patients treated for early-stage cervical cancer using radiation therapy alone and 9% in patients treated with surgery and external radiation therapy. In the paper by Eifel *et al.*<sup>[37]</sup>, among the seven patients who experienced "leg edema," six had undergone lymph node surgery combined with radiation therapy, and only one patient was treated with radiation therapy alone. In the series by Perez *et al.*<sup>[39]</sup> involving 811 patients treated with radiation therapy, only one case of leg edema was observed.

Even with the potential limit of underreporting in the current study, we demonstrated a very high morbidity rate after hysterectomy following CRT. One patient died of postoperative complications. Three groups of complications were mainly observed: lymphadenectomy-related morbidities, urinary or digestive tract morbidities, and infectious morbidities (peritonitis or a deep abscess) treated using further surgery. The last two groups of complications were strongly correlated because peritonitis or a deep abscess often occurred secondary to a urinary or bowel fistula. In the paper by Eifel *et al.*<sup>[37]</sup>, the risk for digestive or urinary tract fistula was double in patients who underwent a hysterectomy (and in that series only an extrafascial procedure was performed), compared with patients treated with radiation therapy alone (2.6% versus 5.3%;  $p = 0.04$ ). Those complications were strongly correlated with the type of surgery used: the rate of ureteral stenosis or fistula or bowel fistula was greater in cases of more radical hysterectomy (with parametrial dissection). This phenomenon was previously reported at the time of pelvic surgery in patients treated with initial external radiation therapy<sup>(40)</sup>. We also observed a greater rate of morbidity in patients subjected to parametrial dissection in the present study. Such radical hysterectomies were statistically more frequently used in patients with RD in order to ensure clear surgical margins. These two factors (radical hysterectomy and RD) were correlated Table (4). This result clearly suggests that systematic radical hysterectomy should be avoided in this context (if completion surgery is considered).

Basically, if completion surgery is discussed (it has been proposed systematically by several teams) after CRT in patients devoid of macroscopic RD in the cervix, an extrafascial hysterectomy should be considered. A radical hysterectomy is more "logical" in patients with RD to guarantee free margins. However, such a basic proposal would also increase the morbidity of surgery, whereas the therapeutic value of completion surgery in patients with bulky RD



(>1 cm or 2 cm according to the series) remains totally unproven because these poor responders also run a higher risk for extrapelvic disease (nodal involvement or distant metastasis) <sup>[12,14]</sup>. This point also raises the important question of the evaluation of response (and thus, the potential presence of RD) at the end of CRT (should completion surgery be discussed). Response evaluation is based on a clinical examination and imaging (MRI) performed 6-8 weeks after irradiation, but the accuracy of such management is still debated <sup>[41]</sup>. Perhaps adding diffusion-weighted MRI or PET-CT imaging to predict potential RD could be helpful in this context <sup>[42,43]</sup>.

A laparoscopic approach could also be a way to decrease the morbidity of the surgery. In the present study, a laparoscopic hysterectomy was used in a selected group of patients devoid of clinical or radiological RD in the cervix, who had therefore undergone a "simple extrafascial hysterectomy." Logically, no urinary or digestive tract morbidity was observed. Most of the morbidities in laparoscopically treated patients in our study were related to the use of lymphadenectomy. The differences in the rates of lymphocysts and chylous ascites between the laparoscopic and laparotomic approach were almost of borderline statistical significance. We have no explanation for this higher rate of lymphatic morbidities in the laparoscopy group, but this explains why the use of a laparoscopic approach failed to reduce morbidity in our study. An interesting paper published on this topic compared a group of 46 patients undergoing radical hysterectomy by laparoscopy after CRT with a group of 56 patients undergoing abdominal radical hysterectomy <sup>[16]</sup>. The rate of postoperative complications (particularly urinary fistula) was significantly lower in the laparoscopically treated patients without a higher rate of positive margins <sup>[16]</sup>. We were unable to conduct such a comparison in our study because no radical hysterectomy was performed laparoscopically.

The morbidity of completion surgery (based on hysterectomy with or without lymphadenectomy) was very high as the patients initially treated with CRT for locally advanced cervical cancer. Mortality was observed in 2% of cases, and the overall rate of urinary or bowel tract morbidity was close to 20%. The therapeutic value of completion surgery (which remains unproven today) should be weighed against the high morbidity rate in this context. Perhaps a laparoscopic approach could reduce the overall morbidity of completion surgery. Nevertheless, because the therapeutic value of this surgery has not been demonstrated, using an approach that could reduce surgery-related morbidity is not a proof of the usefulness of such surgery in terms of improving survival. Finally, the only certainty about completion

surgery after CRT is that it gives rise to a high incidence of morbidity.

## Conclusion

In this study, the presence and size of RD and histologic nodal involvement were the strongest prognostic factors. Such results suggest that the survival of patients treated using CRT for locally advanced cervical cancer could potentially be enhanced by improving the rate of complete response in the irradiated area (cervix or pelvic nodes) and by initially detecting patients with para-aortic spread so that treatment could be adapted in such patients. The morbidity of completion surgery is high.

## References

1. Mohar A, Frias-Mendivil M.: Epidemiology of cervical cancer. *Cancer Invest* 2000; 18: 584-590.
2. Touboul C., Mauouen A., Gouv S., *et al.*: Prognostic Factors and Morbidities After Completion Surgery in Patients Undergoing Initial Chemoradiation Therapy for Locally Advanced Cervical Cancer *The Oncologist* 2010; 15(4):405-415.
3. Peters WA III, Liu PY, Barrett R *et al.*: Concurrent chemotherapy and pelvic radiation therapy compared with pelvic radiation therapy alone as adjuvant therapy after radical surgery in high-risk early-stage cancer of the cervix. *J Clin Oncol* 2000; 18: 1606-1613.
4. Morris M, Eifel PJ, Lu J *et al.*: Pelvic radiation with concurrent chemotherapy compared with pelvic and para-aortic radiation for high-risk cervical cancer. *New Engl J Med* 1999;340: 1137-1143.
5. Keys HM, Bundy BN, Stehman FB *et al.*: A comparison of weekly cisplatin during radiation therapy versus irradiation alone each followed by adjuvant hysterectomy in bulky stage IB cervical carcinoma: a randomized trial of the Gynecology Oncology Group. *New Engl J Med* 1999;340: 1154-1161.
6. Rose PG, Bundy BN, Watkins EB *et al.*: Concurrent cisplatin-based chemoradiation improves progression-free survival in advanced cervical cancer: results of randomized Gynecologic Oncology Group study. *New Engl J Med* 1999; 340: 1144-1153.
7. Whitney CW, Sause W, Bundy BN *et al.*: A randomized comparison of fluorouracil plus cisplatin versus hydroxyurea as an adjunct to radiation therapy in stages IIB-TVA carcinoma cervix with negative para-aortic lymph nodes. GOG and Southwest Oncology Group study. *J Clin Oncol* 1999; 17: 1339-1348.

8. Thomas GM.: Concurrent chemotherapy and radiation for locally advanced cervical cancer: the new standard of care. *Semin Radiat Oncol.* 2000;(1) 10:44-50.
9. Green J, Kirwan J, Tierney J, Vale C, Symonds P, Fresco L, *et al.*: Concomitant chemotherapy and radiation therapy for cancer of the uterine cervix. *Cochrane Database Syst Rev.* 2005; (3) CD002225.
10. Roberts KB, Urdaneta N, Vera R *et al.*: Interim results of a randomized trial of mitomycin C as an adjunct to radical radiotherapy in the treatment of locally advanced squamous-cell carcinoma of the cervix. *Int J Cancer* 2000; 90: 206-223.
11. Houvenaeghel G, Lelievre L, Gonzague-Casabianca L *et al.*: Long-term survival after concomitant chemoradiotherapy prior to surgery in advanced cervical carcinoma. *Gynecol Oncol* 2006;100:338-343.
12. Ferrandina G, Legge F, Fagotti A, *et al.*: Preoperative concomitant chemoradiotherapy in locally advanced cervical cancer: Safety, outcome, and prognostic measures. *Gynecol Oncol* 2007;107 suppl 1:S127-S132.
13. Classe JM, Rauch P, Rodier JF, *et al.*: Surgery after concurrent chemoradiotherapy and brachytherapy for the treatment of advanced cervical cancer: Morbidity and outcome: Results of a multicenter study of the GCCLCC (Groupe des Chirurgiens de Centres de Lutte Centre le Cancer). *Gynecol Oncol* 2006; 102:523-529.
14. Azria E, Morice P, Haie-Meder C, *et al.*: results of hysterectomy in patients with bulky residual disease at the end of chemoradiotherapy for stage IB2/II cervical carcinoma. *Ann Surg Oncol* 2005; 12:332-337.
15. Darus CJ, Callahan MB, Nguyen QN, *et al.*: Chemoradiation with and without adjuvant extrafascial hysterectomy for IB2 cervical carcinoma. *Int J Gynecol Cancer* 2008; 18:730-735.
16. Colombo PE, Bertrand MM, Gutowski M, *et al.*: Total laparoscopic radical hysterectomy for locally advanced cervical carcinoma (stages IIB, IIA and bulky stages IB) after concurrent chemoradiation therapy: Surgical morbidity and oncological results. *Gynecol Oncol* 2009; 14:404-409.
17. Huguet F, Cojocariu OM, Levy P, *et al.*: Preoperative concurrent radiation therapy and chemotherapy for bulky stage IB2, IIA, and IIB carcinoma of the uterine cervix with proximal parametrial invasion. *Int J Radiat Oncol Biol Phys* 2008; 72:1508-1515.
18. Ota T, Takeshima N, Tabata T, *et al.*: Adjuvant hysterectomy for treatment of residual disease in patients with cervical cancer treated with radiation therapy. *Br J Cancer* 2008; 99:1216-1220.
19. Dindo D, Demartines N, Clavien PA.: Classification of surgical complications: A new proposal with evaluation in a cohort of 6336 patients and results of a survey. *Ann Surg* 2004;240:205-213.
20. Green JA, Kirwan JM, Tierney JF, *et al.*: Survival and recurrence after concomitant chemotherapy and radiotherapy for cancer of the uterine cervix: A systematic review and meta-analysis. *Lancet* 2001;358:781-786.
21. Chemoradiotherapy for Cervical Cancer Meta-Analysis Collaboration. Reducing uncertainties about the effects of chemoradiotherapy for cervical cancer: A systematic review and meta-analysis of individual patient data from 18 randomized trials. *J Clin Oncol* 2008; 26:5802-5812.
22. Delpech Y, Haie-Meder C, Rey A, *et al.*: Para-aortic involvement and interest of para-aortic lymphadenectomy after chemoradiation therapy in patients with stage IB2 and II cervical carcinoma radiologically confined to the pelvic cavity. *Ann Surg Oncol* 2007; 14:3223-3231.
23. Grigsby PW, Siegel BA, Dehdashti F. *et al.*: Lymph node staging by positron emission tomography in patients with carcinoma of the cervix. *J Clin Oncol* 2001; 19:3745-3749.
24. Wright JD, Dehdashti F, Herzog TJ, *et al.*: Preoperative lymph node staging of early-stage cervical carcinoma by [18F]-fluoro-2-deoxy-D-glucose-positron emission tomography. *Cancer* 2005; 104:2484-2491.
25. Boughanim M, Leboulleux S, Rey A, *et al.*: Histologic results of para-aortic lymphadenectomy in patients treated for stage IB2/II cervical cancer with negative [18F] fluorodeoxyglucose positron emission tomography scans in the para-aortic area. *J Clin Oncol* 2008; 26:2558-2561.
26. Mortier DG, Stroobants S, Amant F, *et al.*: Laparoscopic para-aortic lymphadenectomy and positron emission tomography scan as staging procedures in patients with cervical ca stage IB2-IIIB. *Int J Gynecol Cancer* 2008;18:723-729.
27. Leblanc E, Narducci F, Frumovitz M, *et al.*: Therapeutic value of pretherapeutic extraperitoneal laparoscopic staging in locally advanced cervical carcinoma. *Gynecol Oncol* 2007; 105:304-311.
28. Varia MA, Bundy BN, Deppe G, *et al.*: Cervical carcinoma metastatic to para-aortic nodes:

- Extended field radiation therapy with concomitant 5-fluorouracil and cisplatin chemotherapy: A Gynecologic Oncology Group study. *Int J Radiat Oncol Biol Phys* 1998; 42:1015-1023.
29. Lai CH, Huang KG, Hong JH, *et al.*: Randomized trial of surgical staging (extraperitoneal or laparoscopic) versus clinical staging in locally advanced cervical cancer. *Gynecol Oncol* 2003; 89:160-167.
  30. Gold MA, Tian C, Whitney CW, *et al.*: Surgical versus radiographic determination of para-aortic lymph node metastases before chemoradiation for locally advanced cervical ca: A Gynecologic Oncology Group Study. *Cancer* 2008; 112:1954-1963.
  31. Houvenaeghel G, Lelievre L, Rigouard AL, *et al.*: Residual pelvic lymph node involvement after concomitant chemoradiation for locally advanced cervical cancer. *Gynecol Oncol* 2006; 102:74-79.
  32. Ferrandina G, Distefano M, Ludovisi M, *et al.*: Lymph node involvement in locally advanced cervical cancer patients administered preoperative chemoradiation versus chemotherapy. *Ann Surg Oncol* 2007; 14:1129-1135.
  33. Kupets R, Thomas GM, Covens A., *et al.*: Is there a role for pelvic lymph node debulking in advanced cervical cancer? *Gynecol Oncol* 2002; 87:163-170.
  34. Grigsby PW, Singh AK, Siegel BA, *et al.*: Lymph node control in cervical cancer. *Int J Radiat Oncol Biol Phys* 2004; 59:706-712
  35. Ariga T, Toita T, M, Kasuya G, *et al.*: External beam boost irradiation for clinically positive pelvic nodes. *J Radiat Res* 2013; 54(4):690-696.
  36. Macdonald DM, Lin LL, Biehl K, *et al.*: Combined intensity-modulated radiation therapy and brachytherapy in the treatment of cervical cancer. *Int J Radiat Oncol Biol Phys* 2008; 71:618-624.
  37. Eifel PJ, Levenback C, Wharton JT, *et al.*: Time course and incidence of late complications in patients treated with radiation therapy for FIGO stage IB carcinoma of the uterine cervix. *Int J Radiat Oncol Biol Phys* 1995; 32:1289-1300.
  38. Landoni F, Maneo A, Colombo A, *et al.*: Randomized study of radical surgery versus radiotherapy for stage Ib-IIa cervical cancer. *Lancet* 1997;350:535-540.
  39. Perez CA, Breaux S, Bedwinek JM, *et al.*: Radiation therapy alone in the treatment of carcinoma of the uterine cervix. II. Analysis of complications. *Cancer* 1984; 54:235-246.
  40. Morice P, Le Bouedec G, Pomel C, *et al.*: Complications of primary external radiation therapy followed by radical hysterectomy for bulky stage IB and II cervical cancer. *Eur J Cancer* 2001; 37 suppl 6:1232.
  41. Vincens E, Baileyguier C, Rey A, *et al.*: Accuracy of magnetic resonance imaging in predicting residual disease in patients treated for stage IB2/II cervical carcinoma with chemoradiation therapy: Correlation of radiologic findings with surgico-pathologic results. *Cancer* 2008; 113:2158-2165.
  42. Schwarz JK, Siegel BA, Dehdashti F, *et al.*: Association of post-therapy positron emission tomography with tumor response and survival in cervical carcinoma. *JAMA* 2007; 298:2289-2295.
  43. McVeigh PZ, Syed AM, Millosevic M, *et al.*: Diffusion-weighted MRI in cervical cancer. *Eur Radiol* 2008; 18:1058-1064.

12/25/2015