

Concurrent Chemoradiotherapy with Weekly Docetaxel and Cisplatin for Locally Advanced Head and Neck Cancer

Ola Nabih¹, Hoda H. Essa¹, Reham Abdel-Wahab^{1,4}, Nagham Nabil², Dalia G. Yasien³

¹Department of Clinical Oncology, Faculty of Medicine, Assiut University, Assiut, Egypt

²Radio-Diagnosis, Faculty of Medicine, Assiut University, Assiut, Egypt

³Otolaryngology, Faculty of Medicine, Assiut University, Assiut, Egypt

⁴Department of Gastrointestinal Medical Oncology, The University of Texas MD Anderson Cancer Center, Houston, Texas, USA
olanabih1980@gmail.com

Abstract: Background: Concurrent chemoradiotherapy (CCRth) using cisplatin-based regimens are the standard of care in head and neck squamous cell carcinoma (HNSCC). However, the addition of docetaxel to the treatment regimen showed survival improvement. **Objectives:** Our study aims to evaluate the efficacy and toxicity of CCRth with weekly docetaxel and cisplatin in patients with locally advanced HNSCC. **Patients and Methods:** Between March 2010 and April 2012, we enrolled thirty stage III and IVA HNSCC patients. We treated them with 70Gy conventionally fractionated radiotherapy (Rth) concurrently with weekly cisplatin and docetaxel, both given as one hour infusion of 20mg/m² that administered 30 min before Rth. **Results:** The median follow-up period was 23months (range, 2 –53 months). The mean age of the patients was 59 years (range, 29–72 years). The most common primary tumor site was the larynx (53.3%), followed by the hypopharynx (26.7%). 64.5% of patients had N2/N3 disease and 76.7% had T3/T4 disease. Among 30 patients, 13 (43.3%) achieved complete response (CR), 11(36.7%) achieved a partial response (PR), 2(6.7%) had stable disease (SD) and 4 patients (13.3%) had progressive disease (PD). The 2-year overall survival (OS) and progression-free survival (PFS) was 83.3% and 66.7%, respectively with well tolerable toxicities. **Conclusions:** Our study concluded that concurrent administration of weekly cisplatin and docetaxel is a well tolerable promising regimen that can induce only minimal myelosuppression.

[Ola Nabih, Hoda H. Essa, Reham Abdel-Wahab, Nagham Nabil, Dalia G. Yasien. **Concurrent Chemoradio therapy with Weekly Docetaxel and Cisplatin for Locally Advanced Head and Neck Cancer.** *Cancer Biology* 2015;5(4):107-112]. (ISSN: 2150-1041). <http://www.cancerbio.net>. 13. doi:[10.7537/marscbj050415.13](https://doi.org/10.7537/marscbj050415.13).

Keywords: Locally advanced head and neck cancer, chemoradiotherapy, cisplatin, docetaxel.

1. Introduction:

Head and neck squamous cell carcinoma (HNSCC) is one of the most common malignant tumors. Despite using multimodality approaches for treatment, the HNSCC recurrence rate still ranging from 10 to 40%. This could be explained by the fact that approximately 60% of cases presented with an advanced stage (stage III–IV). Furthermore, among patients who have locally advanced stage, 40-60% of patients develop locoregional recurrences or distant metastases with the 3 year overall survival (OS) ranging from 30-50% after receiving the standard therapy including either surgery or radiotherapy (Rth).¹⁻⁵

However, concurrent chemoradiotherapy (CCRth) remains the standard treatment modality for both resectable HNSCC aiming for organ-preservation and for unresectable disease aiming to achieve maximum locoregional control.^{6,7} Concurrent administration of chemotherapy (Cth) improved locoregional disease control and OS compared with Rth alone. But unfortunately, this didn't induce dramatic impact on the rate of distant metastases.⁸

Although, cisplatin is a potent radiosensitizer and the standard chemotherapeutic agent used in treating

HNSCC patients. Addition of docetaxel have been reported on several clinical trials, and showed improvement in patients' OS.^{3,9} The rationale for using docetaxel in combination with cisplatin is based on several factors including that both docetaxel and cisplatin are the most effective cytostatic agents for treating patients with HNSCC. Additionally, in vitro data showed lack of cross-resistance between docetaxel and cisplatin. Finally, combination of these two cytostatic drugs, may improve the therapeutic index.⁹

This prospective study was designated to assess the efficacy and safety of concurrent administration of weekly docetaxel and cisplatin with normal fractionated Rth for patients with locally advanced HNSCC.

2. Patients and Methods

Our study was a single arm phase II, open-label single center study. The protocol was approved by the Assiut faculty of medicine institutional review board (IRB) and all enrolled patients signed a written informed consent

Eligibility Criteria:

Between March 2010 and April 2012 we enrolled thirty patients who were older than 18 years old,

histologically confirmed to have HNSCC, clinically and radiologically confirmed to have locally advanced stage III or IV squamous cell carcinoma of the larynx, oropharynx or hypopharynx according to the 6th edition of American Joint Committee on Cancer (AJCC), TNM 2010 staging system,¹⁰ non-metastatic, and not previously treated. Furthermore, patients had an Eastern Cooperative Oncology Group performance status (ECOG) 0–1 with adequate hematologic, hepatic and renal functions including hemoglobin >10 g/dl, absolute neutrophil count $\geq 1,500/\text{mm}^3$, platelets $\geq 100,000/\text{mm}^3$, serum bilirubin <2 mg/dl, both ALT and AST $\leq 2 \times$ upper limit of normal (ULN), alkaline phosphates $\leq 5 \times$ ULN, and Serum creatinine ≤ 1.5 mg/dl or creatinine clearance ≥ 60 ml/min. Also, we excluded patients who have a prior history of cardiac disease (serious arrhythmia, heart failure, myocardial infarction, or unstable angina within the last 6 months), active serious infection, or a psychiatric illness that would preclude obtaining informed consent.

According to the protocol, pretreatment assessment was done including direct examination of the ears, nose, and throat by an otolaryngologist. Also, fiberoptic laryngopharyngoscopy, direct endoscopy with biopsy were taken. Additionally, hematological and biochemical testing and a computed tomographic scan (CT) for assessment of the primary tumor site and neck nodes was done with chest x-ray with or without chest CT to exclude distant metastasis.

Study design:

The primary objective was to evaluate the efficacy and toxicity of CCRth with weekly docetaxel and cisplatin in patients with locally advanced HNSCC. Weekly cisplatin (20mg/m²) and docetaxel (Taxotere, Sanofi-Aventis Spain) (20 mg/m²) were given over an hour infusion and 30 min before Rth. All patients received a 6MV photon conventionally fractionated RT until a total tumor dose of 70Gy and a total nodal dose of 50GY in case of microscopic disease. In case of clinically positive lymph nodes, an electron beam (9–12MeV) was used to increase the dose to the posterior cervical nodes after 50Gy without allowing further dose to the spinal cord. Treatment of the primary tumor and gross nodal disease continued via shrinking field's to a total dose of 66Gy.

Treatment Response and Adverse Events Assessments:

Objective response and adverse events were assessed through both the RECIST criteria¹¹, and the National Cancer Institute Common Toxicity Criteria (NCI CTCAE) v2.0. Patients' evaluation was done on a weekly bases by history, physical examination, documentation of ECOG and toxicity evaluation. Laboratory testing was carried out at every other week and more often as indicated. The response evaluation was performed 4–6 weeks after the completion of CCRT

by head and neck imaging (CT/MRI) and upper endoscopy. Biopsy was performed if there was clinical evidence of residual tumor. Chest X-ray was annually performed or when it was clinically indicated. Finally, patients were monitored monthly for detection of recurrence in the first year, every 2 months in the second year, every 3 months in the third year, and every 6 months thereafter until death or data censoring.

Statistical methods of analysis:

We used SPSS version 21 for windows (SPSS Inc, Chicago, IL, USA) software. Categorical variables were analyzed by the use of Fisher's exact test and continuous variables were analyzed by Wilcoxon test. The primary endpoint was evaluation of the objective response, and secondary endpoints were evaluating response rate (RR), progression-free survival (PFS), and OS. The PFS was defined as the time from the initiation of treatment to the date of first observation of progressive disease or the date of death. While, OS was defined as the time from date of treatment initiation to the death date or last follow up date. Both PFS and OS were analyzed according to the Kaplan–Meier method.¹² *P* value <0.05 was considered to be significant.

3. Results

Patient and tumor characteristics:

Patients' and tumor characteristics were detailed in (table1). The median follow-up time was 23 months (range, 2 – 53 months). 23(76.7%) of patients were males with the mean of age \pm standard deviation (SD) was 59.8 ± 9.4 years (range, 29–72 years). All patients had an ECOG (0–1) at time of enrollment and 70% of them were smokers. The most common primary tumor site was the larynx followed by the hypopharynx and oropharynx (53.3%, 26.7% and 20%), respectively. 76.6% of patients had T3/T4 and 70% had advanced nodal metastasis (N2/3) at time of presentation and all patients were M0.

Tumor efficacy:

Among 30 patients, 24 (80%) achieved an objective response rate including 13 patients (43.3%) had a CR, and 11 patients (36.7%) had partial response (PR). Also, we have 2 patients (6.7%) had stable disease (SD) and 4 patients (13.3%) had progressive disease (PD). Consistent response rates across primary tumor sites were observed in a subgroup analysis and included the larynx (CR 56.25%, PR 37.5%), pharynx (CR 25%, PR 50%), and laryngopharynx (CR 33.3%, PR 16.7%). (Table 2).

Among 24 patients who showed a complete or partial response after CCRth, local and/or regional treatment failures were developed in 4 (13.3%) patients without evidence of distant metastasis. Figure (1 & 2) showed that the 2-year OS and PFS rates were 79% (95% CI; 64.4–93.6%) and 59% (95% CI; 41.1–76.6%),

respectively. While, both median OS and PFS was not achieved.

Radio-chemotherapy related toxicity

The most commonly reported treatment related toxicities were grade 1-2 and none of our enrolled patients developed grade 4 toxicity. The most commonly reported hematologic adverse effect was neutropenia that developed in 9 (30%) of patients; of whom 5 (16.7%) were grade 1, 3 (10%) were grade 2, and 1 (3.3%) were grade 3 and all of them were treated with granulocyte colony stimulating factors (G-CSF) and prophylactic antibiotic therapy. Grade 1 anemia and thrombocytopenia were reported in 5 (16.7%) and 4 (12%), respectively. While, grade 2 anemia was reported in 4 (12%) and grade 2 thrombocytopenia was reported in 1 (3.3%). Furthermore, none of our patients had grade 3 anemia or thrombocytopenia.

Furthermore, patients develop several non-hematological toxicities including mucositis, stomatitis, skin reaction, hepatotoxicity and nephrotoxicity. The worst mucositis was observed during the fifth week of treatment. All patients with grade 3 mucositis required parenteral nutritional support and drug administration.

The reported late toxic effects were skin pigmentation, fibrosis and xerostomia. The majority of our patients presented with skin fibrosis during follow up period (56.7%, 33.3%) for both grade 1 and 2 respectively. Furthermore, grade 1 xerostomia was developed in 5 (16.7%), while grade 2 and 3 were developed in 2 (6.7%) and 6 (20%), respectively. Finally, only 4 (12%) of patients developed grade 1 skin pigmentation and none of them develop grade 2 or 3. (Table 3, Figure 3)

Table (1): Demographics, risk factors, and Clinico-pathological Characteristics:

Patient characteristic	Parameter	PatientsN=30 (%)
Age (years)	Mean \pm SD	59.8 \pm 9.4
	\leq 60	14 (46.7%)
	>60	16 (53.3%)
Sex	Male	23 (76.7%)
	Female	7 (23.3%)
Smoking	Smoker	21 (70%)
	Non-smoker	9 (30%)
Complaint	Hoarseness of voice	19 (63.3%)
	Dysphagia	17 (56.7%)
	Odynophagia	2 (6.7%)
ECOG	PS_0	17 (56.7%)
	PS_1	13 (43.3%)
Tumor site	Larynx	16 (53.3%)
	Hypopharynx	8 (26.7%)
	Oropharyngeal	6 (20%)
Tumor (T)	T2	7 (23.3%)
	T3	22 (73.3%)
	T4A/B	1 (3.3%)
Lymph nodes (LN)	N0	1 (6.7%)
	N1	9 (30%)
	N2	19 (66.7%)
	N3	1 (3.3%)
TNM Staging	Stage III	4 (13.3%)
	Stage IVA/B	26 (84.7%)
Tumor differentiation	Well differentiated	9 (30%)
	Moderately differentiated	13 (43.3%)
	Poorly differentiated	6 (20%)
	Undifferentiated	1 (3.3%)

Table (2): Initial Treatment Response after Concurrent Chemoradiotherapy:

Disease site	Total no.	Achieved response N (%)				Overall response
		CR	PR	SD	PD	
Overall	30	13 (43.3%)	11 (36.7%)	2 (6.7%)	4 (13.3%)	24 (80%)
Larynx	16	9 (56.25%)	6 (37.5%)	0	1 (6.25%)	15 (93.75%)
Pharynx	8	2 (25%)	4 (50%)	0	2 (25%)	6 (75%)
Laryngopharyngeal	6	2 (33.3%)	1 (16.7%)	2 (33.3%)	1 (16.7%)	3 (50%)

*CR, Complete response; PR, partial response; SD, stable disease; PD, progressive disease

Table (3): Early and Late non Hematological toxicity During Concurrent Chemoradiotherapy:

Variables	Patients N=30 (%)				
	G0	G1	G2	G3	G4
Leucopenia	21 (70%)	5 (16.7%)	3 (10%)	1 (3.3%)	0
Thrombocytopenia	25 (20%)	4 (12%)	1 (3.3%)	0	0
Anemia	21 (70%)	5 (16.7%)	4 (12%)	0	0
Nephrotoxicity	27 (67.7%)	1 (3.3%)	0	1 (3.3%)	0
Hepatotoxicity	28 (93.3%)	2 (6.7%)	0	0	0
Stomatitis	14 (46.7%)	12 (40%)	4(12%)	0	0
Mucositis	15 (50%)	5 (16.7%)	3 (10%)	2(6.7%)	0
Skin reaction	18 (60%)	10 (33.3%)	0	2 (6.7%)	0
Salivary gland inflammation	25 (83.3%)	3 (10%)	2 (6.7%)	0	0
Dysphagia	14 (46.7%)	10 (33.3%)	5 (16.7%)	1 (3.3%)	0
Skin pigmentation	26 (%88)	4 (12%)	0	0	0
Fibrosis	3 (10%)	17 (56.7%)	10 (33.3%)	0	0
Xerostomia	17 (56.7%)	5 (16.7%)	2 (6.7%)	6 (20%)	0

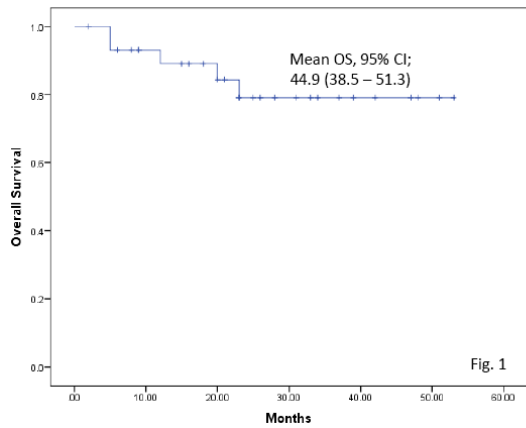


Fig. 1

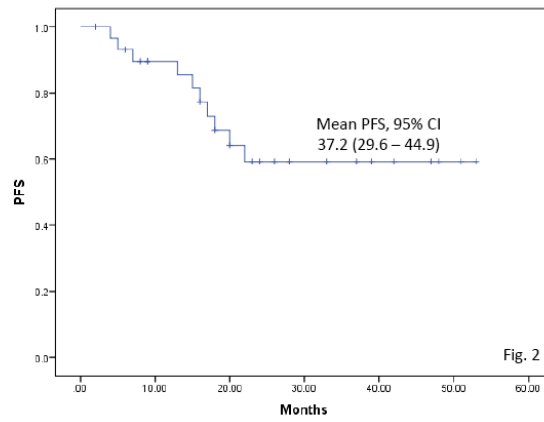


Fig. 2

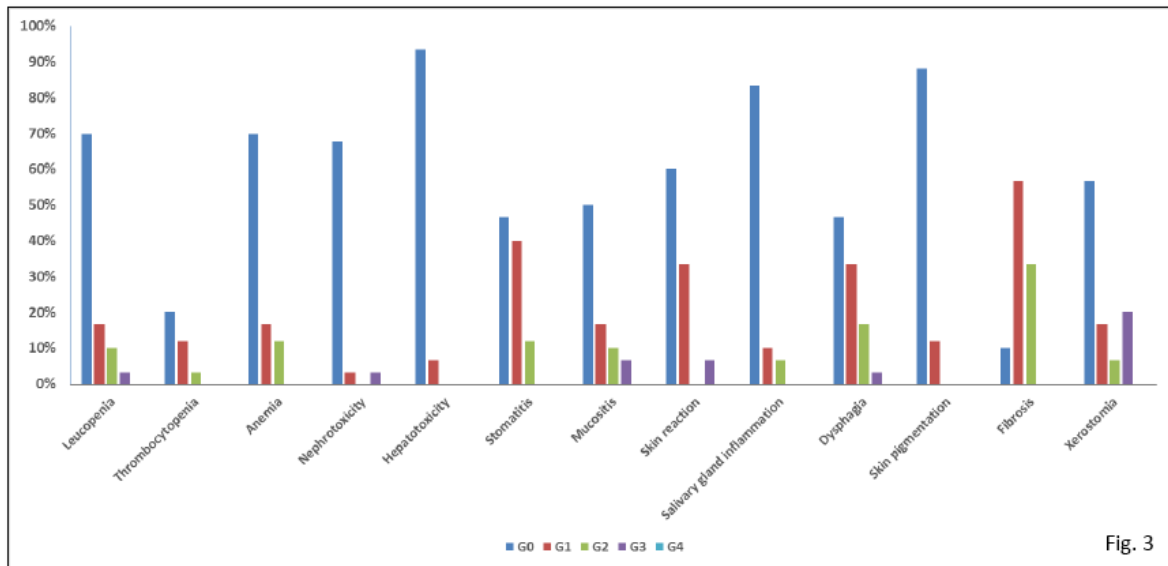


Fig. 3

4. Discussion

Despite that using multimodality approaches in treating HNSCC reduced the incidence of loco-regional recurrence, it didn't affect the rate of distant metastasis

with a median survival time less than a year.⁴ Cisplatin is a potent radiosensitizer that inhibit radiation induced DNA repair. Addition of docetaxel enhances the effect of radiation by two mechanisms; sensitization and direct

tumor cell killing.¹³⁻¹⁵ These two drugs were chosen because cisplatin is the gold standard drug in HNSCC and docetaxel has satisfactory effect either when used as a single agent or in combination with several agents e.g. 5-FU, Irinotecan, celecoxib and erlotinib.¹⁶⁻²⁰

In our study, we reported that 43.3% achieved CR. Although, this results was lower than that was reported by Baykaraet and his colleagues (71.2%), this is explained by that the majority of our patients were stage IVA. On the other hand, CR rate was higher than that was reported by few previous trials^{16,21} but this may be attributed to inclusion of patients with recurrent disease in these trials.

The doublet (docetaxel/cisplatin) along with radiation had been tested in various trials. Hematological toxicity was most commonly reported adverse events,²²⁻²⁵ and we reported that grade 3-4 toxicities rates were similar to that is shown in previously published literature.

The magnitude of the survival benefit associated with CCRth was 8% at 5 years. However, long-term survival is currently poor; the disease-free survival rate is only 30-40 %.⁸ Very few CCRth regimens have undergone head-to-head comparison in randomized clinical trials. In our study, the 2y OS and PFS was higher than that was reported in previously trials.²⁶⁻²⁸ Furthermore, it has a longer OS when compared to using taxane^{29,30} or cisplatin as a single agent.²⁹

In conclusion, weekly docetaxel and cisplatin is an effective treatment program in locally advanced non-metastatic HNSCC with acceptable toxicities. There is warranty for multicenter randomized phase III trials to evaluate the impact of adding docetaxel to the standard CCRth regimen.

Conflict of interest: None

References

- Adelstein DJ, Li Y, Adams GL, *et al.* An intergroup phase III comparison of standard radiation therapy and two schedules of concurrent chemoradiotherapy in patients with unresectable squamous cell head and neck cancer. *Journal of clinical oncology: official journal of the American Society of Clinical Oncology*. Jan 1 2003;21(1):92-98.
- Denis F, Garaud P, Bardet E, *et al.* Final results of the 94-01 French Head and Neck Oncology and Radiotherapy Group randomized trial comparing radiotherapy alone with concomitant radiochemotherapy in advanced-stage oropharynx carcinoma. *Journal of clinical oncology: official journal of the American Society of Clinical Oncology*. Jan 1 2004;22(1):69-76.
- Glisson BS, Murphy BA, Frenette G, Khuri FR, Forastiere AA. Phase II Trial of docetaxel and cisplatin combination chemotherapy in patients with squamous cell carcinoma of the head and neck. *Journal of clinical oncology: official journal of the American Society of Clinical Oncology*. Mar 15 2002;20(6):1593-1599.
- Lefebvre JL, Chevalier D, Luboinski B, Kirkpatrick A, Collette L, Sahnoud T. Larynx preservation in pyriform sinus cancer: preliminary results of a European Organization for Research and Treatment of Cancer phase III trial. EORTC Head and Neck Cancer Cooperative Group. *Journal of the National Cancer Institute*. Jul 3 1996; 88(13):890-899.
- Seiwert TY, Cohen EE. State-of-the-art management of locally advanced head and neck cancer. *British journal of cancer*. Apr 25 2005;92(8):1341-1348.
- Forastiere AA, Goepfert H, Maor M, *et al.* Concurrent chemotherapy and radiotherapy for organ preservation in advanced laryngeal cancer. *The New England journal of medicine*. Nov 27 2003;349(22):2091-2098.
- Forastiere AA, Zhang Q, Weber RS, *et al.* Long-term results of RTOG 91-11: a comparison of three nonsurgical treatment strategies to preserve the larynx in patients with locally advanced larynx cancer. *Journal of clinical oncology: official journal of the American Society of Clinical Oncology*. Mar 1 2013;31(7):845-852.
- Pignon JP, le Maitre A, Maillard E, Bourhis J. Meta-analysis of chemotherapy in head and neck cancer (MACH-NC): an update on 93 randomised trials and 17,346 patients. *Radiotherapy and oncology: journal of the European Society for Therapeutic Radiology and Oncology*. Jul 2009;92(1):4-14.
- Schoffski P, Catimel G, Planting AS, *et al.* Docetaxel and cisplatin: an active regimen in patients with locally advanced, recurrent or metastatic squamous cell carcinoma of the head and neck. Results of a phase II study of the EORTC Early Clinical Studies Group. *Annals of oncology: official journal of the European Society for Medical Oncology / ESMO*. Jan 1999;10(1):119-122.
- Edge SB, Compton CC. The American Joint Committee on Cancer: the 7th edition of the AJCC cancer staging manual and the future of TNM. *Annals of surgical oncology*. Jun 2010;17(6):1471-1474.
- Eisenhauer E, Therasse P, Bogaerts J, *et al.* New response evaluation criteria in solid tumours: revised RECIST guideline (version 1.1). *European journal of cancer*. 2009;45(2):228-247.
- Cox DR. Regression Models and Life-Tables. *Journal of the Royal Statistical Society. Series B (Methodological)*. 1972;34(2):187-220.
- Guadagnolo BA, Haddad RI, Posner MR, *et al.* Organ preservation and treatment toxicity with induction chemotherapy followed by radiation therapy or chemoradiation for advanced laryngeal cancer. *American journal of clinical oncology*. Aug 2005;28(4):371-378.
- Hennequin C, Favaudon V. Biological basis for chemo-radiotherapy interactions. *European journal*

- of cancer (Oxford, England: 1990). Jan 2002;38(2):223-230.
15. Paccagnella A, Orlando A, Marchiori C, *et al.* Phase III trial of initial chemotherapy in stage III or IV head and neck cancers: a study by the Gruppo di Studio sui Tumori della Testa e del Collo. *Journal of the National Cancer Institute.* Feb 16 1994;86(4):265-272.
 16. Argiris A, Goldwasser M, Brockstein B, Axelrod R, Forastiere A. Weekly docetaxel (D) and irinotecan (I) in patients (pts) with recurrent or metastatic head and neck cancer (HNC): A phase II trial of the Eastern Cooperative Oncology Group (ECOG). Paper presented at: ASCO Annual Meeting Proceedings 2005.
 17. Axelrod R, Machtay M, Anne P, *et al.* Phase I study of weekly docetaxel (T), cisplatin (P) with daily celecoxib (C) and concurrent radiotherapy (RT) for patients with locally advanced head and neck cancer (HNC). Paper presented at: ASCO Annual Meeting Proceedings 2005.
 18. Haddad R, Tishler R, Wirth L, *et al.* Rate of complete pathological responses (pCR) to docetaxel/cisplatin/5-fluorouracil (TPF) induction chemotherapy in patients with newly diagnosed, locally advanced squamous cell carcinoma of the head and neck (SCCHN). Paper presented at: ASCO Annual Meeting Proceedings 2005.
 19. Kim E, Kies M, Sabichi A, *et al.* Phase II study of combination cisplatin, docetaxel and erlotinib in patients with metastatic/recurrent head and neck squamous cell carcinoma (HNSCC). Paper presented at: ASCO Annual Meeting Proceedings 2005.
 20. Smaradottir A, Siddiqi A, Ray C, Haider J, Azrin M, Hegde U. Increased incidence of cardiotoxicity after infusional 5-fluorouracil, cisplatin and docetaxel combination chemotherapy in patients with locally advanced head and neck cancer. Paper presented at: ASCO Annual Meeting Proceedings 2005.
 21. Baur M, Kienzer HR, Schweiger J, *et al.* Docetaxel/cisplatin as first-line chemotherapy in patients with head and neck carcinoma: a phase II trial. *Cancer.* Jun 1 2002;94(11):2953-2958.
 22. Airolidi M, Cattel L, Cortesina G, *et al.* Docetaxel, carboplatin and concomitant radiotherapy for unresectable squamous cell carcinoma of the head and neck: pharmacokinetic and clinical data of a phase I-II study. *American journal of clinical oncology.* Apr 2004;27(2):155-163.
 23. Hambek M, Baghi M, Strebhardt K, Baumann H, Gstottner W, Knecht R. Reduction of cisplatin dosage by ZD 1839. *Anticancer research.* Nov-Dec 2005;25(6B):3985-3988.
 24. Magne N, Fischel JL, Tiffon C, *et al.* Molecular mechanisms underlying the interaction between ZD1839 ('Iressa') and cisplatin/5-fluorouracil. *British journal of cancer.* Aug 4 2003;89(3):585-592.
 25. Schwartz DL, Montgomery RB, Yueh B, *et al.* Phase I and initial phase II results from a trial investigating weekly docetaxel and carboplatin given neoadjuvantly and then concurrently with concomitant boost radiotherapy for locally advanced squamous cell carcinoma of the head and neck. *Cancer.* Jun 15 2005;103(12):2534-2543.
 26. Baykara M, Buyukberber S, Ozturk B, *et al.* Efficacy and safety of concomitant chemoradiotherapy with cisplatin and docetaxel in patients with locally advanced squamous cell head and neck cancers. *Asian Pacific journal of cancer prevention: APJCP.* 2013;14(4):2557-2561.
 27. Chitapanarux I, Lorvidhaya V, Tharavichitkul E, *et al.* A phase II study of docetaxel and carboplatin with concurrent radiation therapy for locally advanced head and neck cancer. *Auris, nasus, larynx.* Feb 2011;38(1):108-113.
 28. Tsao AS, Garden AS, Kies MS, *et al.* Phase I/II study of docetaxel, cisplatin, and concomitant boost radiation for locally advanced squamous cell cancer of the head and neck. *Journal of clinical oncology: official journal of the American Society of Clinical Oncology.* Sep 1 2006;24(25):4163-4169.
 29. Essa HH, Azzam M. Concurrent chemoradiation in locally advanced head and neck cancers: a comparative study of weekly Paclitaxel versus Cisplatin-based regimen. *Journal of the Egyptian National Cancer Institute.* Sep 2010;22(3):165-173.
 30. Pergolizzi S, Santacaterina A, Adamo B, *et al.* Induction chemotherapy with paclitaxel and cisplatin to concurrent radiotherapy and weekly paclitaxel in the treatment of loco-regionally advanced, stage IV (M0), head and neck squamous cell carcinoma. Mature results of a prospective study. *Radiation oncology (London, England).* 2011;6:162.