

Prognostic Value of Doppler Perfusion Index in Early Colorectal Cancer for Adjuvant Chemotherapy

Ahmad Alhosainy¹, Ahmed Z Alattar¹, Abd Elmotaleb Mohamed¹, Inas M. Elfiki², Jihan A. Shawky³ and Abd Elhafez M. Elsheweal⁴

¹Clinical Oncology & Nuclear Medicine, ² Radiology, ³ Tropical Medicine, and ⁴ General Surgery Departments, Faculty of Medicine, Zagazig University, Zagazig, Egypt
ahmedenbedo@hotmail.com

Abstract: Objective: Until now there is no clear recommendation for the application of adjuvant chemotherapy in patients with colorectal cancer stage Dukes A, despite undergoing apparently curative resection, are at high risk of recurrence. We assessed whether the doppler perfusion index (DPI; ratio of hepatic arterial to total liver blood flow) could be used to select patients who should receive adjuvant chemotherapy. **Aim:** to assess the value of DPI for selecting patients with early stage colorectal cancer undergoing curative surgery to receive adjuvant chemotherapy. **Patients and methods:** fifty patients (40 males and 10 females, median age 61, range 23-68) undergoing apparently curative surgery for colorectal cancer were staged using Dukes' classification. In addition, DPI was measured before surgery by means of a duplex/color Doppler sonography. A DPI value of at least 0.3 was defined as abnormal. After surgery patients were followed up for recurrences every three months for 3 years. **Results:** patients with normal DPI had recurrence-free survival of 80% and overall survival of 85%, compared with 43.3% and 60% for those with abnormal DPI values. **Conclusion:** we conclude that; DPI can be used to identify patients with early stage colorectal cancer at high risk of recurrence who are in need for adjuvant treatment

[Ahmad Alhosainy, Ahmed Z. Alattar, Abd Elmotaleb Mohamed, Inas M. Elfiki, Jihan A. Shawky, and Abd Elhafez M. Elsheweal. **Value of Doppler Perfusion Index in Early Colorectal Cancer for Adjuvant Chemotherapy.** *Cancer Biology* 2015;5(4):68-75]. (ISSN: 2150-1041). <http://www.cancerbio.net>. 8. doi:[10.7537/marscbj050415.08](https://doi.org/10.7537/marscbj050415.08).

Key words: DPI, colorectal cancer, Dukes' stage A and B.

1. Introduction:

According to epidemiological research, the main cause of death of patients with colorectal cancer is liver metastases (1). It is well known that approximately 25% of patients with colorectal cancer already have liver metastases, and another 25% of patients develop liver metastases during follow up, usually within the first 2 years after the diagnosis of the primary colorectal tumor (2, 3). Adjuvant chemotherapy (5-fluorouracil with levamisole or 5-fluorouracil with folinic acid) leads to a 40% reduction in the rate of recurrence and metastases, and 33% reduction in mortality rates of patients with Dukes C colon cancer (4,5). Despite that, approximately one third of patients with Dukes C colon cancer will survive 5 years even without adjuvant chemotherapy. On the other hand, approximately 30% of patients with Dukes B colon cancer will develop progressive disease. However, the clear recommendation for the application of adjuvant chemotherapy in patients with colorectal cancer stage Dukes B is not well established (6) The sensitivity of imaging methods for detection of lesions smaller than 1cm is in the region of 50% when surgery and intraoperative ultrasound are used as the gold standard, but the accuracy of this reference standard itself cannot be established (7,8). A standard prognostic factor that is used routinely in selecting patients for adjuvant treatment is the Dukes classification of the primary

colorectal cancer (9).

The survival of patients with Dukes C stage and a part of patients with Dukes B stage can be improved by the application of adjuvant chemotherapy after potentially curative surgical resection (10). Unfortunately, the early detection of these occult metastases is beyond the resolution of conventional imaging methods. Current imaging techniques can reliably demonstrate metastases of 1cm or larger using super-paramagnetic iron oxide (SPIO)- enhanced MRI and multidetector CT. Alternative techniques are therefore required (11). One approach proposed to detect occult metastases is based on the alteration in liver blood flow that develops with metastatic seeding in the liver. The ratio of hepatic arterial to total liver blood flow (hepatic perfusion index, HPI), was first investigated using dynamic scintigraphy, and found to be abnormal in 94% of patients with colorectal liver metastases (12). Furthermore, of those patients who developed liver metastases within 3 years of their original primary resection, 87% had an abnormal HPI at presentation (9). The methodology developed for measurement of HPI with scintigraphy was adopted for use with dynamic CT, with similar results (13, 14). With color duplex Doppler ultrasonography, Leen *et al.* (9, 13) reported that liver metastases are associated with an increased ratio of hepatic arterial to total liver blood flow (DPI), which suggests that measurement of changes in liver blood flow could be used to detect the

presence of occult metastases.

The aim of the present study was to correlate changes in DPI in patients who were undergoing potentially curative surgery for early stage colorectal cancer, and thereby assessed its value as a method for the selection of patients who should receive adjuvant chemotherapy

2. Patients and Methods

This study was conducted in, Tropical Medicine, Radiology, Clinical Oncology & Nuclear Medicine and Surgery departments, faculty of medicine, Zagazig University hospitals, at the period from May 2008 to June 2011.

Informed consent was obtained from all patients throughout the whole study

Fifty patients (40 males and 10 females, mean age 61 years, range 23-68 years) with resectable colorectal cancer were studied, Patients characteristics are shown in table(1). All patients were proven histopathologically to have colorectal cancer from colonoscopic biopsy done at Tropical Medicine Department. Baseline computed tomography (CT), liver ultrasonography, and doppler perfusion index (DPI) measurements were done before surgery. After surgery, Dukes' stage was determined for all patients on the basis of histology of the resected primary tumor and lymph nodes. Dukes' stage A correspond to tumor confined to mucosa; stage B, tumor had invaded muscle; stage C, lymph node metastases were present. The patients who had undergone potentially curative surgery, none of whom received adjuvant treatment, in Clinical Oncology Department were followed-up every three months for 3 years.

Scanning technique: Dynamic contrast enhanced CT scans was done using General Electric Medical System (Hi-Speed), after bolus intravenous injection of 100-150 mL of nonionic contrast media using automatic injector at a rate of 2 mL/sec. Scanning began 30-45 s after bolus injection and the entire liver was scanned within 3-4 min. scanning is done in 10 mm slice thickness in adjacent slice sequence starting above dome of the right diaphragmatic cupula till below right lobe of the liver. Doppler perfusion index measurements was done with a color duplex Doppler scanner (Toshiba Nemio 5) using 3.5 MHz convex phased array probe. Fasting patients were examined in supine position. A transverse scan of the epigastrium was done to locate the common hepatic artery in longitudinal axis. The Doppler cursor was placed over the lumen of the common hepatic artery segment as near to its origin as possible at the point it first became horizontally straight. The Doppler sample volume and Doppler beam angle were adjusted and time-average velocity was calculated over four cardiac cycles. The cross-sectional area of the artery was measured at the same point by mapping the perimeter of the lumen at

right angle to the vessel. The time-averaged cross-sectional area was calculated by taking mean of areas measured separately over the four cardiac cycles. The same parameters were obtained for the portal vein in a similar manner. Measurements were from as near to the origin of the vessel as possible. All measurements were done under respiratory suspension in expiration to allow optimal visualization of the portal vein and to enable a more acute angle to be achieved for Doppler purposes. Each measurement was performed repeatedly until satisfactory spectral patterns were obtained. Overall the procedure took about 25-30 minutes. Hepatic arterial and portal venous blood flows were calculated from the product of velocity averaged over time and cross-sectional area of the vessel.

The ratio of the common hepatic arterial to portal venous blood flow was calculated and termed the Doppler flow ratio (DFR). While the Doppler Perfusion Index (DPI) was calculated as the ratio of hepatic arterial blood flow to the sum of the hepatic arterial and portal venous blood flows. DPI values of 0.30 and higher were defined as abnormal on the basis of previous studies that assessed DPI in the healthy control volunteers and patients with overt colorectal hepatic metastases (upper limited of normal range 0.26) ⁽¹¹⁾.

Statistical analysis: The statistical analysis was performed after importing the perfusion data into SPSS version .10.1 for windows (SPSS Inc., Chicago, IL). Recurrence-free and overall survival curves were generated by the Kaplan-Meier method and compared with the log rank test. Multivariate survival analysis was done with Cox regression with forward stepwise variable selection. A P value of 0.05 or less was defined as significant

3. Results

Fifty patients who underwent potentially curative resection and pathologically classified as Dukes' stage A and B. Of whom 15 patients (30 %) had developed treatment failure in the form of local recurrence and distant metastases (Table 2). The 3-year recurrence-free survival of patients with Dukes' stage A and B tumors was 38% and 20. % respectively. The 3-year overall survival 79.2% and 60.3% in patients with Dukes stage A and B respectively (Fig. 1). The variation in recurrence-free and overall survival with Dukes' stage was significant ($P = 0.021$ and $P = 0.008$, respectively). Twenty (40%) patients had normal DPI values (< 0.30), while thirty (60%) patients had abnormally raised DPI values (≥ 0.3). There was a significant association between DPI status and Dukes' stage ($P = 0.006$, Fisher's exact test), but none between DPI status and age, sex, or site of primary tumor. Of the 20 patients with normal DPI, three (15 %) had recurrent disease, and two of these patients

died. One patient also died with no evidence of recurrence. Sixteen (80 %) patients were alive and disease-free at 3-years. By contrast, of the 30 patients with abnormal DPI, 12 (40%) patients developed recurrent disease, of whom 7 died, and five patients died with no evidence of recurrence. Thirteen (43.3%) patients were alive and disease free at 3-years.

The 3-year recurrence-free survival was 80% in patients with normal DPI values versus 43.3 % in patients with abnormal DPI values (Fig. 2). While, it was 72.7% and 66.7% for Dukes stages A and B patients with normal DPI values versus 40% and 10% for Dukes stages A and B patients with abnormal DPI values.

The 3-year overall survival was n=17 patients (85%) in patients with normal DPI values and n=18 patients (60%) in patients with abnormal DPI values.

While, it was 90.9% and 77.8% for Dukes stages A and B patients with normal DPI values versus 70% and

55% for Dukes stages A and B patients with abnormal DPI value (Fig.3). The variation in recurrence-free and overall survival with DPI status was significant ($P < 0.05$) in both cases.

The sensitivity, specificity, positive and negative predictive values, and accuracy of DPI technique in identifying recurrence were 94%, 68%, 71%, 93% and 80% respectively.

The distribution of recurrence and death in patients grouped by DPI status and Dukes' stage is shown in table (3). In pairwise comparisons of the four groups by DPI status and Dukes' stage, the dependence of recurrence-free and overall survival on DPI status was significant ($P = 0.001$) (Figs.4, 5, 6, 7).

In multivariate analysis, which include age, sex, primary tumor site, Dukes' stage, and DPI status as covarities, only DPI status had independent prognostic significance ($P < 0.003$) for recurrence-free and overall survival.

Table (1) Patients characteristics:

Characteristic	Number (50 patients)	%
Sex		
Male	40	80
Female	10	20
Age		
Median (range in years)	61 (23-68)	
Histological diagnosis		
Adenocarcinoma	38	76
Mucinous	9	18
Signet ring	3	6
Primary site		
Colon	35	70
Rectum	15	30
Dukes' stage		
A	20	40
B	30	60

Table (2) Patterns of treatment failure:

Pattern	Number of patients with recurrent disease (15)	
	No	%
Distant metastases:		
Liver metastases alone	8	53.3
Liver and lung metastases	2	13.3
Local recurrence	3	20
Distant and local failure	2	13.3

Table (3): Recurrences, and deaths in patients, by DPI status, and Dukes' stage.

	Number of patients	Recurrences		Deaths		Recurrence-free survival (%)	Overall survival (%)
		No	%	No	%		
Normal DPI						16 (80%)	17 (85%)
Dukes' stage A	11	2	18.2	1	9.1	72.7	90.9
Dukes' stage B	9	1	11.1	2	22	66.7	77.8
Abnormal DPI						13 (43.3%)	18 (60%)
Dukes' Stage A	10	3	30	3	30	40	70
Dukes' Stage B	20	9	45	9	45	10	55

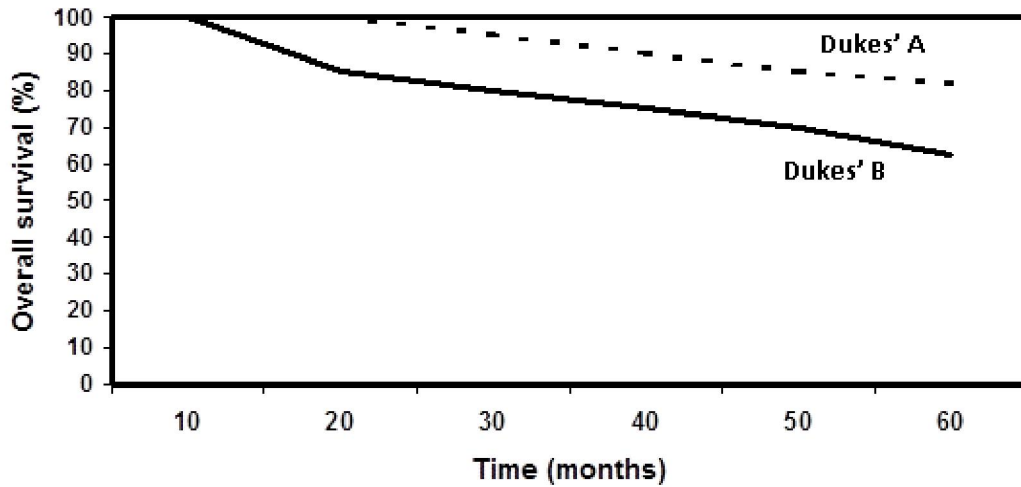


Fig. (1): Overall survival in patients by Dukes' stage.

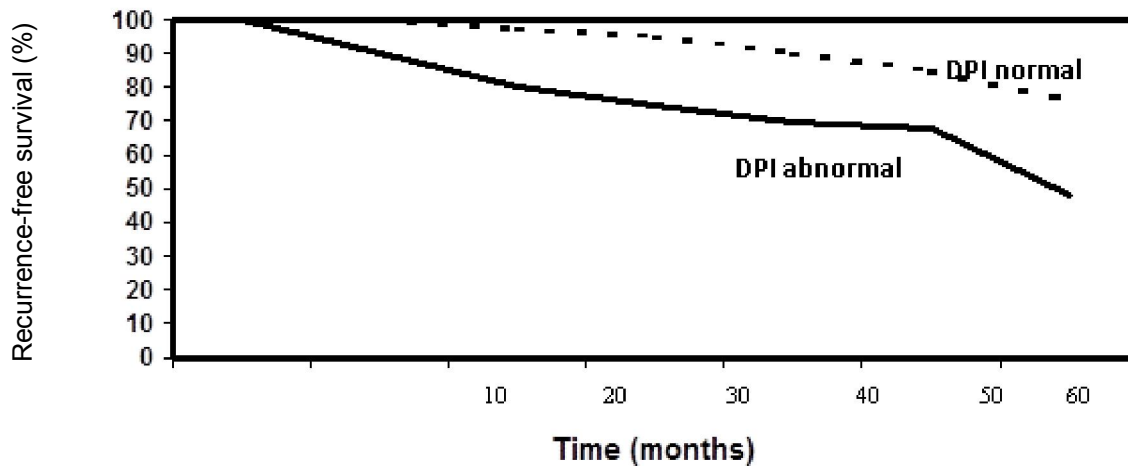


Fig. (2): Recurrence-free survival in patients by DPI status

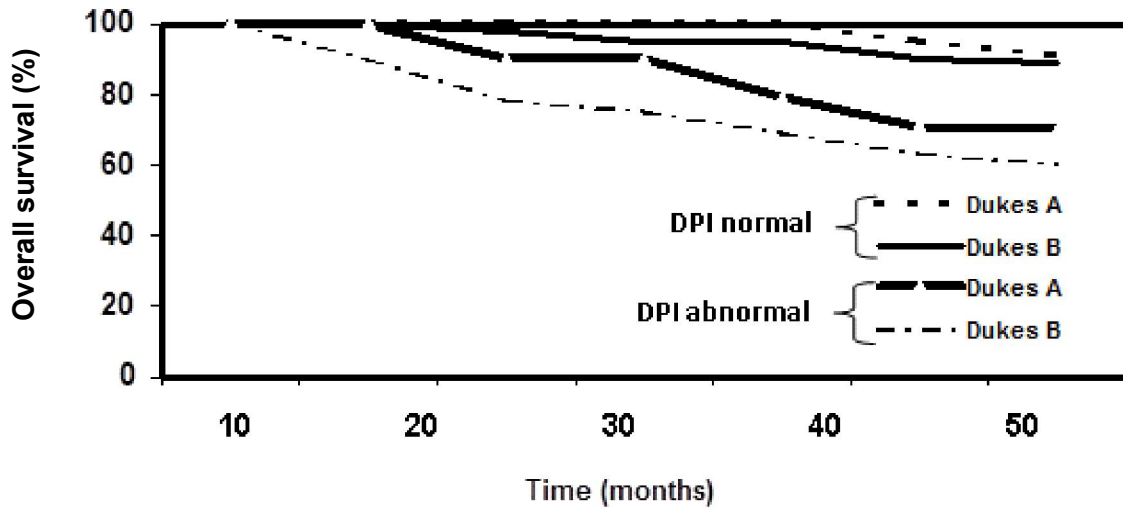


Fig. (3): Overall survival in patients by DPI status and Dukes' stage.

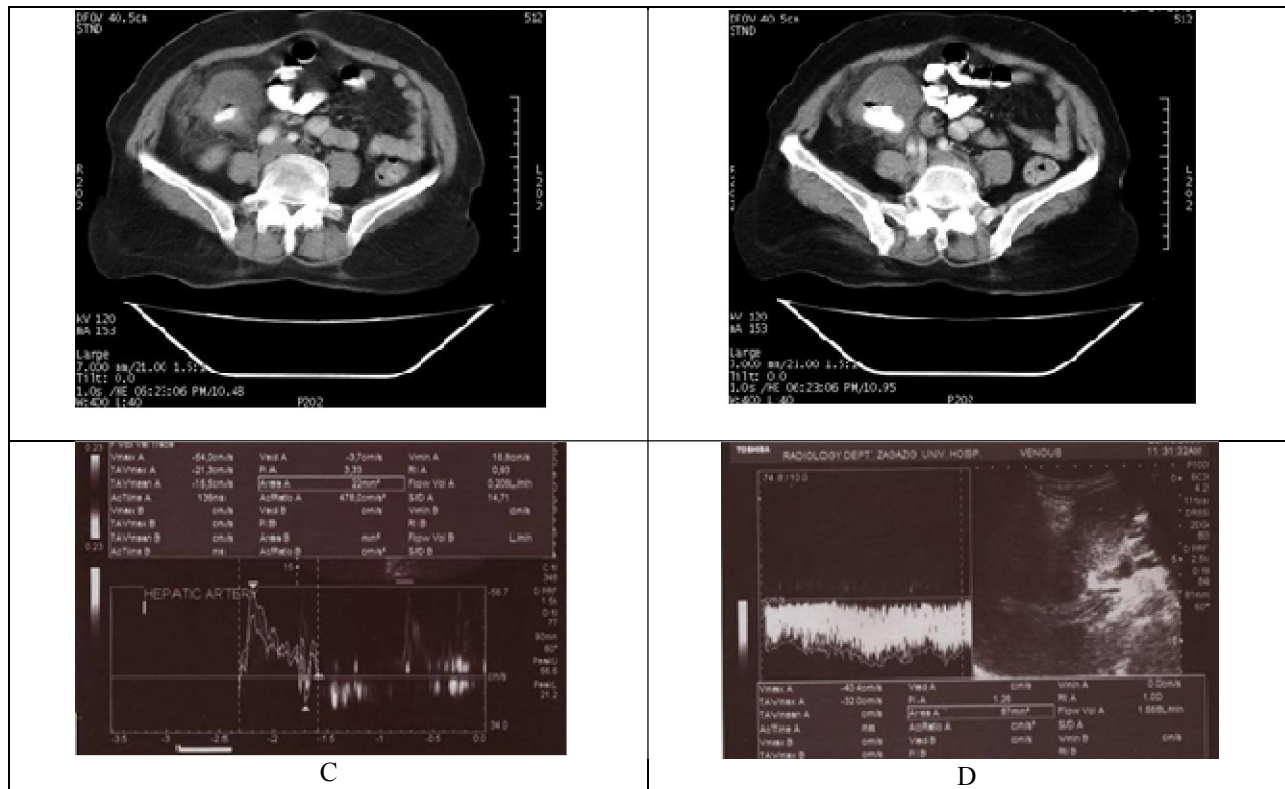


Fig. (4): A case with right colonic cancer (caecal) A & B: contrast enhanced CT examination with caecal mass encircling colonic wall all around. C & D are hepatic artery and portal vein Doppler study with normal calculated Doppler Perfusion Index (DPI). Follow up CT examination (not included) showed no evidence of local or distant metastasis.

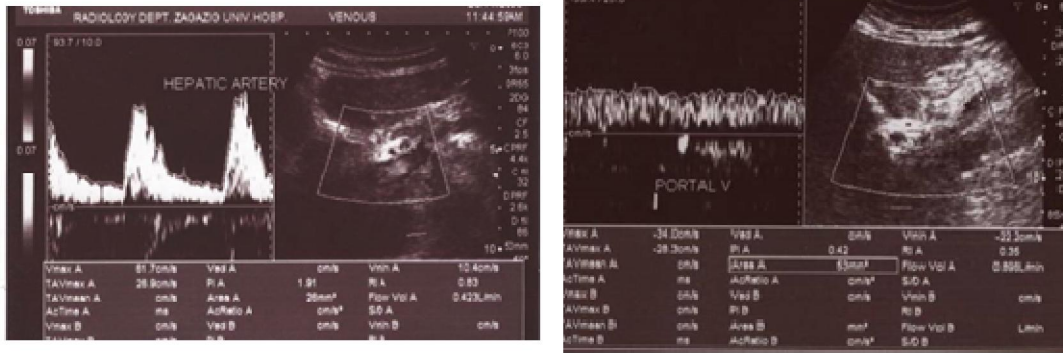


Fig. (5)
0.320

dex is

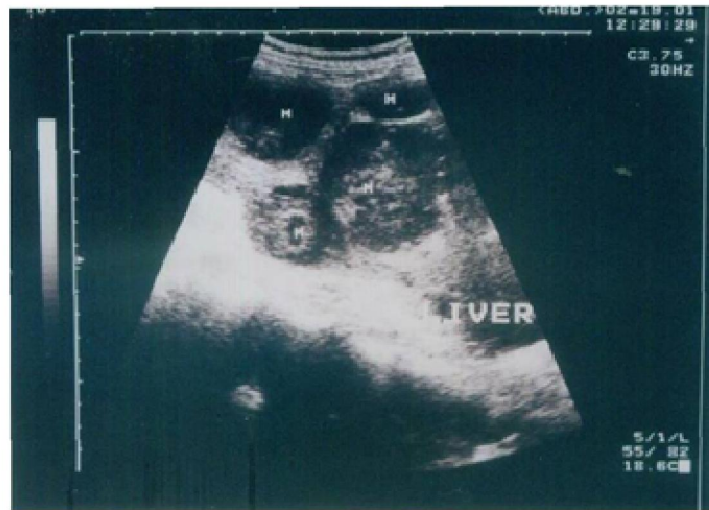
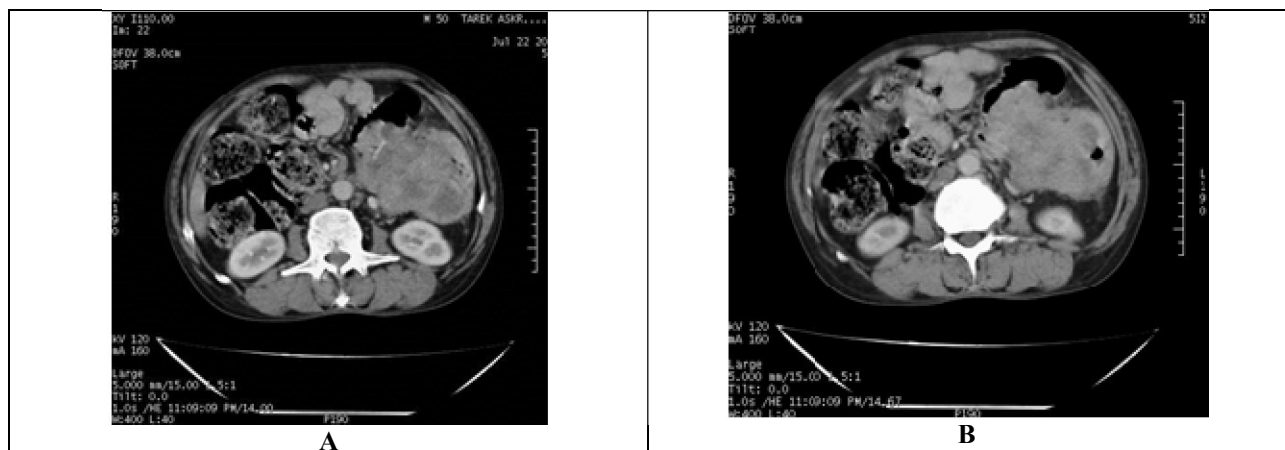


Fig. (6)
variabl

tipte



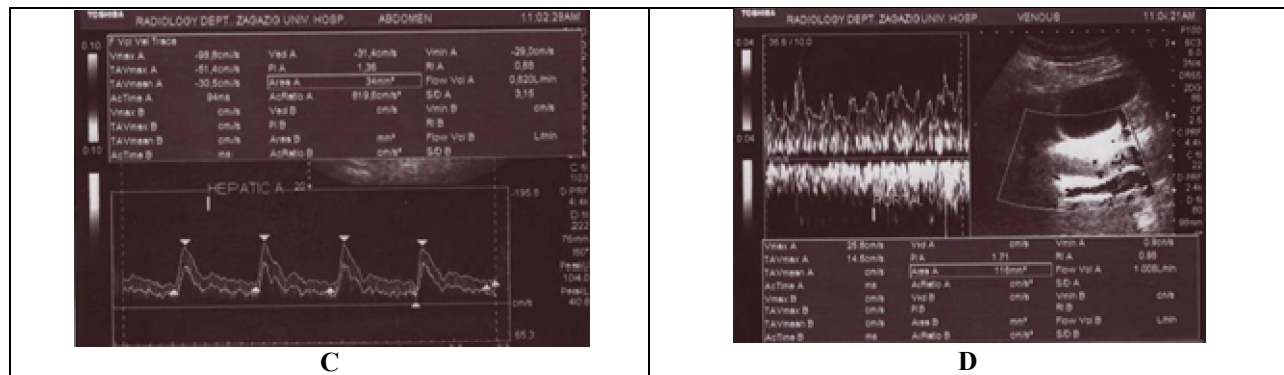


Fig. (7): A case with left colonic cancer, A & B: contrast enhanced CT examination showing large left colonic mass obstructing descending colon with proximal dilatation. C & D are hepatic artery and portal vein Doppler study with the calculated Doppler Perfusion Index (DPI) measuring about 0.381 (increased). Follow up CT examination 1 year later (not included) showed local recurrence and liver metastases.

4. Discussion

The presence of micro metastases in early stage colorectal cancer might have prognostic value. Detection of micro metastases could aid the selection of patients for adjuvant systemic chemotherapy^(1,15). Patients with detectable micro-metastases could be considered for adjuvant chemotherapy. This approach is currently not the standard treatment for Dukes' stage A and B colorectal cancer but, controversially, some oncologists do offer it^(1, 15). However, without treatment about one third of patients with Dukes' stage A and B tumor will have recurrent disease, but are generally denied chemotherapy. Therefore, the current criteria that determine the selection of patients with colorectal cancer for chemotherapy require re-evaluation⁽¹⁵⁾. The prognostic indicators commonly used in clinical practice are limited in this respect. Although Dukes' stage has been the most widely used, it provides only a probability of survival for any given stage⁽¹⁶⁾. In our study, Dukes' stage failed to clearly define those patients at risk of early recurrence, 18.1% of patients with Dukes' stage A and 11.1% of patients with Dukes' stage B had recurrent disease.

By contrast, DPI values accurately predicted outcome over 3 years. Only 40% of Dukes' stage A and 10% of Dukes' stage B patients with an abnormally raised DPI value remained disease-free compared with 72.7% of Dukes' A and 66.7% of Dukes' stage B patients with normal DPI value (both $P < 0.005$). The 3-year overall survival rates were 90.9% for Dukes stage A and 77.8% for Dukes stage B patients with normal DPI, compared to 70% and 55% for Dukes stages A and B patients with abnormal DPI values.

These results are comparable to the results reported by **Leen et al.**⁽⁹⁾, who concluded that patients with normal DPI had recurrence-free survival of 89% and overall survival of 91%, compared with 22% and 29% for those with abnormal DPI values (both $P < 0.001$). Furthermore, in this study, patients with normal DPI

status have a good outcome irrespective of Dukes' stage. Similarly, those with abnormally raised DPI values have a poor prognosis irrespective of Dukes' stage. DPI can accurately predict recurrence after potentially curative surgery for colorectal cancer. Furthermore, DPI is more sensitive than conventional imaging techniques^(9,11). There are, however, potential pitfalls associated with the technique, including variation of hepatic arterial anatomy, which are present in about 30% of patients^(2, 16). Only some of these variations may affect the measurement of DPI. Specifically, if there is a dual arterial supply or an accessory artery, hepatic arterial flow and hence DPI maybe underestimated. A small proportion of patients with normal DPI might therefore be wrongly assumed to have no occult metastases^(17, 18). However, not all authors were able to prove the clinical usefulness of DPI measurement in the detection of liver metastasis. In a clinical study conducted by Roumen *et al.*⁽¹⁹⁾, 133 patients with different stages of colorectal cancer were examined. Reliable DPI measurements were not possible in 29 patients, mostly due to technical difficulties caused by the presence of air or other contrast media, obesity, scars or other reasons. In their study, they were unable to detect a single cut-off value that could reliably discriminate patients with liver metastases. It has to be noted that in this study no pre-selection of patients was performed and the focus was placed on the clinical usefulness of Doppler measurements in unselected population of patients. DPI measurement might also be affected by the presence of liver cirrhosis, which may lead to changes in liver blood flow. However, although DPI is also abnormally raised in the presence of cirrhosis, the haemo-dynamic changes could be clearly differentiated by the measurement of portal-vein congestive index (ratio of portal-vein cross sectional area to velocity averaged over time) which is only raised in cirrhotic patients^(17, 18). In this study, the sensitivity, specificity, and

accuracy of DPI technique in identifying recurrence were 94%, 68% and 80% respectively, which are comparable to the results reported by **Leen *et al.*** ⁽⁹⁾. Who reported a sensitivity, specificity and accuracy of 95%, 69% and 81% respectively. In conclusion, DPI can be used to identify patients with colorectal cancer at high risk of recurrence who are in need of adjuvant treatment. This technique has the potential to provide a valuable methods for early detection of “occult lesions”. However, further studies with larger number of patients are needed to confirm these findings.

References

1. Boyle P, Langman JS. ABC of colorectal cancer: Epidemiology. *BMJ* 2000;321:805-8.
2. Kopljar M, Brkljacic B, Doko M, et al. Nature of Doppler perfusion index changes in patients with colorectal cancer liver metastases. *J Ultrasound Med* 2004;23:1295-300.
3. Milas J, Samardzić S, Miskulin M. Neoplasms (C00-D48) in Osijek-Baranja County from 2001 to 2006, Croatia. *Coll Antropol* 2013;37:1209-22
4. Samardzić S, Mihaljević S, Dmitrović B, *et al.* First six years of implementing colorectal cancer screening in the Osijek-Baranja County, Croatia--can we do better? *Coll Antropol* 2013;37:913-8.
5. Moertel CG, Fleming TR, Macdonald JS, et al. Fluorouracil plus levamisole as effective adjuvant therapy after resection of stage III colon carcinoma: a final report. *Ann Intern Med* 1995;122:321-6.
6. Doko M, Zovak M, Ledinsky M, *et al.* Safety of simultaneous resections of colorectal cancer and liver metastases. *Coll Antropol* 2000;24:381-90
7. Kopljar M, Brkljacic B, Doko M, *et al.* Nature of Doppler perfusion index changes in patients with colorectal cancer liver metastases. *J Ultrasound Med* 2004;23:1295-300.
8. Totman JJ, O’Gorman, Kane PA *et al.* Comparison of the hepatic perfusion index measured with gadolinium-enhanced volumetric MRI in controls and in patients with colorectal cancer. *Br. J. Radiol* 2005: 78, 105-109.
9. Leen E, Goldberg JA, Angerson WJ, *et al.* Potential role of doppler perfusion index in selection of patients with colorectal cancer for adjuvant chemotherapy. *Lancet* 2000; 355:34-7.
10. Akhurst T, Kates TJ, Mazumdar M, *et al.* Recent chemotherapy reduces the sensitivity of [18F]fluorodeoxyglucose positron emission tomography in the detection of colorectal metastases. *J Clin Oncol* 2005; 23:8713-6.
11. Harvey C and Biomley M. Imaging investigation of liver haemodynamics in patients at risk for hepatic metastatic disease. *Br. J. Radiol.*, February 1, 2005; 78 (926): 103-104.
12. Parkin A, Goldstone KE and Robinson PJ. Hepatic perfusion index measured using MRI and scintigraphy *Br. J. Radiol.*, December 1, 2005; 78 (936): 1118-1118.
13. White MJ, O’Gorman RL, Charles-Edwards EM, *et al.* Parametric mapping of the hepatic perfusion index with gadolinium-enhanced volumetric MRI. *Br. J. Radiol.*, February 1, 2007; 80 (950): 113-120.
14. Lee VS, Lavelle MT, Rofsky NM, Laub G, Thomasson DM, Krinsky GA, *et al.* Hepatic MR imaging with dynamic contrast enhanced isotropic volumetric breath hold examination: feasibility, reproducibility and technical quality. *Radiology* 2000; 215: 365-72.
15. Anton B, Better detection of colon cancer micrometastases, *Ann Surg* 2007; 246: 568-77.
16. Benson AB, Shrag D, Sorrerfield MR et al. American Society of Clinical Oncology recommendation on adjuvant chemotherapy for stage II colon cancer. *J. Clin Oncology* 2004; 22: 3408-3419.
17. Totman JJ, O’Gorman, Kane PA *et al.* Comparison of the hepatic perfusion index measured with gadolinium-enhanced volumetric MRI in controls and in patients with colorectal cancer. *Br. J. Radiol* 2005: 78, 105-109.
18. Parkin A, Goldstone KE and Robinson PJ. Hepatic perfusion index measured using MRI and scintigraphy *Br. J. Radiol.*, December 1, 2005; 78 (936): 1118-1118.
19. Roumen RM, Scheltinga MR, Slooter GD, et al. Doppler perfusion index fails to predict the presence of occult hepatic colorectal metastases. *Eur J Surg Oncol* 2005;31:521-7.

12/08/2015