

Retention versus Removal of pectoralis minor in Axillary surgery for breast cancer

Ali Zedan, Haisam Atta², Adel gabr³ and Tareq Salah⁴

¹Department of Surgical Oncology, South Egypt Cancer Institute (SECI), Assiut University, Egypt.

²Department of Radiology/Oncoradiology, South Egypt Cancer Institute (SECI), Assiut University, Egypt.

³Department of Medical Oncology, South Egypt Cancer Institute (SECI), Assiut University, Egypt.

⁴Department of Clinical Oncology, Faculty of Medicine, Assiut University, Egypt.

Abstract: Background and Objectives: There has been a gradual shift away from radical surgery towards conservation treatment, for breast cancer. The pectoralis minor muscle is increasingly preserved in women undergoing axillary clearance as part of either breast conservation or mastectomy. We compare Retention versus Removal of pectoralis minor **Patients and methods:** A retrospective study of 278 patients who underwent axillary clearance, 86 with (Removed Group) and 192 who had the muscle preserved (Retained Group,) operated in South Egypt Cancer Institute, Assiut University in the period from January 2005 to January 2010. Study was aiming at evaluation of operative blood loss, operative time, Immediate post operative complication, functional impairment, Atrophy and fibrosis of pectoralis major muscle, pain, neuralgia, paraesthesia, decreased range of motion of the arm or shoulder, wound infection, Seroma formation, lymphedema of the arm, 5-years relapse free survival (*RFS*), cancer specific survival (*CSS*), Recurrence rates. **Results:** Similar Tumour size and type in the two groups. operative time of axillary dissection (37 in Removed Group vs. 33 minutes in Retained Group ($P=0.07$)). The mean operative blood loss was 220mL Removed Group vs 140mL in Retained Group. breast-conserving surgery (63% Retained Group v 57% Removed Group. *CSS*, *RFS*, was 89.7% and 80.8%, respectively in Removed Group. Retained Group it was 84.5% and 78.7%., wound infection (3.48%) in Removed Group and (6.77%) in Retained Group. Incidences of seroma (5.8%) in Removed Group, and (5.2%) in Retained Group ($p<0.02$) the Retained Group, ROM of the shoulder (45.34%) in Removed Group and (44.27%) in Retained Group, paresthesia (33.72%) in Removed Group and (30.73%) in Retained Group, and lymphedema (4.65%) in Removed Group and (3.13%) in Retained Group, partial atrophy and fibrosis of the pectoralis major muscle in (8.14%) of Removed Group vs (4.27%) in Retained Group. locoregional recurrence (1.16%) in Removed Group and (1.04%) in Retained Group ($P = 0.19$). The mean total number of nodes 16 in Removed Group and 15 in Retained Group. **Conclusion** For the majority of patients with operable breast cancer, retention of the pectoralis minor muscle is not associated with under staging or under treatment of the axilla.

[Ali Zedan, Haisam Atta, Adel gabr and Tareq Salah. **Retention versus Removal of pectoralis minor in Axillary surgery for breast cancer.** *Cancer Biology* 2015;5(3):178-184]. (ISSN: 2150-1041). <http://www.cancerbio.net>. 15. doi:[10.7537/marscbj050315.15](https://doi.org/10.7537/marscbj050315.15).

Keywords: Breast cancer, pectoralis minor, Axillary surgery

1. Introduction

Breast cancer is the most common cancer. Modified radical mastectomy can remove axillary lymph nodes as completely as radical mastectomy [1]. Complete axillary dissection has been an integral component as the gold standard practice since it is both a staging and a therapeutic intervention. Decreasing locoregional relapse and mortality rates, possibility of an accurate adjuvant systemic treatment planning, and improved survival rates [2,3,4,5,6,7]. Over the years the surgical management of the primary tumor in localized breast cancer has become less extensive and less mutilating. corresponding decrease in morbidity. surgical management of axilla changed from routine axillary dissection to sentinel lymph node biopsy with the development of effective systemic therapy and improvement in diagnostic tools [4,5,8,9] axillary lymph node dissection (ALND). associated with a decrease in quality of life and significant

morbidity namely postoperative pain, arm lymphoedema and restriction of shoulder movement. [10] which reduced if the pectoralis minor muscle is not excised., the pectoralis minor muscle was invariably sacrificed. With experience it was appreciated that the muscle could be retracted, without division of the nerve and blood supply, enabling a level III clearance. Since 1990 it has been usual to preserve the pectoralis muscle [11]. Procedures commonly used include the resection of the pectoralis minor muscle and/or pectoralis nerves. the pectoralis minor muscle is cut off close to its attachment to the coracoid process, and an axillary dissection is thereby easily and thoroughly accomplished [13]. Since 1984 performed axillary dissection has been done by sparing both the pectoralis muscles and their nerves [14] and has been appreciated cosmetic and functional advantages with equal satisfactory results [13], maintained the normal anatomy and function of the

shoulder[15]. Lymphatics from the breast pass only in the fascia encircling the surface of the muscles and not in the muscles themselves strips the covering fascia from the pectoral muscles, [16]

2. Patients and methods

A retrospective study was conducted in 278 patients who underwent axillary clearance, 86 with removal of pectoralis minor (Removed Group) and 192 who had the muscle preserved (Retained Group,), South Egypt Cancer Institute, Assuit University, from January 2005 to January 2010.

All patients underwent breast-conserving surgery or mastectomy as necessary based on tumor

characteristics, surgeon recommendation, and patient choice. operative blood loss, operative time, Immediate post operative complication, functional impairment, Atrophy and fibrosis of pectoralis major muscle, pain, neuralgia, paraesthesia, decreased range of motion of the arm or shoulder, Paresthesia was defined as numbness that was subjectively reported by patients. Decreased range of motion of the ipsilateral shoulder as compared to the contraletaral shoulder was defined as reduced abduction., wound complication/infection, lymphedema of the arm, quantity or duration of serum draning from the axilla, 5-years overall survival and disease free survival *RFS*, *CSS*, Local Recurrence.

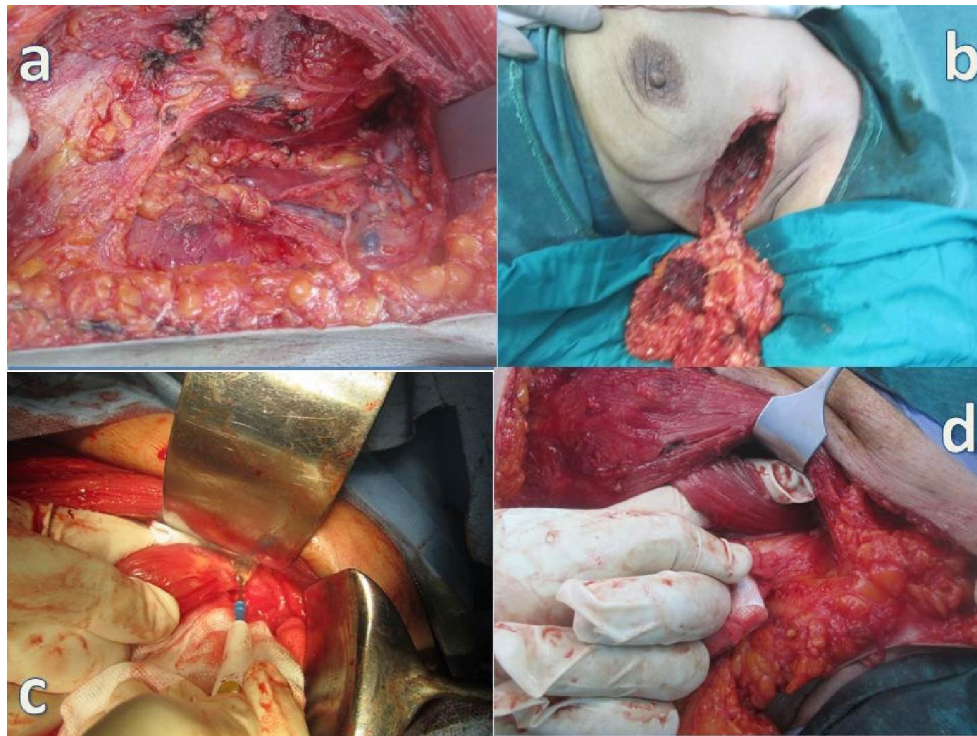


Figure (1): *a]* Axillary clearance pectoralis minor muscle removed. *b]* Breast conservation, sacrificed pectoralis minor muscle. *c]* Pectoralis minor muscles served near its attachment to the coracoid process. *d]* preservation of pectoralis minor in axillary clearance.

The axillary vein was identified and all fatty and lymphatic tissue was removed inferior to the axillary vein, between the anterior border of latissimusdorsi muscle laterally and the lateral border of the pectoralis minor muscle (level of first rib) medially excising the pectoralis minor muscle severed near its attachment to the coracoid process, and the deep pectoral fascia covering the axillary structures are opened in Removed Group and preserve retracting the pectoralis major muscle mobilization and swinging of the pectoralis minor into different directions by means of a sling to facilitate Axillary Nodal Dissection at selected levels. in the Retained Group. To

enable the pathologist to establish the level of the nodes, axillary lymph nodes are divided into three levels using the pectoralis minor as a landmark. Level I, or low axillary nodes, includes nodes located lateral and inferior to the pectoralis minor sign by prolins sutures,. Level II, or mid axillary nodes, includes nodes located beneath the pectoralis minor silk sutures. Level III, or high axillary nodes, includes nodes located medial and superior to the upper medial edge of the pectoralis minor. Level III nodes are also referred to as subclavicular or infraclavicular vicryl sutures. the number of lymph nodes / proportion of positive nodes at each level was

counted, the entire mammary gland is removed with pectoral fascia. Between the two pectoral muscles, the interpectoral fat pad is dissected from neurovascular supply to the pectoralis major. Written informed consent was obtained from all the participants and the study had full ethical approval by the Institutional Review Boards Patients underwent quarterly clinical examinations for the first 5 years and annually thereafter. Chest x-ray, bilateral mammography, liver ultrasound examination, and total body bone scan were performed yearly.

Results:

No. of patients 278, 86 Pectoralis minor Removed Group, 192 Pectoralis minor Retained Group, the mean age for Removed Group was 57 years (29-81), for Retained Group was 53 years (32-67). Clinical details were similar Tumour size and type were also similar in the two groups. operative time of axillary dissection (37 in Removed Group vs 33 minutes in Retained No statistically significant differences ($P=0.07$). The mean operative blood loss was 220mL Removed Groups vs 140mL in Retained Group. breast-conserving surgery (63% Retained Group v 57% Removed Group.

the five-year overall survival and disease-free survival was 89.7% and 80.8%, in Removed Group respectively, whereas in Retained Group it was

84.5% and 78.7%. Acute complications were, wound infection 3/86 (3.48%) in Removed Group and 13/192 (6.77%) in Retained Group. Incidences of seroma 5/86(5.8%) in Removed Group, and 10/192 (5.2%) in Retained Group ($p<0.02$) respectively was not statistically different between the groups., the only chronic complications were decreased but not statistically different in Retained Group, range of movement (ROM) of the shoulder 39/86(45.34%) in Removed Group and 85/192 (44.27%) in Retained Group, paresthesia 29/86 (33.72%) in Removed Group and 59/192 (30.73%) in Retained Group, and lymphedema 4/86 (4.65%) in Removed Group and 6/192 (3.13%) in Retained Group, partial atrophy and fibrosis of the pectoralis major muscle in (8.14%)% of Removed Groups vs (4.27%) in Retained Group. locoregional recurrence occurred in 1/86 (1.16%) in Removed Group and in 2/192 (1.04%) in Retained Group which was not statistically different ($P = 0.19$). The mean drain output volume during the initial 48 h postoperatively was 350 ml (range, 90–700 ml) Removed Group. 290 ml (80-625) Retained Group, The mean duration of drainage was 14days (range, 6–29 days) Removed Group, 12 days (range, 4-21) Retained Group. The mean total number of nodes removed in the two groups was similar: 16(range, 7-31) in Removed Group and 15 (range, 6-28) in those in Retained Group.

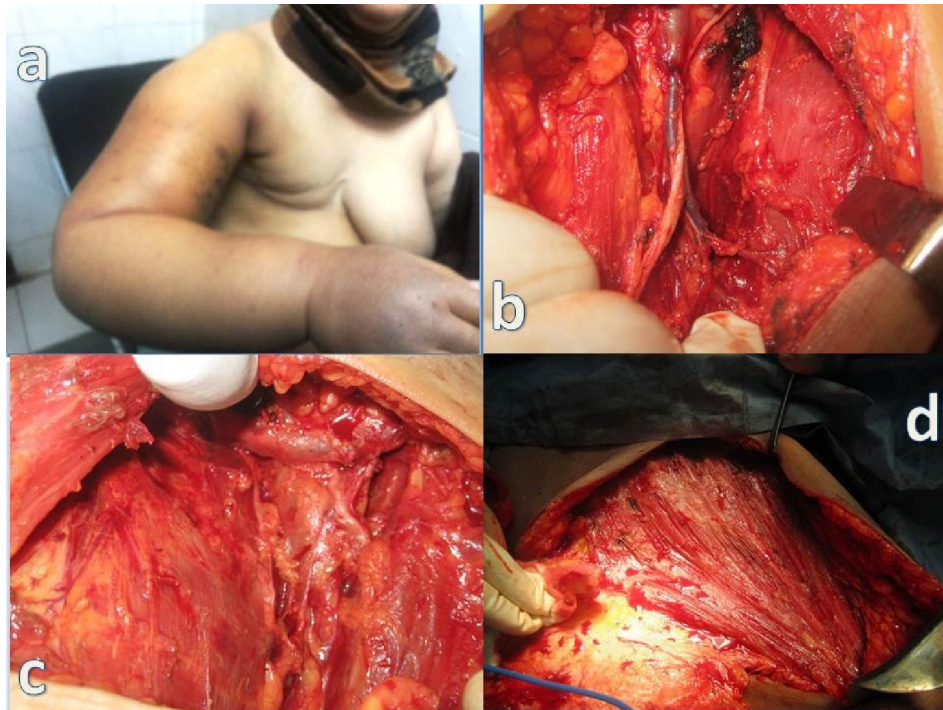


Figure (2): a] Lymphoedema of the right upper limb following modified radical mastectomy. b] Axillary lymph node dissection (ALND). c] Fatty and lymphatic tissue was removed inferior to the axillary vein. d] Removal the covering fascia from the pectoral muscle.

Pathological node status:

Node negative: 38 (44.2%) patients Removed Group and 79 (41.1%) in Retained Group

Node positive:

1–3 nodes in 34 (39.5%) patient in Removed Group, and 69 (35.9%) in, Retained Group.

4–9 nodes in 9 (10.5%) patients in Removed Group, and 35 (18.3) patients in Retained Group.

10 nodes 5 (5.8%) patients in Removed Group, 9 (4.7%) patients in Retained Group.

Total number of nodes removed according to level of dissection:

Level I; 7 nodes (3-12) in Removed Group and 7 nodes (2-14) in Retained Group.

Level II: 6 nodes (2-11) in Removed Group and 5 nodes (1-9) Retained Group

Level III :3 nodes (0-7) in Removed Group and 3 nodes (0-6) in Retained Group.

Statistical analysis

Statistical methods:

All analyses were done using SPSS® (Statistical Package for Social Sciences) software version 21, IL, Chicago, USA. Numerical values were expressed as means or medians and standard deviation (SD) or range. Parametric and non parametric t test compared means of 2 independent groups. Chi-square / Fisher exact test compared independent proportions. Survival was estimated using Kaplan Meier method and compared using Log rank test. P value is always 2 tailed and significant at 0.05 level.

4. Discussion:

Breast cancer is the most common type of cancer in women Axillary lymph node status is the most important determinant in the regional spread of invasive breast carcinoma.

the single most important prognostic factor. The prognosis is also inversely related to the number of involved nodes [18]. Patients with breast cancer present much earlier than in the past and in these early cancers, the axilla is frequently uninvolved[3] the axillary lymph nodes, especially the subclavicular nodes group which cannot be touched by the conventional muscle-preserving operation, the pectoralis minor muscle is pulled laterally and detached from the ribs. In this way the interpectoral nodes (Rotter's nodes) with fatty tissue and branches of the thoracoacromial vessels can be dissected out[13].

The operative times were 40.63±14.27 minutes in Removed Group and 31.18±10.78 minutes in Retained Group, respectively (no statistically significant difference between the 2 groups).[17] in

our study operative time of axillary dissection (37 in Removed Group vs 33 minutes in Retained Group, ($P=0.07$).

Breast cancer does not invade the underlying muscles except in very advanced cases. The main purpose of sacrificing the pectoral muscles is provide more easy and complete dissection of the axillary nodes. Because of the fear of an incomplete lymph node extirpation [13].

The pectoralis minor muscle is a flat, triangular muscle of the anterior chest wall originating from the 3rd, 4th, and 5th ribs and inserting onto the coracoid process of the scapula. The pedicled pectoralis minor muscle flap easy to dissect and reproducible, involving minor esthetic sequelae and no functional complications raised and transposed to cover the vital structures in the axilla with minimal functional loss [19,20,21,22,23].

Retention of the pectoralis minor muscle does not result in a significant fall in the number of nodes excised. It is thus unlikely to lead either to understaging of the disease or an increased risk of axillary recurrence. This agrees with a previous study from Milan which compared results after resection and preservation of pectoralis minor in women undergoing breast conservation therapy. If this approach is adopted, it is important to palpate the interpectoral (Rotter's) nodes during operation since these may be involved in up to 21 per cent of patients [2]. Total number of 13 nodes Retained Group (range 11–17) in compared to 16 axillary nodes in Removed Group (range 13–20) [24]. Inverse correlation between a low number of removed axillary lymph nodes (often <10) and overall survival, current guidelines recommend the removal of at least 10 lymph nodes the cut off at 10 lymph nodes to allow a 90% certainty of a true negative axillary status [24,25]. The mean number of isolated lymph nodes was 19.8 (spared muscle group) and 18.5 (removed muscle group)[10].

The pectoralis minor muscle is severed near its attachment to the coracoid process and an axillary dissection is thereby easily and thoroughly accomplished The effectiveness of lymph node dissection by this method was ascertained when the number of the lymph nodes removed by this procedure was compared with that removed by the conventional muscle preserving mastectomy (Madden's operation) and the radical mastectomy [13]. In our study (no statistically significant difference between the 2 groups A mean of 15 lymph nodes (range, 8-31) Retained Group and 16 (range, 7-36) in Removed Group, similar numbers of nodes at level I in the two groups but significantly fewer at level II in patients who had pectoralis minor

preserved. It is likely that this arose from the difficulty in marking accurately the upper border of pectoralis minor on the specimen. Similar numbers of nodes were found at level III.

The 5-year survival rate in patients with breast cancer ranges from 74 to 82 % [18,26].

A significant increase in local-regional recurrence rates was related to a decrease in long-term overall survival rates in patients with breast cancer. Therefore, the extent of axillary lymph nodes surgery possibly influences longterm overall survival [27].

The five-year overall survival and disease-free survival was 91.8% and 82.2%, in Retained group whereas, in Removed it was 92.5% and 83.9% [28]. In our study no significant difference in disease-free, overall survival was observed the five-year overall survival and disease-free survival was 89.7% and 80.8%, in Removed Group respectively, whereas in Retained Group it was 84.5% and 78.7%.

Conserving the pectoralis minor muscle lessens both immediate postoperative pain and also both pain and shoulder dysfunction 6 months after surgery [3,4] compared to Radical surgery to the axilla, which is associated with a higher incidence of complications and longer hospitalization [29]. The early complications include skin erythema, seroma, wound infection, pain decreased range of motion (ROM) of the ipsilateral shoulder, and change in sensation (paresthesia). and inadvertent damage to neurovascular structures. The late complications include postoperative pain, intercostobrachial nerve syndrome (paraesthesia of the axilla, shoulder and upper arm limitations of shoulder movements, numbness of the upper arm, and, lymph edema predisposing to cellulitis, rarely lymphangio-sarcoma and Stewart-Treves syndrome, decreased ROM of the ipsilateral shoulder, and paresthesia, limitation of arm abduction (0-41.4%), pain (5.6-51.1%), paresthesia (5.1-51.1%) and lymphedema (0-27.3%). [5,30,31,32,33].

Acute complications the same in the two groups. However, at longer follow-up (more than 6 months after surgery) the patients whose pectoralis minor muscle was preserved showed a reduction in the incidence of partial atrophy and fibrosis of the pectoralis major muscle[10]. Partial atrophy and fibrosis of the pectoralis major muscle in (8.14%)% of Removed Group vs (4.27%) in Retained Group. This fact may be related to disruption of the pectoral nerves, which are in close contact with the pectoralis minor during their course from the brachial plexus to the pectoralis major muscle [10]. Acute complication rates of 20–30% including seroma formation, local swelling, numbness, impaired shoulder movement, neuropathy, infection, and chronic lymphoedema

rates of 7–37% [34]. Our study corroborates previous findings that report excellent arm function results after Acute complications were, seroma, and wound infection (6.97%) in Removed Group and (6.25%) in Retained Group, ($p < 0.05$, respectively) was not statistically different between the groups. The only chronic complications were decreased but not statistically different in Retained Group, ROM of the shoulder (45.34%) in Pectoralis minor Removed Group and (44.27%) in Retained Group, paresthesia (33.72%) in Pectoralis minor Removed Group and (30.73%) in (Pectoralis minor Retained Group, and lymphedema assessed by patients (4.65%) in Pectoralis minor Removed Group and (3.13%) in Retained Group, partial atrophy and fibrosis of the pectoralis major muscle in (8.14%) of Removed Group vs (4.27%) in Retained Group. The reported incidence of seroma varies widely between 8 and 81%, 22.55% following modified radical mastectomy [33]. Seroma occurs in 4.8% in Pectoralis minor Retained Group, and 6.2% in Removed Group ($P = .11$) Therefore, there is no clear advantage of Retained in terms of reducing postoperative lymphorrhea. [17,32] In the present study seroma 6/86 (6.97%) in Pectoralis minor Removed Group and 12/192 (6.25%) in Pectoralis minor Retained Group, ($p < 0.05$, respectively) was not statistically different between the groups Similar to the scarcity of reporting of the rates of seroma, mean drain output volume during the initial 48 h postoperatively was 350 ml Removed Group, 290 ml Retained Group, The mean duration of drainage was 14 days Removed Group (range: 6–29 days), 12 days (range: 4-21) in Retained Group, recording of wound infections was - 2.7% in Retained Group and 8.7% in Removed Group - was similar two other studies that provided data on wound infection [32] in our study wound infection (3.48%) in Removed Group and (6.77%) in Retained Group.

Axillary nodal involvement is a strong predictor of recurrence The incidence of axillary recurrence after ALND is low (2-5%) [34]. Patients undergoing ALND, have axillary recurrence rates around 1% at 5 the incidence of local recurrence is about the same whether the surgical procedure is a Halsted radical or a modified radical mastectomy[7]. Locoregional recurrence occurred in 0.7% of the overall population, which was not statistically different between the two groups (4.1%, 1.1%, 1.9%) Retained Group versus (2.8%, 1.0%, 1.5%) Removed Group ($P = 0.11$). [5,11,27], in our study locoregional recurrence occurred in 1/86 (1.16%) in Retained Group and in 2/192 (1.04%) in Removed Group which was not statistically different ($P = 0.19$).

Conclusion

Satisfactory surgical exposure of the axilla and a complete axillary dissection can be accomplished without removing the pectoralis minor Muscle, no statistical difference in overall survival and in disease free survival removed nodal metastases reducing morbidities of axillary surgery.

References

- Nemoto T, Dao TL. Is modified radical mastectomy adequate for axillary lymph node dissection? *Annals of surgery* 1975;182(6):722.
- Markandoo P, Smith P, Chaudary M, Fentiman I. Preservation of pectoralis minor in axillary clearance for breast cancer. *British journal of surgery* 1998;85(11):1547-8.
- Veronesi U, Orecchia R, Zurrada S, et al. Avoiding axillary dissection in breast cancer surgery: a randomized trial to assess the role of axillary radiotherapy. *Annals of oncology* 2005;16(3):383-8.
- Zervoudis S, Iatrakis G, Tomara E, Bothou A, Papadopoulos G, Tsakiris G. Main controversies in breast cancer. *World journal of clinical oncology* 2014;5(3):359.
- Oliveira M, Cortés J, Bellet M, et al. Management of the axilla in early breast cancer patients in the genomic era. *Annals of oncology* 2013;24(5):1163-70.
- Erb KM, Julian TB. Completion of axillary dissection for a positive sentinel node: necessary or not? *Current oncology reports* 2009;11(1):15-20.
- Cserni G. Estimating the overlap between sentinel lymph nodes and axillary node samples in breast cancer. *Pathology & Oncology Research* 1999;5(2):129-33.
- Caudle AS, Kuerer HM. Targeting and limiting surgery for patients with node-positive breast cancer. *BMC medicine* 2015;13(1):149.
- Voutsadakis IA, Spadafora S. Axillary lymph node management in breast cancer with positive sentinel lymph node biopsy. *World journal of clinical oncology* 2015;6(1):1.
- Merson M, Pirovano C, Balzarini A, et al. The preservation of minor pectoralis muscle in axillary dissection for breast cancer: functional and cosmetic evaluation. *European journal of surgical oncology: the journal of the European Society of Surgical Oncology and the British Association of Surgical Oncology* 1992;18(3):215-8.
- Wazir U, Manson A, Mokbel K. Towards optimal management of the axilla in the context of a positive sentinel node biopsy in early breast cancer. *World journal of clinical oncology* 2014;5(5):792.
- Lee MC, Joh JE, Chau A. Axillary staging prior to neoadjuvant chemotherapy: the roles of sentinel lymph node biopsy and axillary ultrasonography. *Cancer Control* 2012;19(4).
- Kodama H. Modification of muscle - preserving radical mastectomy. *Cancer* 1979;44(4):1517-22.
- Muscolino G, Leo E, Sacchini V, Bedini A, Luini A. Resectable breast cancer: axillary dissection sparing pectoralis muscles and nerves. *European journal of surgical oncology: the journal of the European Society of Surgical Oncology and the British Association of Surgical Oncology* 1988;14(5):429-33.
- Dasgupta S, Sanyal S, Sengupta S. Transpectoral anterior approach to the axilla for lymph node dissection in association with mastectomy preserving both pectoral muscles and their neurovascular bundles. *Tumori* 1998;85(6):498-502.
- Cucin RL, Guthrie RH, Deschner EE. Lymphatic drainage of the breast on and through the pectoral muscles: importance in breast cancer. *Cancer* 1975;35(1):260-2.
- Luo C, Guo W, Yang J, et al. Comparison of mastoscopic and conventional axillary lymph node dissection in breast cancer: long-term results from a randomized, multicenter trial. In. *Mayo Clinic Proceedings: Elsevier*, 2012: 1153-61.
- Pierga J, Mouret E, Dieras V, et al. Prognostic value of persistent node involvement after neoadjuvant chemotherapy in patients with operable breast cancer. *British journal of cancer* 2000;83(11):1480.
- Bourdais L, Bellier-Waast F, Perrot P, Delpierre J, Pannier M, Duteille F. Coverage of clavicular area by a pectoralis minor pedicle flap: anatomical study and description of three clinical cases. *Annals of plastic surgery* 2009;63(4):409-13.
- Manstein CH, Manstein G, Somers RG, Barwick WJ. Use of pectoralis minor muscle in immediate reconstruction of the breast. *Plastic and reconstructive surgery* 1985;76(4):566-9.
- van de Sande MA, Cosker T, McDonnell SM, Gibbons C, Giele H. Use of the Composite Pedicled Pectoralis Minor Flap after Resection of Soft Tissue Sarcoma in Reconstruction of the Glenohumeral Joint. *Case reports in orthopedics* 2014;2014.
- Palmer RS, Miller TA. Anterior shoulder reconstruction with pectoralis minor muscle

- flap. *Plastic and reconstructive surgery* 1988;81(3):437-9.
23. Li J, Jia S, Zhang W, et al. Partial axillary lymph node dissection inferior to the intercostobrachial nerves complements sentinel node biopsy in patients with clinically node-negative breast cancer. *BMC surgery* 2015;15(1):79.
 24. Cserni G. Axillary staging of breast cancer and the sentinel node. *Journal of clinical pathology* 2000;53(10):733-41.
 25. Matsuzawa F, Omoto K, Einama T, et al. Accurate evaluation of axillary sentinel lymph node metastasis using contrast-enhanced ultrasonography with Sonazoid in breast cancer: a preliminary clinical trial. *SpringerPlus* 2015;4(1):1-9.
 26. Takei H, Suemasu K, Kurosumi M, et al. Recurrence after sentinel lymph node biopsy with or without axillary lymph node dissection in patients with breast cancer. *Breast Cancer* 2007;14(1):16-24.
 27. Ahmed M, Douek M. What is the future of axillary surgery for breast cancer? *ecancermedicalscience* 2013;7.
 28. Soares EWS. Anatomical variations of the axilla. *SpringerPlus* 2014;3(1):306.
 29. Li J-w, Mo M, Chen C-m, et al. ER-Poor and HER2-Positive: A Potential Subtype of Breast Cancer to Avoid Axillary Dissection in Node Positive Patients after Neoadjuvant Chemotherapy. *PloS one* 2014;9(12):e114646.
 30. Wernicke AG, Shamis M, Sidhu KK, et al. Complication rates in patients with negative axillary nodes 10-years after local breast radiotherapy following either sentinel lymph node dissection or axillary clearance. *American journal of clinical oncology* 2013;36(1):12.
 31. Pan X-F, Huan J-L, Qin X-J. Potential risk factors for the development of seroma following mastectomy with axillary dissection. *Molecular and clinical oncology* 2015;3(1):222-6.
 32. Pazaiti A, Fentiman IS. Which patients need an axillary clearance after sentinel node biopsy? *International journal of breast cancer* 2011;2011.
 33. Lumachi F, Basso SM, Bonamini M, et al. Incidence of arm lymphoedema following sentinel node biopsy, axillary sampling and axillary dissection in patients with breast cancer. *in vivo* 2009;23(6):1017-20.
 34. Atalay C. New concepts in axillary management of breast cancer. *World journal of clinical oncology* 2014;5(5):895.

9/25/2015