

Histopathologic Study of Antiestrogenic Anticancer Nolvadex Induced Liver Damage in Rats and Vitamins Ameliorative Effect

Fatma A. Morsy, Amina Gamal el-Din, Nermeen M. Shaffie and Manal A. Badawi

Department of Pathology, National Research Center, Dokki, Cairo, 12622, Egypt
hassaneinamina@yahoo.com

ABSTRACT: This study was designed to evaluate the effects of antiestrogenic anticancer Nolvadex (used for breast cancer treatment) on rat liver and the possible protective effects of vitamin C and/ or E. Material and methods: A total of 140 adult female albino rats were used; divided into seven groups; each containing 20 rats: First group: as control. Second group: orally daily dosed with Nolvadex 20 mg/kg b. w. for three weeks. Third group: orally given vitamin C (0.02 g/100 g b wt), 15 min before daily Nolvadex administration. Fourth group: given vitamin E (120 mg/Kg b.w), 15 min prior to daily Nolvadex administration. The fifth group was given combination of the two vitamins C & E (0.02 g/100 g b.w.) and (120 mg/kg b.w.) respectively, 15 min before daily Nolvadex administration. Each of the remaining two groups was daily given vitamin C (0.02 g/100 g b.w.) and/or E (120 mg/kg b.w.) for two weeks. Paraffin sections were used for histopathological , quantitative image analysis DNA ploidy and histochemical studies .Electron microscopy was performed. Results: Histopathological degenerative effects in the form of vacuolar degeneration, fatty changes and hydropic degeneration were noticed in Nolvadex treated rat liver. Karyolysis and karyorrhexis were also seen. Dysplasia and chromatin clumping were observed in scattered hepatocytes together with a decrease in DNA content (hypoploidy) and marked diminution of protein and mucopolysaccharides content. Histopathological, histochemical and ultra structural changes were diminished in rats treated with vitamins C and/ or E prior to Nolvadex. Conclusion: The treatment of rats with vitamins C and/or E prior to Nolvadex resulted in amelioration of the histopathological ,histochemical and ultrastructural changes in liver.

[Fatma A. Morsy, Amina Gamal el-Din, Nermeen M. Shaffie and Manal A. Badawi. **Histopathologic Study of Antiestrogenic Anticancer Nolvadex Induced Liver Damage in Rats and Vitamins Ameliorative Effect.** *Cancer Biology* 2014;4(2):1-15]. (ISSN: 2150-1041): (ISSN: 2150-105X (online). <http://www.cancerbio.net>. 1

Key words: Histopathology – antiestrogenic – anticancer- Nolvadex – liver – rat – Vitamins

1. Introduction

Breast cancer remains the most common malignancy in women world wide. Estrogen levels appear to be associated with an increased risk for the development of breast cancer (Lo. and Vogel 2004). In 1998 the National Surgical Adjuvant Breast and Bowel Project (NSABP) demonstrated that Nolvadex treatment reduced the incidence of both invasive and non -invasive breast cancer in population at high risk for disease (Tan- Chiu et al., 2003).

Tamoxifen (TAM), a non steroidal antiestrogen is used as a chemotherapeutic and chemopreventive agent for breast cancer (Goss and Stresses-Weipple, 2004). Tamoxifen is a nonsteroidal triphenylethyl compound that belongs to a class of selective estrogen receptor modulators (SERMs), binds to estrogen receptors (ERs) and elicits estrogen agonist or antagonistic responses, depending on the target tissue. Its estrogen antagonistic properties have made Nolvadex an important treatment modality for patients with breast cancer, especially those whose tumors are positive for ERs Dray et al., 2000 reported a case of non-alcoholic steatohepatitis with cirrhosis in a woman receiving tamoxifen as adjuvant treatment for breast cancer. Nolvadex has been used as an agent for

the treatment and prevention of breast cancer. However, long-term treatment of Nolvadex in women increases the risk of the developing endometrial cancer. The secondary cancer may be due to the genotoxicity of TAM (Kim et al., 2006). Nolvadex -induced non-alcoholic steatohepatitis (NASH) may increase the demand on oncologists, not only with regard to screening for diabetes, but also for the suggested link of NASH with high incidence of coronary heart disease (Osman et al., 2007). The incidence of toremifene-induced fatty liver was significantly lower than that induced by tamoxifen. Accordingly, in terms of fatty liver and NASH, toremifene is considered to be more appropriate agent than Nolvadex. (Hamada et al., 2000).

Nolvadex is liver carcinogenic in rats and has been associated with an increased risk of endometrial cancer in women (Curtis et al., 2004). Furthermore Nolvadex use has been associated with a 35% decrease in incidence of osteoporotic bone fractures (Decensi et al., 1998). In mice, TAM produced proliferative lesions in the oviduct and uterus (Srinivas et al., 2004) followed by uterine carcinoma (Newboid et al., 1997).

Nolvadex affects some types of visual pathway (Eisner et al., 2004). Woman taking Nolvadex suffer

from damage of retina and corneal opacities. These changes may have no immediate effect on visual acuity, but may predispose the eye to latter problems including cataracts (Epstein et al., 1997). Nolvadex induces menstrual irregularities in premenopausal woman. Amenorrhoea (absence of menstrual cycle) often results and can be permanent (Sellman, 1998). Nolvadex can induce multinucleated giant cells and germinal epithelial sloughing, seminiferous tubules distortion and these changes are detrimental to male fertility (Dsouza, 2003).

Nolvadex and its metabolites, 4-hydroxytamoxifen (4OH-TAM), N-desmethyltamoxifen (DMT) and 4-OH-N-desmethyltamoxifen (endoxifen) exhibit antiestrogenic activities by competitively inhibiting the binding of potent agonists to the estrogen receptor (ER), thus antagonizing their proliferative effects (Johnson et al, 2004). Despite the high therapeutic index of TAM for breast cancer, there are concerns regarding the increased occurrence of uterine cancer as early as 2 years after initiating treatment (Fisher, 1994). Nolvadex is classified as a selective estrogen receptor modulator (SERM) as a result of its differential effects in breast and uterine tissues. A number of factors influence the specificity and efficacy of SERM-bound, ER-mediated gene expression, and the subsequent physiological effects (Fong et al., 2007).

Nolvadex has demonstrated genotoxic activity in the rat liver causing DNA adducts (Divi et al., 2001) unscheduled DNA synthesis, hepatic aneuploidy and mitotic spindle disruption (Phillips, 2001). For the formation of DNA adducts, metabolic activation of tamoxifen is indispensable; the metabolites α -hydroxytamoxifen (Beland et al, 1999) and its O-sulfate (Shibutani et al, 1998) are characterized as proximate and ultimate carcinogens, respectively. On the other hand, major metabolites such as N-desmethyltamoxifen, tamoxifen N-oxide and 4-hydroxytamoxifen are generally characterized as detoxification forms, although the further metabolites, α -hydroxyl forms of the N-desmethyltamoxifen and tamoxifen N-oxide, are able to produce the DNA adducts (Umamoto et al, 2000). Long term administration of Nolvadex induced hepatoproliferative lesions and hepatocellular tumors in rats (Hirsimaki et al., 1993). In the stage before the formation of hyperplastic nodules in the liver, the genes of several hepatic enzymes responsible for not only detoxification but also activation of Nolvadex were activated and that in the later stage (in the nodules), the gene activation of detoxification enzymes was selectively maintained, while that of activation enzymes was suppressed. Thus, the overall change in the gene expression of the Nolvadex-metabolizing enzymes by Nolvadex treatment appears to be

reasonable for the formation and growth of the hepatic hyperplastic nodules, because the increase in detoxification enzymes in the later stage would be expected to confer tamoxifen resistance to the induced nodules (Kasahara et al., 2002).

One of the proposed pathways for the metabolic activation of Nolvadex involves oxidation to 4-hydroxy tamoxifen, which may further oxidize to electrophilic Quinone methide (Costa et al., 2001). Nolvadex is well tolerated but causes steatosis in 43% of recipients (Nishino et al., 2003). Steatohepatitis can develop, particularly in overweight women (Bruno et al., 2005), and can lead to cirrhosis (Oien et al., 1999). Nolvadex administration decreases fatty acid synthase (FAS) expression in rat liver (Lelliott et al., 2005), and tamoxifen both uncouples and inhibits mitochondrial respiration (Larosche et al., 2007).

Antioxidants have been reported to play a significant role in protection against lipid peroxidation (Steenwooden and Henegouwen, 1999). Some investigators reported that antioxidants inhibit chemical carcinogenesis when the antioxidants are administered either prior or with carcinogen (Ames, 1983). Vitamin C (ascorbic acid) has a considerable antioxidant activity: it scavenges reactive oxygen species and may, thereby, prevent oxidative damage to the important biological macromolecules, such as DNA, proteins, and lipids (Konopacka, 2004). Ascorbic acid (vitamin C) exerts protective role against acute ultraviolet B-rays (Sunburn cell formation) (Meves et al., 2002), organophosphorous pesticides (Kurata et al., 1993), and could reduce aflatoxin induced liver cancer (Yu et al., 1994). Moreover vitamin C abolishes chromosome damage resulted from the effect of toxic substances (Trommer et al., 2002), and help to protect the body against pollutants (Masaki et al., 2000).

Because vitamin C is a biological reducing agent, it is also linked to preventive of degenerative diseases such as cataracts, certain cancer and cardiovascular disease (Barros et al., 2004 and Wang & sun, 2004). Increased vitamin C intake could possibly reduce and prevent nephrotoxic effect (Nagyova et al., 1994). It assists in the prevention of blood clotting and bruising; it strengthens the walls of the capillaries (Tousoulis et al., 2003) and it is also needed for healthy gum (Ambros et al., 1998). Vitamin C helps to reduce cholesterol levels, high blood pressure and preventing atherosclerosis (Napoli et al., 2004 and Zureik et al., 2004). It protects susceptible cells from genotoxicity associated with antiestrogen metabolite-4- hydroxy tamoxifen (4-OH tom) (Sharma and Slocum, 1999), and inhibit DNA adduct induced by tamoxifen (Sierens et al., 2001 and Sharma et al., 2003).

Vitamin E (alpha tocopherol) is the naturally occurring lipid soluble antioxidant (Butterfield et al.,

1999). It is a powerful antioxidant that combats damaging free radical. It is important for reproduction, prevention of various diseases (Biri et al., 1998). It appeared significant for reduction of hot flash (Barton et al., 1998), toxicity of doxorubicin in tissue of rats (Geetha et al., 1990). Alpha tocopherol prevents oxidation of LDL cholesterol and help to protect against atherosclerosis. Vitamin E exerted protective effects against cyanide induced tissue lesions in rabbits (Okolie and Iroanya, 2003) and protected neurons against oxidative cell death in vitro (Behl, 2000). Vitamin E maintained bone mineral density in ovariectomized rats and caused conflicting effect on bone calcium content (Norazlina et al., 2000), and could enhance the proliferative status of prostate gland (Yao et al., 1996). Moreover the increased level of enzyme in fibrosarcoma in rats was reduced by vitamin E administration (Vinitha et al., 1995). Vitamin E is used in the treatment of Alzheimer's disease through preventing brain cell damage by destroying toxic free radicals (Klatte et al., 2003 and Zandi et al., 2004) and in the treatment of disorders in the central nervous system (Vatassery et al., 1999).

Co administration of vitamin C and vitamin E reduces the Nolvadex induced hypertriglyceridemia (Babu et al., 2000). Vitamin C and alpha tocopherol alone reduce the growth of human melanoma (sk-30) cells in culture (Prasad et al., 1994).

The aim of the present study is to investigate the possible protective effect of vitamin C and vitamin E to ameliorate antiestrogenic Nolvadex induced histopathological, histochemical and ultrastructure changes in liver of rats.

2. Material and Methods

140 female albino rats weighting 130-160g were used in this study. The animals were divided into seven groups. Each group contained 20 rats.

Group (1): was kept as control.

Group (2): was given Nolvadex daily for two weeks at dose level of 20mg/kg b.w.

Group (3): was given vitamin C only at dose level of 0.01g/100g b.w. by stomach tube for two weeks.

Group (4) was given vitamin E only 100 mg/kg b.w. by stomach tube daily for two weeks.

Group (5) was given vitamin C at dose level of 0.01g/100g b.w. (Padget and Barnes, 1964) by stomach tube, 15 min before Nolvadex administration daily for two weeks.

Group (6) was given vitamin E at dose level of 100 mg/kg b.w., 15 min before Nolvadex administration.

Group (7) was given combination of vitamin C at dose level of 0.01g/100g b.w. and vitamin E at dose level of 100mg/kg b.w., 15 min before Nolvadex administration daily for two weeks.

Histopathological and histochemical studies:

The liver of different groups were removed and fixed in 10% formal saline. Paraffin sections 5 μ m thick were stained with haematoxylin and eosin (Drury and Wallington, 1980) and Masson trichrome stain to demonstrate the collagen fibers (Masson, 1929). All sections were investigated by the light microscope.

DNA Ploidy studies:

Further sections were stained for DNA (Feulgen and Rosenbeck, 1942) and counterstained with Light Green. DNA analysis was performed by lecia Qwin 500 image cytometry in the department of pathology, National Research Center. For each section (100-120 cells) were randomly measured. The threshold values were defined by measuring control cells. The results are presented as histograms and tables which demonstrate the percentage of the diploid cells (2C), the triploid cells (3C), the tetraploid cells (4C) and the aneuploid cells (>5C). The DNA histogram classified according to Danque et al., (1993). Protein stain (Mazia et al., 1953) and mucopolysaccharids stain (Mac-Manus and Cason, 1950) were also performed.

The ultrastructural studies:

Sample processing for electron microscopy together with examining the thin sections and getting the electron micrographs was done in the Electron Microscope Unit, Institute of Ophthalmology. Small pieces of liver, about 1mm³ in size were prepared.

Thin sections 60-90 nm thick were prepared by using ultra cats/ FCS; the thin sections were mounted on copper grids, stained with uranyl acetate and lead citrate (Watson, 1958) and finally examined with transmission JEM- 100x IL electron microscope. Photographs using Kodak films and photographic paper were taken and examined. Further sections were stained for DNA (Feulgen and Rosenbeck, 1942) and counterstained with Light Green. DNA analysis was performed by lecia Qwin 500 image cytometry in the department of pathology, National Research Center. For each section (100-120 cells) were randomly measured. The threshold values were defined by measuring control cells. The results are presented as histograms and tables which demonstrate the percentage of the diploid cells (2C), the triploid cells (3C), the tetraploid cells (4C) and the aneuploid cells (>5C). The DNA histogram classified according to Danque et al., (1993). Protein stain (Mazia et al., 1953) and mucopolysaccharids stain (Mac-Manus and Cason, 1950) were also performed.

3. Results

• Histopathological results:

The liver of control rats revealed the characteristic hepatic architecture (Fig. 1, A).

No pathological changes could be noticed in the

liver of rats treated with either vitamin C or vitamin E.

The liver of rats treated with Nolvadex only showed hydropic degeneration, nuclei with variable sizes and dysplastic cells (Fig. 1,B). Fatty changes, vacuolar degeneration, mitotic figure and fibrosis were seen (Fig.1,C). Dilation, congestion of blood sinusoid and peripheral chromatin clumping were also observed (Fig.1, D).

Concerning rats treated with vitamin C and Nolvadex in combination for two weeks, examination of liver sections showed marked diminution of hydropic degeneration, fatty changes and mitotic figure. No fibrosis and no chromatin clumping were noticed. While some hepatocytes still showed hypertrophy, others showed signs of degeneration in the form of karyolysis and karyorrhexis. The kupffer cells showed mild hypertrophy (Fig.1, E).

The rats treated with vitamin E and Nolvadex in combination, showed some protective effects as compared to the group of rats subjected to Nolvadex only. Examination of liver sections showed moderate hypertrophy of kupffer cells. Red blood cells are seen in the blood sinusoids. Focal area of necrosis was also noticed. The liver of rats subjected to combination of vitamin C and vitamin E prior to administration of Nolvadex showed some histological changes, but these changes were somewhat less than those of rats treated with Nolvadex only. Examination of liver sections showed focal necrosis and a number of binucleated cells (Fig. 1, F).

Examination of control liver sections showed normal distribution of collagen, which showed small amount of wavy fibrils (Fig. 2,A). Treated group with Nolvadex showed collagen fibrils that occurred as wavy fibrils either singly or fused together in dense bundles (Fig. 2, B). The liver of rats subjected to vitamin C and / or vitamin E prior to administration of Nolvadex showed improvement in collagen deposition and connective tissue fibers as compared to liver of rats treated with Nolvadex only (Fig. 2, C).

• DNA Ploidy results:

DNA content in all the studied groups:

In the present study, the Qwin 500 image analyzer was used to evaluate the DNA content. The image analysis system automatically express the DNA content of each individual cell measured then gave the percentage of each cell out of the total number of cells examined. Also, it classifies the cells into four groups; diploid (2C), proliferating cells (3C), tetraploid (4C) and aneuploid cells (>5C). The proliferating cells were further classified according to Lee et al. (1999) into; (<10%) low proliferation index, (10-20%) medium proliferation index and (>20%) high proliferation index.

Normal distribution of DNA content in the liver

of the control group showed that 20.18 % of the examined cells contained DNA (<1.5C), 65.13% of the examined cells contained diploid DNA value (2C), 12.84% of the examined cells contained (3C) DNA value (medium Proliferation Index) and 1.83% of the examined cells at (4C) area (Histogram 1). The group treated with Nolvadex showed that 93.54% of the examined cells contained DNA (<1.5C) this means decrease in DNA content (hypoploidy) compared to the control. (Histogram 2).

In the present work the treatment of rats with Nolvadex along with vitamin C showed that 31.63% of the examined cells contained DNA (<1.5C), 61.22% of the examined cells contained diploid DNA value (2C), 6.12% of the examined cells contained (3C) DNA value (low Proliferation Index) and 1.02% of the examined cells at (4C) area (Histogram 3).

The group treated with Nolvadex along with vitamin E showed that 43% of the examined cells contained DNA (<1.5C), 51% of the examined cells contained diploid DNA value (2C), 6% of the examined cells contained (3C) DNA value (low Proliferation Index) The group treated with Nolvadex along with combination of vitamin C and E showed that 9.90% of the examined cells contained DNA (<1.5C), 86.13% of the examined cells contained diploid DNA value. (2C), 3.96% of the examined cells contained (3C) DNA value (low Proliferation Index). These results indicate that treatment with vitamin C & E showed DNA values comparable to the control values while, the group treated with Nolvadex showed decreased DNA values (hypoploidy).

• Histochemical Results

Examination of control liver sections showed moderate protein content in the cytoplasm of hepatocytes. Some nuclei showed deep protein content. After daily treatment of rats with an oral dose of Nolvadex for two weeks, the protein inclusions showed marked diminution in the cytoplasm of hepatocytes and stainability was mostly diffused. Slight increase in protein content was noticed in the case of rats subjected to vitamin C in combination with Nolvadex as compared to liver of rats subjected to Nolvadex only. Moderate increase in protein content in the cytoplasm of hepatocytes was also recorded in the case of rats treated with vitamin E in combination with Nolvadex as compared to rats subjected to Nolvadex only. The pretreatment of rats with combination of vitamins (vitamin C and vitamin E) along with Nolvadex showed marked increase in protein content in the cytoplasm of hepatocytes.

Examination of control liver sections stained with periodic acid schiff's (PAS) showed mucopolysaccharide granules in the cytoplasm of hepatocytes; the peripheral zonal cells showed higher

mucopolysaccharide content than the central zonal cells (Fig.3, A). Daily treatment of rats with tamoxifen only for two weeks induced marked decrease in stainability of PAS +ve materials (Fig.3 B). Daily administration of vitamin E in combination with tamoxifen showed moderate increase in mucopolysaccharides content in the cytoplasm of hepatocytes and mild increase in mucopolysaccharides content could be noticed in the case of rats subjected to vitamin E and tamoxifen as compared to rats subjected to Nolvadex only (Fig. 3 C). Co administration of vitamins (vitamin C and vitamin E) in combination with Nolvadex showed marked generalized increase in mucopolysaccharides content in the cytoplasm of hepatocytes (Fig. 3 D).

Electron microscopic results:

Figure (4 A) showed electron micrograph of control liver cells. Hepatocytes of rats treated with Nolvadex only show areas of cytoplasmic dissolution, partial clumping of nuclear chromatin and corrugated nuclear membranes. Mitochondria were swollen with dense matrix (Fig.4 B). Endoplasmic reticulum dilated cisternae with no obvious attached ribosomes (Fig.4 C). The treatment of rats with vitamin C or vitamin E showed improvement in the ultrastructural changes in the form of diminution of cytoplasmic dissolution and restoration of nuclear normal shape (Fig. 4 D).

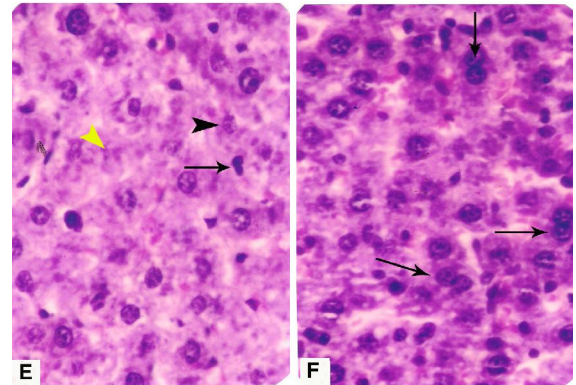
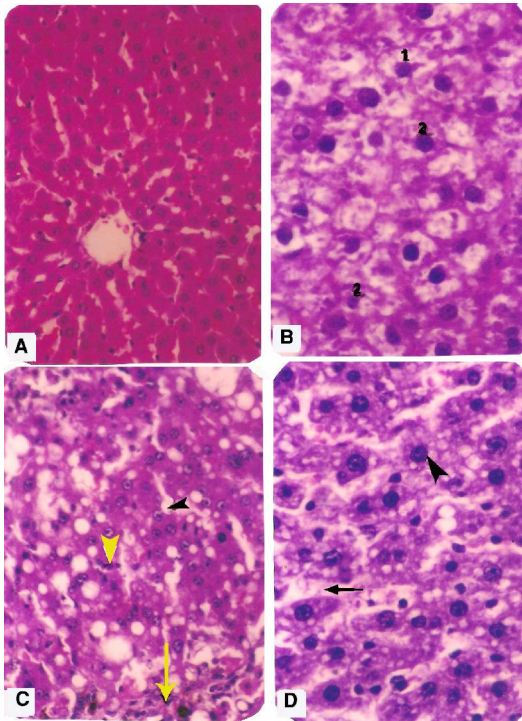


Figure (1): (A) Section in the liver of control rat showing normal histological structure of hepatic lobules and central vein (Hx.&E. X 200). (B) Section of the liver of a rat treated with Nolvadex showing hydropic degeneration (1), variable sized nuclei (2). Also seen, many pyknotic nuclei and some hepatocytes are devoid of nuclei (Hx.&E. X400). (C) Section of the liver of the same group showing lymphocytic infiltration (arrow), fatty changes, vacuolar degeneration (arrow head) and mitotic figures (yellow arrow head) (Hx.&E. X 200). (D) Section of the liver of a rat treated with Nolvadex showing dilation and congestion of blood sinusoids (arrow) and peripheral chromatin clumping (arrow head) (Hx.&E. X400). (E) Section in the liver of a rat treated with vitamin C along with Nolvadex showing no fibrosis, no fatty changes and no vacuolar degeneration. Karyolysis (black arrow head), karyorrhexis (yellow arrow head) & mild hypertrophy of Kupffer cells (arrow) were noticed. The same results were obtained with Vitamin E along with Nolvadex (Hx.&E. X400). (F) Section of the liver of a rat treated with Nolvadex along with vitamin C and vitamin E showing scattered binucleated cells (arrows). (Hx & E X 400).

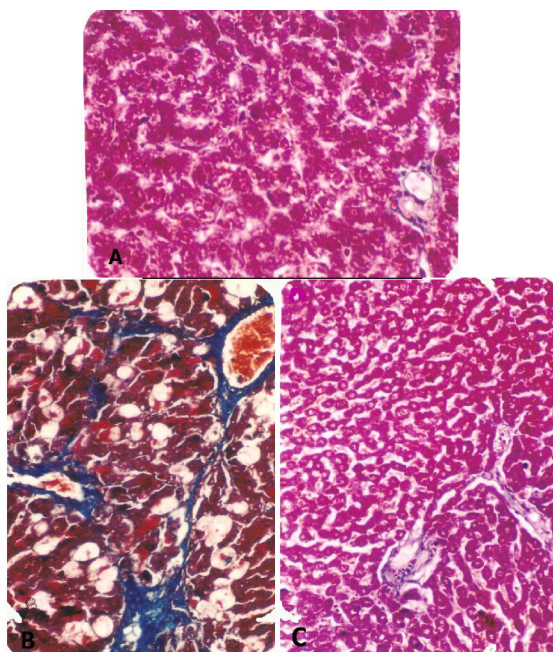


Figure 2: Section of the liver of a rat showing collagen (A): control. (B): treated group with Nolvadex showing collagen fibrils occurred as wavy fibrils either singly or fused together in dense bundles especially in and around the portal area, around the central vein and in-between hepatocytes. (C): treated group with Nolvadex along with vitamin C showing mild amount of fibrous tissue in the portal area. (Masson trichrome stain x 200).

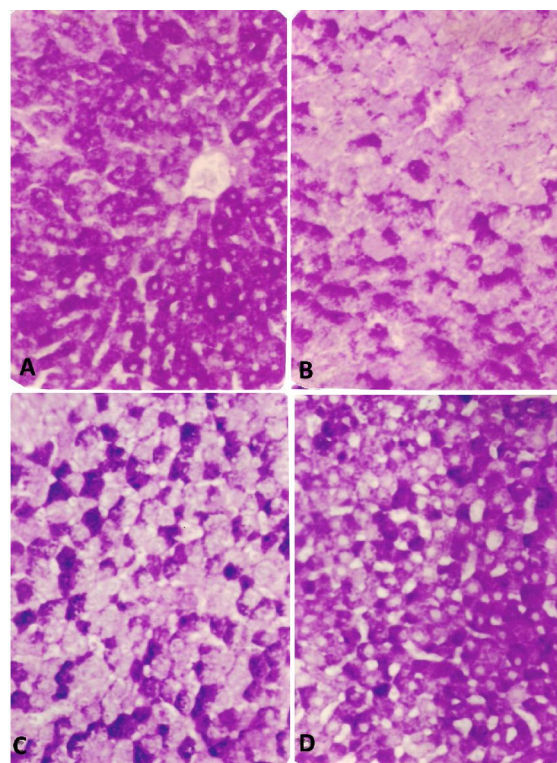


Figure (3): Section of the liver of a rat showing PAS+ve materials in the cytoplasm of hepatocytes (A) control. (B): Treated with Nolvadex: showing decreased stainability of PAS + ve materials. (C): Treated with vitamin E along with Nolvadex showing mild improvement in PAS +ve materials. The same results were obtained from the group of rats treated with Vitamin C along with Nolvadex. (D): Treated with Nolvadex along with vitamin C and vitamin E showing increased PAS+ ve materials. (PAS reaction x 400).

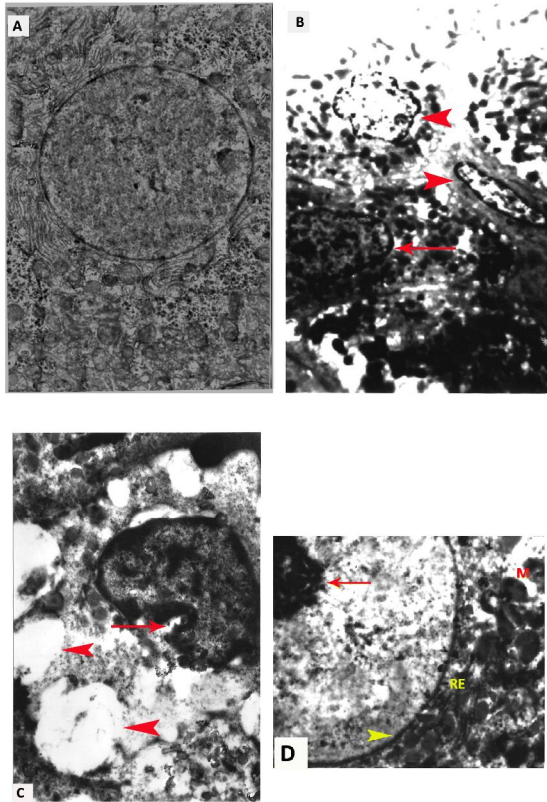
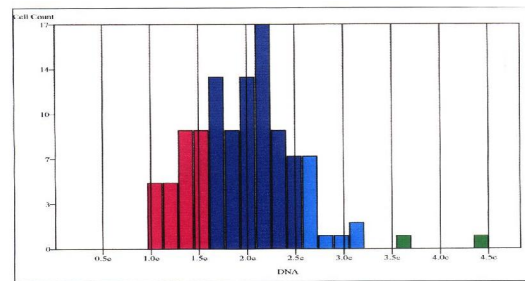


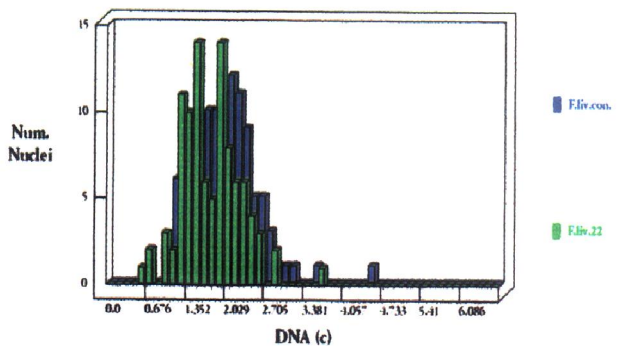
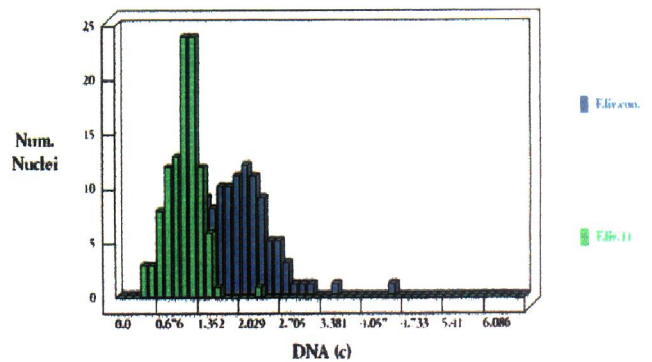
Fig. 4: (A): Photoelectron micrograph of a control adult albino rat (x8000), (B): Electron micrograph of hepatocytes treated with Nolvadex showing swollen mitochondria with dense matrix, partial clumping of nuclear chromatine (arrow) and nuclear shrinkage (arrow head) (x6000). (C): Another field of electron micrograph of hepatocytes treated with Nolvadex showing dilatation of endoplasmic reticulum with no obvious ribosomes (arrow head) the nuclear membrane is corrugated. (arrow) (x 10000). (D): treated group with a combination of vitamin C & E along with Nolvadex showing well-defined nucleolus (arrow) and nuclear envelope (arrow head). Also seen normal-shaped rough endoplasmic reticulum (RE), although mitochondria (M) are still dilated. (x 6000).

Histogram (1): DNA Ploidy of the Control Rat Liver



Histogram (2) & Table (2): DNA Ploidy of Rat Liver Treated with Tamoxifen.

Histogram (2): DNA Ploidy of Rat Liver Treated with Nolvadex.



Histogram (3): DNA Ploidy of Rat Liver Treated with Nolvadex along with Vitamin C .

4. Discussion

Nolvadex is a triphenyl ethylene derivative commonly used in the treatment of breast cancer (Kennel et al., 2003 and Mati & Chen, 2003). Nolvadex is known to have varied biological effects ranging from complete estrogen antagonism to pure estrogen agonism depending upon its concentrations, the sex of animals and target organ (Williams, 1984). In humans and rats Nolvadex is predominantly antiestrogenic with residual estrogenic activities (Furr and Jordan, 1984).

Rat liver is an organ with especial sensitivity of developing tumors after exposure to many chemicals and drugs (Maronpot et al., 1995). The rat at which the liver tumors develop is known to be strongly influenced by Nolvadex's promoting effect on hepatocyte proliferation where sustained proliferation has also been associated with chronic cell death (Carthew et al., 1996).

The microscopical appearance of liver in rats receiving 20mg/kg b.w. of Nolvadex by an oral route for two weeks was characterized by vacuolar degeneration and hydropic degeneration. Results of this work go in agreement with Hirsimaki et al., (1993) who noticed that the treatment of rats with Nolvadex at dose level of 45 mg/kg b.w. for two weeks caused vacuolar degeneration in the liver of rats. In controversy Kasahara et al., (2002) stated that no pathological changes could be noticed in the liver of rats treated with Nolvadex at dose level of 20 mg/kg b.w. for two weeks. Pathological altered cell foci and placental form of glutathione s-transferase (GST-P) positive foci were observed in the liver after 12 weeks. Treatment for 52 weeks resulted in the formation of liver hyperplastic nodules that strongly expressed GST-P. According to Badawy et al., (2002) the treatment of rabbit with Nolvadex at dose level of 14 mg/kg b.w. daily for 60 days induced histopathological changes in the testis in the form of vacuolar degeneration of spermatogenic cells, atrophied and collapsed seminiferous tubules with asospermia.

Vacuolation observed in the present study may be due expansion of the mitochondrial intermembrane space and extension of the outer mitochondrial membrane (Higgins et al., 2003) consistent with ultrastructural changes observed in the present study. Vacuolation may be due to disturbance of ionic milieu of the cell with consequent retention of water and sodium leading to cellular swelling (Jaarsma et al., 2001 and Wiedemann et al., 2002).

Nolvadex was associated with higher risk of development of non-alcoholic steatohepatitis only in overweight and obese women (Bruno et al., 2005). Adjuvant Nolvadex increases the incidence of fatty liver in patients with breast cancer (Liu et al., 2006). In the present work fatty changes were observed in the

liver after treatment of rats with Nolvadex only. Fatty change observed in the present work may be due to damage in rough endoplasmic reticulum confirmed by electron microscopic changes observed in the present work, impaired protein synthesis and inhibition of lipoprotein manufacture. The latter is involved in the transport to hepatic triglycerides to extrahepatic tissue and its inhibition results in accumulation of fat in the cytoplasm (Deboyser et al., 1989). According to Marzouk (1995) mitochondria are known to contain many of the enzymes necessary for the metabolism of triglycerides (i.e. fatty acid oxidases). This leads to another explanation that the fatty changes observed in the present work may be due to mitochondrial damage.

Nolvadex decreases hepatic triglyceride secretion, and it accumulates electrophoretically in mitochondria, where it impairs β -oxidation and respiration. Nolvadex also inhibits topoisomerases and mitochondrial DNA synthesis and progressively depletes hepatic mitochondrial DNA in vivo. These combined effects could decrease fat removal from the liver, thus causing hepatic steatosis despite the secondary down-regulation of hepatic fatty acid synthase expression (Larosche et al; 2007).

In the present work the treatment of rats with Nolvadex only induced foci of necrosis, signs of degeneration in the form of, karyolysis, karyorhexis and fibrosis of hepatocytes. Displastic cells could be noticed. These results were in agreement with Hirsimaki et al. (1993) they noticed that the treatment of rats with Nolvadex only induced area of hepatic necrosis and apoptosis. In controversy Coe et al., (1992) reported that subcutaneous injection of Nolvadex alone at dose level of 0.1mg (5mg) did not cause degenerative changes or neoplastic lesions in Armenian hamster. Also Sauvez et al. (1999) they found that the treatment of rats with Nolvadex induced biliary proliferation and peribiliary fibrosis and degeneration of hepatocytes. Coinciding with Smith et al. (2000), they reported that Nolvadex revealed tissue damage and carcinogenic changes in rats by an oral route.

The hepatic fibrosis observed in the present study may be due to increased level of malondialdehyde (MDA) and decreased production of superoxide dismutase (SOD) and glutathione peroxidase in the liver cells. Oxidative stress plays a role in the development of hepatic fibrosis and degeneration (Duthie et al., 1995). According to Hu et al. (2003) one of the proposed pathways for the metabolic activation of Nolvadex involves oxidation to 4-hydroxytamoxifen which may further oxidized to an electrophilic quinone methide and may affect cytochrome P-450. However, Badawy et al. (2002) they reported that the administration of Nolvadex caused the production of reactive oxygen species

(ROS) which can damage the cellular elements. Oxidative modifications of DNA, protein and lipid by ROS play a role in ageing and disease.

In the present work the pathological changes observed in the liver of rats due to oral route of Nolvadex may be due to lipid peroxidation and free radicals. Free radical may propagate damage in the endoplasmic reticulum and oxidation of membrane component of the liver cells consistent with ultrastructural changes observed in the present work. Oxidation has been shown to be associated with apoptosis (Programmed cell death) (Mohan et al., 2003). The effects of Nolvadex may be neutralized by radical scavenger antioxidants such as vitamin C and /or vitamin E (Babu et al., 2000).

In the present work the oral administration of vitamin C prior to administration of Nolvadex showed some improvement in pathological changes in comparison with group of rats subjected to Nolvadex only. According to Okolie and Iroanya (2003) the supplementation of vitamin C led to marked reduction of histopathological degeneration in tissues by toxic agents. Vitamin c exerted antioxidant action and free radical scavenger (Barros et al., 2004). Coinciding with Sharma and Slocum (1999), they reported that vitamin C adverse some pathological changes induced in liver of rats treated with Nolvadex. According to Sharma et al., (2003) ascorbic acid reduced the level of alpha hydroxytamoxifen substantially (68.9%) when exposure of endometrial explanted culture to 100 micro M Nolvadex and 1mM ascorbic acid.

The treatment of rats with vitamin E conditioned the adverse effect of Nolvadex in liver of rats. According to Custodio et al. (1994) oral administration of antioxidant such as vitamin E has a high protective capacity of vitamin against lipid peroxidation. Also Inal and Kahraman (2000) they reported that vitamin E exerted the antioxidant action and can interfere with the production of reactive oxygen species and other reactive oxygen species scavengers such as glutathione peroxidase, superoxide dismutase, xanthine and increase glutathione in cells.

In the present work the treatment of rats with vitamin E prior to administration of Nolvadex showed marked diminution of vacuolar degeneration and fatty changes. Crewe et al. (2002) found that the vitamin E may be possible therapeutic agent with potential applications against pathological states due to reactive oxygen species. Coinciding with Babu et al. (2000) they demonstrated that vitamin E adverse some pathological changes induced in tissue of rats treated with Nolvadex. Vitamin E also decreased dimethyl valeronitrile induced phospholipid peroxidation. Also Mohan et al. (2003) reported that the pretreatment of rats with vitamin E inhibited apoptosis by acting a quite upstream in the apoptosis cascade at the

mitochondrial level as well as down stream at the caspase.

In the present work the treatment of rats with combination of the two vitamins (vitamin C and vitamin E) before an oral route of Nolvadex showed more improvement in the pathological changes. Results of this work go in agreement with Prasad et al. (1994) who reported that a mixture of vitamins (vitamin C and vitamin E) were more effective in reducing the effect of Nolvadex on tissue damage and they were more effective in reducing growth of human melanoma cells. In the previous studies of Babu et al. (2000) showed that the combined effect of Nolvadex, vitamin C and vitamin E encumber the abnormalities investigated by Nolvadex.

The measurement of DNA ploidy has the advantages of being precise, rapid and quantitative, (Filipe et al., 1991). Image cytometry for DNA quantification has become an established technique in the field of analytical cellular pathology, used as an important parameter providing significant information about the biological behavior of tumors (Cohen, 1996). Concerning ploidy results, the treatment of rats with Nolvadex only resulted in decreased nuclear DNA content, 93.54% of the examined cells contained DNA <1.5c i.e hypoploidy and low proliferation index. 6.54% of the examined cells contained diploid DNA value. These results go in agreement with (Phillips, 2001 and Cardoso et al. 2003) who reported that, the mechanism by which Nolvadex causes liver cancer in rats is through accumulation of DNA damage, caused by adduct formation between Nolvadex and hepatocytes DNA. According to Süzme et al. (2001) Nolvadex injections induced DNA aneuploidy, but did not stimulate proliferation in the liver as estimated by S-phase fraction. Friedlander et al. (1984) found that the normal human somatic cell contains 46 chromosomes which is referred diploid (2n), the gametes contain one set of chromosomes (23) referred to as haploid. While a cell with fewer or more than 46 chromosomes is described as hypoploid or hyperploid respectively. Also Umenoto et al. (2001) found that DNA adduct is formed when chemical carcinogen or their metabolites bind covalently with DNA. On the other hand Sierens et al. (2001) and Kasahara et al. (2003) found that Nolvadex has demonstrated genotox activity in rat liver causing unscheduled DNA synthesis and hepatic aneuploidy. They added that tamoxifen causes hepatic tumors through a genotoxic mechanism. Moreover Dragan et al. (1998) found that the treatment of rats with Nolvadex resulted in a shift of DNA from tetraploid to diploid. Marrero et al. (1996) reported that the cellular DNA content is abnormal at an early stage in dysplasia and may even predate it. Increasing value of abnormal DNA content is related to the severity of dysplasia. Also Carthew et

al. (1997) explained that the endogenous DNA damage was not generated by estrogen receptor mechanisms but by microsomal cytochrome p-450 mediated redox cycling of catechol estrogen.

In the present work the treatment of rats with vitamin C along with Nolvadex showing improvement in DNA content as compared to group of rats treated with Nolvadex only. According to Nefic (2001) vitamin C (ascorbic acid) is an antioxidant that can scavenge free radicals and protect cellular macromolecules, including DNA, from oxidative damage induced by different agents. Some studies indicated that vitamin C is much more than just an antioxidant; it regulates the expression of some genes participating in apoptosis or DNA repair processes (Konopacka, 2004). Also, vitamin C provides high ability to decrease the number of aneuploid DNA value. Tarin et al., (1998) reported that the DNA aneuploid and diploid were highly increased in mouse treated with some toxic agents and decreased DNA aneuploid after administration of vitamin C. They added that mixture of vitamins C and vitamin E induced more improvement in DNA content.

In the present work the treatment of rats with Nolvadex only showed marked diminution in protein content. These results disagreement with Kulesar and Gergely (1991) stated that Nolvadex caused protein synthesis in healthy and in injured liver. These results were in agreement with Gong et al. (1999) who reported that the Nolvadex or 4-hydroxytamoxifen caused decrease in mRNA and protein levels depending on time and dose. Also Divi et al. (2001) noticed that Nolvadex induces the formation of hepatic enzyme altered foci that have lost the capacity to metabolize the drug to DNA binding species. Nolvadex induced modified mitochondrial DNA or Nolvadex modified protein. On the other hand Matin et al. (1987) showed that subcellular fractionation of mouse liver showed that 82% of the antiestrogen binding protein was associated with the rough endoplasmic reticulum where it was confined to the membranous component. The antiestrogen binding protein was also present in smooth endoplasmic reticulum, nuclei and cytosol. High affinity of protein was recorded in tissue of mouse treated with Nolvadex

In the present work the treatment of rats with vitamin C and/or vitamin E prior to administration of Nolvadex produced more improvement in protein content. These results are in agreement with Sierens et al. (2001) who stated that the antioxidant species may act in vivo to decrease damage of protein content in tissues. However Sharma et al. (2003) noticed that the antioxidants vitamin C & vitamin E play an important role in stimulating intercellular signals indirectly for activation of gene responsible for protein synthesis related to DNA repair.

Results of the present work showed that the oral administration of rats with Nolvadex produced marked diminution in mucopolysaccharides content. Results of this work go in agreement with Kulesar and Gergely (1991) who found that Nolvadex caused moderate glycogen loss in liver lesion. According to Hirsimaki et al. (1993) the amount of smooth endoplasmic reticulum appeared to be increased in some cells after administration of Nolvadex at the dose level of 45 mg/kg at total period of 52 weeks.

Depletion of glycogen that was observed in the present study was most probably consequent to hydropic and fatty degeneration manifested in this work, or due damaging effect of Nolvadex on the cytoplasmic organelles and the associated enzymes. However Poop and Cattley (1991) reported that the decrease in mucopolysaccharides content in tissues may be due to disturbed role of Golgi apparatus which is responsible for synthesis of polysaccharides.

In the present work the treatment of rats with Nolvadex only showed swollen mitochondria with dense matrix. According to Hirota (1997) Nolvadex induced mitochondrial disappearance of cristae. However Hoyta et al. (2000) stated that high concentration of Nolvadex (100micro M) caused mitochondrial depolarization. Also Andreassen et al. (2000) reported that mitochondrial dysfunction can lead to energy deficiency, ionic imbalance, elevated reactive oxygen species (ROS) and oxidative damage. The mitochondrial vacuolation and swelling represent an accelerated form of mitochondrial damage caused by high level of mutant superoxide dismutase accumulation (Wang et al., 2002).

The liver of rats treated with Nolvadex only showed dilated endoplasmic reticulum with no obvious attached ribosomes. According to Hirota (1997) Nolvadex induced damage of granular endoplasmic reticulae. The dilatation of endoplasmic reticulum may be the cause of vacuolation of the cytoplasm observed by light microscope in the liver of rats treated with Nolvadex only. The dilatation of rough endoplasmic reticulum was considered by Robbin et al. (1984) to be reaction to cell injury. Detachment of ribosomes most probably reflected a disturbance in protein synthesis confirmed by histochemical changes observed in the present work. According to Traynor and Hall (1981) the increase of protein catabolism is a major effect of the body's response to stress.

Conclusion:

Nolvadex treatment induces liver damage that was performed by histopathological, histochemical and ultrastructural changes. These changes may be due to the production of reactive oxygen species (ROS) which could damage the cellular elements. The using

of vitamin C and/ or vitamin E ameliorate the harmful effects of Nolvadex. This protection may be due antioxidant action which can interfere with production of reactive oxygen species scavengers such as glutathione peroxidase, superoxide dismutase, xanthine and increase glutathione in cells.

Correspondence to:

Amina GamalelDin
National Research Centre
Dokki, Cairo, 12622, Egypt
Phone: +202 3371382/3371 433
Mobile: +2 012 34 32 554
Fax: +202 3370931/33478742
Email: hassaneinamina@yahoo.com

References:

- Ambros MC, Podczeczek F, Podczeczek H and Newton JM (1998): The characterization of the mechanical strength of chewable tablets. *Pharm. Dev. Technol.*, (4): 509-515.
- Ames BN (1983): Dietary carcinogens and anticarcinogens of oxygen radicals and degenerative diseases. *Science*, 211: 1256-1262.
- Andreassen OA, Ferrante RJ, Klivenyi P, et al. (2000): Paratotal deficiency of manganese superoxide dismutase exacerbates a transgenic mouse model of amyotrophic lateral sclerosis. *Ann. Neurol.*, 47: 447-455.
- Babu JR, Sundravel S, Arumugam G, et al. (2000): Salubrious effect of vitamin C and vitamin E on tamoxifen treated women in breast cancer with reference to plasma lipid and lipoprotein levels. *Cancer Lett.*, 3, 151 (1): 1-5.
- Badawy SA, El-Far FI and Amer HA (2002): Testicular and post testicular role of estrogen in adult male rabbit. *Egypt. J. Basic and Appl. Physiol.*, 1(2): 269-280.
- Barros PS, Safatle AM, Queiroz I, et al. (2004): Blood and aqueous humor antioxidants in cataractous poodles. *Can. J. Ophthalmol.*, 39 (1): 19-24.
- Barton DL, Loprinzi CL, Quella SK, et al. (1998): Prospective evaluation of vitamin E for hot flashes in breast cancer survivors. *J. Clin. Oncol.*, 16 (2): 495-500.
- Behl C (2000): Vitamin E protects neurons against oxidative cell death in vitro more effectively than 17-beta estradiol and induces the activity of the transcription factor NF-Kappa B. *J. Neurol. Transm.*, 107 (4): 393-407.
- Beland FA, McDaniel LP and Marques MM (1999): Comparison of the DNA adducts formed by tamoxifen and 4-hydroxytamoxifen in vivo. *Carcinogenesis*, 20 (3): 471-477.
- Biri H, Ozturk HS, Buyukkocak C, et al. (1998): Antioxidant defense potential of rabbit tissues after Eswi: Protective effects of antioxidants vitamins; *Nephron.*, 79 (2): 181-185.
- Bruno S, Maisonneuve P, Castellana P, et al. (2005): Incidence and risk factors for non-alcoholic steatohepatitis: prospective study of 5408 women enrolled in Italian tamoxifen chemoprevention trial. *Br. Med. J.* 330: 932
- Butterfield DA, Koppal T, Subramanian R and Yatin S (1999): Vitamin E as an antioxidant free radical scavenger against amyloid beta-peptide induced oxidative stress in neocortical synaptosomal membrane and hippocampal neurons in culture: insights into Alzheimer's disease. *Rev. Neuro. Sci.*, 10 (2): 141-149.
- Cardoso CM, Morea OAJ, Almeida M and Castodio JB (2003): Comparison of the changes in adenine nucleotides of rat liver mitochondria induced by tamoxifen and 4-hydroxytamoxifen. *Toxicol.*, 17 (16): 663-670.
- Carthew P, Edwards RE and Nolan BM (1997): Depletion of hepatocyte nuclear estrogen receptor expression is associated with promotion of tamoxifen induced GST-P foci to tumours in rat liver. *Carcinogenesis*, 18 (5): 1109-1112.
- Carthew p, Nobn BM, Edwards RE and Smith LL (1996): The role of cell death and cell proliferation in the promotion of rat liver tumors by tamoxifen. *Cancer Lett.*, 106: 163-169.
- Coe JE, Ishak KG, Ward JM and Ross MJ (1992): Tamoxifen prevents induction hepatic neoplasia by zearanol, an estrogenic food contaminants. *Proc. Natl. Acad. Sci.*, 89: 1085-1089.
- Cohen C (1996): Image cytometric analysis in pathology. *Hum. Pathol.*, 27: 482-493.
- Costa GG, Mc-Daniel-Hamilton LP, Heflich RH, et al. (2001): DNA adducts formation and mutagenesis induction in Sprague. Dawley in rats treated with tamoxifen and its derivatives. *Carcinogenesis*, 22 (8): 1307-1315.
- Crewe HK, Nothey LM, Wunach RM, et al. (2002): Metabolism of tamoxifen by recombinant human cytochrome p 450 enzymes: formation of the 4- hydroxy and N-desmethyl metabolites and isomerization of trans-4- hydroxy-tamoxifen. *Drug Metab. Dispos.*, 30 (8): 869-874.

19. Curtis RF, Freedman DM, Sherman MF and Fraumeni JF (2004): Risk of malignant mixed müllerian tumors after tamoxifen therapy for breast cancer. *J. Nat. Cancer Inst.*, 7, 96 (1): 70-74.
20. Custodio JB, Dinis TC, Slmeida LM and Madeira VM (1994): Tamoxifen and hydroxytamoxifen as intramembraneous inhibitors of lipid peroxidation. Evidence for peroxyl radical scavenging activity. *Biochem. Pharmacol.*, 1 (11): 1989-1998.
21. Danque PD, Chen HB, Patil J, et al. (1993): Image analysis versus flow cytometry for DNA ploidy Quantitation of solid tumors: A comparison of six methods of sample preparation. *Mod. Pathol.* 6: 270-275.
22. Deboyser D, Goethals F, Krack G and Robertroid M (1989): Investigation into the mechanism of tetracycline induced steatosis: study in isolated hepatocytes. *Toxicol. Appl. Pharmacol.*, 97: 473-479.
23. Decensi A, Bonanni B, Guerrieri A, et al. (1998): Biologic activity of tamoxifen at low doses in healthy women. *J. Natl. Cancer. Inst.*, 90: 146-1467.
24. Divi RL, Dragam YP, Pitot HC and Poirler MC (2001): Immunohistochemical localization and semiquantitation of hepatic tamoxifen DNA adducts in rats exposed orally by tamoxifen. *Carcinogenesis*, 22 (10): 1693-1699.
25. Dragan YP, Shimel RJ, Bahhub N, et al. (1998): Effect of chronic of mesfranol, Tamoxifen and Toremifene on hepatic ploid in rats. *Toxicological Sciences*, 43 (2): 129-138.
26. Dray X, Tainturier MH, De La Lande P, et al. (2000): Cirrhosis with non alcoholic steatohepatitis: role of tamoxifen. *Gastroenterol. Clin. Biol.*, 24(11):1122-1123.
27. Drury RAB and Wallington FA (1980): Corleton's Histological Technique 4th Ed. Oxford, New York, Toronto, Oxford university press.
28. Dsouza UJ (2003): Tamoxifen induces multinucleated cells (symplasts) and distortion of seminiferous tubules in rats' testes. *Asian J. Androl.*, 5 (3): 217-220.
29. Duthie SJ, Melvin WT and Burke MD (1995): Drug toxicity mechanisms in human hepatoma Hep G2 cells: cyclosporin A and tamoxifen. 25 (10); 1151-1164.
30. Eisner A, Austin DF and Samples JR (2004): Short wave length automated perimetry and tamoxifen uses. *Br. J. Ophthalmol.*, 88 (1): 125-130.
31. Epstein MD, Samuel S and David S (1997): The Breast Cancer Prevention program. Macmillan, New York. PP 145.
32. Feulgen R and Rosenbeck HC (1942): Manual of Histological Demonstration Technique. Butter worth & Co (publishers) Ltd. London, Therford, havrhill.
33. Filipe MI, Rosa FJ, Sandey A, et al. (1991): DNA ploidy and proliferative activity of prognostic value in advanced gastric carcinoma. *Hum. Pathol.*, 22: 373-378.
34. Fisher DE (1994): Apoptosis in cancer therapy: crossing the threshold. *Cell.* 78:539-542
35. Fong CJ, Burgoon LD, Williams KJ, et al. (2007): Comparative temporal and dose-dependent morphological and transcriptional uterine effects elicited by tamoxifen and ethynylestradiol in immature, ovariectomized mice. *BMC Genomics*, 8: 151.
36. Freidlander L, Michael L, David W and Heldely H (1984): Clinical and biological significance of aneuploid in human tumors. *J. Clin. Pathol.*, 37: 691-974.
37. Furr BJA and Jordan VC (1984): The pharmacology and clinical uses of tamoxifen. *Pharmacol. Ther.*, 25: 127-205.
38. Geetha A, Sankar R, Marar T and Davi CS (1990): Alpha tocopherol reduces doxorubicin idnuced toxicity in rats histological and biochemical evidences. *Indian J. Physiol. Pharmacol.*, 37 (2): 94-100.
39. Gong Y, Zhong M and Minuk GY (1999): Regulation of transforming growth factor betal gene expression and cell proliferation in human hepatocellular carcinoma cells (PLC/PRF/5) by tamoxifen. *J. Lab. Clin. Med.*, 1 (1): 90-95.
40. Goss PE and Stresses-Weipple K (2004): Aromatase inhibitors for chemoprevention. *Best Pract. Res. Clin. Endocrinol. Metab.*, 18 (1): 113-130.
41. Hamada N, Ogawa Y, Saibara T, et al. (2000): Toremifene-induced fatty liver and NASH in breast cancer patients with breast-conservation treatment. *Int. J. Oncol.*, 17(6):1119-1123.
42. Higgins CM, Jung C, Ding H and Xu Z (2003): Mutant Cu, Zn supreoxide dismutase that causes motonuron degeneration is present in mitochondria in the CNC. *J. Neuro. Sci.*, 22: 215.
43. Hirota T (1997): Ultrastructural study of anti-tumor effects of tamoxifen in two malignant melanoma patients. *J. Dermatol.*, 1 24 (7): 441-450.
44. Hirsimaki P, Hirsimaki Y, Neiminen L and Joe-Payne B (1993): Tamoxifen induced hepatocellular carcinoma in rat liver: A-1 year

- study with antiestrogen. *Arch. Toxicol.*, 67: 49-54.
45. Hoyta KR, Mclaughlin BA, Higgins DS and Reynolds IJ (2000). Inhibition of glutamate induced mitochondrial depolarization by tamoxifen in cultured neurons. *J. Pharmacol. Exp. Ther.*, 293 (2) 480-486.
 46. Hu Y, Dehal SS, Hynd G, et al. (2003): Cyp5B6 mediated catalysis of tamoxifen aromatic hydroxylation with NIII shift: Similar hydroxylation mechanism in chicken rat and human liver microsomes. *Xenobiotica*, 33 (2): 141-151.
 47. Inal EM and Kahraman A (2000): The protective effect of flavonol quercetin against ultraviolet A induced oxidative stress in rats. *Toxicology*, 23, 154 (3): 21-29.
 48. Jaarsma D, Rognoni F, Van Dugn W, et al. (2001): Cu Zn superoxide dismutase (SODI) accumulates in vacuolated mitochondria in transgenic mice expression amyotrophic lateral sclerosis linked SODI mutations. *Acta Neuropathol.*, 102: 293-305.
 49. Johnson MD, Zuo H, Lee KH, et al. (2004): Pharmacological characterization of 4-hydroxy-N-desmethyl tamoxifen, a novel active metabolite of tamoxifen. *Breast Cancer Res. Treat.*, 85:151-159.
 50. Kasahara T, Hashiba M, Harada T and Degawa M (2002): Change in gene expression of hepatic tamoxifen metabolizing enzymes during the process of tamoxifen induced hepatocarcinogenesis in female rats. *Carcinogenesis*, 23 (3): 491-498.
 51. Kasahara T, Kuwaysma C, Hashiba M, et al. (2003): The gene expression of hepatic proteins responsible for DNA repair and cell proliferation in tamoxifen induced hepatocarcinogenesis. *Cancer Sci.*, 94 (7): 582-588.
 52. Kennel PC, Pallen C, Barale-Thomas E, et al. (2003): Tamoxifen: 28 day oral toxicity study in the rat based on the enhanced OECD test guideline 407 to detect endocrine effects. *Regulatory toxicology*, 10: 1-25.
 53. Kim SY, Suzuki NYR, Laxmi S, et al. (2006): Antiestrogens and the formation of DNA damage in rats: A comparison. *Chem. Res. Toxicol.*, 19(6): 852-858.
 54. Klatter ET, Scharrer DW, Nagaraja HN, et al. (2003): Combination therapy of donepezil and vitamin E in Alzheimer disease. *Alzheimer Dis. Assoc. Disord.*, 17(2): 113-116.
 55. Konopacka M (2004): Role of vitamin C in oxidative DNA damage. *Postepy Hig. Med. Dosw.*, 58:343-348.
 56. Kulesar A and Gergely KJ (1991): Effect of tamoxifen and levonorgestrel treatment on carbon tetrachloride induced alterations in rats. *Arzneimittel forschung.*, 41 (12): 1298-1301.
 57. Kurata M, Zuzuki M and Agar NS (1993): Antioxidant system and erythrocyte life span in mammals. *Comp. Physiol.*, 106 (3): 477-487.
 58. Larosche I, Lettèron P, Fromenty B, et al. (2007): Tamoxifen Inhibits Topoisomerases, Depletes Mitochondrial DNA, and Triggers Steatosis in Mouse Liver. *Journal of Pharmacology and Experimental Therapeutics*, JPET 321:526-535.
 59. Lee KH, Lee JS, Lee JH, Kim, et al. (1999): Prognostic value of DNA flow cytometry in stomach cancer: a 5-year prospective study. *Br. J. Cancer* 79(11-12): 1727-1735.
 60. Lelliott CJ, López M, Curtis RK, et al. (2005): Transcript and metabolite analysis of the effects of tamoxifen in rat liver reveals inhibition of fatty acid synthesis in the presence of hepatic steatosis. *FASEB J.* 19: 1108-1119
 61. Liu L, Huang JK, Cheng SP, et al. (2006): Fatty liver and transaminase changes with adjuvant tamoxifen therapy. *Anticancer Drugs*, 17(6):709-713.
 62. Lo SS and Vogel VG (2004): Endocrine prevention of breast cancer using selective oestrogen receptor modulators (SORMS). *Best. Pract. Res. Clin. Endocrinol. Metab.*, 18 (1): 97-111.
 63. Mac-Manus JPA and Cason JE (1950): Carbohydrate histochemistry studies by a cetylation technique. *Periodic acid method. J. Exp. Med.*, 91: 651.
 64. Maronpot RR, Fox T, Malarkey DE and Goldsworthy TL (1995): Mutations in rats Photo-oncogene: clues to etiology and molecular pathogenesis of mouse liver tumors. *Toxicology*, 101: 125-156.
 65. Marrero JM, De-Caestecker JS, Corbishley CM, et al. (1996): Gastric DNA content in postgastrectomy patients. Relationship to mucosal dysplasia. *Cancer*, 77 (1): 19-24.
 66. Marzouk AS (1995): The effect of 20 hydroxy ecdysone on the secretory cells of the removal gland in the tick. (*yalamma*. "Hyalomma" dromedril) Acari: Ixodoidea: Ixodidae). *Egypt. J. Histol.* 15 (2): 603-613.
 67. Masaki KH, Losonczy KG, Izmirlan G, et al. (2000): Association of vitamin E and supplement use cognitive function and dementia in elderly men. *Neurology*, 28 (6): 1265-1272.
 68. Masson P (1929): Some histological methods. Trichrome stainings and their preliminary

- technique. *Bulletin of the International Association of Medicine*, 12,75. Cited from: Bancroft J and Stevens A (1982): *Theory and Practice of Histological Techniques*, 2nd Ed, pp131- 135, Churchill-Livingstone, NY.
69. Mati S and Chen G (2003): Tamoxifen induction of aryl-sulfotransferase and hydroxy steroid sulfotransferase in male and female rat liver and intestine. *Drug metab. Dispos.*, 31 (5): 637-644.
 70. Matin A, Hwang PI and Kon OI (1987): Murine antiestrogen binding protein characterization, solubilization and modulation by lipids. *Biochem. Biophys. Acta.* 10 (3): 36-75.
 71. Mazia D, Drewer PA and Alfert M (1953): The cytochemical staining and measurement of protein with mercuric bromophenol blue. *Biol. Bull.*, 104: 57-67.
 72. Meves A, Stock SN, Beyerle A, et al. (2002): Vitamin C derivatives a scorbyl palmitate promotes ultraviolet B-induced peroxidation and cytotoxicity in kartinocytes. *J. Invest. Dermatol.*, 119 (5): 1103-1108.
 73. Mohan M, Taneja TK, Sahaev S, et al. (2003): Antioxidants prevent UV induced apoptosis by inhibiting mitochondrial cytochrome C release and caspase activation in *spodoptera frugiperda* (sf9) cells. *Cell Biol. Int.*, 27 (6): 483-490.
 74. Nagyova A, Galbavy A and Ginter E (1994): Histopathological evidence of vitamin C protection against cadmium nephrotoxicity in guinea pig. *Exp. Toxic. Pathol.*, 46: 11-14.
 75. Napoli C, Williams I S, Denigris F, et al. (2004): Long term combined beneficial effects of physical training and metabolic treatment on atherosclerosis in hypercholesterolemic mice. *Proc. Natl. Acad. Sci.*, 8: 101 (23): 8797-8802.
 76. Nefic H (2001): Anticlastogenic effect of vitamin C on cisplatin induced chromosome aberrations in human lymphocyte cultures. *Mutat. Res.*, 15 (2): 89-98.
 77. Newboid RR, Jefferson WN and Padilla burgos E (1997): Neonatally treated with tamoxifen. *Carcinogenesis (Lond)*, 18: 2293-2298.
 78. Nishino M, Hayakawa K, Nakamura Y, et al. (2003): Effects of tamoxifen on hepatic fat content and the development of hepatic steatosis in patients with breast cancer: high frequency of involvement and rapid reversal after completion of tamoxifen therapy. *Am. J. Roentgenol.*, 180: 129-134.
 79. Norazlina M, Ima- Nirwona S, Gapo MT and Khalid BA (2000): Palm vitamin E is comparable to alpha tocopherol in maintaining bone mineral density in ovariectomized female rats. *Exp. Clin Endocrinol. Diabetes*, 108 (4): 305-310.
 80. Oien KA, Moffat D, Curry GW, et al. (1999): Cirrhosis with steatohepatitis after adjuvant tamoxifen. *Lancet*, 353: 36-37
 81. Okolie NP and Iroanya CU (2003): Some histological and biochemical evidence for mitigation of cyanide induced tissue lesions by antioxidants vitamins administration in rabbits. *Food Chem. Toxicol.*, 41 (4): 465-469.
 82. Osman KA, Osman MM and Ahmed MH. (2007): Tamoxifen-induced non-alcoholic steatohepatitis: where are we now and where are we going? *Expert. Opin. Drug Saf.*, 6(1):1-4.
 83. Padget GE and Barnes JM (1964): *Evaluation of Drug Activities Pharmacometrics*. Vol. 1-Academic press. London, New York.
 84. Phillips DH (2001): Understanding the genotoxicity of tamoxifen. *Carcinogenesis*, 22 (6): 839-849.
 85. Popp J A and Cattely RC (1991): *Hepatobiliary System in: Handbook of Toxicology and Pathology*. Academic press, inc. London 14, pp. 279.
 86. Prasad KN, Hernandez C, Edwards-Prasad J, et al. (1994): Modification of the effect of tamoxifen, cisplatin, DTIC, and interferon alpha 2b on human melanoma cells in culture by mixture of vitamins. *Nutr. Cancer*, 22 (3): 233-245.
 87. Robbin's SL, Cotran RS and Kumar V (1984): *Pathologic Basis of Disease*. 3rd ed. Philadelphia, London, Toronto: WB Saunders company, 1-39.
 88. Sauvez F, Drouin D, Attia A, et al. (1999): Cutaneously applied 4- hydroxytamoxifen is not carcinogenic in female rats. *Carcinogenesis*, 20 (5): 843-850.
 89. Sellman S (1998): Tamoxifen amajor medical mistake? Extracted from Nexus Magazine, 5: 4.
 90. Sharma M and Slocum HK (1999): Prevention of Quinon mediated DNA arylation by antioxidants. *Biochem. Biophys. Res. Commun.*, 7: 262(3): 769-774.
 91. Sharma M, Shubert DE, Sharma M, et al. (2003): Antioxidants inhibits tamoxifen DNA adducts in endometrial explant culture. *Biochem. Biophys. Res. Commun.*, 18 (1): 157-164.
 92. Shibutani S, Shaw PM, Suzuki N, et al. (1998): Sulfation of α -hydroxytamoxifen catalyzed by

- human hydroxysteroid sulfotransferase results in tamoxifen-DNA adducts. *Carcinogenesis*, 19, 2007–2011
93. Sierens J, Hartley JA, Campbell MJ, et al. (2001): Effect of phytoestrogen and antioxidant supplementation on oxidative DNA damage assessed using the comet assay. *Mutat. Res.*, 7: 48 5(2) 169-176.
 94. Smith LL, Brown K, Crathew p, et al. (2000): Chemoprevention of breast cancer by tamoxifen: risks and opportunities. *Crit. Rev. Toxicol.*, 30 (5): 571-594.
 95. Srinivas G, Annab LA, Gopinath G, et al. (2004): Antisense blocking of BRCA1 enhances sensitivity to plumbagin but not tamoxifen in BG-1 ovarian cancer cells. *Mol. Carcinogen*, 39 (1): 15-25.
 96. Steenvoorden DP and Henegouwen BVG (1999): Protection against UV induced systemic immunosuppression in mice by a single topical application of the antioxidant vitamin C and vitamin E. *Int. J. Radial. Res.*, 751 (1): 747-755.
 97. Süzme R Gürdöl F, Deniz G and Ozden T. (2001): Response in DNA ploidy of hepatocytes to tamoxifen and/or melatonin in vivo. *Res. Commun. Mol. Pathol. Pharmacol.*, 109(5-6):275-286.
 98. Tan-Chiu E, Wang J, Castantino JP, et al. (2003): Effect of tamoxifen on benign breast disease in woman at high risk for breast cancer. *J. Natl. Cancer Inst.* 19: 95 (4): 302-307.
 99. Tarin JJ, Vendrell FJ, Ten J and Cano A (1998): Antioxidant therapy counteracts the disturbing effects of didmide and maternal ageing on merotic division and chromosomal segregation in mouse oocytes. *Mol. Hum. Reprod.*, 4 (3): 281-288.
 100. Tousoulis D, Antoniades C, Tountas C, et al. (2003): Vitamin C affects thrombosis/fibrinolysis system and reactive hyperemia in patients with type 2 diabetes and coronary artery disease. *Diabetes Care*, 26 (10): 2749-2753.
 101. Traynor C and Hall GM (1981): Endocrine and metabolic changes during surgery: Anesthesia implications. *Br. J. Anesth.*, 53: 153-160.
 102. Trommer B, Bottcher R, Poppi A, et al. (2002): Role of ascorbic acid in stratum corneum lipid models exposed to UV irradiation. *Pharm. Res.*, 19 (7): 982-990.
 103. Umenoto A, Kamaki K, Monden Y, et al. (2001): Identification and Quantification of tamoxifen DNA adducts in the liver of rats and mice. *Chem. Res. Toxicol.*, 14 (8): 1006-1013.
 104. Vatassery GT, Bauer T and Tysken M (1999): High doses of vitamin E in the treatment of disorders of the central nervous system in the aged. *Am. J. Clin. Nutr.*, 70 (5): 793-801.
 105. Vinitha R, Thangara J M and Sachdanand P (1995): Effect of administering cyclophosphamide and vitamin E on the levels of tumor marker enzymes in rats with experimentally idnuced fibrosarcoma. *Jpm. J. Med. Sci. Biol.*, 48 (3): 145-156.
 106. Wang J, Xu G, Gonzales V, et al. (2002): Fibrillar inclusions and motor nurone degeneration in transgenic expression superoxide dismutase I with a disrupted copper binding site. *Neurobiol. Dis.*, 10: 128-138.
 107. Wang K, Li D and Sun F (2004): Dietry caloric restriction may delay the development of cataract by attenuation the oxidative stress in the lenses of Brown Norway rats. *Exp. Eye. Res.*, 78 (1): 151-158.
 108. Watson MI (1958): Staining of tissue sections for electron microscopy with heavy metals. *J. Biophys. Biochem. Cytolo.*, 4: 475.
 109. Wiedemann FR, Manfredi G, Mawrin C, et al. (2002): Mitochondrial DNA and respiratory chain function in spinal cords of ALS patients. *J. Neurochem.*, 80: 616-625.
 110. Williams GM (1984): Sex hormones and liver cancer. *Lab. Invest.*, 46, 352-354.
 111. Yao K, Latta M and Bird RP (1996): Modulation of colonic aberrant crypt foci and proliferative indexes in colon and prostate glands of rats by vitamin E. *Nutr. Cancer*, 26 (1): 99-109.
 112. Yu MW, Zhang YJ, Blaner WS and Santella RM (1994): Influence of vitamins A, C, E and beta-carotene on aflatoxin B1 binding to DNA in wood chuck hepatocytes. *Cancer*, 73 (3): 596-604.
 113. Zandi PP, Anthony JC, Khachaturian AS, et al. (2004): Reduced risk of Alzhiemer disease in uses of antioxidant vitamin supplements: the cache country study. *Arch. Neurol.*, 61 (1) 82-88.
 114. Zureik M, Glan P, Bertrais S, et al. (2004): Effect of long term daily low dose supplementation with antioxidant vitamins and minerals on structure and function of large arteries. *Arterioscler. Thromb. Vasc. Biol.*, 24(Under Publication).