

Protective Effect Of *Nigella Sativa* Seeds Against Dimethylaminoazobenzene (Dab) Induced Liver Carcinogenesis

H. A. Mohamed¹, I. H. El-Sayed² and M. Moawad³

¹Plant Pathology Institute, Agriculture Research Center, Cairo, Egypt, ²Molecular Biology Department, Genetic Engineering and Biotechnology Institute, Minufiya University, Sadat City, Minufiya, Egypt, and ³Pathology Department, National Cancer Institute, Cairo University, Cairo, Egypt.

ibrahimelsayed@yahoo.com

ABSTRACT: Liver cancer is one of the most common solid tumors worldwide. Extensive research was carried out to document the powerful properties of *Nigella sativa* (*N. sativa*) as an anti-tumor, bactericide, anticestode, antinematode, anti-inflammatory, analgesic, anti-diabetic and diuretic with many other uses. Little is known about the *Nigella sativa* anti-tumor property in liver cancers, thus our current study was performed to investigate the protective role of *Nigella sativa* in DAB induced liver carcinogenesis. 140 male Albino mice weighing 40-50 gm divided into four groups. Group one was normal control group without treatment of any type. Group two was *Nigella sativa* treated control group. Group three was treated with DAB carcinogen. Group four was treated with both *Nigella sativa* and DAB. Biochemical investigations, flow cytometric analysis, and histopathological examination of the liver tissue were performed for all groups. The results showed that there was a significant change in the DNA content, histomorphology, and antioxidant enzymes in the liver tissues of the DAB treated group. These changes were restored to approximately the normal counterpart with *Nigella sativa* treatment. In addition, treatment with *Nigella sativa* only showed comparable results with control untreated groups on different levels. Collectively, these results give clear evidence that *Nigella sativa* alone induce no harmful effects on the liver. Moreover, it exerts hepatoprotective effect against liver carcinogens. Antioxidant property is mediated its actions and investigating other underlying mechanisms merits further studies.

[H. A. Mohamed, I. H. El-Sayed and M. Moawad. **Protective Effect Of *Nigella Sativa* Seeds Against Dimethylaminoazobenzene (Dab) Induced Liver Carcinogenesis.** Cancer Biology 2011;1(1):43-50]. (ISSN: 2150-1041). <http://www.cancer-biology.org>.

Keywords: *Nigella sativa*, Dimethylaminoazobenzene, Liver, antioxidant, Carcinogenesis.

INTRODUCTION

Liver cancer is one of the most common cancers representing a leading cause of cancer related mortality, with an increasing incidence worldwide, being responsible for more than one million deaths annually [1, 2]. Historically, most drugs have been derived from natural products, but there has been a shift away from their use with the increasing predominance of molecular approaches to drug discovery [3]. Among chemotherapeutic or chemopreventive natural sources, *Nigella sativa* seeds come as a good protector being a natural product [4]. *Nigella sativa*, a spicy plant, is cultivated in various parts of the world. The seeds, also known as black cumin or black caraway, are commonly used in the Middle East, Northern Africa and India as a condiment in bread and other dishes. The seeds of *Nigella sativa* have been used for medicinal purposes as a natural remedy for a number of illnesses and conditions that include bronchial asthma, rheumatism, hypertension, diabetes, inflammation, cough, headache, eczema, fever and influenza. The seeds or its oil are also used as carminative, diuretic, lactagogue and vermifuge [5, 6].

The effect of *Nigella sativa* has been evaluated in animal studies. There are many reports on its biological activities including immunopotential,

anti-tumor, anti-inflammatory, analgesic, antihypertensive, anti-diabetic, antiulcerogenic, respiratory stimulation, anti-bacterial, antifungal, anticestode and antinematode effects in the literature [6-8]. *N. sativa* decreases DNA damage and thereby prevents initiation of carcinogenesis in colonic tissue secondary to exposure to toxic agents such as azoxymethane [9]. In fact, sustained delivery of thymoquinone (derived from *N. sativa*) is almost as effective in causing apoptosis of colon cancer cells as sustained delivery of 5-fluorouracil [10]. Similarly, hepatic metastasis from tumors such as mastocytomas is markedly decreased following administration of *N. sativa* [11].

Administration of *N. sativa* oil showed protective effect on the liver of Swiss Albino mice against exposure to radiation [12]. It has been reported that *N. sativa* oil could diminish the CCl₄-induced hepatotoxicity, the doxorubicin-induced cardiotoxicity and the harmful effects of some chemicals [5, 13-19]. Abnormal activities of some enzymes are usually indicative of the hepatic cellular injury in animals and humans [20]. Interrelationships between protective effects of the *N. sativa* oil and harmful effects of CCl₄ have been investigated, and it has been reported that there is protective and antioxidative role of *N. sativa* oil

[5, 14]. Therefore, the present study was designed to investigate the effects of *N. sativa* seeds on activities of functional liver enzymes, antioxidant status and on the liver injury generated by dimethylaminoazobenzene (DAB) in male albino mice through biochemical, histopathological and flow cytometric analyses.

MATERIALS AND METHODS

Animals

A total number of 140 adult male Swiss Albino mice weighing 40-50 g were used in the current study. The animals were maintained on a standard cube diet and free water supply, and were treated for 32 weeks. The animals were divided into four groups each containing 35 rats. The first is the untreated control group. The second is the carcinogen treated group with 0.05% DAB mixed with diet. The third group is the *N. sativa* control group treated only with 5.0 % grinded seeds of *N. sativa* mixed with diet. The fourth group is the treated with 5.0 % *N. sativa* plus 0.05% of DAB mixed with diet. All animals were sacrificed 32 weeks after starting the experiment. The local ethical committee approved the present study.

Blood was collected and sera were separated, divided into aliquots and stored frozen at 70°C till analysis. Liver specimens were cleared of surrounding fat, cut into small pieces and weighed out. 10 % liver homogenates were prepared in distilled water. Samples were kept cold on crushed ice all times during preparation then kept frozen at -70°C till analysis. The serum was used to determine alanine transaminase (ALT), aspartate transaminase (AST), alkaline phosphatase (ALP), total proteins, and serum albumin using standard protocols. Liver tissues specimens of different groups were fixed in 10 % formalin and paraffin embedded for histopathological examination and 5 µm sections were stained with Hematoxylin and Eosin.

Lipid peroxidation and antioxidant enzymes determination

Activity of superoxide dismutase (SOD) was determined by the method of Winterbourn *et al* [21]. Glutathione Peroxidase (GPx), was determined by method of described by Flohe and Gunzler [22]. Catalase (CAT) was determined by methods of Beers and Sizer [23]. Lipid peroxidation was expressed as level of malondialdehyde (MDA) measured using a thiobarbituric acid assay as reported and described earlier by Ohkawa *et al* [24]. Protein determinations were assayed by the method of Lowry *et al* [25].

Flow cytometric analysis

A single-cell suspension of tissue specimens was prepared by mechanical disaggregating in RPMI-1640 medium, filtration through a piece of fine nylon mesh, and centrifugation at 1900g for 10 min to remove debris and cell clumps. The cell suspension then was

permeabilized with Triton-X 100. Cells were stained at room temperature for 2–3 h in 50 µg/mL propidium iodide and 100 U/mL RNase A in phosphate buffer saline. Samples were analyzed with a FACSCalibur cytometer using Cell-Quest software (Beckton Dickinson, San Jose, CA). Propidium iodide-stained samples were analyzed using doublet discrimination, which permits a distinction to be made between the signals coming from a single nucleus and the ones produced by two or more aggregated nuclei. For the computer analysis, only signals from single nuclei were considered. The DNA histogram derived from each specimen was analyzed using the DNA analysis software. DNA content was derived from the DNA index (DI), $DI = G0/G1$ peak average channel value in experimental sample DNA histogram divided by $G0/G1$ peak average channel value in normal cell sample DNA histogram. DNA ploidy was judged according to DI value. DI in diploid cell was 1.0. A diploid DNA histogram was defined as $DI = 1.0 \pm 2CV$ (coefficient of variation). An aneuploid DNA histogram was defined as $DI = 1.0 \pm 2CV$. The results were recorded as normal DNA content (diploid pattern) and abnormal DNA content (aneuploid pattern).

Statistical analysis

The statistical analysis was computed using analysis of variance (ANOVA). The significant mean differences were separated by Duncan's Multiple Range Test. *P* values < 0.05 were considered statistically significant.

RESULTS

The mean body weight of DAB and DAB + N.S treated groups were significantly decreased ($p < 0.001$) compared to the normal control group. The mean body weight of the protected group (DAB+N.S) was not significantly increased compared to the DAB treated group as shown in (Figure. 1).

The obtained results indicated that no significant difference in ALT, AST, ALP, total proteins, and serum albumin between *N. sativa* treated group and untreated control group. Serum ALT and AST were slightly elevated in the DAB treated group when compared to the normal control and other groups. The mean level of serum ALP was significantly increased ($P < 0.001$) in the DAB treated group when compared to the normal control group and to the other groups. The mean level of serum ALP was non-significantly elevated in the DAB plus *N. sativa* treated group when compared to the normal control group (Table 1). The mean body weight of DAB alone, and DAB plus *N. sativa* treated groups were significantly decreased ($P < 0.001$) compared to the normal control group. The body weight of the protected group (DAB plus *N. sativa*) was non-significantly increased compared to the DAB treated group.

The results of antioxidant enzymes and MDA analysis indicated that a pronounced elevation of MDA in the DAB treated group, this elevation was significantly different in comparison to the other three groups. On the hand, this elevation of MDA was accompanied with lowering the level of antioxidant enzymes namely SOD, GPx and CAT in the DAB treated group, this decreasing was significantly different in comparison to the other three groups (Table 2). These results clearly indicate that DAB is affecting the liver negatively by increasing the level of peroxidation and meanwhile decreasing the level of antioxidant protecting enzymes. Moreover, since no differences were existed between the other three groups, reflecting that the *N. sativa* treatment have no harmful effect on the liver, and the *N. sativa* treatment in rats previously treated with DAB can effectively maintain the protective enzymatic balance effectively.

In histomorphology analysis, in the control untreated group, the liver was seen strictly with normal architecture of liver cells and bile ducts. On the other hand, the DAB treated group showed 42.9 % with marked dysplasia of liver cells with cirrhotic liver nodules and the bile ducts showed well differentiated cholangiocarcinoma. 57.1% of this group showed marked bile duct proliferation, early cirrhotic liver changes as well as moderate dysplasia of liver cells.

Regarding the *N. sativa* treated group, it showed absolutely normal architecture of liver cells and bile ducts similar to that of the control group. Finally, the DAB plus *N. sativa* treated group, 28.6% of them showed resistant bile duct proliferation with moderate dysplasia of hepatocytes and the other 71.4% showed no cirrhosis, no bile duct proliferation, dysplasia or carcinoma (Figure 2).

In the flow cytometric analysis, the control untreated group showed a single diploid peak. Similarly, the *N. sativa* treated group showed a single diploid peak as well. Regarding the group of rats treated with DAB only, an additional abnormal peak was detected in 84.6% of samples (aneuploid cells) along with the diploid one. 15.4% of samples showed a single diploid peak. Rats treated group with both *N. sativa* and DAB showed a diploid DNA peak in 80% of samples with disappearance of the abnormal aneuploid peak that was detected in the DAB treated group. However, 20% of liver samples showed aneuploidy. On the other hand, the S phase fraction was recorded as 4.6 vs. 5.1 vs. 15.1 vs. 9.8 in untreated control, *N. sativa*, DAB only, and *N. sativa* with DAB treated groups respectively, indicating a significant elevation in DAB treated group versus the others (Figure 3)

Table (1): The levels of the ALT, AST, total protein, albumin, and ALP recorded in the different experimental groups.

	ALT	AST	Total protein	Albumin	ALP
Control	8.67± 1.91	98.67 ± 12.87	7 ± 0.25	3.31 ± 0.17	19.92 ± 1.92
DAB	9.93 ± 4.01	108.86 ± 16.63	6.83 ± 0.35	2.72 ± 0.17	28.49± 4.72
N.S	7.92 ± 1.61	100.62 ± 10.56	6.87 ± 0.27	2.97 ± 0.22	19.56± 1.92
N.S. + DAB	8.79± 2.15	103.36 ± 11.90	6.81 ± 0.23	2.78 ± 0.23	23.46 ± 5.76

N.S: *Niglla sativa*; DAB : Dimethylaminoazobenzene.

Table (2): The level of liver MDA and antioxidant enzyme activity (SOD, CAT, and GST-Px) recorded in different groups.

*Significant compared to control

Groups	Liver MDA (nmol/g protein)	Liver CAT (U/mg protein)	Liver SOD (U/mg Protein)	Liver GSP-PX (U/mg Protein)
Control	22.6 ± 2.4	9.81 ± 0.76	72 ± 7	5.97 ± 0.48
DAB	110 ± 12.4*	5.96 ± 0.56*	32 ± 6*	3.37 ± 0.29*
N.S	24.8 ± 7.5	9.06 ± 0.9	68 ± 8	6.09 ± 0.50
N.S. + DAB	45.4 ± 4.2	7.06 ± 0.18	65 ± 7	5.90 0.73

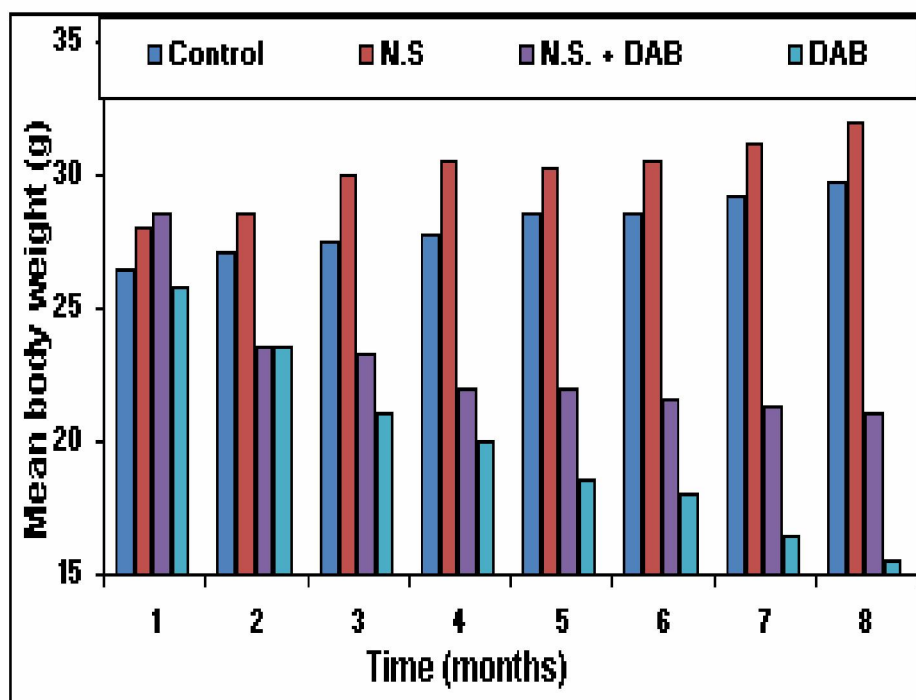


Figure (1): Gradual change in the mean body weight (gm) of control and treated animals

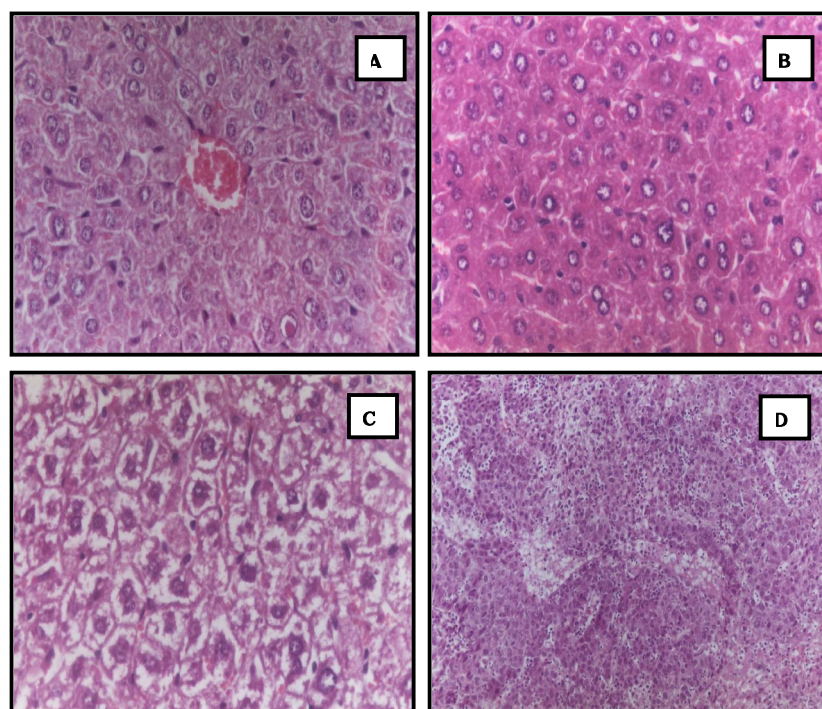


Figure (2): Histomorphology examination of different tissues. (A) Liver tissue section of control group stained by hematoxylin and eosin showing normal hepatic architecture[x 400], (B) Liver tissue section of treated group with *N. sativa* showing no changes in liver cells and bile ducts [x 400], (C) Liver tissue section of animal treated with DAB with *N. sativa* group showing mild dysplasia of hepatic cells [x 400], (D) Liver tissue section of treated group with DAB only showing liver cirrhotic nodules and bile duct proliferation [x 400].

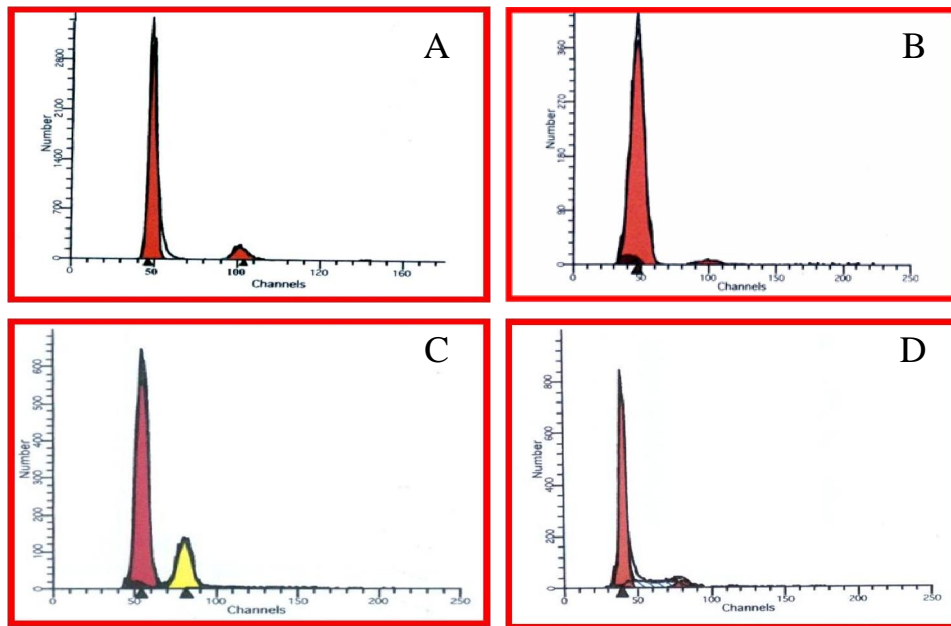


Figure (3): Flow cytometric analysis (A) Control untreated group (one diploid peak); (B) N.S treated group (one diploid peak); (C) DAB treated group (aneuploid peakpattern) and (D) DAB+N.S treated group (one diploid peak with SPF)

DISCUSSION

The liver is the primary target for carcinogen effect of more than two hundred chemicals (including pesticides, food additives, pharmaceuticals, and industrial intermediates) tested in long-term toxicity safety assessment assays [26]. Some of these harmful agents for the liver are carbon tetrachloride (CCl₄), N-methyl-N-nitrosourea, 1, 2-dimethylhydrazine, 3'-methyl-4-dimethylamino-benzene and ortho-aminoazotoluene. Dimethylaminoazobenzene (DAB) is a well known liver carcinogen induces multiple cellular, molecular, and biochemical changes [27-32].

In the current study, we sought the harmful effect of DAB on the rat liver and the possible ameliorating effect of *N. sativa* treatment in those animals. The results showed significant decrease in body weight in DAB, and DAB plus *N. sativa* treated groups compared to the untreated control group. These results in agreement with others who found weight loss in disturbed liver proliferation activity [27, 33]. There were no significant difference in ALT, AST, total proteins, and albumin in different groups. While Serum alkaline phosphatase showed significant increase in DAB treated group when compared to DAB plus *N. sativa* treated group and to normal control group. There is no significant difference between the DAB plus *N. sativa* group when compared to the normal control group. The present experimental model using DAB as a

hepatocarcinogen induce mainly cholangiocarcinoma and this might explain the normal level of ALT, AST, albumin and total proteins recorded. The present findings are in agreement with prior reports [33, 34].

The flow cytometric results showed that *N. sativa* treated group showed a single diploid peak similar to that of untreated control group, while rats treated with DAB, an additional aneuploid peak was detected. In case of DAB plus *N. sativa* treated group, it was found that most of samples had a diploid DNA peak without the aneuploid one. The present result is in agreement with other reports that showed the aneuploid pattern in majority of cases bearing adenocarcinoma of the extrahepatic bile ducts [34, 35]. Histopathological results *N. sativa* treated group showed normal architecture of liver cells and bile ducts similar to that of untreated control group. In DAB treated group 42.9% of cases showed marked dysplasia of liver cells and cirrhotic liver nodules and the bile ducts showed well differentiated cholangiocarcinoma. Primary carcinoma of the liver can usually be classified as hepatocellular carcinoma (HCC) or cholangiocarcinoma (CC). Approximately 98% of liver cancer is HCC, which originates from the hepatocytes, and approximately 2% is CC, which originates from the epithelium of the intrahepatic bile duct. The carcinogenic mechanism of HCC correlates with chronic liver disease and with

persistent HBV or HCV infection, but CC has no relation to viral hepatitis. Combined hepatocellular-cholangiocarcinoma is a rare form of primary liver cancer with features of both hepatocellular and biliary epithelial differentiation [36]. There are many molecular alterations associated with CC including p53 mutation, cyclins, proliferation indices, mucins, CA19-9, and aneuploidy appear to hold significant potential as predictors of outcome in CC [37]. CC is ideally induced using DAB carcinogen in experimental rats [27, 38]. The current study showed in cases treated with DAB plus *N. sativa*, most of the harmful alterations were apparently corrected. These results are comparable with the findings of others [34], and the antitumor action was recorded in addition to hepatobiliary cancers, in different other tumors [6, 11], and this action may strongly relates to the chemical composition and activity of *N. sativa*.

The results of the current study indicated that a pronounced elevation of MDA in the DAB treated group that was accompanied with lowering the levels of antioxidant enzymes investigated. These results clearly indicate that DAB is affecting the liver negatively by increasing the level of peroxidation and meanwhile decreasing the level of antioxidant protecting enzymes. Moreover, since no differences were existed between the other three groups, reflecting that the *N. sativa* treatment have no harmful effect on the liver, and the *N. sativa* combined with DAB treatment can effectively maintain the protective enzymatic balance effectively. The prominent antioxidant activity of *N. sativa* was extensively documented in different experimental situations, including hepatocarcinogenesis [39-43]. It has been shown that both the fixed oil of *N. sativa*, as well as thymoquinone (the main compound of the essential oil), inhibit non-enzymatic lipid peroxidation in liposomes [44]. Using thin-layer chromatography (TLC), it has also been shown that compounds isolated from *N. sativa* (including thymoquinone carvacol, t-anethole and 4-terpineol) have appreciable free radical scavenging properties [5]. These compounds were found in a series of other *in vitro* tests to have antioxidant activity, but no prooxidant properties. The antioxidant action of *N. sativa* may explain its claimed usefulness in folk medicine. This antioxidant property would explain its action against CCl₄ hepatotoxicity [14], liver fibrosis and cirrhosis [45], and hepatic damage induced by *Schistosoma mansoni* infection [46].

Collectively, these results give clear evidence that *Nigella sativa* lonely induce no harmful effects on the liver. Moreover, it exerts hepatoprotective effect against hepatobiliary carcinogens. Antioxidant property is mediated its actions and investigating other underlying mechanisms merits further studies.

Corresponding Author

Ibrahim Helmy El-Sayed, Molecular Biology Department, Genetic Engineering and Biotechnology Research Institute, Minufiya University, Sadat City, P.O. Box 22857-79, Minufiya, Egypt. Tel: 002048-601265, Fax: 002048-601268, Mobil; 002124252842, E mail: ibrahimelsayed@yahoo.com

REFERENCES

1. Fong TL, Kanel GC, Conrad A, Valinluck B, Charboneau F, Adkins RH. Clinical significance of concomitant hepatitis C infection in patients with alcoholic liver disease. *Hepatology* 1994; 19: 554-557.
2. Lee SE, Steiner M, Lin RI. Thiallyl compounds: potent inhibitors of cell proliferation. *Biochim Biophys Acta* 2005; 122: 73-77.
3. Harvey AL. Medicines from nature: are natural products still relevant to drug discovery. *Trends in Pharmacological Sciences* 1999; 20:196-198.
4. Vihan VS, Panwar HS. Galactopoitic effect of *Nigella sativa* in clinical cases of galactia goats. *Indian Vet J* 2006; 64: 247-249.
5. Burits M, Bucar F. Antioxidant activity of *Nigella sativa* essential oil. *Phytotherapy Research* 2000; 14: 323-328.
6. Ali BH, Blunden G. Pharmacological and toxicological properties of *Nigella sativa*. *Phytotherapy Research* 2003; 17: 299-305.
7. Swamy SMK, Tan BKH. Extraction, isolation and characterization of antitumor Principle, -hederin from the seeds of *Nigella sativa*. *Planta Medica* 2001; 67: 29-32.
8. Al-Naggar TB, Gomez-Serranillos MP, Carreto ME, Villar AM. Neuropharmacological activity of *Nigella sativa* L. extracts. *Journal of Ethnopharmacology* 2003; 88: 63-68.
9. Al-Johar D, Shinwari N, Arif J, Al-Sanea N, Jabbar AA, El-Sayed R, Mashhour A, Billedo G, El-Doush I, Al-Saleh I. Role of *Nigella sativa* and a number of its antioxidant constituents towards azoxymethane-induced genotoxic effects and colon cancer in rats. *Phytother Res* 2008; 22: 1311-1323.
10. Norwood AA, Tucci M, Benghuzzi H. A comparison of 5-fluorouracil and natural chemotherapeutic agents, EGCG and thymoquinone, delivered by sustained drug delivery on colon cancer cells. *Biomed Sci Instrum* 2007; 43: 272-277.
11. Ait Mbarek L, Ait Mouse H, Elabbadi N, Bensalah M, Gamouh A, Aboufatima R,

- Benharref A, Chait A, Kamal M, Dalal A, Ziad A. Anti-tumor properties of black seed (*Nigella sativa* L.) extracts. *Braz J Med Biol Res* 2007; 40: 839-847.
12. Abdel-Salam IM, Amira R, Hassan AM. Radio-protective effects of *Nigella Sativa* oil on the liver of Swiss albino mice. *J Egypt Bioch* 1998; 16: 167-176.
 13. Mansour MA. Protective effect of thymoquinone and desferrioxamine against hepatotoxicity of carbon tetrachloride in mice. *Life Sci* 2000; 66: 2583-2591.
 14. Nagi MN, Alam K, Badary OA, Al-Shabanah OA, Al-Sawaf HA, Al-Bekairi AM. Thymoquinone protects against carbon tetrachloride hepatotoxicity in mice via an antioxidant mechanism. *Biochem Mol Biol Int* 1999; 47:153-159.
 15. Enomoto S, Asano R, Iwahori Y, *et al.* Hematological studies on black cumin oil from the seeds of *Nigella sativa* L. *Biol Pharm Bull* 2001; 24:307-310.
 16. Hanafy MSM, Hatem ME. Studies on the antimicrobial activity of *Nigella sativa* seed (black cumin). *J Ethnopharmacol* 1991; 34: 275-278.
 17. Salem ML, Hossain MS. Protective effect of black seed oil from *Nigella sativa* against murine cytomegalovirus infection. *Int J Immunopharmacol* 2000; 22:729-740.
 18. Swamy SM, Tan BK. Cytotoxic and immunopotentiating effects of ethanolic extract of *Nigella sativa* L. seeds. *J Ethnopharmacol* 2000; 70:1-7.
 19. Zerín M, Karakılıçık Z, Arslan O, Vural H. Effects of vitamin C and E on erythrocyte osmotic fragility (EOF) and some hematological parameters in experimental aflatoxicosis of rabbits. *Turkiye Klinikleri J Med Sci* 2002; 20:11-15.
 20. Murray RK, Granner DK, Mayes PA, Rodwell VW. *Harper's Biochemistry*. 22nd Norwalk: Mc Graw-Hill; 1988. p574-576.
 21. Winterbourn CC, Hawkins RE, Brian M, Carrell RW. The estimation of red cell superoxide dismutase activity. *J Lab Clin Med* 1975; 85:337-341.
 22. Flohe L, Gunzler WA Assays of glutathione peroxidase. *Methods Enzymol* 1984; 105:114-121.
 23. Beers RF, Sizer IW. A spectrophotometric method for measuring the breakdown of hydrogen peroxide by catalase. *J Biol Chem* 1952; 195:133-134.
 24. Ohkawa H, Ohishi N, Yagi K. Assay for lipid peroxides in animal tissues by thiobarbituric acid reaction. *Anal Biochem* 1979; 95:351-358.
 25. Lowry OH, Rosebrough NJ, Farr AL, Randall RJ. Protein measurement with the folin phenol reagent. *J Biol Chem* 1951; 193:265-275.
 26. Ward JM, Shibata MA, Devor DE. Emerging tissue in mouse liver carcinogenesis. *Toxicol Pathol* 2005; 24: 129-137.
 27. Daoust R, Cantero A. The numerical proportions of cell types in rat liver during carcinogenesis by 4-Dimethylaminoazobenzene (DAB). *Cancer Research* 1959; 19: 757- 762.
 28. De Lamirande G. Protein bound dye and purine catabolizing enzymes in parenchymal and non-parenchymal cells of rats fed 4-dimethylamine- azobenzene (DAB). *Cancer Res* 1964; 24:742-750.
 29. El-Aaser AA, Ibrahim HA, Abdeen AM, Akl SA. Effect of soybean feeding on experimental carcinogenesis. 1. Hepatocarcinogenesis by para-dimethylaminoazobenzene (DAB) in rats fed soybean: histopathological and histochemical studies. *J Egypt Natl Cancer Inst* 1986; 2; 443- 453.
 30. Brière N, Daoust R. Histochemical studies on rat liver proteins during 4-dimethylaminoazobenzene carcinogenesis. *Cancer Research* 1970; 30:1370-1375.
 31. Sessa A, Desiderio MA, Baizini M, Perin A. Diamine oxidase activity in regenerating rat liver and in 4-dimethylaminoazobenzene-induced and Yoshida AH 130 hepatomas. *Cancer Research* 1981; 41; 1929-1934.
 32. Pakharukova MY, Smetanina MA, Kaledin VI, Kobzev VF, Romanova IV, Merkulova TI. Activation of constitutive androstane receptor under the effect of hepatocarcinogenic aminoazo dyes in *mouse* and rat liver. *Byulleten' Eksperimental'noi Biologii i Meditsiny*, 2007; 144: 316-319.
 33. Zibari GB, Riche A, Zizzi HC, McDonald JC. Surgical and nonsurgical management of primary and metastatic liver tumors. *Am Surg* 2003; 64: 211-221.
 34. Abdel-Salam M, Abu-Bedair FA, El-Huseiny S, Ali RM, Raafat A, El-Aaser AA. Protective Effect of *Nigella Sativa* during hepatocarcinogenesis induced by dimethyl aminoazobenzene (DAB) in Rat. *Arab J Lab Med* 2001; 27: 133-141.
 35. Brunt EM, Kraemer BB. DNA image analysis study of lesions of the gall bladder and biliary system. *Liver Transpl Surg* 2001; 2: 284-289.
 36. Hsu H-M, Liu Y-C, Chen T-W, Chao D-G. Combined hepatocellular

- cholangiocarcinoma: A case report and review of the literature. *J Med Sci* 1999; 20:84-89.
37. Briggs CD, Neal CP, Mann CD, Steward WP, Manson MM, Berry DP. Prognostic molecular markers in cholangiocarcinoma: A systematic review. *European Journal of Cancer* 2009; 45: 33 – 47.
 38. Reddy KP, Buschmann RJ, Chomet B. Cholangiocarcinomas induced by feeding 3'-methyl-4-dimethylaminoazobenzene to rats: histopathology and ultrastructure. *Am J Pathol* 1977; 87:189-204.
 39. Mansour MA, Ginawi OT, El-Hadiyah T, El-Khatib AS, Al-Shabanah OA, Al-Sawaf HA. Effects of volatile oil constituents of *Nigella sativa* on carbon tetrachloride-induced hepatotoxicity in mice: evidence for antioxidant effects of thymoquinone. *Res Commun Mol Pathol Pharmacol* 2001; 110: 239-251.
 40. El Gendy S, Hessien M, Abdel Salam I, Morad M, El-Magraby K, Ibrahim HA, Kalifa MH, El-Aaser AA. Evaluation of the possible antioxidant effects of soybean and *Nigella Sativa* during experimental hepatocarcinogenesis by nitrosamine precursors. *Turkish Journal of Biochemistry* 2007; 32; 5–11.
 41. Mabrouk GM, Moselhy SS, Zohny SF, Ali EM, Helal TE, Amin AA. Inhibition of methylnitrosourea (MNU) induced oxidative stress and carcinogenesis by orally administered bee honey and *Nigella* grains in Sprague Dawley rats. *J Exp Clin Cancer Res*. 2002; 21: 341-346.
 42. Ilhan A, Gurel A, Armutcu F, Kamisli S, Iraz M. Antiepileptogenic and antioxidant effects of *Nigella sativa* oil against pentylenetetrazol-induced kindling in mice. *Neuropharmacology* 2005; 49; 456- 464.
 43. Mariod AA, Ibrahim RM, Ismail M, Ismail N. Antioxidant activity and phenolic content of phenolic rich fractions obtained from black cumin (*Nigella sativa*) seedcake. *Food Chemistry* 2009; 116: 306–312.
 44. Houghton PJ, Zarka R, de las Heras B, Hoult JRS. 1995. Fixed oil of *Nigella sativa* and derived thymoquinone inhibit eicosanoid generation in leukocytes and membrane lipid peroxidation. *Planta Med* 61: 33–36.
 45. Türkdogan MK, Agaoglu Z, Yener Z, Sekeroglu R, Akkan HA, Avci ME. The role of antioxidant vitamins (C and E), selenium and *Nigella sativa* in the prevention of liver fibrosis and cirrhosis in rabbits, new hopes. *Dtsch Tierarzt Wschr* 2000; 108: 71–73.
 46. Mahmoud MR, El-Abhar HS, Saleh S. The effects of *Nigella sativa* oil against the liver damage induced by *Schistosoma mansoni* in mice. *J Ethnopharmacol* 2002; 79: 1–11.

7/7/2010